

MRgFUS treatment of uterine fibroid in a nulliparous woman with acute retention of urine

Vinay Nyapathy^{1*}, Laveena Polina¹

1. Department of Radiology, Godavari imaging sciences and research centre & GSL medical college, Rajahmundry, Andhra Pradesh, India

* Correspondence: Dr. Vinay Nyapathy. M.D., Godavari imaging sciences and research centre, Rajahmundry, Andhra Pradesh, India
(✉ drvinay02@yahoo.co.in)

Radiology Case. 2012 Feb; 6(2):1-8 :: DOI: 10.3941/jrcr.v6i2.809

ABSTRACT

Uterine fibroids are the most common tumors of the female reproductive tract. Although most fibroids are asymptomatic, about 25% are associated with symptoms that can have a significant impact on patient's quality of life, including prolonged or excessive menstrual bleeding, pelvic pain or bulkiness, dyspareunia, increased urinary frequency, and infertility. Various treatment options available for symptomatic uterine fibroids include hysterectomy, myomectomy (abdominal or laparoscopic), uterine artery embolization, MR-guided Focused Ultrasound (MRgFUS), and hormonal therapy, which also is sometimes used as adjuvant to other therapies. MRgFUS is a non-invasive treatment approach for symptomatic uterine fibroids. The following case report demonstrates successful treatment of a fibroid that is hyper-intense on T2WIs by MRgFUS with immediate alleviation of pressure symptoms on the urinary bladder.

CASE REPORT

CASE REPORT

A 44-year-old unmarried, nulliparous Indian woman, BMI of 24.5 with a large posterior myometrial uterine fibroid was referred to our center with Foley's catheterization of the urinary bladder for acute retention of urine that occurred one week prior. She also complained of fluctuations in the duration and length of her monthly cycle, heavy bleeding, passing clots during menstrual cycle, fatigue and back pain for the past six months and amenorrhea for the past two months. Her Symptom Severity Score (on the 0 to 100 Scale of the UFS-QoL questionnaire [1]) was 47.5 points.

The patient was referred for MRI screening to evaluate her suitability for the MRgFUS treatment. MRI showed a single large intramural fibroid in the posterior myometrium measuring 9.0 x 5.6 x 7.2cm (cranio-caudal x AP x transverse) with a volume of 176cc on T2WI. Intensity of the fibroid relative to the uterine wall was hyperintense on T2WIs, and its texture was very heterogeneous (Figure 1). To evaluate the fibroid's viability more fully, and as part of our screening routine for MRgFUS, SPGR (Spoiled gradient recalled acquisition in the steady state) images with contrast were

acquired. Post-gadolinium contrast images revealed enhancement. (Figure 2)

After consulting with the patient about the potential benefits and risks involved in treating her specific fibroid, she chose to undergo MRgFUS, knowing that results might be less than satisfactory due to the hyperintense appearance of her fibroid. Treatment was performed using the ExAblate 2000 system (InSightec, Haifa, Israel) and SIGNA HDxt 1.5T MRI (GE Healthcare, Milwaukee, U.S.).

On the day of the MRgFUS treatment, the patient was administered conscious sedation (one ample of Fentanyl) to alleviate pain and reduce motion. Bowels obstructed the beam path to the myoma. To remove the obstruction resulting from the presence of bowels between the transducer and the myoma, the bladder was filled using Foley's catheter with 150 cc of saline. A rectal balloon was placed, and as it was inflated the bladder was synchronously emptied to push the uterus towards the anterior abdominal wall (Figure 3).

T2WIs were acquired for treatment planning. Treatment duration was 120 minutes (from first to last sonication) using 75 focal spots or sonications (Figure 4) with a mean energy of

2345 Joules and a frequency of 1.15MHz . Temperature achieved, was in the range of 55-75°C. Contrast enhanced spoiled gradient recalled acquisition in the steady state (SPGR) images were acquired five minutes post treatment, showing non-perfused volume of 100cc (Figure 5) achieving a NPV ratio of 54%

Treatment was completed without complications, and the patient was discharged 30 minutes later. The Foley's catheter was removed after 6hours. During her follow up phone call the next day, she reported that she could pass urine normally and was feeling well with no adverse events. Two days later she also informed that she had her menstrual cycle. In a phone call seven-day post treatment, the patient said she was feeling better and that her symptoms have decreased a lot. In follow up, the patient had persistent improvement of her symptoms and was completely asymptomatic at 6 month's post treatment. No recurrence of urinary retention was noted. Her symptom severity scores were 25 and 20 (the least on the scale) at 3 and 6 month's post treatment respectively.

DISCUSSION

Uterine fibroids or myomas are the commonest uterine neoplasms of unknown etiology. Fibroids have been reported to occur in up to 70% of women by the age of 50 years[2]. Black race, heredity, nulliparity, obesity, polycystic ovary syndrome, diabetes and hypertension are associated with increased risk for fibroids[3]. Although most fibroids are asymptomatic, about 25% are associated with symptoms that can have a significant impact on patient's quality of life, including prolonged or excessive menstrual bleeding, pelvic pain or bulkiness, dyspareunia, increased urinary frequency, and infertility[4]

On ultrasound, fibroids appear as well defined echogenic or hypoechoic solid masses with a degree of posterior acoustic shadowing even in non-calcified fibroids. CT scan is not the investigation of choice for the characterization of pelvic masses. The typical finding is a bulky irregular uterus or a mass in continuity with the uterus. Degenerate fibroids show complex appearance. On contrast-enhanced scans, fibroids usually show low attenuation relative to the myometrium.

MRI is the most sensitive method for accurately diagnosing uterine fibroids. Typically, non-degenerate fibroids are well-defined masses of low-signal intensity as compared to the myometrium on T2WI images and isointense to the myometrium on T1WI images. Degenerated fibroids show complex appearance with heterogeneous or high signal on T2WI images.

Focal adenomyosis is the major imaging differential for a fibroid. On ultrasound adenomyosis appears as a hypoechoic heterogeneous myometrial mass with ill defined margins and in contiguity with the junctional zone. CT findings include uterine enlargement, myometrial thickening and multiple small cystic areas within the myometrium. On MR there is focal or diffuse thickening of the junctional zone (> 12mm), an ill-

defined low signal intensity myometrial mass with high signal intensity foci on T1WI and T2WI. Focal adenomyosis shows ill defined margins and causes no mass effect whereas fibroids are well defined, have a fibrous capsule and cause mass effect.

Women who wish to undergo treatment for symptomatic relief from uterine myomas while retaining the possibility of future pregnancies can currently choose among several options, ranging from surgery to less invasive approaches [5]. As all surgeries carry potential risks (operative, anesthetic, or infection) and possible complications, (uterine rupture and increased likelihood for a Caesarian delivery) patients may opt for less invasive alternatives, which will also allow them to return to their daily activities faster. [5,6]

Myomectomy is a commonly done procedure to remove the myomas. However, this is a major abdominal procedure, and especially in the case of intramural myomas, the morbidity of the intervention may outweigh the benefits of removing the myomas. Besides surgical issues such as infection and blood loss, removing myomas may also impair fertility by inducing the formation of surgical adhesions.

Uterine artery embolization has recently been offered as a treatment option for women with myomas who have a desire for future fertility. However, this approach is associated with an increased rate of caesarian delivery along with a relatively higher percentage of complications (miscarriage, preterm delivery, intrauterine growth restriction, abnormal placentation, malpresentation, and postpartum hemorrhage) [7] suggesting that further study is required before the use of this procedure becomes widespread in this patient population.

MRgFUS is a non-invasive treatment approach for symptomatic uterine fibroids. This procedure is non-invasive, thus avoiding scar formation in the uterus. Several clinical studies demonstrate that MRgFUS is a safe and effective treatment for symptomatic uterine fibroids [8,9,10]

Magnetic resonance imaging-guided focused ultrasound surgery (MRgFUS) is currently used in our center for the treatment of symptomatic uterine myomas. It utilizes precisely focused ultrasound waves to generate and maintain high temperatures within the targeted fibroid, resulting in protein denaturation and coagulative necrosis [4]

The treatment procedure incorporates a 1.5T MRI scanner (Signa HDxt , GE Healthcare, Milwaukee, WI, USA) along with a focused ultrasound system (ExAblate 2000, Insightec, Haifa, Israel). The patient table docks to the MR scanner and houses the phased array transducer in a sealed water bath. The patient lies prone and a gel pad is used to couple the patient's abdomen to the transducer.

Coronal, sagittal and axial T2-weighted MR images are obtained to localize the lesion and to define the region of treatment (ROT). Based on tumor volume and depth, the system computes the energy and the number of focal energy deliveries (sonications) required to treat completely the defined region. The planned sonications can be modified interactively during the procedure to cover as much fibroid

volume as possible to achieve maximum tumor ablation. The skin lines, sensitive structures like bowel, bone are marked so that the ultrasound beam path doesn't pass through them. During treatment the ultrasound beam path can be angled by 20 degrees to avoid sensitive structures. Any bowel anterior to the uterus is mitigated by using techniques like bladder filling, rectal filling, cut gel pad.

The focused ultrasound system generates a high intensity acoustic beam (sonication) that is focused onto the target. Each sonication creates an elongated elliptical focus of high temperature (60-80°C), resulting in tissue necrosis. The heat generated during these sonications is monitored using real-time MR images acquired in three planes. Real-time thermal imaging is done by repeatedly performing phase-difference fast-spoiled gradient-echo MR imaging, or "phase map" imaging, at the targeted region before, during, and immediately after sonication. The images are compared and presented as a thermal map either as simple subtraction images or colorized with a threshold temperature. A graph of the temperature rise over time also is created to enable actual temperatures to be assessed at any point. The patient is asked to report sensations such as skin warmth or burning, back pain, or intense uterine cramping. Patients are provided with a stop sonication or panic button which they may press at any time to interrupt a treatment cycle, especially in the case of pain. Treatment parameters can be adjusted between sonications based on MR thermometry and patient feedback. This process is repeated till all the planned sonications are delivered. Each sonication lasts for approximately 15-20 seconds with a cooling time of about 90 seconds between sonications.

At the end of treatment, the results are evaluated by the non-perfused regions on contrast enhanced SPGR images. These areas are summed to create a volume, termed non-perfused volume (NPV). The ratio of the NPV to the volume of the myoma, the NPV ratio has been associated with treatment effectiveness and myoma shrinkage. [11,12]

In most of the previous studies, patients had scheduled follow-up at 3, 6, 12, and 24 months. SSS score was assessed at each follow up. Magnetic resonance imaging with gadolinium to assess the myoma sizes, nonperfused volume and nonperfused volume ratio was again performed at 6, 12, and 24 months after treatment. For our patients we assess the SSS score at 3, 6, 12, and 24 months and perform MR imaging with gadolinium at 12 and 24 months after treatment.

MRgFUS is a non-invasive, daycare procedure requiring no admission. Studies have shown that adverse events from MRgFUS are quite uncommon [13]. However both near and far field heating effects can occur. Poor coupling and scars in the ultrasound beam path can lead to skin burns. Awareness of scars in the treatment path, shaving of the skin and cleaning of the skin with alcohol has virtually eliminated skin burns. Inflammation of the fat and underlying abdominal wall musculature is one of the more commonly seen adverse effects, been reported in 11% of patients by So et al [14]. Fortunately, these inflammatory changes cause minimal if any post treatment discomfort to the patients. Damage to adjacent organs, such as bowel perforation, is also possible during

treatment but rare. Careful monitoring of real-time magnetic resonance images generated automatically with each sonication for changes in position of structures, such as bowel, uterus, or bladder, is important in minimizing the risk to the patient. In addition, targeting of the fibroid with a distance of 15 mm or more from the serosal surface is recommended to prevent injury to adjacent structures. Heating of the bony and neural structures in the far field can occur. Hindley et al in 109 patients treated, reported 1 case of a patient developing leg paresthesia, which completely resolved by 12 months. It is now recommended that sonications are performed at least 4 cm from bony structures to minimize the amount of heating of the bone, which can in turn heat the fat surrounding the nerves and lead to stimulation or potential damage of the nerve. Deep venous thrombosis can also occur due to the length of the procedure. The use of compression stockings can help decrease the already low likelihood of thrombosis.

MRgFUS is a suitable option for women with myomas who are seeking to retain their reproductive capabilities. A number of successful cases have been published [15,16,17,18] showing the feasibility of pregnancy following MRgFUS.

In our case, the woman was unmarried, nulliparous and wished to retain her reproductive abilities and opted for MRgFUS. While clinical studies demonstrate that MRgFUS is a safe and effective treatment for symptomatic uterine fibroids [8,9,10], not all patients are considered to be equally suitable candidates for the procedure [19]. Potential candidates are screened with pelvic MRI to determine if they meet patient selection guidelines. Factors considered for MRgFUS patient selection include the imaging characteristics and location of the fibroid within the pelvis, the number and size of fibroids, presence of structures obstructing the energy beam pathway, and the vicinity of the fibroid relative to vulnerable structures [20]. Exclusion criteria are, weight more than 115Kg, serious health complications, contraindications to MRI, massive abdominal scarring that cannot be avoided by manipulations or covered by a scar patch, uterine size more than 24 weeks, pedunculated fibroids, non-enhancing fibroids, heavily calcified fibroids.

One imaging characteristic considered in the patient selection process is the fibroid's capacity to absorb heat, as the effects of MRgFUS result from the thermal ablation of the fibroid tissue. This is often assessed based on the signal intensity of the fibroid compared with the surrounding myometrium on T2-weighted MR images (T2WIs). Previous reports suggest that the average nonperfused volume (NPV), as measured by post treatment, contrast-enhanced image, obtained with MRgFUS in the treatment of hyper-intense fibroids, is lower than that achieved in iso- or hypointense fibroids [19]. In our case, the fibroid was hyperintense and heterogenous but we could achieve a NPV of 54%, which led to immediate relief of the pressure effect on her urinary bladder. Six months post treatment the patient was completely asymptomatic. From this experience, we suggest that even in hyperintense fibroids, MRgFUS can attain a NPV significant enough to cause symptomatic relief.

TEACHING POINT

MR-guided Focused Ultrasound (MRgFUS) is a suitable treatment option for symptomatic myomas, especially in patients who wish to retain future fertility. Even in hyperintense fibroids, MRgFUS can attain a non perfused volume, significant enough to cause symptomatic relief. In patients with fibroids causing acute urinary retention, MRgFUS can produce immediate symptomatic relief.

REFERENCES

1. Spies JB, Coyne K, Guaou Guaou N, Boyle D, Skyrnarz-Murphy K, Gonzalves SM. The UFS-QOL, a new disease-specific symptom and health-related quality of life questionnaire for leiomyomata. *Obstetrics and Gynecology*. 2002; 99(2):290-300. PMID:11814511
2. Day Baird D, Dunson DB, Hill MC, Cousins D, Schectman J. High cumulative incidence of uterine leiomyoma in black and white women: Ultrasound evidence. *Am J Obstet Gynecol* 2003;188:100-07. PMID: 12548202
3. Okolo S. Incidence, aetiology and epidemiology of uterine fibroids: *Best Pract Res Clin Obstet Gynaecol*. 2008 Aug;22(4):571-88. PMID:18534913
4. Fennessy FM, Tempany CM. A review of magnetic resonance imaging-guided focused ultrasound surgery of uterine fibroids. *Topics in Magnetic Resonance Imaging*. 2006;17(3):173-179. PMID: 17414074
5. Somigliana E, Vercellini P, Daguati R, Pasin R, De Giorgi O, Crosignani PG. Fibroids and female reproduction: a critical analysis of the evidence. *Human Reprod Update* 2007;13:465-76. PMID: 17584819
6. Parker WH. Etiology, symptomatology, and diagnosis of uterine myomas. *Fertil Steril* 2007;87:725-36. PMID:17430732
7. Walker WJ, McDowell SJ. Pregnancy after uterine artery embolization for leiomyomata: a series of 56 completed pregnancies. *Am J Obstet Gynecol* 2006;195:1266-71. PMID:16796984
8. Morita Y, Ito N, Ohashi H. Pregnancy following MR-guided focused ultrasound surgery for a uterine fibroid. *International Journal of Gynecology and Obstetrics*. 2007;99(1):56-57. PMID:17599842
9. Rabinovici J, Inbar Y, Revel A, et al. Clinical improvement and shrinkage of uterine fibroids after thermal ablation by magnetic resonance-guided focused ultrasound surgery. *Ultrasound in Obstetrics and Gynecology*. 2007;30(5):771-777. PMID: 17899577
10. Stewart EA, Gostout B, Rabinovici J, Kim HS, Regan L, Tempany CMC. Sustained relief of leiomyoma symptoms by using focused ultrasound surgery. *Obstetrics and Gynecology*. 2007;110(2):279-287. PMID:17666601
11. Funaki K, Fukunishi H, Funaki T, Sawada K, Kaji Y, Maruo T. Magnetic resonance-guided focused ultrasound surgery for uterine fibroids: relationship between the therapeutic effects and signal intensity of preexisting T2-weighted magnetic resonance images. *Am J Obstet Gynecol* 2007;196:184.e1-6. PMID:17306674
12. Morita Y, Ito N, Hikida H, Takeuchi S, Nakamura K, Ohashi H. Non-invasive magnetic resonance imaging-guided focused ultrasound treatment for uterine fibroids - early experience. *Eur J Obstet Gynecol Reprod Biol* 2008;139:199-203. PMID:18160200
13. Hesley GK, Gorny KR, Henrichsen TL, Woodrum DA, Brown DL. A clinical review of focused ultrasound ablation with magnetic resonance guidance: an option for treating uterine fibroids. *Ultrasound Q*. 2008 Jun;24(2):131-9. PMID:18528271
14. So MJ, McDannold N, Fennessy FM, et al. Evaluation of the impact of body mass and abdominal fat on MR-guided focused ultrasound surgery for uterine fibroids. *Proc Int Soc Magn Reson Med*. 2005; 13:2141.
15. Rabinovici J, Inbar Y, Eylon SC, Schiff E, Hananel A, Freundlich D. Pregnancy and live birth after focused ultrasound surgery for symptomatic focal adenomyosis: a case report. *Hum Reprod* 2006;21:1255-9. PMID:16410334
16. Gavriloja-Jordan LP, Rose CH, Traynor KD, Brost BC, Gostout BS. Successful term pregnancy following MR-guided focused ultrasound treatment of uterine leiomyoma. *J Perinatol* 2007;27:59-61. PMID:17180132
17. Hanstede MM, Tempany CM, Stewart EA. Focused ultrasound surgery of intramural leiomyomas may facilitate fertility: a case report. *Fertil Steril* 2007;88:497.e5-7. PMID:17292361
18. Morita Y, Ito N, Ohashi H. Pregnancy following MR-guided focused ultrasound surgery for a uterine fibroid. *Int J Gynaecol Obstet* 2007;99:56-7. PMID:17599842
19. Funaki K, Sawada K, Maeda F, Nagai S. Subjective effect of magnetic resonance-guided focused ultrasound surgery for uterine fibroids. *Journal of Obstetrics and Gynaecology Research*. 2007;33(6):834-839. PMID:18001451
20. Yoon S-W, Lee C, Cha SH, et al. Patient selection guidelines in MR-guided focused ultrasound surgery of uterine fibroids: a pictorial guide to relevant findings in screening pelvic MRI. *European Radiology*. 2008;18(12):2997-3006. PMID:18618119

FIGURES

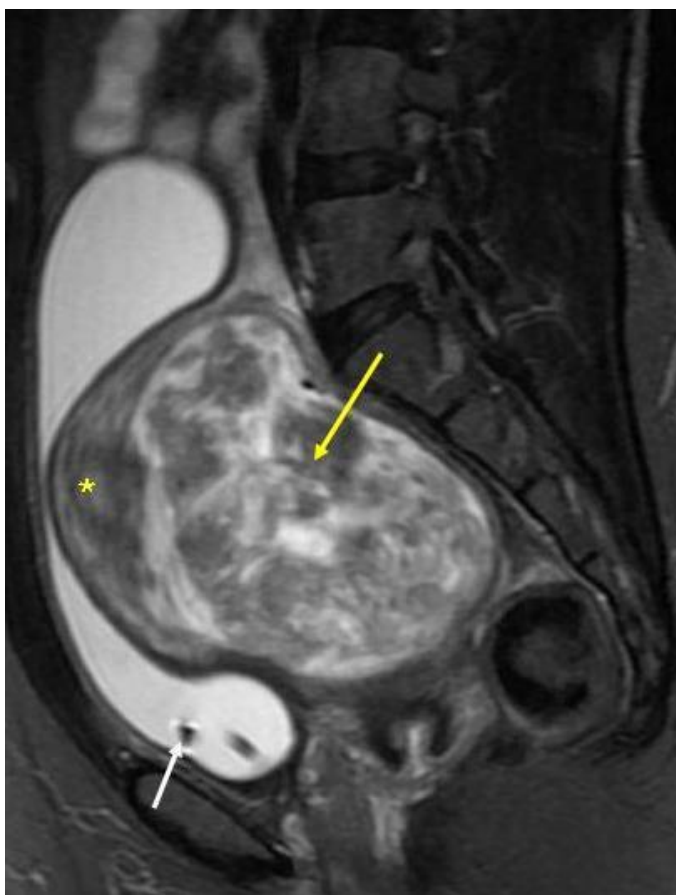

Figure 1 (left): 44 year old nulliparous woman with intramural fibroid and acute retention of urine. T2WI fat suppressed sagittal screening MR of the pelvis shows a heterogenous fibroid (yellow arrow), hyperintense relative to the uterine wall (asterix). Note the Foley's bulb in urinary bladder (white arrow) (Protocol: 1.5T MRI, TR: 5560ms, TE: 105.3ms)

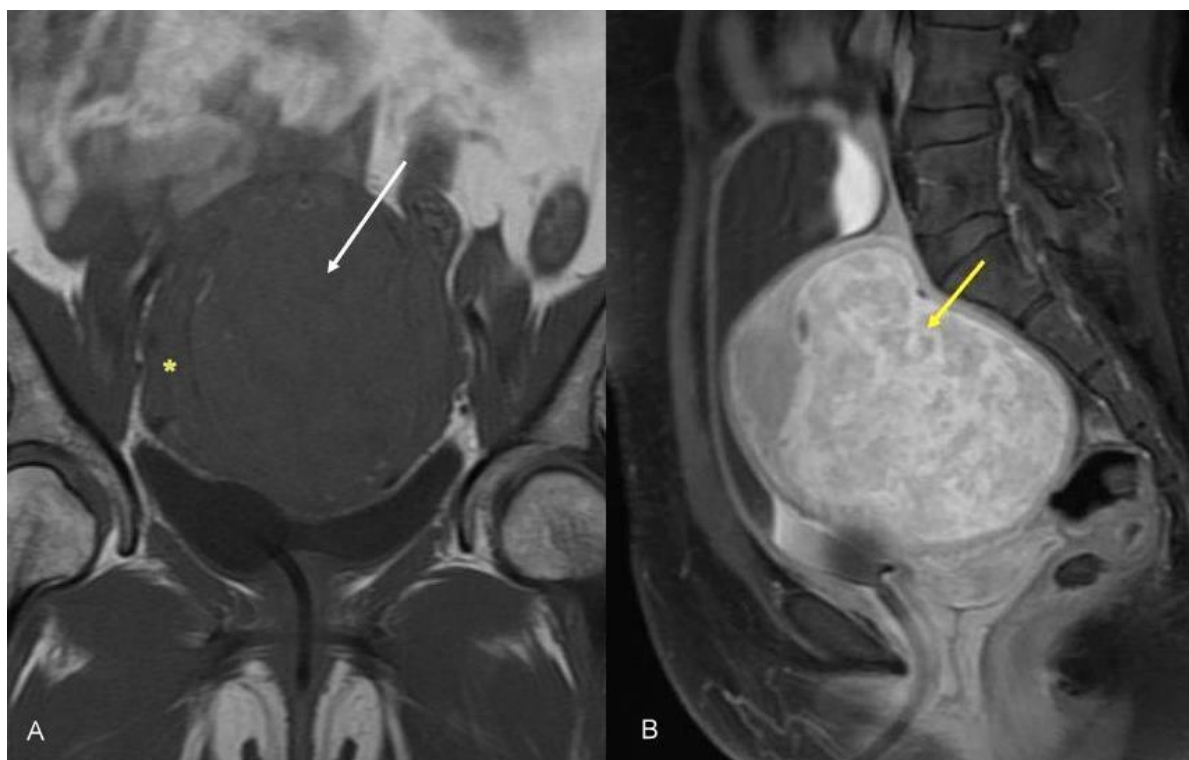

Figure 2: 44 year old nulliparous woman with intramural fibroid and acute retention of urine. A: T1WI coronal screening MR of the pelvis shows the fibroid (white arrow) isointense relative to the uterine wall (asterix). B: Contrast enhanced SPGR sagittal screening MR of the pelvis shows enhancement of the fibroid (yellow arrow). (Protocol- A: 1.5T MRI, TR: 720ms, TE: 13.2ms) (Protocol- B: 1.5T MRI, TR: 900ms, TE: 13.2ms, 10ml gadodiamide USP [Omniscan])

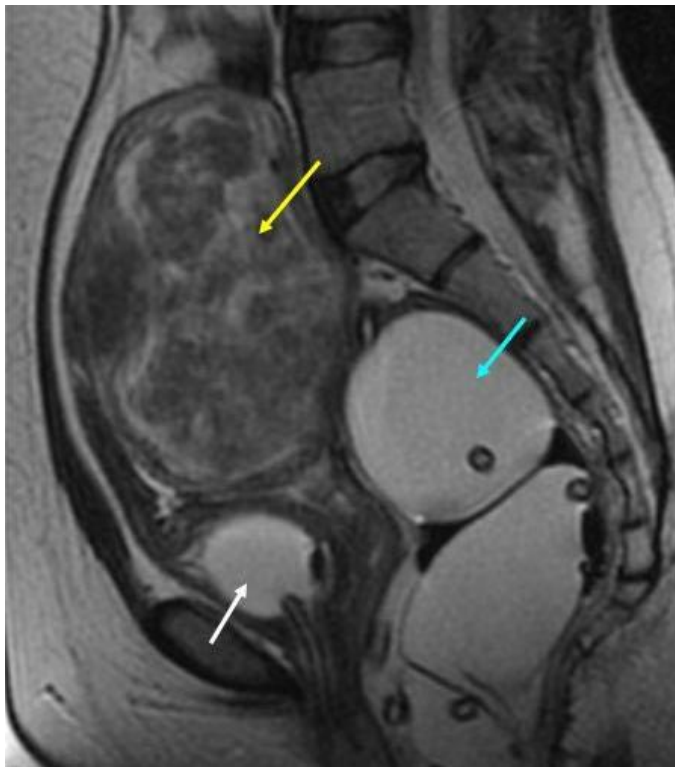

Figure 3 (left): 44 year old nulliparous woman with intramural fibroid and acute retention of urine. T2WI sagittal MR of the pelvis during treatment planning shows an inflated rectal balloon (blue arrow), empty urinary bladder with Foley's in situ (white arrow) bringing the fibroid (yellow arrow) close to the anterior abdominal wall. (Protocol: 1.5T MRI, TR: 4200ms, TE: 86.6ms)

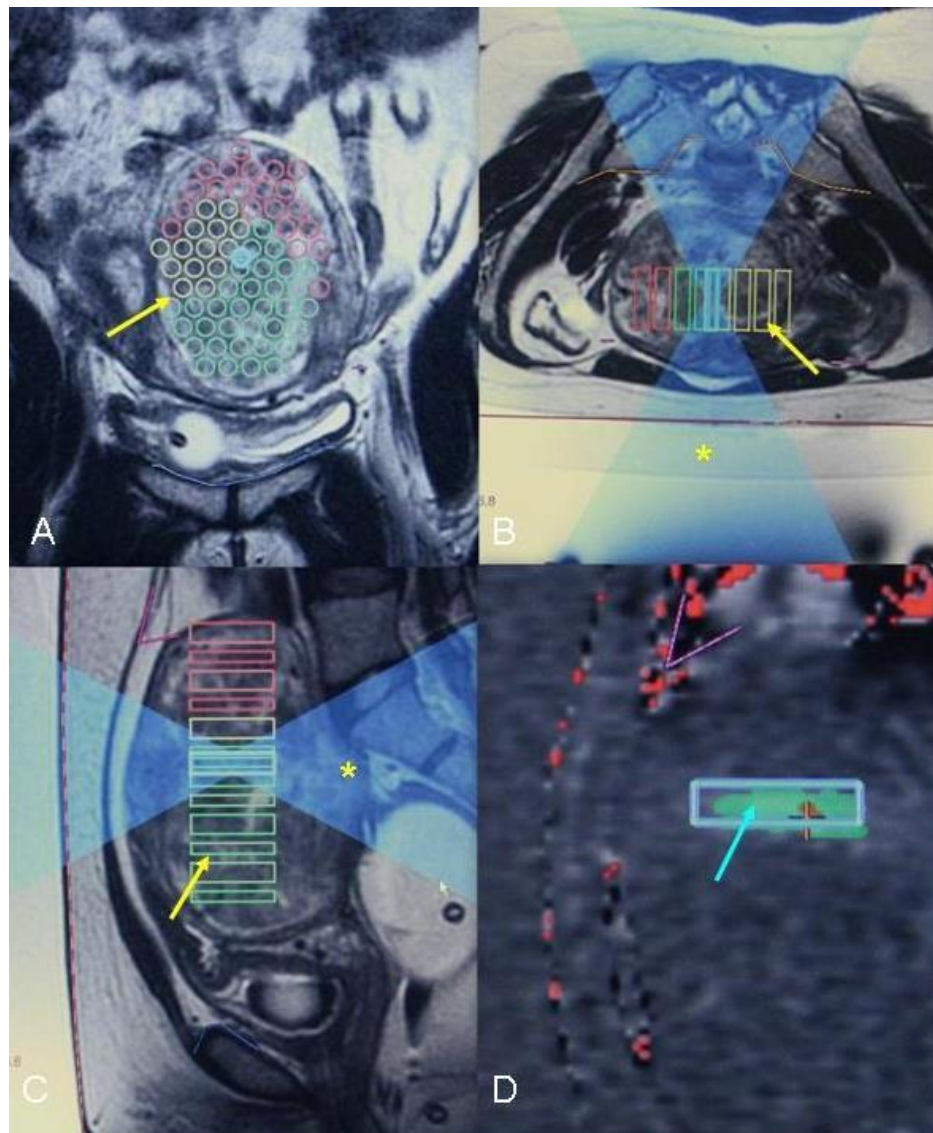


Figure 4 (left): 44 year old nulliparous woman with intramural fibroid and acute retention of urine. Coronal (A), axial (B) and sagittal (C) T2WI images obtained during treatment showing sonication spots (yellow arrow) and ultrasound beam path(*)
 Red line: skin surface; blue line: pubic bone; yellow line: far field; pink line: bowel. FigD: post sonication image showing sonicated spot (blue arrow)
 (Protocol: 1.5T MRI+ ExAblate 2000, TR: 4200ms, TE: 86.8ms)

Journal of Radiology Case Reports

www.RadiologyCases.com

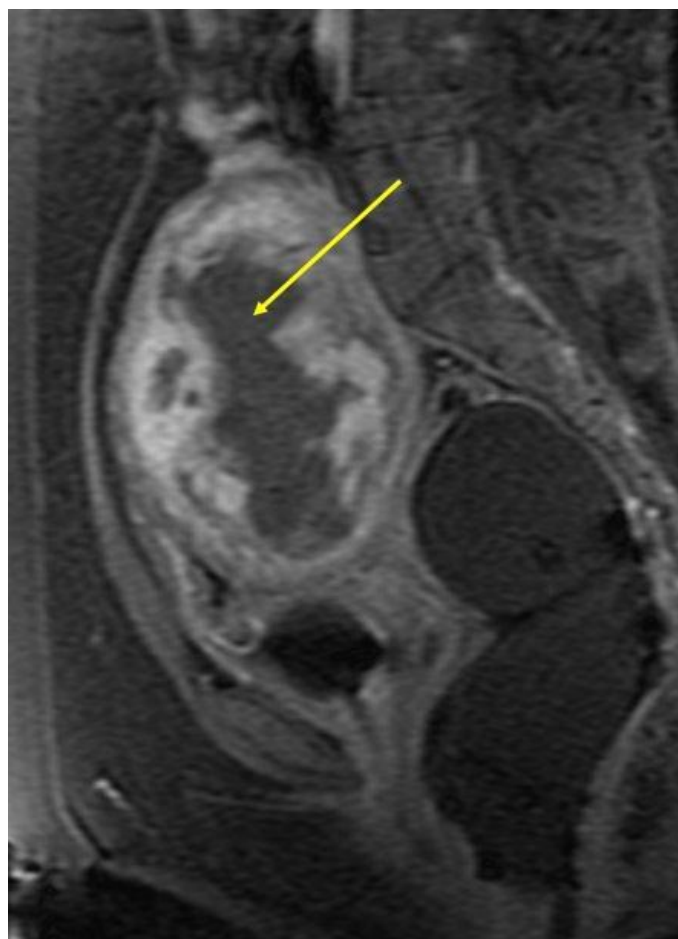


Figure 5 (left): 44 year old nulliparous woman with intramural fibroid and acute retention of urine. Contrast enhanced spoiled gradient recalled acquisition in the steady state(SPGR) sagittal MR of the pelvis after MRgFUS treatment shows non enhancing area (arrow) corresponding to non-perfused volume of 54% (Protocol: 1.5T MRI, TR: 260ms, TE: 1.4ms, 10ml gadodiamide USP [Omniscan])

Etiology	Unknown
Incidence	70% of women by the age of 50 years.
Age predilection	> 30years
Risk factors	Black race, heredity, nulliparity, obesity, polycystic ovary syndrome, diabetes and hypertension.
Symptoms	Prolonged or excessive menstrual bleeding, pelvic pain or bulkiness, dyspareunia, infertility and symptoms related to the pressure effects on the urinary and gastro-intestinal tracts.
Treatment	Frequently asymptomatic. Treatment is required in 25%.Treatment options include hysterectomy, myomectomy (abdominal or laparoscopic), uterine artery embolization, MR-guided Focused Ultrasound (MRgFUS), and hormonal therapy
Prognosis	Benign tumor. Excellent prognosis.
Findings on imaging	<u>Ultrasound:</u> well defined echogenic or hypoechoic solid mass. Calcifications+/- <u>CT:</u> Bulky irregular uterus or a mass in continuity with uterus. Degenerated fibroids: complex appearance. Low attenuation compared to myometrium on contrast scans. <u>MR:</u> Well-defined masses of low-signal intensity as compared to the myometrium on T2WI images and isointense to the myometrium on T1WI images. Degenerated fibroids show complex appearance with heterogeneous or high signal on T2WI images.

Table 1: Summary table of uterine fibroid

	ULTRASOUND	CT	MRI
FIBROID	Well defined echogenic or hypoechoic solid mass. Calcifications+/-. Mass effect present.	Bulky irregular uterus or a mass in continuity with uterus. Degenerated fibroids: complex appearance. Low attenuation compared to myometrium on contrast scans.	Well-defined masses of low-signal intensity as compared to the myometrium on T2WI images and isointense to the myometrium on T1WI images. Degenerated fibroids show complex appearance with heterogenous or high signal on T2WI images.
FOCAL ADENOMYOSIS	Hypoechoic heterogenous myometrial mass with ill defined margins and in contiguity with junctional zone. No mass effect.	Enlarged uterus, myometrial thickening, multiple small cystic areas	Focal or diffuse thickening of junctional zone(> 12mm). Ill-defined low signal intensity myometrial mass with high signal intensity foci on T1WI and T2WI. No mass effect.

Table 2: Differential table of uterine fibroid

ABBREVIATIONS

BMI: Body mass index.
 CT: Computed tomography
 MR: Magnetic resonance imaging.
 MRgFUS: MR-guided Focused Ultrasound
 NPV: Nonperfused volume
 SPGR: Spoiled gradient recalled acquisition in the steady state
 SSS: Symptom severity score
 T1WI: T1 weighted imaging
 T2WI: T2 weighted imaging
 UFS-QoL: Uterine Fibroid Symptom and Quality of Life questionnaire

KEYWORDS

MRgFUS; Fibroid; Acute bladder retention; Nulliparous

ACKNOWLEDGEMENTS

We would like to thank senior technician Mr. Narsing Rao and team for the technical support.

Online access

This publication is online available at:
www.radiologycases.com/index.php/radiologycases/article/view/809

Peer discussion

Discuss this manuscript in our protected discussion forum at:
www.radiopolis.com/forums/JRCR

Interactivity

This publication is available as an interactive article with scroll, window/level, magnify and more features.
 Available online at www.RadiologyCases.com

Published by EduRad



www.EduRad.org