


Impact of geometric mean imaging in the accurate determination of partial function in MAG3 renal scanning in a patient with retroperitoneal mass

Mustafa Takesh^{*1, 2}, Christian M. Zechmann¹, Sabine Haufe¹,
Frederik L. Giesel¹, Clemens Kratochwil¹

1. Department of Nuclear Medicine, University of Heidelberg, Heidelberg, Germany

2. Department of Nuclear Medicine, Damascus University, Damascus, Syria

* **Correspondence:** Dr. Mustafa Takesh, University Heidelberg, Dept. of Nuclear Medicine, Im Neuenheimer Feld 400, D - 69120 Heidelberg, Germany

 Mustafa.Takesh@med.uni-heidelberg.de

Radiology Case. 2011 June; 5(6):9-17 :: DOI: 10.3941/jrcr.v5i6.711

ABSTRACT

Liposarcoma frequently occurs in the retroperitoneum and lower extremities, accounting for 20% of all mesenchymal malignancies. Liposarcomas vary by histology and can be classified into four types. Those four types are well differentiated, myxoid/round cell, pleomorphic and dedifferentiated. Due to retroperitoneal location of this tumor, it is expected to affect the kidney position. Renography has provided a unique tool for noninvasive evaluation of various functional parameters e.g. relative renal function. Most renography studies are carried out using the posterior view, under the assumption that the depths of both kidneys are similar so that the radiotracer counts in the region of interest will be attenuated to the same extent. Errors in estimation of the relative renal function may arise if the kidneys are at different depths e.g. secondary to a pushing tumor. Geometric mean imaging from combined anterior and posterior views helps to overcome this issue. This case shows the impact of geometric mean imaging in the truthful determination of partial function in patients with retroperitoneal liposarcoma.

CASE REPORT

CASE REPORT

A 72-years-old female patient with a diagnosis of dedifferentiated retroperitoneal liposarcoma was referred to perform renal scan. The purpose was to assess the function of contralateral kidney, since the respective tumor dwells close to the right kidney (surgeon's plan was tumor resection associated with adjacent kidney).

Furthermore the patient had to undergo bone scan (BS) to exclude bone metastases before the operative management. In the absence of morphological images (MRI was at that time not available) the radionuclide renography was carried out as usual using a single-head camera, so that the quantification was performed based on posterior images. The ratio was: left 85 %, right 15 % (Fig: 1).

In the light of this result the removal of the tumor mass including the right kidney seemed not to have a significant negative influence on the total renal function, because the partial function of the right kidney contributed anyway to a small extent in the entire function.

However an abnormal uptake discovered by bone scan in the ventral abdomen region urged us to perform a morphological correlation study. According to MRI-imaging an ectopic position (ventral) of the right kidney due to anterior displacement by a mass was demonstrated. Hence the right kidney position was responsible for the equivocal uptake detected by BS (FIG.2-3). Consequently there was a need to repeat the renal scan using geometric mean technique, so that the relative right to left renal function assessment would be less affected by kidney depth.

The corrected ratio was then: left 41%, right: 59% (Fig-4). Although the new ratio demonstrated a dominance of the right kidney this kidney had to be removed due to potential tumor infiltration. However, the new results enabled us to estimate correctly the remaining renal function after nephrectomy.

This case illustrates the value of using simultaneous anterior and posterior imaging and geometric mean calculations for a correct functional analysis in a case of a retroperitoneal mass resulting in renal displacement. Moreover, this case shows the importance of considering the morphological imaging before the renal scan. In this case a balanced left / right kidney function was misdiagnosed due to ectopic position of one kidney caused by a retroperitoneal liposarcoma.

DISCUSSION

Liposarcoma is the most common type of soft tissue sarcoma and accounts for approximately 20% of all mesenchymal malignancies. According to the current World Health Organization classification, liposarcoma is divided into four main subtypes: atypical lipomatous tumor/well-differentiated liposarcoma (ALT/WDL); myxoid/round cell liposarcoma; dedifferentiated liposarcoma (DDL); and pleomorphic liposarcoma. ALT/WDL is further subdivided into four subtypes: adipocytic (lipoma-like) liposarcoma; sclerosing liposarcoma; inflammatory liposarcoma; and spindle cell liposarcoma SCLS [1].

Dedifferentiated liposarcoma is a special type of liposarcoma in which transition from low-grade to high-grade nonlipogenic morphology within a well-differentiated liposarcoma is observed. The transition usually occurs in an abrupt fashion. However, in rare cases it can be more gradual. Recently, it also has been proposed that dedifferentiated liposarcoma should be further classified into low and high grade [2]. Dedifferentiated liposarcoma is most commonly located in the retroperitoneum, consisting of well-differentiated liposarcoma close to a pleomorphic sarcoma. On CT and MR images, dedifferentiated liposarcoma is seen as well-defined non-lipomatous mass juxtaposed with fatty tumor. On T1- weighted MR images, signal is hypointense relative to the muscle, whereas on T2-weighted MR images, the tumor is heterogeneous hyperintense relative to muscle signal (Fig. 5).

The tumor extent should be defined with caution. Since the fat components of the tumor could easily be mistaken for adjacent normal fat structures. As a consequence the missed tumor components could be left after surgical resection. The presence of calcification or ossification and the first recurrence after a mean of 13 months are significant adverse prognostic factors for primary dedifferentiated liposarcoma of the retroperitoneum [3].

Radionuclide renography is used extensively in the assessment of renal function. Parameters describing both the ability of the kidneys to extract radiopharmaceuticals from the blood and also their rate of transit through the kidney are obtained. One particular parameter of interest that is regularly

used clinically is the relative, right to left, renal function (RRF) [4].

Based on kinetic, renal radiopharmaceuticals can be divided into two broad classes -those that are excreted rapidly into the urine and those that are retained for prolonged periods in the renal parenchyma. In the first category are ^{99m}Tc mercaptoacetyltriglycine (MAG3), ^{99m}Tc diethylenetriamine pentaacetic acid (DTPA), I-131-orthoiodohippurate (I-131-OIH). In the second category are ^{99m}Tc- Dimercaptosuccinic acid (DMSA) and ^{99m}Tc Glucoheptonate (GHA) [5].

Because of its ready availability and excellent imaging characteristics MAG3 is considered as favored agent for dynamic renography [6]. If only RRF is required, then static renal imaging using ^{99m}Tc-dimercaptosuccinic acid (^{99m}Tc-DMSA) is preferable. However, the benefit of using ^{99m}Tc-mercaptoacetyltriglycine (^{99m}Tc-MAG3) is that it offers the possibility to evaluate both - the renal transit and RRF - simultaneously in one session.

The first minute after radiotracer administration represents the vascular delivery phase, the next 2 min constitute the parenchymal phase. Uptake in the kidney during this interval, i.e. between 1 and 3 min after radiotracer injection is proportional to its function using either tubular or glomerular agents. In practice, renal counts of the radiotracer are obtained over a 1-min period (typically between 1 and 2 min for ^{99m}Tc-MAG3), and expressed as a percentage of combined renal counts [5].

Accurate determination of individual renal function requires ureteric catheterization to assess clearance from each kidney. This technique is not only invasive, but is also time consuming and requires surgical expertise to perform. Using radionuclide techniques it is possible to assess differential renal function quite simply and noninvasively [7]. Most renal scans are carried out using the posterior view. Counts in the region of interest will be attenuated by a varying amount related to the thickness of tissue between the kidney and camera.

In normal cases it can be assumed to a rational approximation that attenuation of left and right kidney counts is equal by posterior analysis. Before validating this assumption we should make sure that both kidneys are at the same distance from the detector. This can be achieved by considering morphological images, when available. One of the principal sources of error in assessing both absolute and relative renal function from renography using posterior imaging is due to attenuation of gamma rays.

It has been shown that reasonably accurate assessment of renal depth is possible from lateral imaging taken at the end of the renography study. However, these images suffer from a variety of complicating factors. First, the images are often of poor quality due to low counts and uptake, as the kidneys may have low activity at the end of study. Furthermore, it is often difficult to distinguish the two kidneys as their images on a lateral view overlap. Geometric mean imaging represents a relatively simple adaptation to conventional posterior

renography which helps to overcome this complexity [8]. It is therefore reasonable to consider the use of geometric mean renography as an optimal procedure to avoid the effect of depth differences in calculating the RRF (relative renal function), especially when anatomical abnormalities are suspected (e.g. pushing tumor).

In our case the imaging in both anterior and posterior projections resulted in an accurate assessment of right renal function and should be considered in all cases of suspected ectopic kidney. The importance of anterior and posterior dual detector imaging in retroperitoneal mass is due to the tumor being located between the kidney and the posterior detector. This results in an increasing attenuation, and therefore imaging and analysis using routine posterior acquisition may result in underestimating the contribution of the displaced kidney in the total function.

TEACHING POINT

Kidney position is most likely to be altered in case of retroperitoneal mass, making the utilization of single-head gamma camera invalid in evaluating the renal function. Instead, the geometric mean using dual-headed gamma camera should be highly considered, so that this assessment will be less affected by kidney location.

REFERENCES

1. Shioi Y, Hasegawa T, Otsuka K, et al. Primary retroperitoneal spindle cell liposarcoma: Pathological and immunohistochemical findings. *Pathology International* 2010;60(6):472-6. PMID: 20518903
2. Dei Tos AP. Liposarcoma: new entities and evolving concepts. *Ann Diagn Pathol.* 2000;4(4):252-66. PMID: 10982304
3. Shin NY, Kim MJ, Chung JJ, Chung JY, Choi JY, Park YN. The differential imaging features of fat-containing tumors in the peritoneal cavity and retroperitoneum: the radiologic-pathologic correlation. *Korean J Radiol.* 2010;11(3):333-45. PMID: 20461188
4. Fleming JS. A technique for analysis of geometric mean renography. *Nucl Med Commun.* 2006;27(9):701-8. PMID: 16894324
5. Salil D, Sarkar, Pravin C. Singhal Basis of Renal Scintigraphy in: *The Pathophysiologic Basis of Nuclear Medicine.* 2nd ed New York, 2006, 249-163.
6. Michael Hoskinson, Keevin Bernstein, *Kidney in: Nuclear Medicine* 1rd ed, Georgetown, Texas 2003, 163-195.
7. Wujanto R, Lawson RS, Prescott MC, Testa HJ. The importance of using anterior and posterior views in the calculation of differential renal function using 99m Tc-DMSA. *Br J Radiol* 1987;60(717):869-72. PMID: 2822198
8. Lessne ML, Shah NP, Stinchon JF, Cross ME, Oates ME. Optimal scintigraphic evaluation of a hydronephrotic horseshoe kidney. *J Nucl Med Technol.* 2007;35(4):255-58. PMID: 18055697
9. Yapar AF, Aydin M, Reyhan M, Yapar Z, Sukan A. The conditions for which the geometric mean method revealed a more accurate calculation of relative renal function in 99mTc-DMSA scintigraphy. *Nucl Med Commun.* 2005; 26(2):141-6. PMID: 15657508
10. Hervás I, Martí JF, González A, et al. Is the depth correction using the geometric mean really necessary in a 99Tcm-DMSA scan in the paediatric population? *Nucl Med Commun.* 2001;22(5):547-52. PMID: 11388577
11. Porn U, Rossmüller B, Alalp S, Fischer S, Dresel S, Hahn K. Calculation of the partial function of the kidney with DMSA in pediatrics: is the evaluation of the geometric mean necessary? *Nuklearmedizin.* 2001;40(4):107-10. [Article in German] PMID: 11556199
12. Henricks WH, Chu YC, Goldblum JR, Weiss SW. Dedifferentiated liposarcoma: A clinicopathological analysis of 155 cases with a proposal for an expanded definition of dedifferentiation *Am J Surg Pathol.* 1997;21(3):271-81. PMID: 9060596

FIGURES

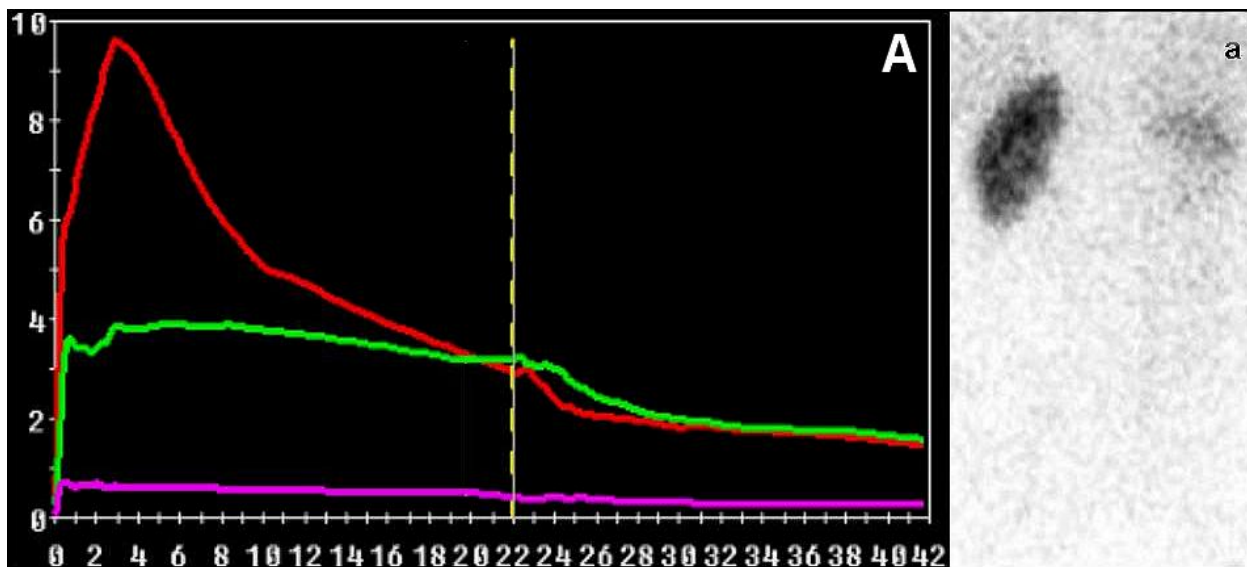


Figure 1: A 72-year-old female patient with retroperitoneal liposarcoma referred for renal scan. Dynamic renal scan after application of 70 MBq (1.9 mCi) ^{99m}Tc -MAG3 with a single head gamma camera (dorsal view). The balance of kidney function was calculated with 15% right and 85% left derived from time activity curves (A). The scintigraphic picture 2 min. p.i. showed a decreased tracer uptake of the right kidney (a). According to this result the removal of the tumor mass including the right kidney seemed acceptable, because the partial function of the right kidney contributes solely to a small extent in the entire function. (red curve = left kidney, green curve = right kidney)

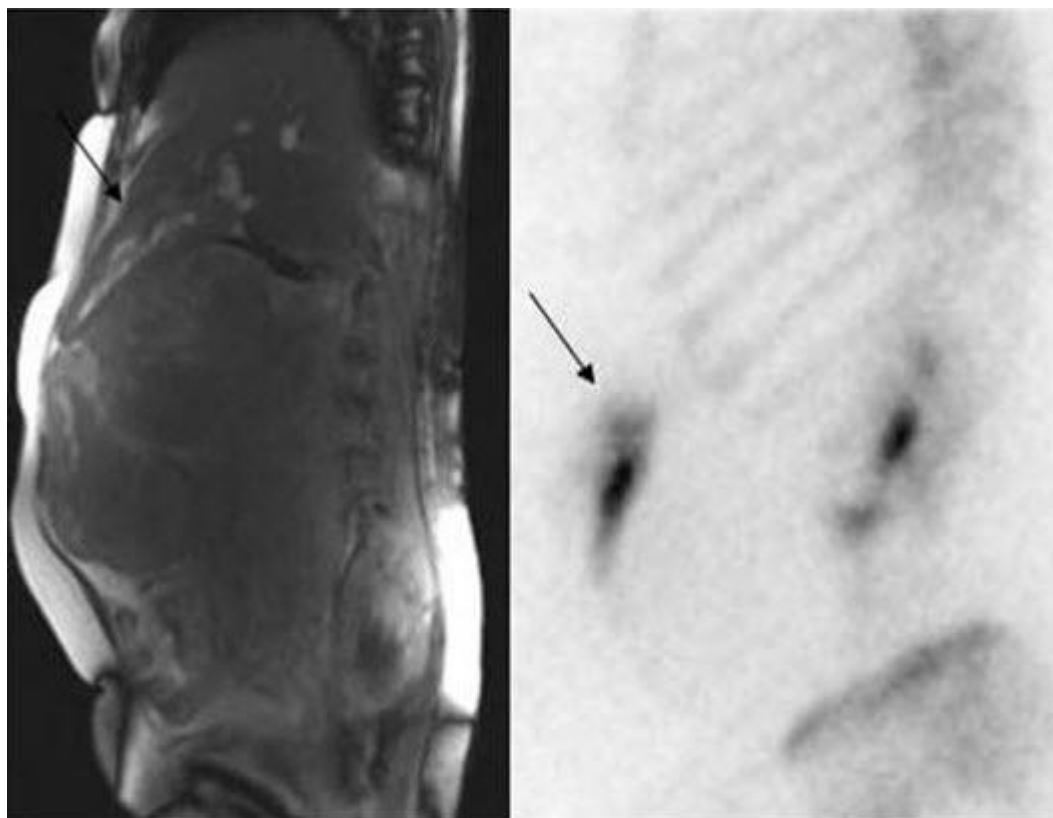


Figure 2: A 72 year old female patient with retroperitoneal liposarcoma referred for bone scan to exclude possible bone metastasis before the surgical management. Lateral spot imaging (lateral view) of bone scan 2 hours after application of 696 MBq (18.8 mCi) ^{99m}Tc methylene diphosphonate (MDP) showing an ectopic position of the right kidney (arrow right) corresponding with T2-weighted sagittal MRI (arrow left).

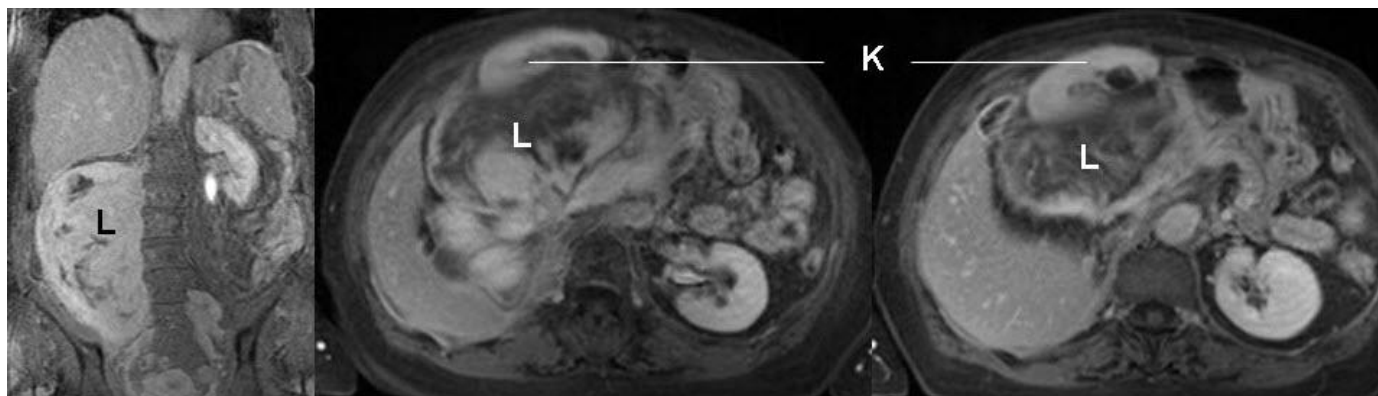


Figure 3: A 72 year old female patient with retroperitoneal liposarcoma. Left: MR-imaging with T1-weighted contrast enhanced coronal view presenting a large retroperitoneal liposarcoma extending vertically from the upper right abdomen to the pelvis with 22 x 15 x 25 cm. Mid and right: Transversal T1-weighted MR-images (two different slices) show this mass extending anteriorly towards the anterior abdominal wall, causing ventral displacement of the right kidney. Hence the distance to the dorsal detector of the gamma camera is 21cm whereas this distance (kidney to dorsal detector) is 8 cm on the left side. In this case we should not consider the renal scan (dorsal view) as a meaningful test. (L = Liposarcoma, K = right kidney)

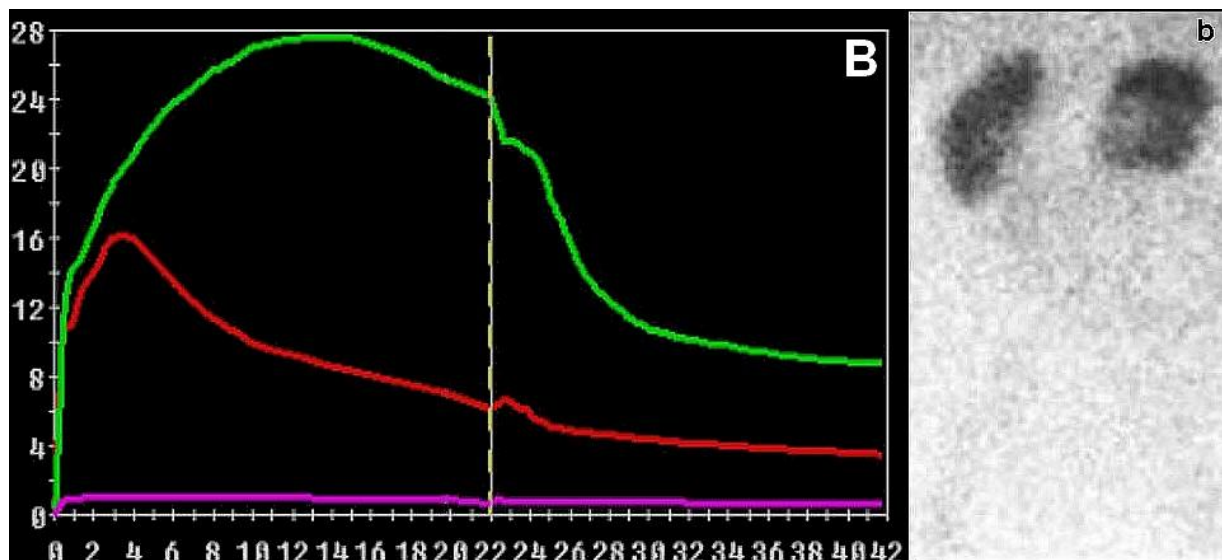


Figure 4: A 72 year old female patient with retroperitoneal liposarcoma referred for renal scan. Dynamic renal scan after application of 70 MBq (1.9mCi) ^{99m}Tc-MAG3 with a dual-head gamma camera using geometric mean performed two weeks after the first study. The contribution of each kidney to the total function was calculated with 59% for the right and 41% for the left kidney based on time activity curves (B). The scintigraphic picture 2 min. p.i. showed nearly the same tracer uptake of both kidneys (b). (red curve = left kidney, green curve = right kidney)

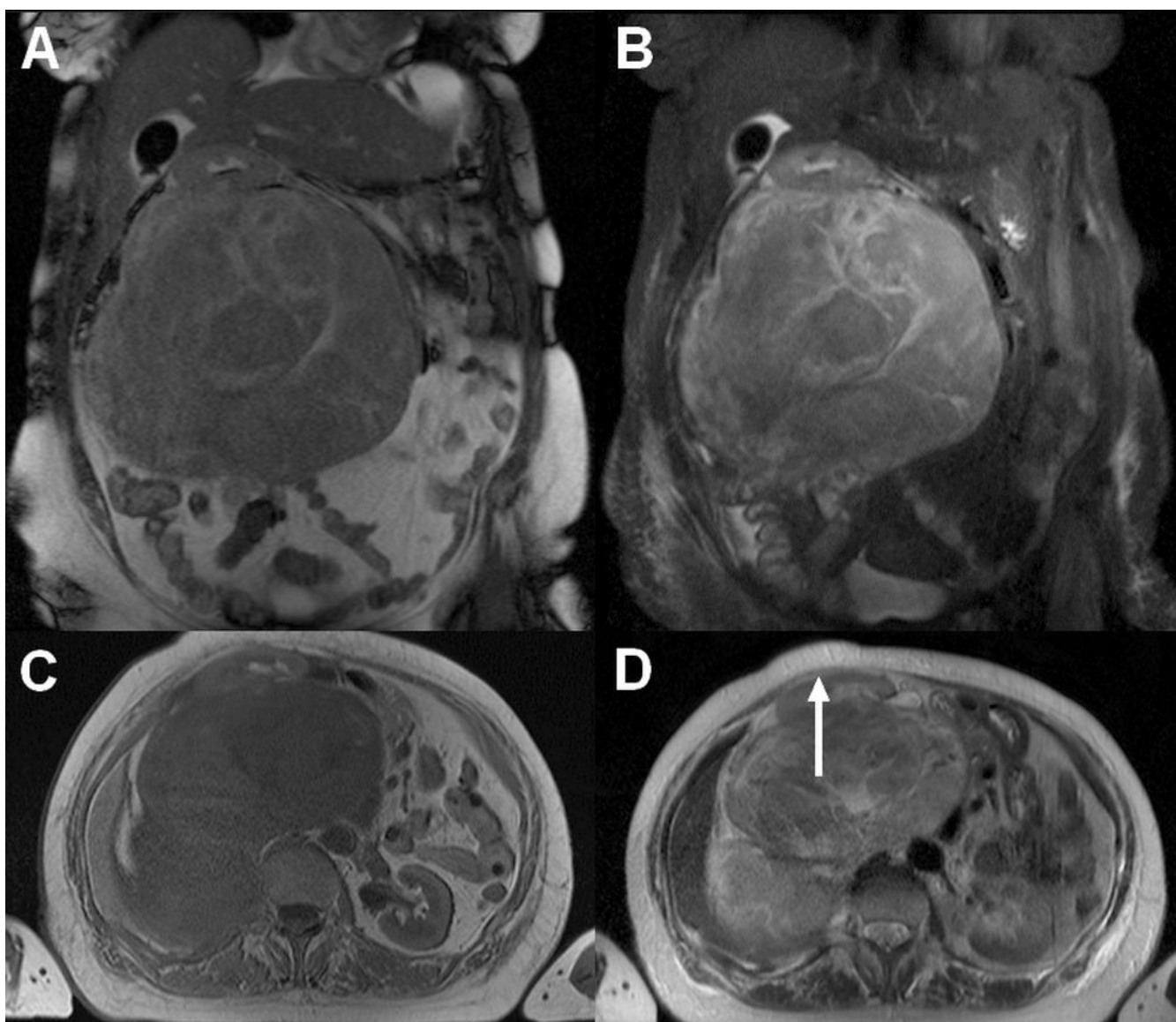


Figure 5: A 72 year old female patient with retroperitoneal liposarcoma; Coronal (A,B) and axial (C,D) MRI imaging (left: T1-weighted, right: T2-weighted). demonstrates a 22 x 15 x 25 cm mass in the right abdomen, showing T1 hypointense and T2 heterogeneous hyperintense relative to muscle.

This histologically confirmed liposarcoma resulted in anterior displacement of the right kidney towards the right anterior abdominal wall.

The axial images demonstrate clearly the tumor mass pressing against the right kidney (note the covering skin; arrow)

MR-Protocol: Siemens Avanto 1.5T,

Fig. 5a: T1 trueFISP (fast imaging with steady state precession) coronal; TR 437.2, TE 1.16, flip angle 65.

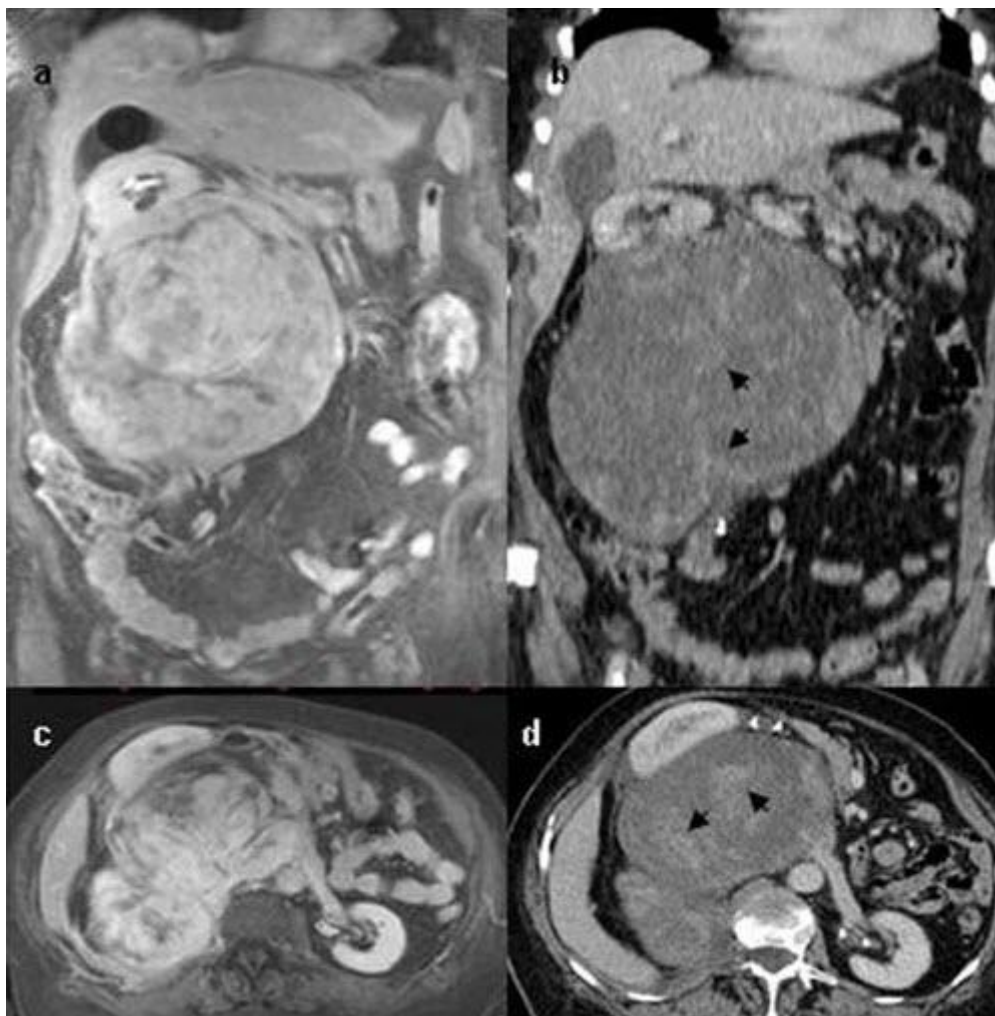


Figure 6: A 72 year old female patient with retroperitoneal liposarcoma Contrast-enhanced T1-weighted MRI (a,c axial and coronal) scan shows huge retroperitoneal liposarcoma resulting in anterior/cranial displacement of the right kidney towards the right anterior abdominal wall and demonstrating a heterogeneous enhancement. Contrast-enhanced CT scan right (b, d axial and coronal) shows slightly inhomogeneous, hypoattenuated mass compared with adjacent liver. Moreover the mass contains multiple thick irregular septa with delayed contrast enhancement (arrows). Bilateral ureteral stent catheter (d); note the right catheter is visible outside the renal collecting system ventral of the mass.

MR-Protocol: Siemens Avanto 1.5T:

Fig. 6a: post contrast (20ml Magnevist®), T1 VIBE (volume interpolated breathhold examination) coronal, TR 3.85, TE 1.34, flip angle 10.

Fig. 6c: T1 FLASH (fast low angle shot) 2D transversal, TR 145, TE 3.57, flip angle 70 post contrast (20ml Magnevist®).

CT-Protocol (Fig. 6b/d): Siemens-Somaris/5 3D Software version VA47C at 300 mAs and 120 kV, 3 mm slice thickness, contrast enhanced with 120 ml intravenous Omnipaque).

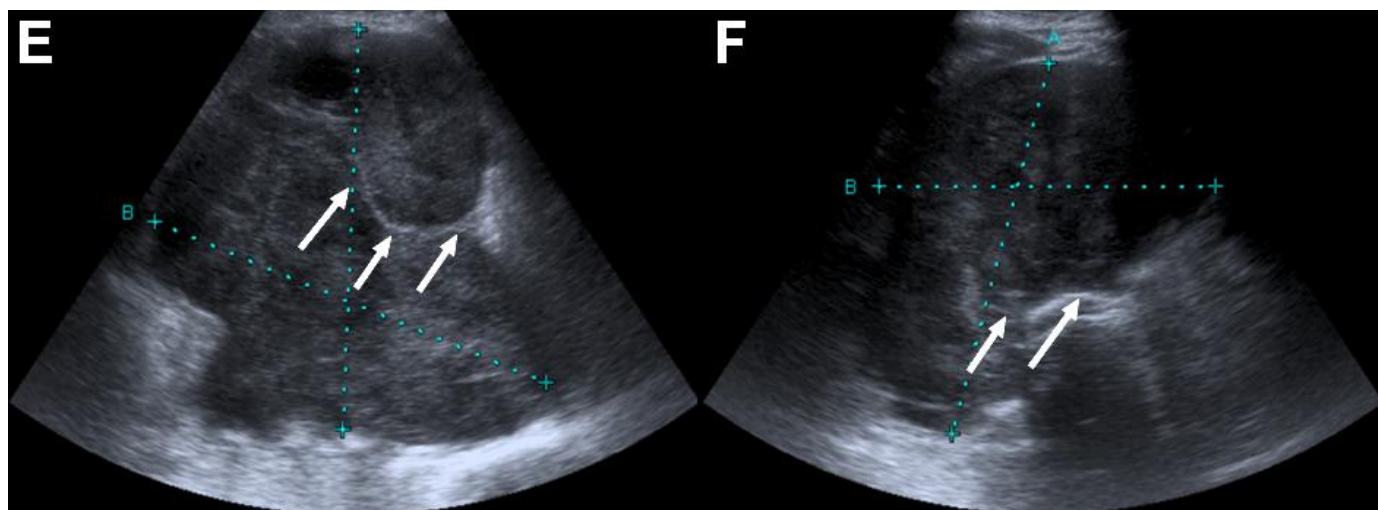


Figure 7: A 72 year old female patient with retroperitoneal liposarcoma Longitudinal (E) and transverse (F) sections of B-mode ultrasound images of the tumor show mixed echogenicity of the tumor the hyperechoic areal represents the fat component of the liposarcoma. See septae (arrow) within tumor.
(Ultrasound: Toshiba, curved array ultrasound probe with 3.5 MHz)

Etiology	Unknown
Incidence	Liposarcoma is the most common type of soft tissue sarcoma and accounts for approximately 20% of all mesenchymal malignancies.
Gender ratio	No specific gender ratio
Age predilection	Tumor occurs in late adult life (median, 61.5 years; range, 21-92 years)
Risk factors	Exactly unknown
Treatment	Surgical resection that is usually combined with the adjacent kidney.
Prognosis	For dedifferentiated liposarcoma prognosis is generally poor compared with the other types of liposarcoma. It shows high recurrence rate of 40-83%, metastasis rate of 15–30%, and an overall 5-year survival rate of 20%.
Findings on imaging	On CT and MR images, dedifferentiated liposarcoma is seen as well-defined non-lipomatous masses juxtaposed with fatty tumor. On the T1- weighted MR images, the signals are hypointense relative to the muscle signals, whereas on the T2-weighted MR images, the tumors show heterogeneous hyperintense signals relative to the muscle intensities.
Pathologic findings	Microscopically, areas of well-differentiated liposarcoma displayed features of both the lipoma-like and sclerosing subtypes. Generally, the lesions present as large (median, 19 cm; range, 2-80 cm), multinodular yellow to yellow-tan masses admixed with firm tan-gray areas that correspond to the dedifferentiated foci noted microscopically.
Popular locations	Retroperitoneum and lower extremities

Table 1. Summary table of retroperitoneal liposarcoma

MRI T1	The signals are hypointense relative to the muscle signals; however when using contrast media it shows heterogeneous enhancement.
MRI T2	The tumor shows heterogeneous hyperintense signals relative to the muscle intensities.
CT Scan	Contrast enhanced CT scan shows slightly inhomogeneous, hypoattenuated mass compared with liver, containing multiple thick irregular septa with delayed contrast enhancement.
Ultrasound	Mixed echogenicity of the tumor, the hyperechoic areal represents the fat component of the liposarcoma.
Bone Scan	Since the most frequent location of this tumor is retroperitoneum the typical bone scan-findings in case of huge tumor is abnormal location of the neighboring kidney.
Renal Scan	Owing to possible ventral displacement of the adjacent kidney the typical manifestation of this tumor is decreasing the contrast of the respecting kidney in dorsal evaluation; however this effect should be avoided using geometric mean.

Table 2. Imaging findings of retroperitoneal liposarcoma.

ABBREVIATIONS

RRF: relative renal function
 BS: bone scan
 MRI: magnetic resonance imaging.
 RS: renal scan.
 MAG3: 3-mercaptoacetyl triglycine
 MDP: methylene-diphosphonate
 p.i.: post injection
 ALT/WDL: atypical lipomatous tumor/well-differentiated liposarcoma
 DDL: dedifferentiated liposarcoma
 DMSA: 99mTc- Dimercaptosuccinic acid
 DTPA: diethylenetriamine pentaacetic acid
 SCLS: spindle cell liposarcoma

KEYWORDS

MAG3; geometric mean; retroperitoneal liposarcoma; renal scan

ACKNOWLEDGEMENTS

I would like to acknowledge the help of Dr. Hussam Al-sahli and Dr. Majdi Zein in completing this work.

Online access

This publication is online available at:
www.radiologycases.com/index.php/radiologycases/article/view/711

Peer discussion

Discuss this manuscript in our protected discussion forum at:
www.radiolopolis.com/forums/JRCR

Interactivity

This publication is available as an interactive article with scroll, window/level, magnify and more features.
 Available online at www.RadiologyCases.com

Published by EduRad



www.EduRad.org