

Acrokeratosis paraneoplastica (Bazex syndrome): Report of a case associated with small cell lung carcinoma and review of the literature

Jessica G. Zarzour^{1*}, Satinder Singh¹, Aleodor Andea², Jennifer A. Cafardi³

1. Department of Radiology. University of Alabama at Birmingham. Birmingham, AL, USA

2. Department of Pathology. University of Alabama at Birmingham. Birmingham, AL, USA

3. Department of Dermatology. University of Alabama at Birmingham. Birmingham, AL, USA

* Correspondence: Jessica Zarzour, MD, University of Alabama at Birmingham, Department of Radiology, 619 19th Street South, Birmingham, AL 35294, USA
(✉ jgzarzour@uabmc.edu)

Radiology Case. 2011 July; 5(7):1-6 :: DOI: 10.3941/jrcr.v5i7.663

ABSTRACT

Acrokeratosis paraneoplastic (Bazex syndrome) is a rare, but distinctive paraneoplastic dermatosis characterized by erythematous squamous lesions located at the acral sites and is most commonly associated with carcinomas of the upper aerodigestive tract. We report a 58-year-old female with a history of a pigmented rash on her extremities, thick keratotic plaques on her hands, and brittle nails. Chest imaging revealed a right upper lobe mass that was proven to be small cell lung carcinoma. While Bazex syndrome has been described in the dermatology literature, it is also important for the radiologist to be aware of this entity and its common presentations.

CASE REPORT

CASE REPORT

A 58 year-old African-American female presented to a dermatology clinic with complaints of a hyperpigmented rash on her arms, legs, hands, and feet for the previous 2 years. She had been treated at an outside hospital for a presumed diagnosis of cutaneous lupus erythematosus with oral corticosteroids, hydrocortisone cream, and 8 months of hydroxychloroquine without any significant benefit. Additionally, she reported a 15-pound weight loss over the past year.

The patient has a past medical history significant for hypertension, possible lupus and smoking. She was up to date on health maintenance issues. She had no contributing family history and no known drug allergies. Complete lab work up revealed a positive ANA (homogeneous 1:1640 titer), but was otherwise normal.

Physical exam hyperkeratotic plaques on her hands most prominent over the joints. Her nails appeared brittle and

atrophied (Figure 1). She had numerous hyperpigmented macules coalescing into patches in a reticulated pattern distributed over the dorsal arms and lower legs (Figure 2). There was a hyperpigmented, slightly scaly patch on her nose, and oral examination was normal.

Three punch biopsies from the forearm, thigh, and finger were somewhat nonspecific but showed mild epidermal psoriasiform hyperplasia and a superficial perivascular lymphohistiocytic infiltrate with eosinophils and neutrophils (Figure 3). Her direct immunofluorescence was positive for a linear IgG and C3 deposition along the basement membrane. The indirect immunofluorescence was negative.

A chest radiograph revealed an enlarged right hilum suggesting adenopathy (Figure 4). A subsequent contrast enhanced chest CT confirmed the presence a large perihilar soft tissue mass with narrowing of the right upper lobe bronchus and right paratracheal adenopathy with narrowing of the right upper lobe bronchus (Figures 5 and 6). No other discrete lung nodule was seen and only non-specific ground

glass opacities were present in the right upper lobe. A CT of the abdomen and pelvis revealed a hypodense focal lesion in the liver consistent with metastatic disease (Figure 6).

A diagnosis of acrokeratosis paraneoplastica was made based on the clinical presentation and evidence of metastatic carcinoma on imaging. The patient underwent bronchoscopy with biopsy of the right perihilar mass that revealed small cell carcinoma.

The patient underwent palliative chemotherapy, but unfortunately died 6 months after the diagnosis was made. Her cutaneous findings did not change during this period.

DISCUSSION

Multiple paraneoplastic syndromes exist and the majority will require radiological investigation for ultimate diagnosis of the underlying malignancy. Several paraneoplastic syndromes commonly associated with lung carcinoma include the syndrome of inappropriate antidiuretic hormone, limbic encephalitis, paraneoplastic cerebellar degeneration, and hypertrophic pulmonary osteoarthropathy. Central pontine myelinolysis can be a manifestation of the syndrome of inappropriate antidiuretic hormone secondary to small-cell lung carcinoma [1]. Limbic encephalitis can be paraneoplastic and is manifest by high T2 signal involving the limbic structures [1]. Paraneoplastic cerebellar degeneration is a diagnosis of exclusion but occurs most commonly in association with small-cell lung cancer [1]. Hypertrophic pulmonary osteoarthropathy (proliferative periostitis, arthropathy and digital clubbing) is most commonly associated with non-small-cell lung cancer [1].

Dermatologic signs and symptoms are also common paraneoplastic manifestations of underlying malignancy. Acanthosis nigricans is a well-known sign of insulin resistance, but it is also known to be associated with malignancy, most commonly gastrointestinal adenocarcinomas [2]. Necrolytic migratory erythema is most commonly associated with islet cell tumors [2]. Erythematous psoriasiform eruption involving the nose and helices, palmoplantar keratoderma and nail dystrophy is typical of Bazex syndrome, and the most common primary malignancy is squamous cell carcinoma of the upper aerodigestive tract [2].

Bazex syndrome is an eponym used to describe two different clinical entities first reported in 1964 and 1965. The first described Bazex syndrome is an x-linked genetic disease also known as 'follicular atrophoderma-basal cell carcinoma' and is characterized by follicular atrophoderma, congenital hypotrichosis and hypohidrosis, and multiple basal cell carcinomas [3]. The second described Bazex syndrome is also known as 'acrokeratosis paraneoplastica' and is characterized by erythematous psoriasiform eruption typically involving the nose and helices, palmoplantar keratoderma and nail dystrophy that is most commonly associated with carcinomas of the upper aerodigestive tract [2,3,4,5].

Gougerot and Rupp first described paraneoplastic acrokeratosis in 1922 in a patient with squamous cell carcinoma of the tongue and with hyperkeratotic lesions of the nose, ears and palmo-plantar regions [4]. The eponymous of Bazex syndrome is ascribed to Andre Bazex who reported a case in 1965 of a squamous cell carcinoma of the piriform fossa associated with a psoriasis-like examthem [7].

Bazex syndrome is characterized by a hyperkeratotic, psoriasiform eruption that favors acral sites and parallels the evolution of a co-existing malignancy [2]. The cutaneous lesions precede the diagnosis of the tumor by an average of 11 months [2]. A review of the literature in 2005 found that 60% the associated neoplasms were squamous cell carcinoma of the head, neck and lungs [6]. Less commonly associated carcinomas are poorly differentiated carcinoma (16%), adenocarcinoma of the prostate, lung, esophagus stomach, and colon (8%), and small cell carcinoma of the lung (2.5%) [7]. Even rarer associated carcinomas include transitional cell carcinoma of the bladder, Hodgkin's disease, T-cell lymphoma, carcinoid, thymoma, vulvar, liposarcoma, cholangiocarcinoma, uterine adenocarcinoma, and breast cancer [7,8,9,10]. Most described cases are white males older than 40 [2].

The cutaneous lesions are erythematous to violaceous in color with an associated scaling eruption and the most frequent sites of involvement are the ears, nose, hands, and feet (including the nails) [2]. They are typically non-pruritic, have ill-defined margins and are symmetric [8, 11].

On the basis of clinical observation, acrokeratosis paraneoplastica has been divided into 3 stages, which reflect the growth and dissemination of the underlying malignancy [8,11]. The psoriasiform dermatitis begins in the fingers, toes, nose, and helix of the ears which progresses to involve the palms, soles, and cheeks to finally extends centripetally to the arms, legs, scalp, and trunk [5,6].

Typically, the histologic examination of the biopsy specimen and direct immunofluorescence is nonspecific, but is useful in ruling out other major dermatoses [9]. Interestingly, the direct immunofluorescence findings in this case paralleled that of a bullous eruption, such as bullous pemphigoid or even paraneoplastic pemphigus which may be characterized by linear deposition of IgG and C3 along the basement membrane however, but no bullae were seen clinically.

Several mechanisms for development of this paraneoplastic syndrome have been proposed. One theory proposes that antibodies against the tumor cross react with the keratinocyte or basement membrane leading to damage of the basal layer of the skin [2]. Alternatively, an immune reaction directed against tumor like antigens in the epidermis could be responsible for the cutaneous eruptions [11]. Yet another proposed mechanism is tumor production of autocrine growth factors for keratinocytes, transforming growth factor- β , and insulin like growth factor-1 leading to epidermal hyperplasia [2,11].

The cutaneous eruptions are typically resistant to topical treatments [2]. Treatment of the underlying neoplasm often improves the cutaneous symptoms significantly and reappearance of the lesions may signal recurrence of the tumor or development of metastatic disease [2,11].

TEACHING POINT

Acrokeratosis paraneoplastica (Bazex syndrome) is a rare, but distinctive paraneoplastic dermatosis characterized by erythematous lesions located at the acral sites and is most commonly associated with carcinomas of the upper aerodigestive tract. When given particular clinical histories, the appropriate radiographic investigations should be initiated and the radiologist's suspicion for an underlying malignancy should heighten leading to prompt diagnosis and ultimately a better prognosis.

REFERENCES

1. Rutherford GC, Dineen RA, O'Connor A. Imaging in the investigation of paraneoplastic syndromes. *Clin Radiol.* 2007 Nov;62(11):1021-35. PMID: 17920860
2. Bologna J, Brewer Y, Cooper D. Bazex syndrome (acrokeratosis paraneoplastica). An analytic review. *Medicine (Baltimore)* 1991; 70: 269-80. PMID: 2067411
3. Bazex, A.; Dupre, A.; Christol, B. Genodermatose complexe de type indetermine associant une hypotrichose, un etat atrophodermique generalise et des degenerescences cutanees multiples (epitheliomas-basocellulaires). *Bull. Soc. Franc. Derm. Syph.* 71: 206 only, 1964.
4. Gougerot H, Rupp C: Erythematous-squamous dermatosis with hyperkeratotic palmo-plantar finger porectasies and latent tongue cancer [in French]. *Paris Med* 43:234-237, 1922.
5. Hsu Y, Lien G, Lai H, et al. Acrokeratosis paraneoplastica (Bazex syndrome) with adenocarcinoma of the colon: report of a case and review of the literature. *J Gastroenterol.* 2000;35(6):460-4. PMID: 10864355
6. Strobel E, Bouveret C, Kohl P. Acrokeratosis paraneoplastica of Bazex as an indicator for underlying squamous cell carcinoma of the lung. *J Cancer Res Clin Oncol* (2006) 132: 376-378. PMID: 16435144
7. Bazex A, Salvador R, Dupre A, et al. Hyperkeratosis of the extremities-like paraneoplastic syndrome: Healing after treatment of a larynx epithelioma. *Bull Soc Fr Dermatol Syphiligr* 72:182, 1965.

8. Karabulut A, Sahin S, Sahin M, Ek?io?lu M, Ustün H. Paraneoplastic acrokeratosis of Bazex (Bazex's syndrome): report of a female case associated with cholangiocarcinoma and review of the published work. *J Dermatol.* 2006 Dec;33(12):850-4. PMID: 17169088
9. Sator P, Breier F, Gschnait F. Acrokeratosis paraneoplastica (Bazex's syndrome): association with liposarcoma. *J Am Acad Dermatol.* 2006 Dec;55(6):1103-5. PMID: 17097409
10. Akhyani M, Mansoori P, Taheri A, Asadi Kani Z. Acrokeratosis paraneoplastica (Bazex syndrome) associated with breast cancer. *Clin Exp Dermatol* 2004;29:429-30. PMID: 15245551
11. Stone S, Buescher L. Life-threatening paraneoplastic cutaneous syndromes. *Clin Dermatol.* 2005 May-Jun;23(3):301-6. PMID: 15896545

FIGURES

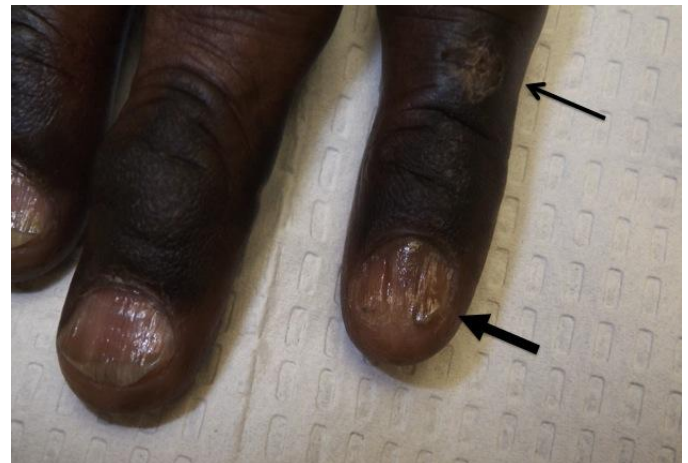

Figure 1: 58 year old female with Bazex syndrome who presented with hyperkeratotic plaques on her hands (arrow) and brittle nails (thick arrow). Picture of hand demonstrates hyperkeratotic plaques most prominent over joints. The nails are brittle and atrophied.

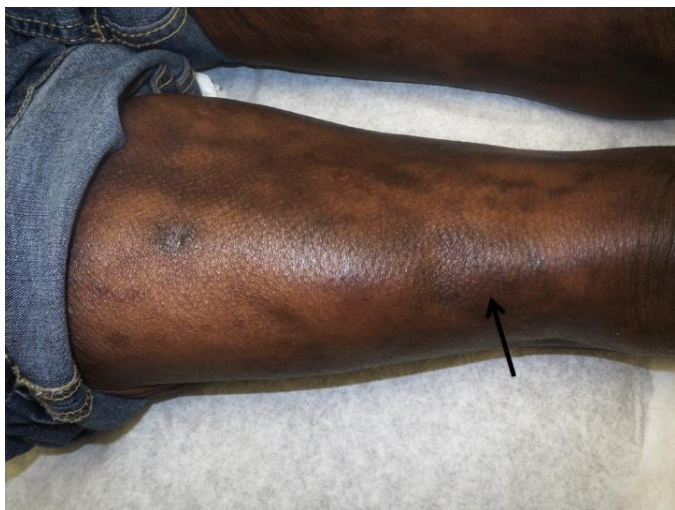

Figure 2: 58 year old female with a 2 year history of a hyperpigmented rash over her forearms and legs. Photograph of the leg shows numerous hyperpigmented macules coalescing into patches in a reticulated pattern (arrow). Diagnosis of Bazex syndrome was eventually made after radiologic work up.

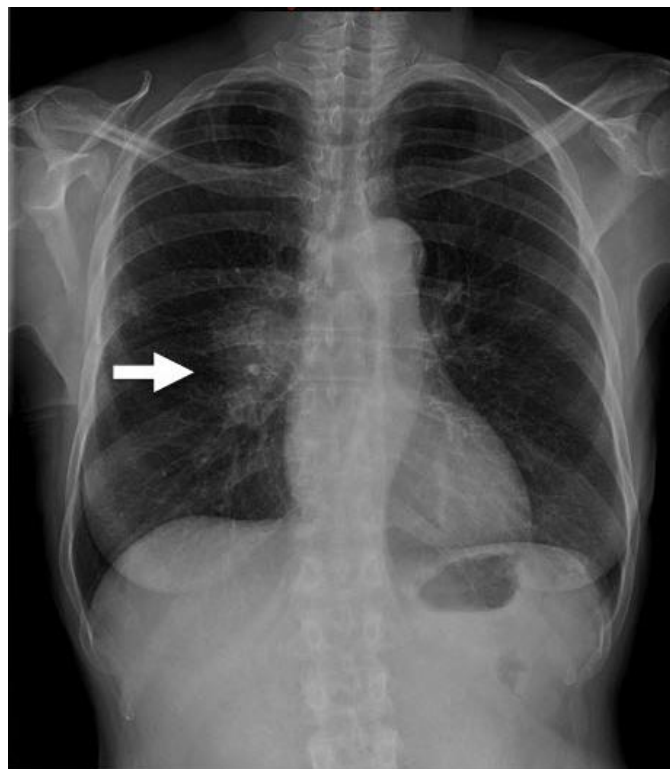

Figure 4: 58 year old woman with Bazex syndrome presented with 2 year history of a hyperpigmented rash and a chest radiograph was obtained. Posteroanterior chest radiograph demonstrates enlarged right hilum due to adenopathy (arrow).

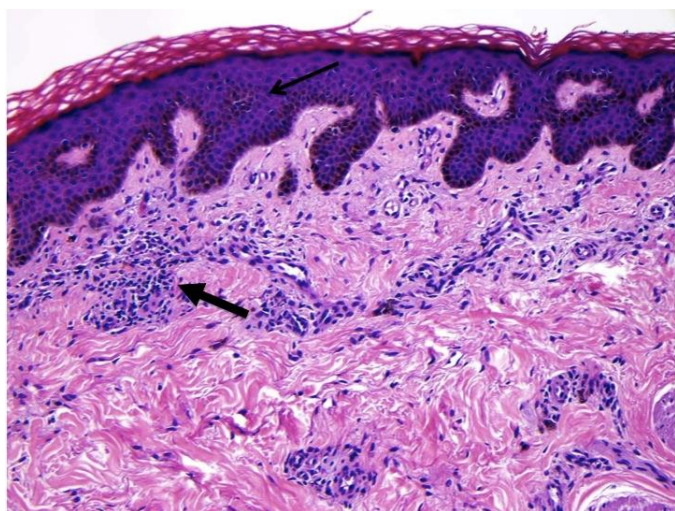


Figure 3: 58 year old female with Bazex syndrome had a 2 year history of a hyperpigmented rash and underwent punch biopsy of thigh. Biopsy from the right thigh showing mild epidermal acanthosis (arrow) and a superficial perivascular lymphohistiocytic infiltrate (thick arrow). (Hematoxylin and eosin, original magnification 200x)

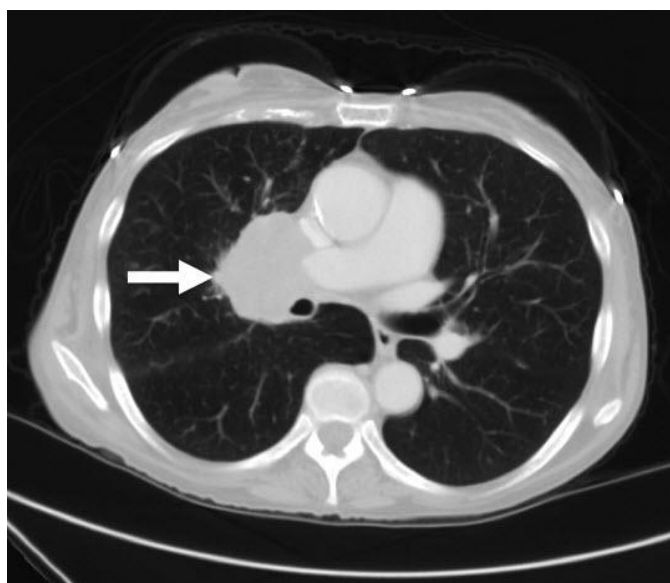


Figure 5: 58 year old female with Bazex syndrome had a 2 year history of a hyperpigmented rash and presented for CT after an abnormal chest radiograph. Contrast enhanced axial CT images of the chest confirms the presence of large right perihilar soft tissue mass. (protocol: 250 mAs, 120 kvp, 5mm slice thickness, venous phase, 100 cc isoview-300.)

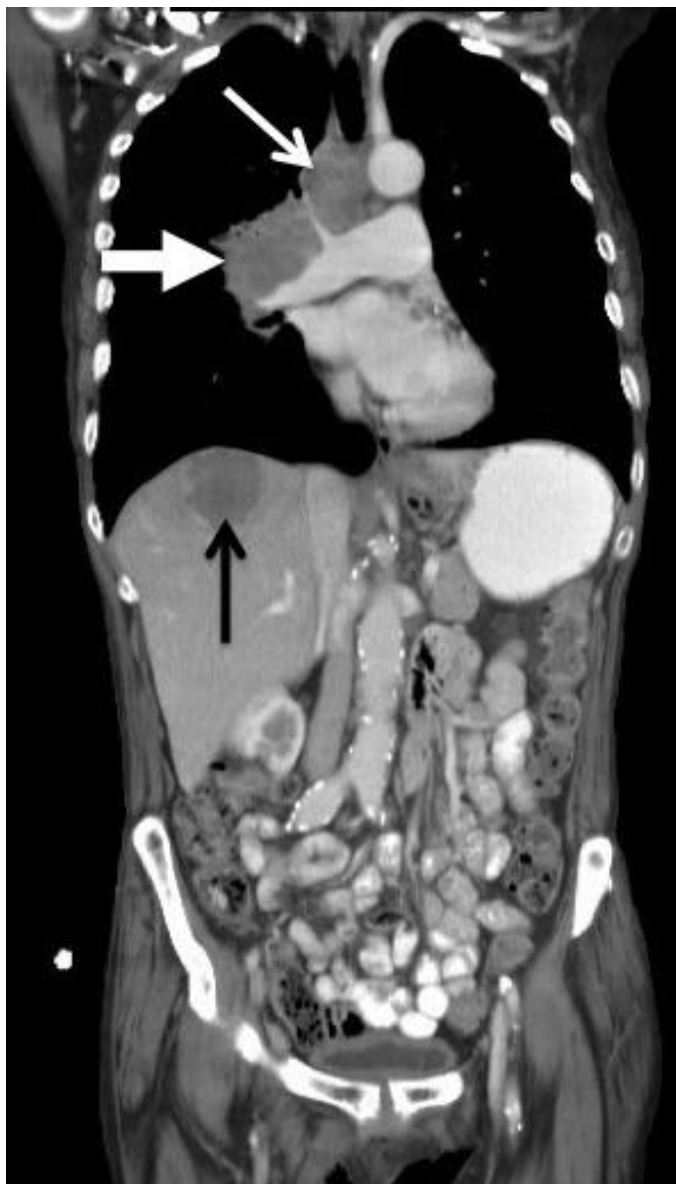

Figure 6 (left): 58 year old female with a 2 year history of a hyperpigmented rash who was found to have Bazex syndrome presented for CT after an abnormal chest radiograph. Contrast enhanced coronal reformatted CT images of the chest demonstrates the presence of large right perihilar soft tissue mass (thick white arrow), associated right paratracheal adenopathy (thin white arrow) and a focal right hepatic lobe metastatic lesion (black arrow). (protocol: 250 mAs, 120 kvp, 5mm slice thickness, venous phase, 100 cc isoview-300)

Etiology	Paraneoplastic syndrome
Incidence	120 reported cases
Gender ratio	More common in males
Age predilection	Most common over age 40
Treatment	Treatment of underlying neoplasm often improves cutaneous symptoms
Prognosis	Depends on extent of cancer
Imaging findings	Neoplastic process most commonly involving the upper aerodigestive tract

Table 1. Summary table for Bazex syndrome (acrokeratosis paraneoplastica)

Paraneoplastic Syndrome	Clinical presentation	Radiological findings	Underlying Malignancy
Syndrome of inappropriate antidiuretic hormone secretion	Hyponatremia	Central pontine myelinolysis on MRI	Small cell lung cancer (most common), head and neck tumors, gastrointestinal tumors, and gynecological malignancy
Limbic encephalitis	Short term memory loss, seizure, irritability, thalamic dysfunction, and psychiatric imbalances.	On MRI, high T2 signal in the limbic structures	Small cell lung cancer (most common), testicular carcinoma, breast carcinoma, Hodgkin's lymphoma, teratoma and thymoma
Paraneoplastic cerebellar degeneration	Ataxia and nystagmus	In acute phase, high T2 signal in the cerebellum on MRI In chronic phase, cerebellar atrophy on MRI and CT	Lung carcinoma (most common), gynecological malignancies, Hodgkin's lymphoma, and breast carcinoma
Hypertrophic pulmonary osteoarthropathy	Pain and swelling in the ankles and wrists	On radiographs, digital clubbing and lamellar periosteal reaction in the diaphyseal regions Bone scintigraphy shows increased uptake along the cortical margin of long bones	Non small cell lung cancer or metastatic disease to the lungs
Acanthosis nigricans	Hyperpigmentation in intertriginous regions	On CT, a mass arising from the gastrointestinal tract; most commonly, the stomach	Adenocarcinoma arising from the gastrointestinal tract (stomach, most common), lungs or uterus
Necrolytic migratory erythema	Hyperglucagonemia and weight loss	On CT, an arterial hyperenhancing pancreatic mass	Glucagonoma
Bazex syndrome	Hyperkeratotic, psoriasiform eruption located at the acral sites	On CT, a mass arising from the upper aerodigestive tract	Squamous cell carcinoma of the head, neck or lungs

Table 2: Summary of paraneoplastic processes and their radiographic manifestations.

Journal of Radiology Case Reports

www.RadiologyCases.com

ABBREVIATIONS

CT: computed tomography
IgG: immunoglobulin G

KEYWORDS

Acrokeratosis paraneoplastica; Bazex syndrome; paraneoplastic

Online access

This publication is online available at:
www.radiologycases.com/index.php/radiologycases/article/view/663

Peer discussion

Discuss this manuscript in our protected discussion forum at:
www.radiopolis.com/forums/JRCR

Interactivity

This publication is available as an interactive article with scroll, window/level, magnify and more features.
Available online at www.RadiologyCases.com

Published by EduRad



www.EduRad.org