

Emperor's Newest Clothes

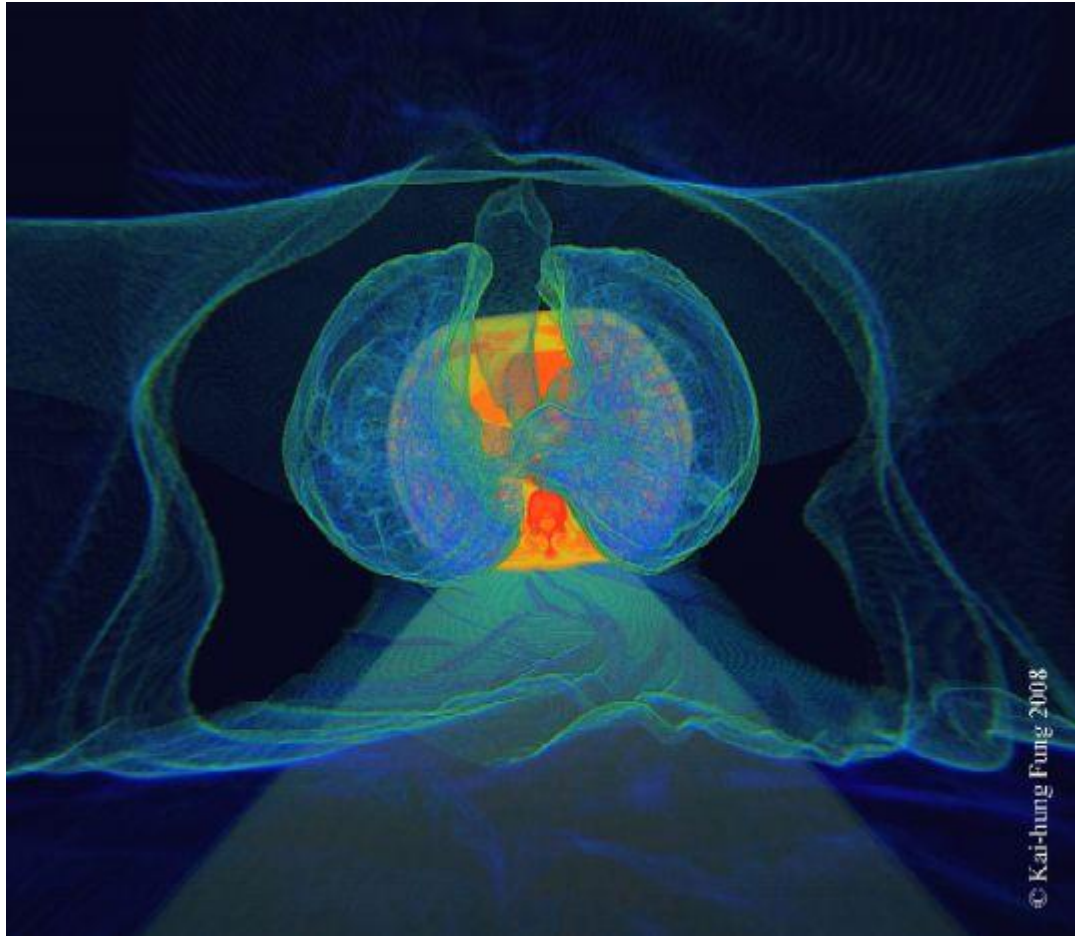
Kai-hung Fung, MBBS, FRCR

Radiology Department, Pamela Youde Nethersole Eastern Hospital, 3 Lok Man Road, Chai Wan, Hong Kong, China

✉ khfung@ha.org.hk :: Telephone: +852 64600393

Radiology Case. 2008 Sep; 2(3):3 :: DOI: 10.3941/jrcr.v2i3.65

INTERESTING IMAGE



EMPEROR'S NEWEST CLOTHES © Kai-hung Fung, 2008

3D-CT after full color spectrum rendering. Digital medium. The skin surface hangs like a soft satin over the transparent body with the trachea and lungs in the centre. Look, can you find some emphysematous bullae in the lungs? Cross section of the thorax at the level of the heart forms the background.

URL of this article:

www.radiologycases.com/index.php/radiologycases/article/view/65

Published by EduRad



www.EduRad.org