

Radiology from a "different" view

Roland Talanow, MD, PhD

The Cleveland Clinic, Department of Radiology, 9500 Euclid Ave., 44195 Cleveland Ohio (✉ roland@talanow.net)

Radiology Case. 2008 Sep; 2(3):1-2 :: DOI: 10.3941/jrcr.v2i3.62

ABSTRACT

This editorial is dedicated to a radiologist who makes diagnostic imaging more appealing to the viewer's eye with special post-processing techniques.

EDITORIAL

The Journal of Radiology Case Reports could not resist to write this editorial about a very special radiologist who whose passion is to make diagnostic imaging more appealing to the viewer's eye.

Dr. Kai-hung Fung is a diagnostic radiologist with his special medical interests including interventional radiology, neurointervention and 3D medical visualization. Dr. Fung is a self-taught new media artist who employs 3D medical imaging as a medium for creative artworks. He started his art career in 2003. He also enjoys photography.

Dr. Fung presented his artwork in multiple national and international exhibitions and museums. He also received multiple awards, including but not limited to the "Best Science Images of 2007" and "Top Ten News Photo Galleries of 2007" by National Geographic, USA. He was also awarded gold, silver and bronze in the "Surgical VR Lab" project in the "Hong Kong Information & Communication Technology (ICT) awards 2007", receive the first prize (tie) in the Science & Engineering Visualization Challenge 2007 organized by Science magazine and National Science Foundation, USA and was finalist in the L'OREAL Art & Science of Color Prize, L'OREAL Art Foundation, Japan in 2005 and 2006.

Dr. Fung started doing this kind of art in 2003, when his institution had the availability of multi-detector CT capable of isotropic high resolution imaging. Through involvement in 3D medical visualization in his "Surgical VR Lab" program, Dr. Fung's interest in performing this kind of art was born while he tried to make 3D images more appealing by using different rendering techniques. He discovered new ways of color image rendering such as the 'rainbow technique' that could enhance the aesthetic value of 3D CT images. Dr. Fung stated that the results of these newly discovered rendering techniques were so good that he could employ them for creative artworks. He added full color spectrum rendering to enhance the aesthetic qualities.

Although CT and MRI can be used to generate 3D images, he still prefers CT because the resolution and dynamic range of images created by his institution's

multi-detector CT is better than their 1.5T MRI. The used 3D software is Vitrea 2.0 (Vital Images Inc.). In order to preserve the pristine nature of the images generated directly from the data set, he normally does not manipulate further on the images, with the exception occasionally making adjustment on contrast, sharpness and brightness.

Since Dr. Fung is using digital media, he can output in various formats including digital prints or transparency or digital projections. Another technique is creating stereoscopic pairs of images by shifting horizontally. Other rendering techniques such as transparency or combination of transparency with rainbow technique are found in his later artworks.

Dr. Fung's present and future interests include 3D medical visualization, virtual reality, stereoscopic rendering and display, augmented reality, 3D tracking and image-guided surgery/intervention, data generated rapid prototyping for 3D modeling and sculpture, application of advance medial imaging in the arts, virtual museum.

To contact Dr. Kai-hung Fung:

Mail address:
Radiology Department
Pamela Youde Nethersole Eastern Hospital
3 Lok Man Road
Chai Wan, Hong Kong
E-mail: khfung@ha.org.hk

References

1. Fung KH. The rainbow technique: an innovative approach to the artistic presentation of 3D computed tomography. LEONARDO 2006; 39(2):101-103.
2. Fung KH. Artwork using 3D computed tomography: extending radiology into the realm of visual art. LEONARDO 2006; 39(3):187-191.
3. 3D Visualization in the Arts Network (U.K.) <http://3dvisa.cch.kcl.ac.uk/project37.html>.
4. Fung KH. Using three dimensional CT to create fine art. Radiographics. 2008 Jul-Aug;28(4):947-8.

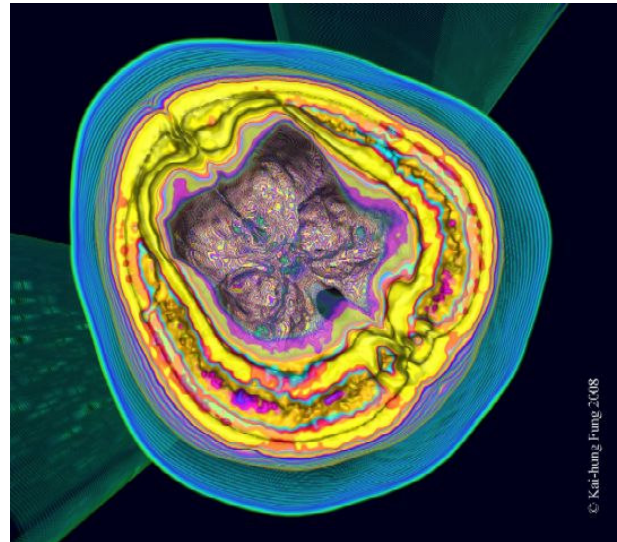


Figure 2: ANATOMY IN A NUTSHELL © Kai-hung Fung, 2008

3D-CT. Digital medium. Looking down through the cut section of the vertex, the skull base and layers of the skull can be clearly seen.

Figures

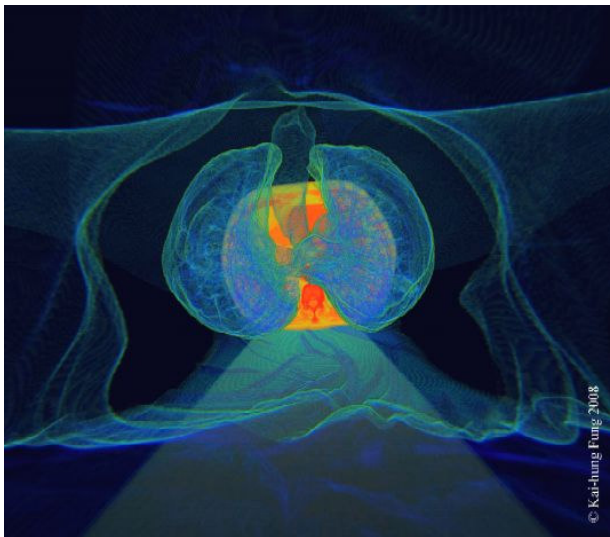


Figure 1: EMPEROR'S NEWEST CLOTHES © Kai-hung Fung, 2008

3D-CT. Digital medium. The skin surface hangs like a soft satin over the transparent body with the trachea and lungs in the centre. Look, can you find some emphysematous bullae in the lungs? Cross section of the thorax at the level of the heart forms the background.

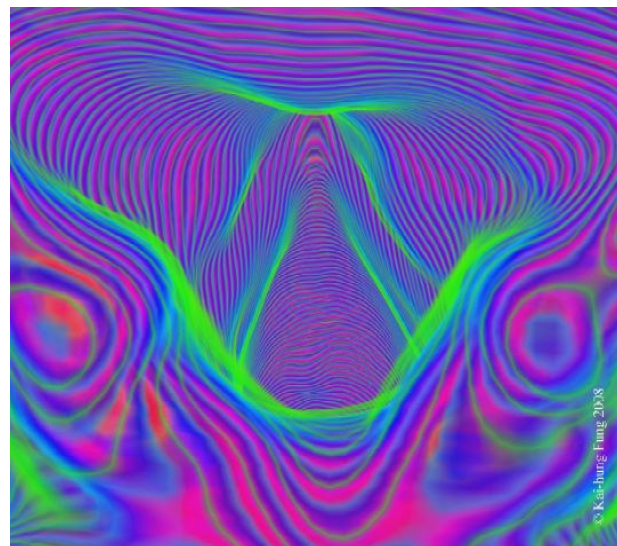


Figure 3: SINGING FOLDS © Kai-hung Fung, 2008

3D-CT. Digital medium. A virtual endoscopy view from behind the cricoid shows the true and false vocal cords (centre). The corniculate tubercles are seen on either side.

URL of this article:

www.radiologycases.com/index.php/radiologycases/article/view/62

Published by EduRad



www.EduRad.org

www.RadiologyCases.com

Journal of Radiology Case Reports