

Successful Treatment of Varicose Great Saphenous Vein Complicated with Acute Thrombosis by Balloon-Assisted Thrombectomy Combined with Radiofrequency Ablation: A Case Report

YangBin Kou¹, MengJuan Feng^{2*}, Xuan Yao¹, Ji Zhang¹, Xiaoling Xie¹, Juan Wan¹

¹Department of Interventional Radiology, Chengdu Xindu District Hospital of Traditional Chinese Medicine, Sichuan, PR China

²Department of Ultrasound, Chengdu First People's Hospital, Sichuan, PR China

*Correspondence: MengJuan Feng, Department of Ultrasound, Chengdu First People's Hospital, Sichuan, Gaoxin District, Chengdu, Sichuan, 610041, People's Republic of China

 419592007@qq.com

Radiology Case. 2026 May; 20(5):1-11 :: DOI: 10.3941/jrcr.6063

AUTHORS' CONTRIBUTIONS

YangBin Kou: Followed up the patient, wrote the manuscript.

MengJuan Feng: Wrote the manuscript, reviewed the manuscript.

Xuan Yao: Processed the patient, followed up the patient.

Ji Zhang: Processed the patient, followed up patient.

Xiaoling Xie: Processed the patient, followed up the patient.

Juan Wan: Processed the patient, followed up the patient.

ACKNOWLEDGEMENTS

None

DISCLOSURES

None

CONSENT

None

HUMAN AND ANIMAL RIGHTS

Ethical approvals were signed by Medical Ethics Committee of Chengdu Xindu District Traditional Chinese Medicine Hospital of Chengdu, with the approval document number 2024NO.05.

ABSTRACT

Introduction: Great Saphenous Vein (GSV) varicosity is a common clinical vascular disease, frequently complicated by Superficial Venous Thrombosis (SVT). SVT may extend to the deep venous system, causing severe Venous Thromboembolism (VTE). The standard treatment for GSV varicosity with acute SVT—especially involving the Saphenofemoral Junction (SFJ)—remains controversial. Anticoagulation is the mainstream to reduce thromboembolic risk, while surgical treatment has drawbacks like significant trauma and excessive bleeding, failing to lower long-term thromboembolic incidence. This leaves gaps in optimal timing and combined regimens, with scarce evidence for alternative therapies without standard equipment. This case report describes a successful combined interventional therapy for a patient with 30-year untreated GSV varicosity and SVT, providing practical evidence.

Case Study: A 74-year-old male presented with right lower limb swelling and pain for 10 days, along with 30-year untreated varicosity. Physical examination showed tortuous and dilated GSV (earthworm-like protrusions), hard nodules, erythema, edema, and ankle pigmentation (CEAP class 4; Venous Clinical Severity Score [VCSS] = 12; Aberdeen Varicose Vein Questionnaire [AVVQ] = 22). Color Doppler ultrasound confirmed extensive GSV thrombosis (extending to SFJ) without deep venous thrombosis. After full risk disclosure of VTE, the patient opted for surgery (declined vena cava filter placement). Lacking a Fogarty catheter, the operator used a deep venous balloon catheter to occlude the SFJ, performed above-knee GSV thrombectomy with a superficial venous balloon, followed by endovenous radiofrequency ablation. Below-knee tributaries were treated with ultrasound-guided foam sclerotherapy combined with minimally invasive phlebectomy. Postoperative anticoagulation relieved symptoms; 10-month follow-up showed no thrombosis recurrence, vessel recanalization, or adverse events.

Conclusion: This case demonstrates the efficacy of combined therapy (deep venous balloon occlusion, alternative catheter-based thrombectomy, radiofrequency ablation, foam sclerotherapy/minimally invasive phlebectomy) for long-standing GSV varicosity with SVT. It confirms that deep venous balloon catheters can replace Fogarty catheters in resource-limited settings. The 10-month follow-up verifies long-term safety, offering a practical treatment paradigm for similar high-risk cases and supplementing evidence for individualized GSV varicosity therapy.

CASE REPORT

CASE REPORT

A 74-year-old male patient presented with the chief complaint of "swelling and pain in the right lower extremity for 10 days". The patient first developed earthworm-like protrusions of the right lower extremity veins over 30 years ago, which gradually worsened over time. There were no accompanying motor or sensory dysfunctions in the lower extremities, so the patient did not pay much attention to the condition. Ten days prior to admission, he developed swelling and pain in the right lower extremity without an obvious cause. The symptoms progressively worsened, affecting his nighttime sleep, and he experienced a heavy, weak sensation in the right lower extremity when walking. The patient denied a history of hypertension, coronary atherosclerotic heart disease, or diabetes. Physical examination revealed earthworm-like protrusions of the right great saphenous vein, with multiple palpable hard nodules accompanied by skin redness and swelling. A subcutaneous mass was palpable on the medial side of the right knee joint, and skin pigmentation was observed in the right foot boot area. The patient was classified as CEAP grade 4, with a VCSS score of 12 and an AVVQ score of 22.

Vascular ultrasound showed extensive dilation of the right great saphenous vein with thrombosis, which was particularly prominent in the mass (thrombus) around the right knee joint (Figure 1). The thrombus extended to the orifice of the femoral-saphenous vein, while no obvious thrombosis was found in the deep veins of the right lower extremity.

The patient underwent surgical treatment, with the following surgical steps:

□ Percutaneous puncture of the left femoral vein was performed, and the guidewire was advanced "crossing over" to the right femoral vein. A 10×120mm-diameter balloon was pre-placed in the right femoral vein and not inflated temporarily (Figure 2);

□ The main trunk of the great saphenous vein was transected at the knee joint level. A 0.035-inch super-slippery guidewire and an 8x60mm-diameter balloon were introduced through the proximal stump opening to the orifice of the femoral-saphenous vein. The 10×120mm balloon in the right femoral vein was inflated to block the orifice of the femoral-saphenous vein (Figure 3). Meanwhile, the 8x60mm balloon was inflated to adhere to the wall of the great saphenous vein. The 8x60mm balloon was then retracted, and the thrombus was extracted by utilizing the frictional force between the balloon and the

vascular wall. This procedure was repeated several times until angiography showed that the thrombus was basically cleared and the blood flow in the main trunk of the great saphenous vein was restored (Figure 4);

□ A 7F vascular sheath and a radiofrequency ablation catheter were introduced. Under real-time ultrasound monitoring, the radiofrequency generator was activated to close the main trunk of the supra-patellar great saphenous vein at a position approximately 2cm away from the junction of the femoral-saphenous vein. For the varicose veins and thrombi below the knee, point stripping combined with foam sclerosing agent injection was performed.

Monitoring and Evaluation

Anticoagulant therapy was administered postoperatively, and the patient's symptoms of swelling and pain in the right lower extremity gradually alleviated. At the 2-month postoperative follow-up, a lower extremity venous ultrasound reexamination showed that the lumen of the great saphenous vein was basically occluded, and no obvious blood flow signal was observed in the lumen (Figure 5). During the 10-month postoperative follow-up, there was no recurrence of thrombosis or recanalization of varicose veins, and no adverse reactions occurred. The VCSS score decreased to 3, and the AVVQ score decreased to 22.

DISCUSSION

Etiology & demographics

Varicose veins represent dilated lesions of the superficial venous system resulting from functional insufficiency. Their pathophysiological process involves not only local hemodynamic disturbances but also systemic abnormalities in blood components. Studies indicate that compared to healthy individuals, patients with varicose veins exhibit significantly elevated levels of systemic inflammatory markers (e.g., C-reactive protein) and prothrombotic markers (e.g., D-dimer, fibrinogen) [1,2]. Lattimer et al. [3] further found that local concentrations of proinflammatory cytokines (e.g., IL-6, IL-8, MCP-1) in lower limb varicose veins were higher than in upper limb veins, suggesting that local inflammatory responses play a crucial role in disease progression.

Hemodynamic alterations represent one of the core mechanisms. Venous valve insufficiency causes reflux and stasis, leading to hypoxia in the valvular sinus region. This hypoxic state activates the *elk-1/egr-1* signaling pathway within endothelial cells, promoting leukocyte and platelet adhesion and aggregation at the valvular sites. This initiates an inflammatory

response and increases the risk of local thrombosis [4]. Venous stasis, endothelial injury, and hypercoagulability collectively form Virchow's triad, making acute superficial vein thrombosis a common complication of varicose veins. Anatomically, approximately 60%–80% of superficial vein thromboses occur in the great saphenous vein, with 10%–20% involving the small saphenous vein [1].

Thrombosis of the great saphenous vein often causes pain, swelling in the affected limb, and palpable cord-like indurations along the course of the varicose veins [5]. Its clinical significance lies in the risk of progression to deep vein thrombosis (DVT) and pulmonary embolism (PE). A prospective observational study (the POST Study) reported that approximately 10.2% of patients with superficial venous thrombosis experience thromboembolic events within 3 months [6]. Without standardized treatment, the incidence of superficial venous thrombosis progressing to DVT ranges from 6% to 40%, the incidence of progression to symptomatic PE ranges from 2% to 13%, and the incidence of asymptomatic PE is even higher [1,7].

Clinical & imaging findings

The typical clinical manifestations of acute thrombosis of the great saphenous vein includes sudden pain, erythema, and palpable, firm, cord-like masses along its course [8]. While clinical examination combined with D-dimer testing aids in initial screening, imaging studies are crucial. Doppler ultrasound (DUS) has become the preferred imaging modality due to its non-invasive nature, convenience, cost-effectiveness, and high diagnostic accuracy [9]. It can accurately assess the scope and location of the thrombus (especially the distance from the saphenofemoral junction), the length of the thrombus, and simultaneously evaluate the deep venous system. A systematic review showed that the sensitivity and specificity of DUS for diagnosing superficial venous thrombosis reached 84% and 94%, respectively [10]. In contrast, lower extremity ascending venography has limited accuracy and is an invasive examination, so it is not recommended as a first-line diagnostic tool [9]. Therefore, for patients with clinically suspected great saphenous vein thrombosis, especially those with thrombus near the saphenofemoral junction or infrapatellar communicating veins, DUS should be performed as early as possible to confirm the diagnosis.

Treatment & prognosis

The treatment strategy for great saphenous varicose veins complicated with superficial venous thrombosis requires individualization, mainly based on the extent of the thrombus, location (whether the saphenofemoral junction is involved), and the severity of phlebitis symptoms. Multiple guidelines emphasize the core role of anticoagulant therapy in managing superficial venous thrombosis and reducing the risk of thromboembolism [11,12]. For patients with localized thrombi (far from the saphenofemoral junction) and mild symptoms, conservative treatments may be considered, such

as compression with elastic stockings, elevation of the affected limb, and nonsteroidal anti-inflammatory drugs (NSAIDs). However, for patients with extensive thrombi, severe symptoms, or thrombi involving the saphenofemoral junction (regarded as high risk for VTE), more aggressive interventions are required, including therapeutic-dose anticoagulants or surgical intervention [6].

The traditional treatment process typically involves anticoagulant and anti-inflammatory therapy first, followed by elective varicose vein surgery after the acute phase. However, this regimen has a long course; some patients experience slow symptom relief or frequent recurrence, which affects quality of life and prognosis. Surgical treatment can effectively remove thrombi and reduce the spread and recurrence of superficial venous thrombosis [13]. The conventional surgical approach is high ligation and segmental stripping of the great saphenous vein. Modified surgical techniques attempt to ligate the proximal and distal ends first, then remove the thrombus with an aspirator before stripping. Nevertheless, these modified methods still have drawbacks such as large trauma and excessive bleeding. Additionally, studies have shown that compared with anticoagulant therapy alone, they fail to further reduce the long-term incidence of thromboembolism [14]. To reduce the risk of intraoperative PE, some case reports have described prophylactic placement of an inferior vena cava (IVC) filter before surgery. However, this measure increases medical costs and the risk of potential complications [15].

The "dual-balloon technique combined with radiofrequency ablation" adopted in this case is an innovative attempt. This method uses a 10-mm balloon to temporarily occlude the saphenofemoral junction, replacing the function of an IVC filter. In the absence of a Fogarty embolectomy catheter, another 8-mm balloon is used for thrombus removal in the great saphenous vein. After successful thrombus clearance, a radiofrequency catheter is immediately used to ablate and occlude the main trunk of the great saphenous vein. This combined regimen integrates the advantages of immediate thrombus removal, venous occlusion, and intraoperative embolism prevention, aiming to achieve one-time radical treatment while reducing the risk of thromboembolism and medical costs. The patient in this case had a good postoperative recovery; short-term follow-up ultrasound confirmed no thrombus recurrence or venous recanalization, and no adverse events occurred.

Differential Diagnoses

In clinical practice, acute thrombosis of the great saphenous vein trunk needs to be differentiated from the following diseases:

1. DVT

This is the most important differential diagnosis. Although both are venous thrombotic diseases, their treatment regimens and prognoses differ significantly. DVT typically presents as diffuse swelling of the entire lower limb, with deeply localized pain, and a positive Homans sign may be present [16]. D-dimer

may be elevated in both conditions, so its value for differentiation is limited [17]. Doppler ultrasound is the gold standard for distinguishing between involvement of the superficial and deep venous systems [9].

2. Lower Limb Cellulitis

This is a bacterial infectious skin disease, which can also present with erythema, pain, and swelling. However, it is characterized by the frequent presence of a clear entry point for infection (e.g., skin breaks, tinea pedis). Systemic symptoms such as fever are more common, and laboratory tests may show a significant increase in white blood cell count and C-reactive protein (CRP). Ultrasound examination shows no evidence of intravascular thrombosis but may reveal subcutaneous tissue edema [18]. Effective response to antibiotic treatment can serve as a retrospective differentiating point.

TEACHING POINT

The presence of acute thrombosis in the main saphenous vein trunk (involving the saphenofemoral junction) carries a high risk of VTE, with DUS being the preferred diagnostic modality. The dual-balloon technique described in this case—utilizing separate balloons to occlude the saphenofemoral junction and perform thrombectomy in the great saphenous vein—combined with immediate radiofrequency ablation, offers a novel minimally invasive therapeutic approach integrating thrombus removal, main trunk closure, and intraoperative embolization protection.

QUESTIONS

Question 1: Which of the following is NOT a common cause of acute thrombosis in patients with great saphenous vein varicosities?

- Elevated levels of inflammatory markers in patients with lower extremity varicose veins
- Abnormal venous valves causing turbulent blood flow, leading to hypoxia within the valvular sac
- Rapid arterial blood flow causing vascular endothelial injury
- Aggregation of leukocytes and platelets at the injury site triggering coagulation
- Venous stasis

Answer C: According to the content in the "Etiology & Demographics" section of the case report, excessively fast arterial blood flow has no definite correlation with venous thrombosis.

Question 2: Which of the following examination methods is the first choice for diagnosing great saphenous varicose veins complicated with acute thrombosis, and is characterized by low cost, non-invasiveness, and high diagnostic efficacy?

- Lower extremity ascending venography
- Computed tomography venography (CTV)
- Magnetic resonance venography (MRV)
- Duplex ultrasound (DUS)
- Angiography

Answer D: It has been clearly mentioned in the "Clinical & Imaging Findings" section. [Doppler ultrasound (DUS) has become the preferred imaging modality due to its non-invasive

nature, convenience, cost-effectiveness, and high diagnostic accuracy]

Question 3: For patients with great saphenous varicose veins complicated by thrombosis, where the thrombus involves the saphenofemoral junction, which of the following treatment methods is more appropriate?

- Conservative treatment with elastic stockings only
- Use of nonsteroidal anti-inflammatory drugs (NSAIDs) only
- Aggressive anticoagulant therapy or surgical intervention
- Anti-inflammatory therapy only
- Watchful waiting without treatment for the time being

Answer C: It has been clearly mentioned in the "Treatment & prognosis" section. [for patients with extensive thrombi, severe symptoms, or thrombi involving the saphenofemoral junction (regarded as high risk for VTE), more aggressive interventions are required, including therapeutic-dose anticoagulants or surgical intervention]

Question 4: In the differential diagnosis of acute thrombosis of the great saphenous vein trunk, compared with deep vein thrombosis (DVT), which of the following clinical features is more consistent with acute thrombosis of the great saphenous vein trunk?

- Diffuse swelling of the entire lower limb
- Positive Homans' sign
- Swelling mostly limited to the calf or the area along the course of the great saphenous vein
- D-dimer test enables definite differentiation
- Often involves the deep venous system

Answer C: It has been clearly mentioned in the "Treatment & prognosis" section. [The typical clinical manifestations of acute thrombosis of the great saphenous vein includes sudden pain, erythema, and palpable, firm, cord-like masses along its course]

Question 5: Regarding the advantages of the dual-balloon technique used in this case for treating acute thrombosis of the great saphenous vein trunk, which of the following statements is incorrect?

- It can rapidly clear the thrombus
- It can completely address the varicose veins
- It increases the risk of intraoperative thrombus dislodgement
- It reduces the patient's treatment costs
- No need for inferior vena cava filter implantation

Answer C: It has been clearly mentioned in the "Treatment & prognosis" section. [This combined regimen integrates the advantages of immediate thrombus removal, venous occlusion, and intraoperative embolism prevention, aiming to achieve one-time radical treatment while reducing the risk of thromboembolism and medical costs]

REFERENCES

- Di Minno MN, Ambrosino P, Ambrosini F, Tremoli E, Di Minno G, Dentali F. Prevalence of deep vein thrombosis and pulmonary embolism in patients with superficial vein thrombosis: a systematic review and meta-analysis. *J Thromb Haemost.* 2016; 14(5): 964-972. PMID: 26845754.

- [2] Poredos P, Spirkoska A, Rucigaj T, Fareed J, Jezovnik MK. Do blood constituents in varicose veins differ from the systemic blood constituents? *Eur J Vasc Endovasc Surg.* 2015; 50(2): 250-256. PMID: 26100448.
- [3] Lattimer CR, Kalodiki E, Geroulakos G, Hoppensteadt D, Fareed J. Are Inflammatory Biomarkers Increased in Varicose Vein Blood? *Clin Appl Thromb Hemost.* 2016; 22(7): 656-664. PMID: 27103338.
- [4] Malone PC, Agutter PS. To what extent might deep venous thrombosis and chronic venous insufficiency share a common etiology? *Int Angiol.* 2009; 28(4): 254-268. PMID: 19648868.
- [5] Scovell SD, Ergul EA, Conrad MF. Medical management of acute superficial vein thrombosis of the saphenous vein. *J Vasc Surg Venous Lymphat Disord.* 2018; 6(1): 109-117. PMID: 29097174.
- [6] Kakkos SK, Gohel M, Baekgaard N, et al. Editor's Choice - European Society for Vascular Surgery (ESVS) 2021 Clinical Practice Guidelines on the Management of Venous Thrombosis. *Eur J Vasc Endovasc Surg.* 2021; 61(1): 9-82. PMID: 33334670.
- [7] Galanaud JP, Genty C, Sevestre MA, et al. Predictive factors for concurrent deep-vein thrombosis and symptomatic venous thromboembolic recurrence in case of superficial venous thrombosis. The OPTIMEV study. *Thromb Haemost.* 2011; 105(1): 31-39. PMID: 20886192.
- [8] Leon L, Giannoukas AD, Dodd D, Chan P, Labropoulos N. Clinical significance of superficial vein thrombosis. *Eur J Vasc Endovasc Surg.* 2005; 29(1): 10-17. PMID: 15570265.
- [9] Górski G, Noszczyk W, Kostewicz W, et al. Progress of local symptoms of superficial vein thrombosis vs. duplex findings. *Vasa.* 2004; 33(4): 219-225. PMID: 15623197.
- [10] Di Nisio M, Van Sluis GL, Bossuyt PM, Büller HR, Porreca E, Rutjes AW. Accuracy of diagnostic tests for clinically suspected upper extremity deep vein thrombosis: a systematic review. *J Thromb Haemost.* 2010; 8(4): 684-692. PMID: 20141579.
- [11] Stevens SM, Woller SC, Kreuziger LB, et al. Antithrombotic Therapy for VTE Disease: Second Update of the CHEST Guideline and Expert Panel Report. *Chest.* 2021; 160(6): e545-e608. PMID: 34352278.
- [12] Scott G, Mahdi AJ, Alikhan R. Superficial vein thrombosis: a current approach to management. *Br J Haematol.* 2015; 168(5): 639-645. PMID: 25521017.
- [13] Casian D, Bzovii F, Culiuc V, Gutu E. Urgent surgery versus anticoagulation for treatment of superficial vein thrombosis in patients with varicose veins. *Vasa.* 2022; 51(3): 174-181. PMID: 35418255.
- [14] Gloviczki P, Lawrence PF, Wasan SM, et al. The 2023 Society for Vascular Surgery, American Venous Forum, and American Vein and Lymphatic Society clinical practice guidelines for the management of varicose veins of the lower extremities. Part II: Endorsed by the Society of Interventional Radiology and the Society for Vascular Medicine. *J Vasc Surg Venous Lymphat Disord.* 2024; 12(1): 101670. PMID: 37652254.
- [15] Zhou, Y. D., Guan, Y. B., Xue, M., Zheng, X. X., & Chen, X. S. (2020). Clinical efficacy of different surgical timings in the treatment of lower extremity varicose veins complicated with acute great saphenous vein thrombosis. *Journal of Vascular and Endovascular Surgery*, 6(3), 194-198, 212.
- [16] Konstantinides SV, Meyer G, Becattini C, et al. The Task Force for the diagnosis and management of acute pulmonary embolism of the European Society of Cardiology (ESC). 2019 ESC Guidelines for the diagnosis and management of acute pulmonary embolism developed in collaboration with the European Respiratory Society (ERS): The Task Force for the diagnosis and management of acute pulmonary embolism of the European Society of Cardiology (ESC). *Eur Respir J.* 2019; 54(3): 1901647. PMID: 31473594.
- [17] Aguilar C, del Villar V. D-dimer is not useful for the diagnosis of isolated superficial venous thrombosis. *Am J Med.* 2005; 118(12): 1417. PMID: 16378801.
- [18] Boettler MA, Kaffenberger BH, Chung CG. Cellulitis: A Review of Current Practice Guidelines and Differentiation from Pseudocellulitis. *Am J Clin Dermatol.* 2022; 23(2): 153-165. PMID: 34902109.

FIGURES

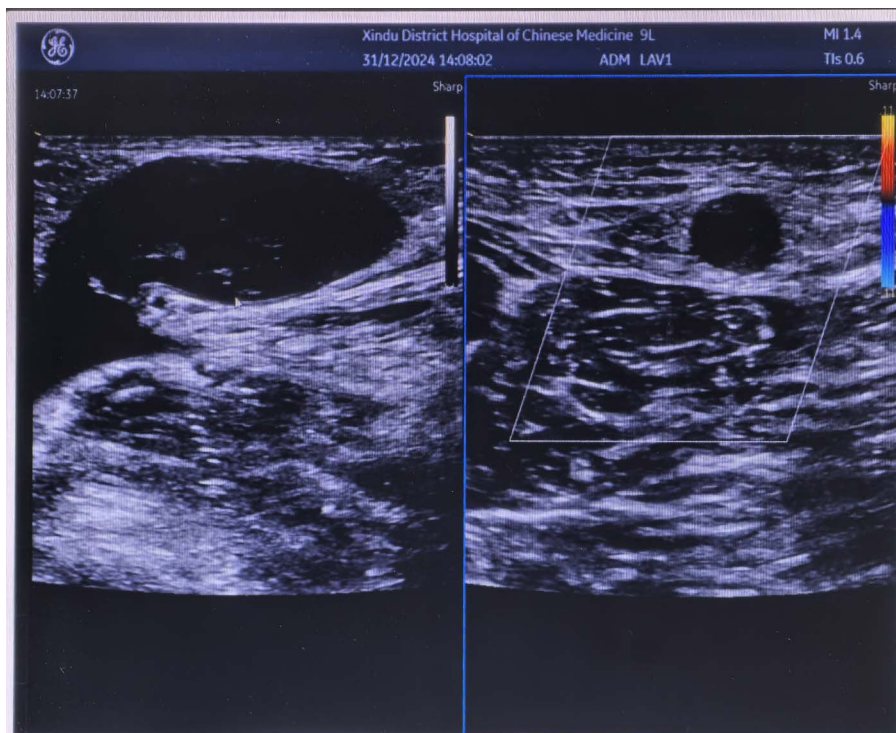


Figure 1A: Doppler ultrasound showed significant dilatation of the main trunk of the right great saphenous vein with thrombosis, and no blood flow signal was detected in the lumen

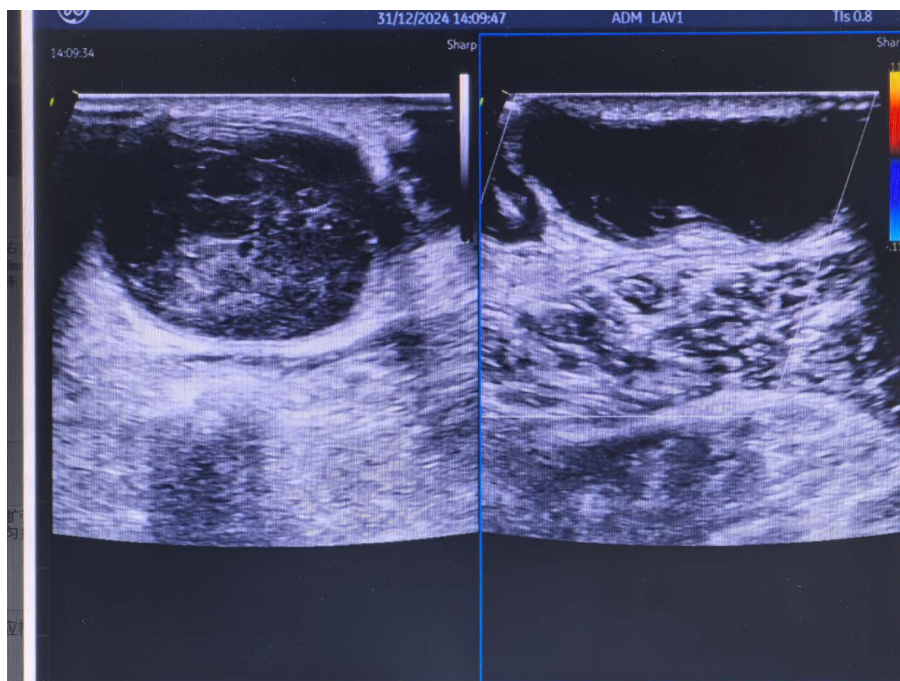


Figure 1B: The main trunk of the great saphenous vein around the right knee joint presented obvious local bulging morphological changes, and a large amount of thrombus filling was observed inside it

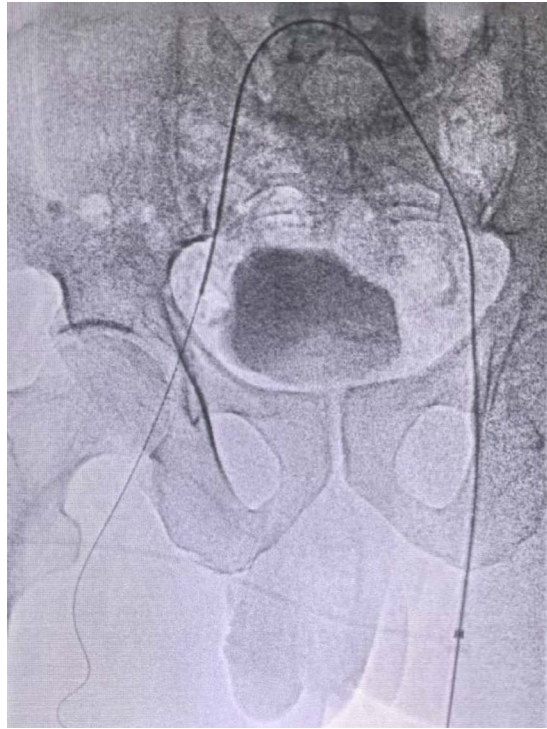

Figure 2: Angiography Examination: A guidewire and a balloon were pre-placed in the affected side femoral vein via the contralateral femoral vein approach.

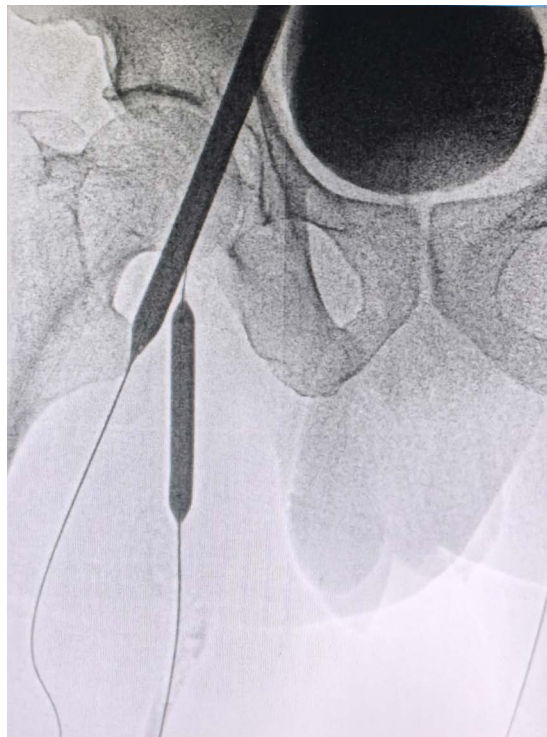


Figure 3: Angiography Examination: The balloon in the right femoral vein and the balloon in the right great saphenous vein were inflated simultaneously.

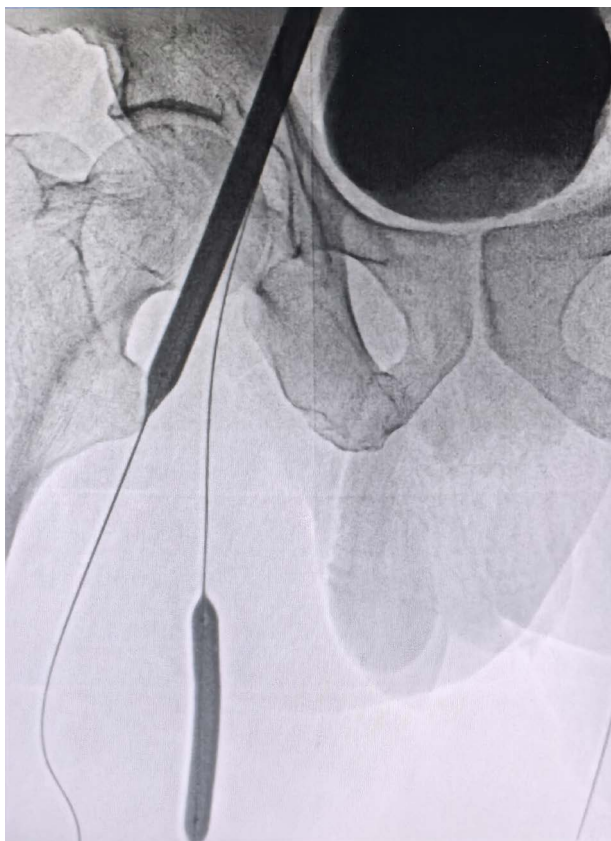


Figure 4A: Inflate the 8×60 mm balloon under non-working pressure, then retract the balloon along the guidewire.

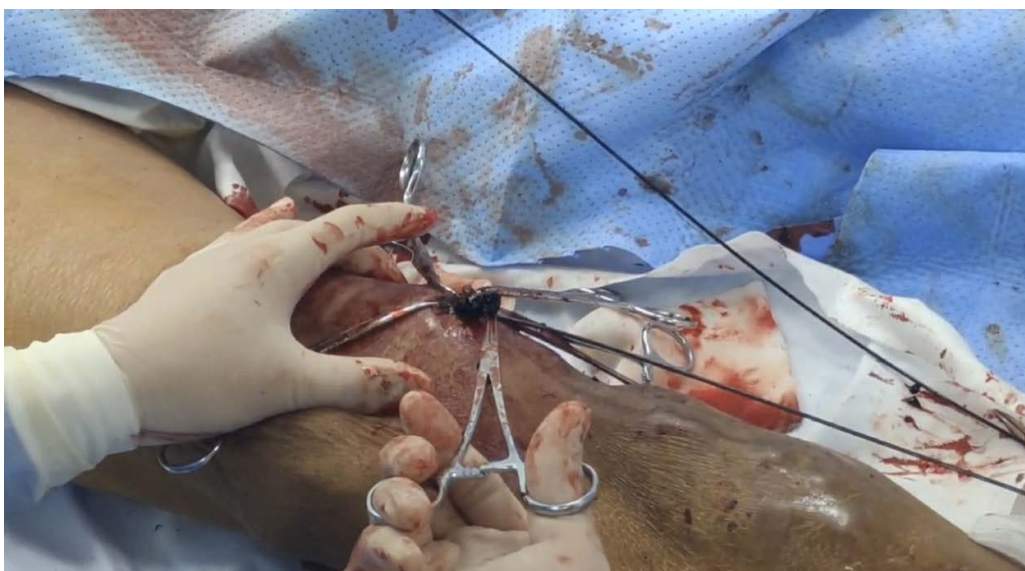

Figure 4B: Utilize the frictional force between the balloon and the blood vessel wall to pull out the thrombus.

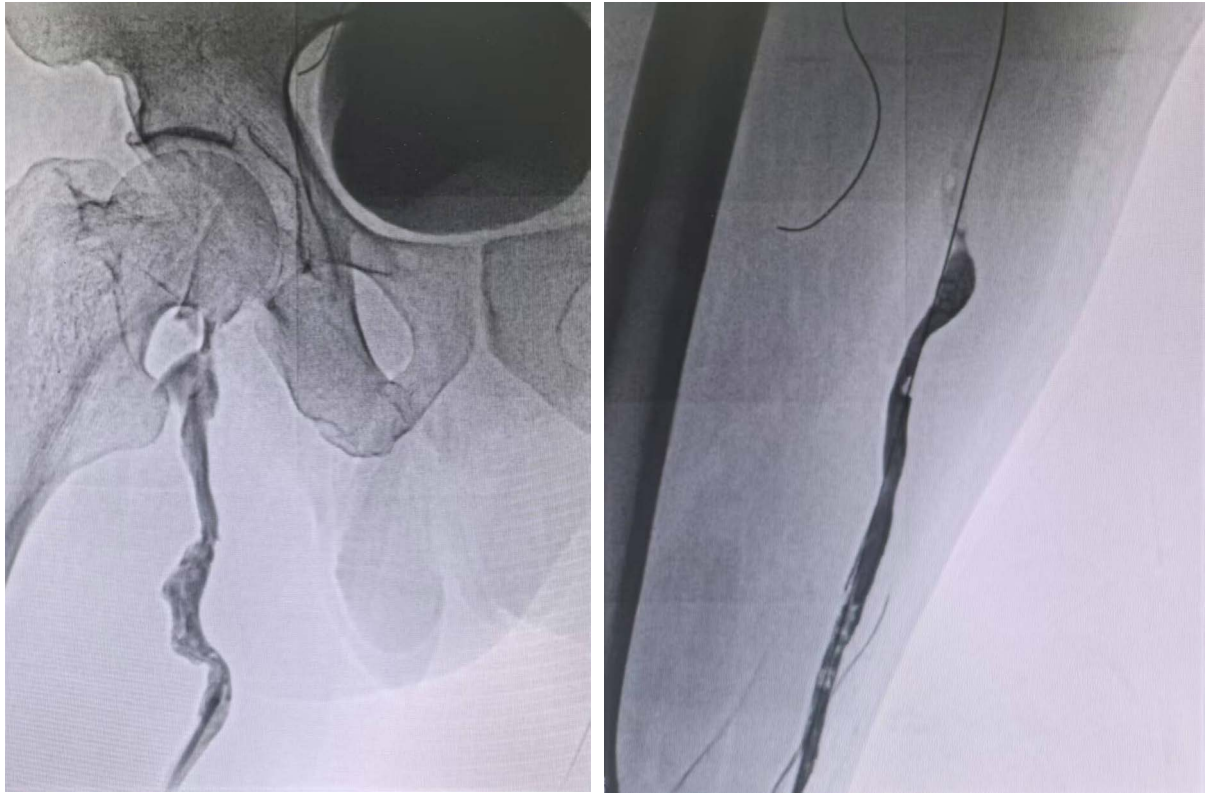

Figure 4C-4D: Angiography shows that the thrombus in the great saphenous vein is basically cleared and the lumen morphology is restored

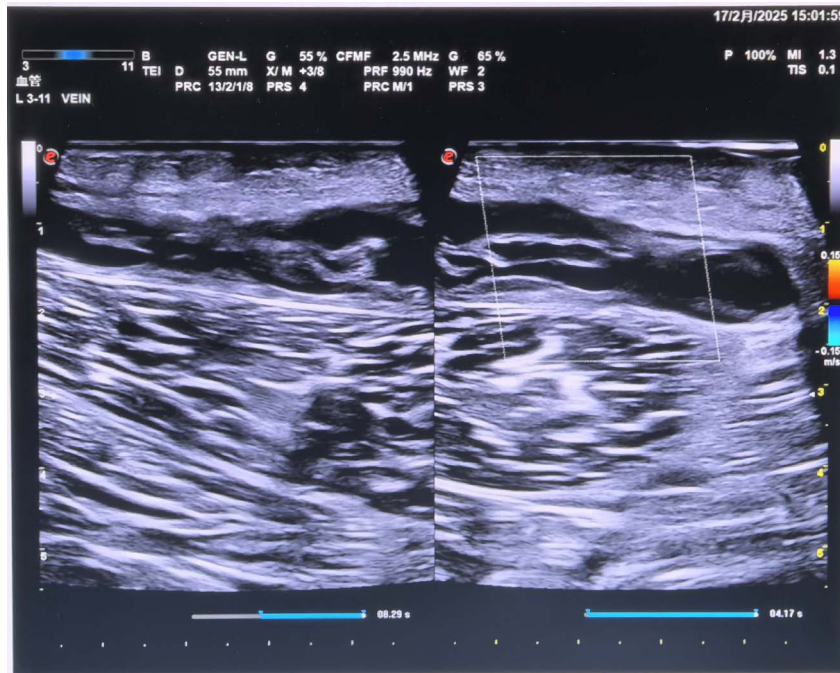


Figure 5: Two months after the operation, DUS showed that the lumen of the great saphenous vein was basically closed, and no obvious blood flow signal was detected in the lumen.

Table 1: Summary table of Varicose Great Saphenous Vein Complicated with Acute Thrombosis

| SUMMARY TABLE | |
|----------------------------|--|
| ETIOLOGY | Local hemodynamic disturbance caused by venous dilatation and insufficiency, accompanied by elevated inflammatory factors and hemodynamic abnormalities |
| INCIDENCE | Unknown |
| AGE PREDILECTION | Adult-onset disease |
| RISK FACTORS | Elevated levels of interleukin-6 (IL-6), interleukin-8 (IL-8), and monocyte chemoattractant protein-1 (MCP-1), along with abnormal venous valve function |
| TREATMENT | Therapeutic-dose anticoagulants or surgical intervention |
| PROGNOSIS | It depends on the extent and location of the thrombus, as well as the severity of phlebitis symptoms; traditional surgical operations cannot avoid problems such as relatively large blood loss and severe surgical trauma, nor can they reduce the incidence of subsequent venous thromboembolism (VTE); endovascular treatment can quickly clear the thrombus, completely address varicose veins, reduce the risk of intraoperative thrombus dislodgement, and lower the patient's costs |
| FINDINGS ON IMAGING | The great saphenous vein shows increased diameter, blood stasis, and intraluminal thrombosis. |

Table 2: Differential Table for Varicose Great Saphenous Vein Complicated with Acute Thrombosis

| Differential | Disease Etiology | Systemic Findings | Imaging Findings |
|--|--|---|---|
| Varicose Great Saphenous Vein Complicated with Acute Thrombosis | Local hemodynamic disturbance caused by venous dilatation and insufficiency, accompanied by elevated inflammatory factors and hemodynamic abnormalities | The typical clinical manifestations of acute thrombosis of the great saphenous vein includes sudden pain, erythema, and palpable, firm, cord-like masses along its course | The great saphenous vein shows increased diameter, blood stasis, and intraluminal thrombosis. |
| Deep Vein Thrombosis | Blood Stasis, Hypercoagulable State, and Vascular Endothelial Injury | Typically presents as diffuse swelling of the entire lower limb, with deeply localized pain, and a positive Homans sign may be present | Blood Stasis in the Deep Venous System and Intraluminal Thrombosis |
| Lower Limb Cellulitis | This is a bacterial infectious skin disease, it is characterized by the frequent presence of a clear entry point for infection (e.g., skin breaks, tinea pedis). | Lower extremity erythema, pain, and swelling | DUS shows no signs of venous thrombosis, but ultrasound may reveal subcutaneous edema |

KEYWORDS

Varicose Great Saphenous Vein, Acute Thrombosis, Superficial Venous Thrombosis, Balloon, Radiofrequency Ablation..

ABBREVIATIONS

GSV = Great Saphenous Vein
SVT = Superficial Venous Thrombosis
VTE = Venous Thrombo Embolism
SFJ = Sapheno Femoral Junction
VCSS = Venous Clinical Severity Score
AVVQ = Aberdeen Varicose Vein Questionnaire
DVT = Deep Vein Thrombosis
PE = Pulmonary Embolism
DUS = Doppler Ultra Sound
NSAIDs = Nonsteroidal Anti-Inflammatory Drugs
IVC = Inferior Vena Cava
CRP = C-Reactive Protein
IL-6 = Inter Leukin-6
IL-8 = Inter Leukin-8
MCP-1 = Monocyte Chemoattractant Protein-1

Online access

This publication is online available at:
www.radiologycases.com/index.php/radiologycases/article/view/6063

Peer discussion

Discuss this manuscript in our protected discussion forum at:
www.radiolopolis.com/forums/JRCR

Interactivity

This publication is available as an interactive article with scroll, window/level, magnify and more features.
Available online at www.RadiologyCases.com

Published by EduRad



www.EduRad.org