

Multimodality Imaging Correctly Diagnosing a Cavernous Cardiac Hemangioma: A Case Report

Yosra Turkistani^{1*}, Sara Al-Harbi², Fatma Aboul-Enein², Fawaz Khateb¹

¹Faculty of Medicine, Umm Al-Qura University, Mecca, Saudi Arabia

²Department of Cardiology, King Abdullah medical city, Mecca, Saudi Arabia

*Correspondence: Yosra Abdulahad Turkistani, Faculty of Medicine, Umm Al-Qura University, Mecca, Saudi Arabia

✉ Yaturkistani@uqu.edu.sa

Radiology Case. 2024 October; 18(10):36-44 :: DOI: 10.3941/jrcr.5441

ABSTRACT

Cardiac hemangioma is a rare benign cardiac tumor. Herein, we report a case of a large cardiac mass in the inter-atrial septum, presenting with syncope. Multimodality imaging correctly characterized the cardiac hemangioma preoperatively and helped plan the surgical excision of this rare cardiac tumor.

CASE REPORT

CASE REPORT

A 51-year-old diabetic male presented to a local hospital with recurrent dizziness and one episode of syncope for 3 minutes. He had atrial fibrillation on the 12-leads ECG and a large echogenic mass attached to the inter-atrial septum on the transthoracic echocardiogram. He was given beta blockers and apixaban for his atrial fibrillation and referred to our institute for resection of possible myxoma.

On presentation to our hospital, he was vitally stable with a normal cardiac examination. His heart sounds were normal, with no added sounds or murmur. JVP was not elevated. His chest was clear to auscultation, and there was no lower limb edema.

Imaging Findings

A transthoracic echocardiogram showed a large (8x6 cm) rounded echogenic mass arising from the inter-atrial septum, bulging into both the left and right atria and filling a significant part of both atrial cavities. It was 17mm from the atrioventricular valves, not affecting valvular function (Figure 1).

Coronary angiography, performed as part of preoperative planning, showed normal coronaries. However, a large vessel was arising from the paraostial segment of the right coronary artery, feeding the tumor with large vascular channels, which retained the contrast for a long time. This finding raised the suspicion of a vascular tumor, namely hemangioma (Figure 2).

Cardiac computed tomography revealed a large, heterogeneous, low-attenuated mass within the inter-atrial septum, characterized by internal scattered enhancing components. It measures about 9 x 9 x 10 cm (Figure 3). The mass exerts a compressive effect on the atria, superior vena cava

(SVC), and the right pulmonary artery (other CT report: and the adjacent left pulmonary vein).

Non-enhanced and arterial phases images were highly suspicious for hemangioma. There was no evidence of vascular occlusion or intra-atrial thrombus but a trace pericardial effusion was noted. The thyroid appeared grossly unremarkable. There was no mediastinal, hilar, or axillary lymphadenopathy. No other masses were seen in the lungs, mediastinum, abdomen, or pelvis.

Cardiac MRI revealed a large, sessile, non-pedunculated mass in the interatrial septum measuring 96 mm (head-foot) x 92 mm (right-left) x 84 mm (anterior-posterior). The mass has smooth margins, is encapsulated, and does not infiltrate nearby structures. It compressed the atrial chambers, superior vena cava (SVC), and right main pulmonary artery. The mass showed homogenous isointense signal intensity on T1WI with no change on FAT SAT. It had homogenous hyperintensity on T2WI. Injection of gadolinium contrast showed rapid first-pass enhancement on resting first-pass perfusion imaging and intense, non-homogeneous delayed hyperenhancement on late gadolinium enhancement (LGE) imaging (Figure 4).

Management

All the findings above were suggestive of cardiac hemangioma. The heart team meeting discussed the case, and he was accepted for surgery.

After a median sternotomy and starting cardiopulmonary bypass, the right atrium was opened. The tumor encompassed the entire right atrium from the superior vena cava down to the inter-atrial septum just above the atrioventricular (AV) valves. It was carefully shaved off along with the right atrial appendage and a portion of the lateral right atrial wall, followed by a patch reconstruction of the right atrial wall and septum.

On gross inspection, the mass was grayish-white, measuring 8.5x7.0x4.0 cm and weighing 162.0 grams (Figure 5). Histological examination demonstrated cavernous hemangioma (Figure 6). The patient had a smooth postoperative course and was discharged one week after the surgery.

Follow up

At the 1-month follow-up, the patient was well with no evidence of tumor recurrence on transthoracic echo. Figure (7)

DISCUSSION

In this case report, we presented a 51-year-old patient who initially presented with syncope caused by a large intracardiac mass. A provisional diagnosis of atrial myxoma was presumed based on the echo findings of the mass arising from the inter-atrial septum. However, multimodality imaging correctly characterized the mass as cardiac hemangioma.

Etiology & demographics

Cardiac hemangiomas are uncommon primary tumors of the heart, with a reported occurrence of 2 % among all primary heart tumors [1]. They are noncancerous vascular tumors classified based on the proliferating vessel. It can be made up of multiple dilated, thin-walled vessels (cavernous), small vessels resembling capillaries (capillaries), or dysplastic arteries and a vein (arteriovenous) [2]. Cardiac hemangioma can be endocardial or intramural. They are usually solitary and can be found in any cardiac chamber, inter-atrial septum, or interventricular septum [3]. We reported a case of a large intracardiac cavernous hemangioma in a middle-aged man.

Clinical and imaging findings

Although benign, clinical presentation can vary depending on location and size, ranging from asymptomatic cases to those experiencing reduced exercise tolerance, chest pain, dyspnea, syncope, tamponade, stroke, or even sudden death [4].

In our case, the patient's symptoms are explained by the mass effect of the large tumor compressing the superior vena cava and filling the right atrial cavity, decreasing preload and, thus, the cardiac output.

Echocardiography is usually the first imaging modality used to diagnose the tumor, defining its size, location, and effect on nearby structures. Cardiac hemangiomas are usually well-circumscribed echogenic masses seen in any cardiac chambers or the septum. Blood flow signal through the mass can be seen by Color Doppler imaging. If image quality allows, 3D echo can help define the 3-dimensional size and location. With contrast-enhanced echocardiography, hyperperfusion relative to the surrounding myocardium can suggest hemangioma [5].

Coronary angiography can demonstrate the presence of feeding vessels and the degree of vascularization of the tumor. The presence of the typical "vascular blush" suggests diagnosis, particularly in capillary and arteriovenous hemangiomas, which

were detected in 80% of cases. Large vascular spaces with slow flow in cavernous hemangiomas may not be enhanced at angiography.

On CT imaging, Cardiac hemangioma can appear with low-density or equal density, oval or round, well-defined mass on non-enhanced images. However, on contrast-enhanced CT, it appears as a heterogeneous and intensely enhanced lesion of the same degree as the cardiac blood pool. However, some slow-flowing masses may show little or no enhancement.

On cardiac MRI, hemangioma typically demonstrates heterogeneous intermediate or low signal intensity on T1-weighted images and high signal intensity on T2-weighted images. Cardiac hemangioma can be diagnosed with PET-CT and angiography exhibiting abnormally increased fluorodeoxyglucose uptake.

Our case has demonstrated the large mass encapsulated by the inter-atrial septum, with typical vascular features on coronary angiography, CT, and cardiac MRI, suggesting the diagnosis of hemangioma.

Treatment & prognosis

Surgical excision is the treatment of choice for cardiac hemangioma, especially if it is symptomatic, large in size, or there is uncertainty about the diagnosis preoperatively. The success of complete resection, with or without reconstruction, depends on its location and origin. Unresectable tumors usually confer a poor prognosis. Conservative treatment with steroids and radiotherapy for cardiac hemangioma was only reported in very few cases [2]. Despite its large size, complete tumor resection with reconstruction of the inter-atrial septum was possible in our case. Postoperative follow-up is necessary to monitor recurrence.

Differential Diagnoses

Myxoma

It is the most common benign cardiac tumor, accounting for 50% of all benign cardiac tumors in adults. They are typically diagnosed between the ages of 30 and 50, with a higher prevalence in males. Around 4.5–10% of cases are familial. On echocardiography, myxomas appear as heterogeneous, mobile masses attached to the fossa ovalis, most commonly extending into the left atrium. They are usually well-defined, ovoid with lobulated contours, and with common calcifications and heterogeneously low attenuating on CT. On MRI, they are iso- to hypointense on T1-weighted images and hyperintense on T2-weighted images. They show uptake on first-pass perfusion and heterogeneous enhancement with contrast.

Angiosarcoma

The most common primary differentiated malignant neoplasm is typically diagnosed between 40 and 50 years old. These tumors are usually found in the right atrium as dense, irregular, and often non-mobile masses with broad-based

endocardial to myocardial extension. On CT, they present as low-attenuation, irregular, intracavitary masses mostly involving the right atrial free wall with heterogeneous enhancement. On MRI, they appear heterogeneous on both T1- and T2-weighted images, with uptake on first-pass perfusion and a characteristic "sunray appearance" with heterogeneous contrast enhancement.

Sarcoma

It accounts for 10% of all primary cardiac tumors and is typically diagnosed around the age of 45, with no sex predilection. On echocardiography, sarcomas appear as broad-based masses with heterogeneous echogenicity commonly located in the left atrium. On CT, they present as large, irregular, intracavitary masses with low attenuation. They are isointense on T1-weighted images and hyperintense on T2-weighted images, with uptake on first-pass perfusion and heterogeneous delayed enhancement.

Lipoma

It constitutes 3% of benign cardiac tumors and is associated with older age, increased body mass, and female sex. Lipomas are typically found in the right atrium. On echocardiography, intracavitary lipomas appear as homogeneous and hyperechoic masses. On CT, they present as homogeneous, low-attenuation masses within a cardiac chamber or pericardial space. They show a hyperintense bright signal on T1- and T2-weighted images, which is reduced with fat suppression techniques, and they exhibit no enhancement.

Lymphoma

It is most commonly found in the pericardial space and is frequently associated with the right-sided chambers. On imaging, lymphomas may present as multiple circumscribed masses or an ill-defined infiltrative lesion, more commonly in the right atrium and often accompanied by pericardial effusion. They are isointense on both T1- and T2-weighted images, with no uptake on first-pass perfusion and variable or no contrast enhancement.

TEACHING POINT

Despite its rarity, multimodality cardiac imaging plays an essential role in the diagnosis and management planning of cardiac hemangioma.

QUESTIONS

Question 1: What is the approximate incidence of cardiac hemangiomas compared to all primary cardiac tumors?

1. 1%
2. 2% (applies)
3. 5%
4. 10%
5. 20%

Explanation:

Hemangioma is a rare benign cardiac tumor that occurs at a rate of 2% of all benign cardiac tumors.

Question 2: Heterogenous intense enhancement of the tumor on coronary angiography is a characteristic feature of which of the following cardiac tumors?

1. Myxoma,
2. Hemangioma (applies)
3. Lipoma
4. Lymphoma
5. Metastasis

Explanation:

1. Myxoma does not have a vascular network that gives the tumor blush
 2. Right answer
 3. Lipoma is non-vascular tumor
 4. lymphoma does not have a vascular network that gives the tumor blush
 5. metastasis does not have a vascular network that gives the tumor blush

Question 3: Cardiac imaging helps differentiate different cardiac tumors; which of the following features favors lipoma?

1. Mobile mass with narrow pedicle arising from the fossa ovalis in echocardiography.
2. Vascular blush on coronary angiography
3. Complete signal loss in fat suppression imaging (applies)
4. Hypointensity on T1WI.
5. Marked contrast enhancement on CT

Explanation

1. Characteristic for myxoma
 2. Characteristic for hemangioma
 3. Right answer
 4. Lipoma is usually hyperintense on T1WI
 5. Lipoma has no contrast enhancement on CT (non-vascular)

Question 4: Which of the following features favor the diagnosis of cardiac angiosarcoma over hemangioma on cardiac imaging?

1. Heterogenous hyperintense appearance on T2WI.
2. Heterogenous enhancement
3. Vascular blush on coronary angiography
4. Location in the right atrium
5. Pericardial thickening and pericardial effusion (applies)

Explanation

1. Both hemangioma and angiosarcoma are hyperintense on T2WI

2. Both hemangioma and angiosarcoma show heterogenous enhancement, with angiosarcoma in a sunray appearance.

3. Vascular blush can be seen in both tumors.

4. Angiosarcoma is commonly seen in the right atrium, but hemangioma can be found in any cardiac chamber, including the right atrium.

5. Pericardial involvement with effusion is usually seen with the malignant cardiac angiosarcoma.

Question 5: Which of the following is adults' most common benign primary cardiac tumor?

1. Hemangioma
2. Rhabdomyoma
3. Lymphoma
4. Myxoma (applies)
5. Lipoma

Explanation

1. Hemangioma is a rare benign primary cardiac tumor (PCT), accounting for 2% of PCT.

2. Rhabdomyoma is the most common benign PCT in infants and children, accounting for more than 60% of all PCTs

3. Lymphoma is a malignant tumor.

4. Myxoma is the most frequent benign PCT in adults, making up 50–70% of them

5. Lipoma constitutes approximately 10% of benign PCTs,

Authors' contributions

Study conception and design: Yosra Turkistani , Sara Alharbi,;

Data collection: Sara Alharbi , Fawaz Khateb;

Analysis and interpretation of results: Yosra Turkistani, Sara Alharbi, Fatma Aboul-Enein;

Draft manuscript preparation: Yosra Turkistani, Fawaz Khateb .

All authors reviewed the results and approved the final version of the manuscript.

Acknowledgements

We want to express our heartfelt thanks to Dr.Mohammad Miny and Dr.Tahira Mahmood for enriching the case report with great gross and histopathology imaging.

Disclosures

The authors declare no financial or competing interests.

Consent

Did the author obtain written informed consent from the patient for submission of this manuscript for publication? Yes and approval by Institutional Review Board – IRB Office at the Executive Administration of Research and Innovation at King Abdullah Medical City, No (24-1303) obtained on (1/08/2024)

Human and animal rights

This case report is a retrospective report, does not involve experiments on human or animal subjects.

REFERENCES

1. Kobayashi T, Numata S, Hohri Y, Kawajiri H, Yaku H. Cardiac cavernous hemangioma with high fluorodeoxyglucose uptake on preoperative positron emission tomography/computed tomography: a case report. *Cardiooncology*. 2023; 9(1): 54-61.
2. Wang P, Chapman D, Siddiqui F. A rare cardiac cavernous hemangioma treated with radiotherapy. *Case Rep Vasc Med*. 2022; 2022: 5698475. PMID: 36105488.
3. Lin Y, Wu W, Gao L, Ji M, Xie M, Li Y. Multimodality imaging of benign primary cardiac tumors. *Diagnostics (Basel)*. 2022; 12(10): 2543. PMID: 36292232.
4. Berdica L, Kola E, Nakuci D, Horjeti E, Alimehmeti M. Cardiac hemangioma presenting as a primary cardiac tumor. *Cardiooncology*. 2023; 9(1): 41-48. PMID: 36647178.
5. Parato VM, Nocco S, Alunni G, et al. Imaging of cardiac masses: an updated overview. *J Cardiovasc Imaging*. 2022; 32(2): 101-110. PMID: 36249434.

FIGURES

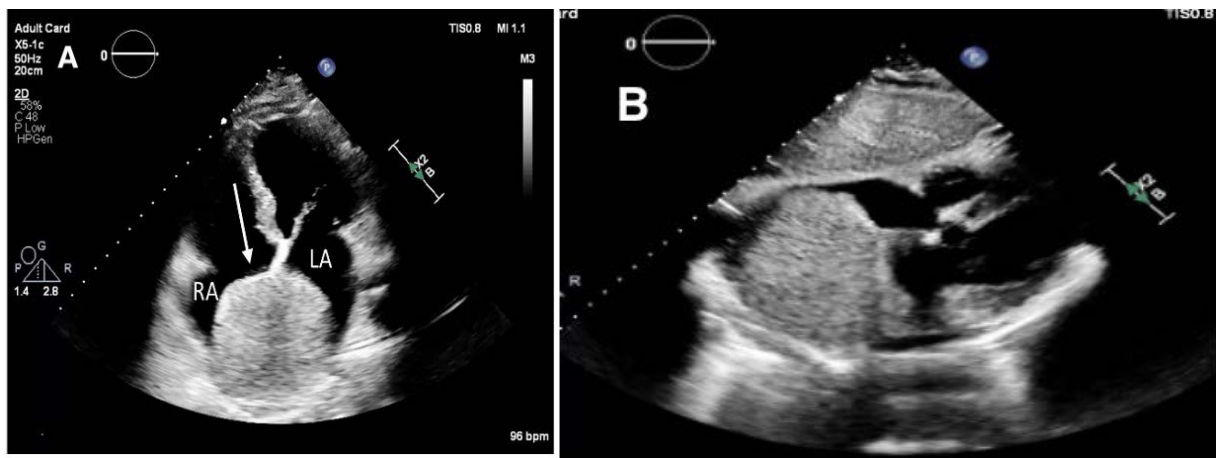


Figure 1: Transthoracic echocardiogram, Apical 4C view (A), and subcostal view (B) show a large (8x6cm), rounded echogenic mass arising from the inter-atrial septum, bulging into both the left and right atria and filling a significant part of both atrial cavities (white arrow). It was 17mm from the atrioventricular valves, not affecting valvular function.

Technique: Transthoracic echocardiography by EPIC CVx PHILIPS machine (cardiac transducer, 2-dimensional scanning) RA: right atrium, LA: left atrium

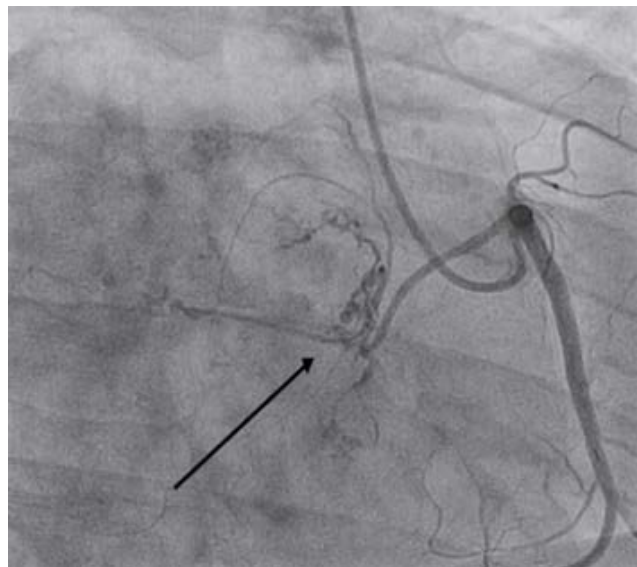


Figure 2. Coronary angiography, performed as part of preoperative planning, showed normal coronaries. However, the right coronary artery on a right anterior oblique view showed a large vessel arising from the paraostial segment of the right coronary artery, seen feeding the tumor with large vascular channels, which retained the contrast for a long time. This finding raised the suspicion of a vascular tumor, namely hemangioma.

Technique: Coronary angiogram. Access: 6F sheath left radial artery. Catheters: 6F JL 3.5 diagnostic catheter to engage the Left coronary artery and 6F JR4 Guide catheter used to engage the Right coronary artery.

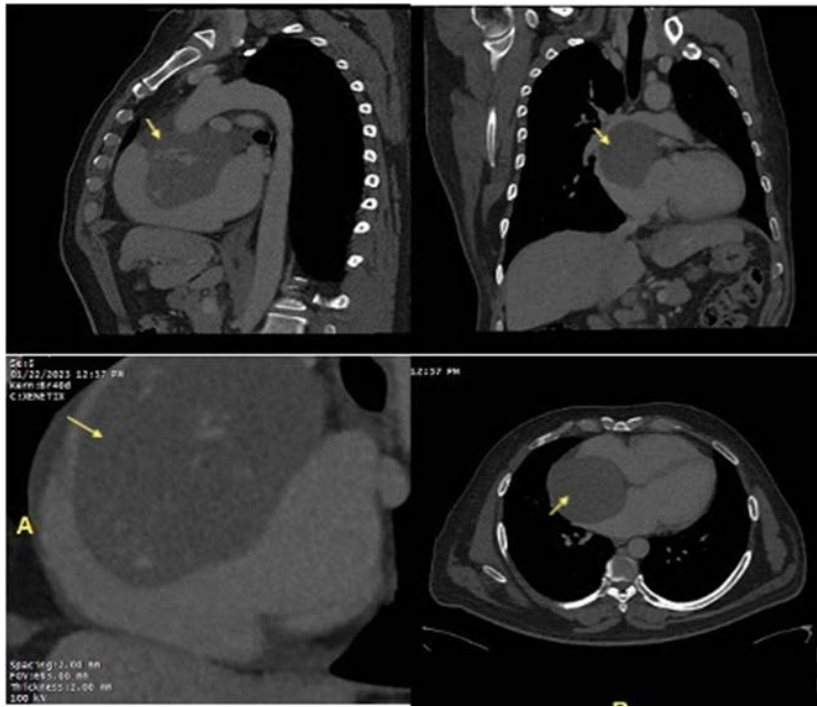


Figure 3: Cardiac computed tomography revealed a large, heterogeneous, low-attenuated mass within the inter-atrial septum, characterized by internal scattered enhancing components. It measures about 9 x 9 x 10 cm (arrow). It compresses the atria, the superior vena cava—and the right pulmonary artery.

Technique: Siemens Somatom Force scanner, Phase Non-contrast, and Arterial Phase. 0.6 mm slice thickness. The contrast agent used Xenetix 350 85 ml, Total DLP 521 mGycm, and Total mAs 2697.

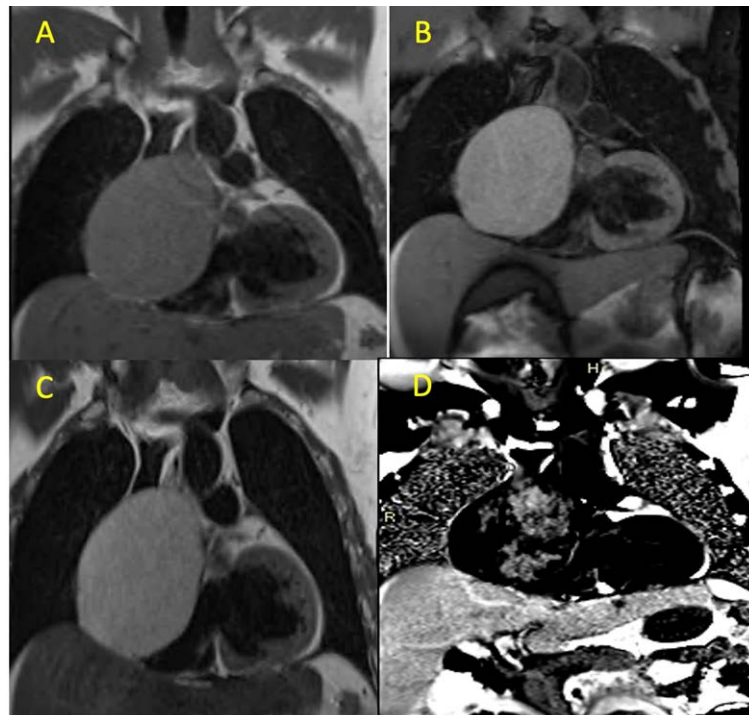


Figure 4: Cardiac MRI showing a large sessile (not pedunculated), non-mobile mass in the interatrial septum appearing homogeneous and iso-intense to the myocardium on T1W (A) with no change on T1W FS(B). T2W shows the mass as homogenous and hyper-intense relative to the myocardium (C). Injection of gadolinium contrast showed intense, non-homogeneous delayed hyperenhancement on Phase-sensitive inversion-recovery (PSIR) (D).

Technique: 1.5 Tesla Siemens Magnetom Area scanner, slice thickness 5 mm, Contrast agent used Dotarem 0.5 mmol/ ml.

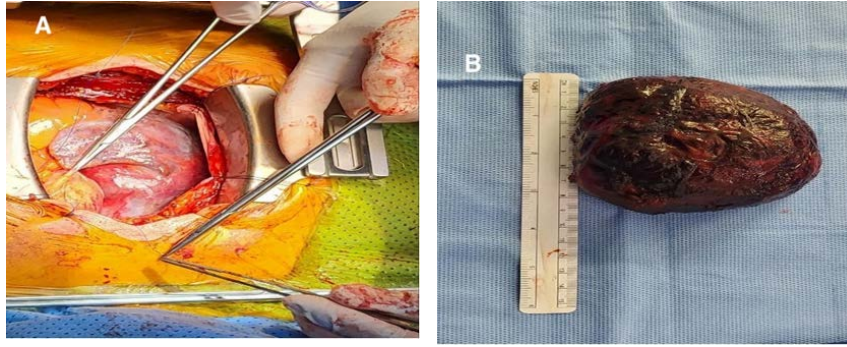


Figure 5: Intraoperative findings of a tumor encompassing the entire right atrium from the superior vena cava down to the septum (A) Gross inspection, the mass was grayish-white, measuring 8.5x7.0x4.0 cm and weighing 162.0 grams (B)

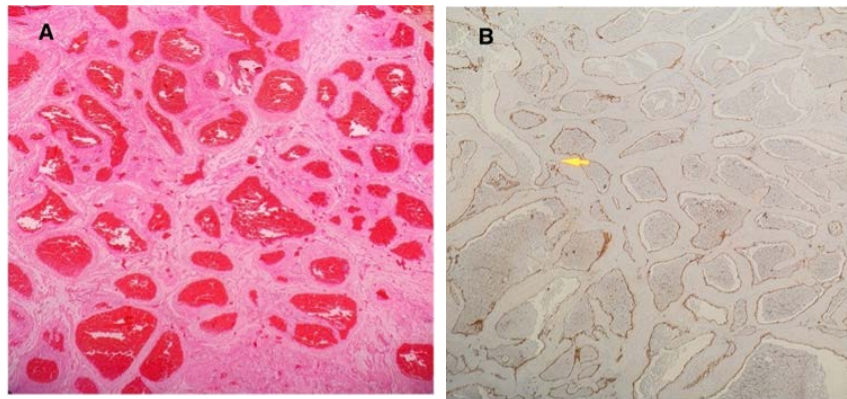


Figure 6: Histological examination demonstrated dilated vascular cavities with many red blood cells in the lumen (A). The immunohistochemical results showed CD34 was positive in vascular endothelium(B)

Technique: Histopathology evaluation (A) H&E staining (x200). Immunohistochemistry for CD34 (B)

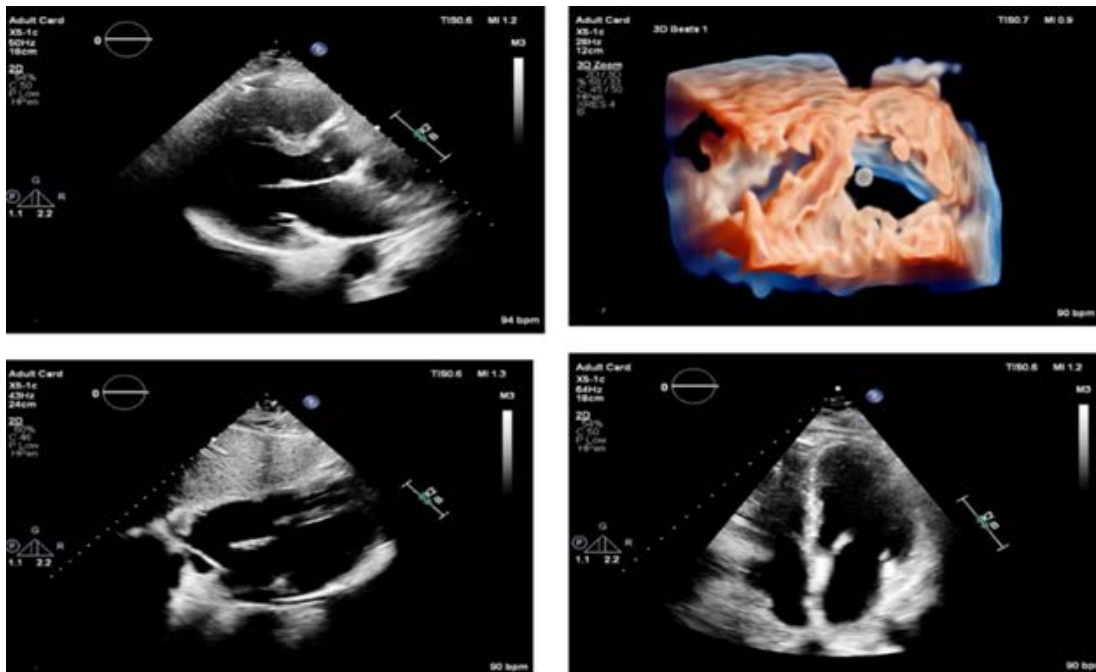


Figure 7: Follow-up transthoracic echocardiography. Parasternal long axis view (A), 3-dimensional short axis view at mid-LV (B), subcostal (C), apical 4C view(D) showing no residual tumor/ mass post-operatively.

Technique: Transthoracic echocardiography by EPIC CVx PHILIPS machine (cardiac transducer, 2-dimensional scanning.

Table 1: Summary table of Cardiac Hemangioma

Etiology	· Congenital, genetic factors, unknown
Incidence	· Incidence of primary cardiac tumors at autopsy is approximately 17 in a million. · Cardiac hemangiomas constitute only 2.8% of primary cardiac tumors.
Gender ratio	· Females are affected more frequently than males.
Age predilection	· Can occur in a wide age group. · Larger group present in adulthood. · Smaller group affecting childhood.
Risk factors	Unknown
Treatment	· Corticosteroid, β -receptor blocker, and interferons · surgical resection
Prognosis	The prognosis of CH is not favorable even though 90% of patients remained stable without tumor regrowth.
Finding on imaging	<ul style="list-style-type: none"> · At echocardiography a well-circumscribed echogenic mass that occasionally oscillates with the cardiac cycle. · Color Doppler flow imaging reveals detectable blood flow signals in this tumor. · Contrast echocardiography reveals hyper-perfusion relative to the surrounding myocardium. · On unenhanced CCT <ul style="list-style-type: none"> - Cardiac hemangiomas appear as a well-defined oval or round and low-density or equal-density mass. - Sometimes, localized high-density shadows can be seen because of their fibers or phleboliths (calcified thrombi). · On contrast-enhanced CT they demonstrate as intense and heterogeneous. · MRI <ul style="list-style-type: none"> - Cardiac hemangiomas generally present as heterogeneous intermediate signal intensity or hypointense signal intensity on T1WI and hyperintense on T2WI. Occasionally, areas of heterogeneous hypointense signal intensity can be described on T2WI. - They manifest as heterogeneous enhancement or avid first-pass enhancement on resting first-pass perfusion images after injection of gadolinium contrast material

Table 2: Differential table of Cardiac Hemangioma

Type of tumor	Echo Features	CT Features	MRI Features
Myxoma	Heterogeneous; narrow pedicle; regular mobile throughout the cardiac cycle	Heterogeneous; low-attenuation; calcification seen in 10–20% of patients	Shape: Smooth, well-defined, lobular or oval T1WI: Isointense T2WI: Hyperintense Enhancement: Heterogeneous
Hemangioma	Well-circumscribed; oscillated with the cardiac cycle; blood flow signals on color Doppler flow imaging; obviously enhancement	Well-defined; low density or equal density; heterogeneous intense enhancement; “vascular blush” on coronary angiography	T1WI: Heterogeneous, isointense or hypointense T2WI: Hyperintense Enhancement: Heterogeneous
Angiosarcoma	Mostly arise in right atrium •Commonly involves the pericardium with pericardial effusion	Filling defect in right atrium that extends across the adjacent wall of right atrium into the epicardial fat, mostly associated with pericardial effusion	T1: Heterogeneous•T2: Heterogeneous•Uptake on perfusion imaging: Present•LGE: Heterogeneous Morphologically, angiosarcoma is a hemorrhagic mass with ill-defined margins and multiple necroses, calcification, and lobulation. The pericardial morphology is characterized by invasive pericardial masses, pericardial thickening, and hemorrhagic pericardial effusion, with right heart failure and cardiac tamponade as the most common manifestations. The heterogeneous hyperintense appearance on T1- and T2-weighted imaging is consistent with the necrosis and hemorrhage within the tumor, which is like a “cauliflower.” The tumor is characterized by obvious enhancement with a “sunray” appearance (37). The large intralésional vessels are often shown as empty blood flow signals on CMR.
Paraganglioma	Granular; oval; well-demarcated; broad base; heterogeneous	Well-circumscribed; heterogeneous; low attenuation; heterogeneous marked enhancement	T1WI: Isointense or hypointense T2WI: Hyperintense Enhancement: Heterogeneous with peripheral rim
Lipoma	Usually hypoechoic in the pericardial space, homogenous and hyperechoic in cardiac chambers; broad base; immobile; well-circumscribed	Homogeneous fat attenuation; well-defined; smooth; encapsulated; no contrast enhanced	T1WI: Homogeneous hyperintense with complete signal loss in fat suppression sequence T2WI: Hyperintense Enhancement: None

KEYWORDS

Hemangioma; Cardiac; Computed tomography; Magnetic Resonance Imaging; Echocardiography; Tumor

ABBREVIATIONS

CT = Computed Tomography
MRI = Magnetic Resonance Imaging
T1WI = T1-Weighted Imaging
T2WI = T2-Weighted Imaging
FAT SAT = Fat Saturation
LGE = Late Gadolinium Enhancement
SVC = Superior Vena Cava
PCT = Perfusion Computed Tomography

Online access

This publication is online available at:
www.radiologycases.com/index.php/radiologycases/article/view/5441

Peer discussion

Discuss this manuscript in our protected discussion forum at:
www.radiopolis.com/forums/JRCR

Interactivity

This publication is available as an interactive article with scroll, window/level, magnify and more features.
Available online at www.RadiologyCases.com

Published by EduRad



www.EduRad.org