

Recurrent Oculomotor Neurovascular Conflict Caused by Fetal Posterior Cerebral Artery: Case Report And Review of Literature

Mohammed Sabawi¹, Jacob A Schroeder¹, Fausto Carlos Dier Melo², Márcio Luís Duarte^{3,4}, Nitesh Shekhrajka¹, Leonardo Furtado Freitas^{1*}

¹Division of Neuroradiology, Department of Radiology, University of Iowa Hospitals and Clinics, USA

²Department of Neurology, University of Iowa Hospitals and Clinics, USA

³Department of Radiology, Universidade de Ribeirão Preto - Campus Guarujá, Guarujá, Brazil

⁴Department of Radiology, Diagnósticos da América S.A., Brazil

*Correspondence: Leonardo Furtado Freitas, Division of Neuroradiology, Department of Radiology, University of Iowa Hospitals and Clinics, Iowa City, Iowa, USA

✉ drleonardofurtado@gmail.com

Radiology Case. 2024 September; 18(9):1-7 :: DOI: 10.3941/jrcr.5418

ABSTRACT

Neurovascular conflict, often asymptomatic, necessitates investigation when neuropathy is suspected. Oculomotor nerve involvement is rare, commonly attributed to microvascular issues, trauma, tumors, or surgery. Arterial conflicts are typically more symptomatic. Clinical presentation includes ptosis and muscle paralysis, with pupillary asymmetry indicating compression of specific nerve areas. Imaging advancements aid in detection, highlighting vessels like the PCA, SCA, Pcom, and ICA, along with anatomical variants. Differential diagnoses encompass various vascular, infectious, inflammatory, and neoplastic conditions. Treatment begins with medical management, using steroids or carbamazepine, with microvascular decompression as a surgical option in persistent cases. Careful consideration is needed due to surgical risks. We aim to present an uncommon oculomotor neurovascular conflict caused by fetal posterior cerebral artery detected by CT scan and MRI.

CASE REPORT

CASE REPORT

A 54-year-old male presenting with nine days of progressively worsening left upper eyelid drooping and double vision. This has happened three times before in the past year, but the symptoms always resolved within a day. On physical exam the patient has drooping of the left upper lid and a down and out position of the left eye. The pupil remained unaffected. He had minimal improvement with an ice pack test, and there was no fatiguing ptosis during held upgaze, or Cogan's lid twitch.

Imaging Findings

The patient underwent brain magnetic resonance imaging (MRI) and magnetic resonance angiography (MRA) which showed mild atrophy of the left *levator palpebrae superioris*/superior rectus muscles (Figure 1), and contact between the proximal fetal left posterior cerebral artery (PCA) with a prominent posterior communicating artery (PCom) and the distal cisternal left oculomotor nerve, at the cavernous sinus entrance (Figure 2).

The ophthalmology team recommended eye patch to help with his double vision and steroid treatment.

DISCUSSION

Etiology & Causes

Neurovascular conflict is a relatively controversial topic in neuroradiology literature, given that the contact between cranial nerves and vessels often occurs in asymptomatic patients. However, it is incumbent upon the neuroradiologist to explore this potentiality upon clinical suspicion of a particular neuropathy, aiming to reveal any signs of displacement, compression, abnormal signal, or caliber [1].

Involvement of the oculomotor nerve is relatively uncommon [2-4] compared to others such as the trigeminal, facial, and vestibulocochlear nerves [1]. Microvascular causes are the most common causes (42%), followed by trauma (12%), tumor (11%), neurosurgery (10%), aneurysm (6%), other (5%), stroke (4%), undetermined (4%), pituitary apoplexy (2%), Tolosa-Hunt syndrome (2%), and giant cell arteritis (1%). The most implicated blood vessels are the superior cerebellar artery (SCA), PCA, fetal PCA [5], and persistent trigeminal artery. In general, arterial conflicts are more symptomatic than venous ones, and therefore the ones that should be valued. Only 43 cases of oculomotor involvement attribute to isolated neurovascular conflict [6].

Clinical Findings

Typically, the clinical presentation is ptosis and paralysis of the extrinsic ocular muscles, except for the lateral rectus and superior oblique muscles, which are innervated by the abducens and trochlear nerves, respectively. Contrary to common belief, pupillary asymmetry (anisocoria) is only observed when compression occurs along the superomedial quadrant of the oculomotor nerve, where the parasympathetic fibers are located (Figure 3). Consequently, inferolateral displacement of the nerve, sparing the medial parasympathetic fibers, may lead to the absence of pupillary dysfunction, potentially resulting in misdiagnosis [7]. The main clinical findings of worsening left upper eyelid drooping, double vision and unaffected pupil were explained by the fetal left PCA causing superolateral compression of the oculomotor nerve, demonstrated on neuroimaging. The progressive and recurrent presentation could be related to arterial blood pressure variations.

The acute manifestation of pulsations on the nerve may explain the sudden onset, while the ischemic impact of pulsations and vessel age-related sclerosis may elucidate the chronic and persistent forms, occasionally presenting intermittently as seen in our patient (oculomotor neuromyotonia - ONM). Symptomatology plays a pivotal role in guiding toward the probable diagnosis: compression typically implicates pial vessels, consequently affecting parasympathetic fibers and resulting in pupillary abnormalities. Conversely, ischemic and metabolic factors affect the vasa nervorum in the central region of the nerve, leading to muscular paralysis [3].

Imaging findings

With the introduction of advanced heavily T2-weighted magnetic resonance (MR) sequences, such as three-dimensional (3D) constructive interference in steady state (CISS), fast imaging employing steady-state acquisition (FIESTA), or 3D T2-SPACE [4], along with MRA, there has been an increase in the identification of neurovascular conflicts [3]. In cases where the brain appears otherwise normal, these cranial nerve sequences can be crucial in diagnosing neurovascular conflict [5]. According to the literature, the vessels most commonly implicated in oculomotor neurovascular conflict are the PCA, SCA, PCOM, and a tortuous internal carotid artery (ICA) [5]. Additionally, anatomical variants such as a persistent trigeminal artery and a duplicated or elongated SCA have also been reported to cause such conflicts [1].

Differential diagnoses

Neurovascular compression is a rare and often overlooked cause of oculomotor nerve palsy. In the absence of trauma, this finding strongly indicates a chronic compressive lesion rather than an ischemic, demyelinating [8], inflammatory, or infectious cause [9]. Diabetes mellitus can also lead to an ischemic oculomotor nerve dysfunction usually sparing the pupil [2]. Intracranial lesions, brainstem infarction, trauma and cavernous sinus tumors are known causes of oculomotor palsy without pupil sparing [10].

Therefore, while neurovascular compression is highly sensitive in detecting nerve paralysis (88,5%), its specificity is low (50%) in MRA. Careful consideration is required when attributing oculomotor nerve palsy to vascular compression [12]. It is crucial to conduct a comprehensive evaluation for other possible causes, including vascular disorders, infectious diseases (such as neurosyphilis, neuroborreliosis, tuberculosis, and Human immunodeficiency virus - HIV) [11], diabetes [2], inflammatory conditions (like Miller-Fisher syndrome and chronic inflammatory demyelinating polyneuropathy (CIDP)), tumors, and Tolosa-Hunt syndrome [3].

Treatment & Prognosis

The initial therapeutic strategy should prioritize medical interventions. Steroids are recommended for acute onset persistent cases associated with inflammation, while carbamazepine (200mg - twice a day) is advised for intermittent cases. Success rate has been reported to vary from 87.8% to 100%, which implies a good prognosis [13]. In certain mild acute instances, a conservative approach may be deemed appropriate. Microvascular decompression (MVD) could be suggested if remission isn't achieved following pharmacological treatment or in cases of chronic persistent manifestation. However, the severity of symptoms must surpass surgical risks before contemplating the procedure [3].

TEACHING POINT

Before concluding that acquired oculomotor nerve palsy is idiopathic, it is important to rule out neurovascular conflict using MR imaging. Understanding the anatomical variants of the circle of Willis is crucial in identifying potential causes of oculomotor neurovascular conflict.

QUESTIONS

Applies to article: *Belotti F, Zanin L, Fontanella MM, Panciani PP. The oculomotor neurovascular conflict: Literature review and proposal of management. Clin Neurol Neurosurg. 2020 Aug;195:105920. doi: 10.1016/j.clineuro.2020.105920.*

1 - Which of the following statements is not a cause of oculomotor neurovascular conflict?

- Microvascular.
- Trauma
- Tumor
- Neurosurgery
- Ptosis

Explanation:

- Microvascular [Is a cause in 42% of the cases].
- Trauma [Is a cause in 12% of the cases]
- Tumor [Is a cause in 11% of the cases]
- Neurosurgery [Is a cause in 10% of the cases]
- Ptosis (applies; is a clinical presentation).

Applies to article: *Belotti F, Zanin L, Fontanella MM, Panciani PP. The oculomotor neurovascular conflict: Literature review and proposal of management. Clin Neurol Neurosurg. 2020 Aug;195:105920. doi: 10.1016/j.clineuro.2020.105920.*

2 - Which of the following statements is not a cause of oculomotor neurovascular conflict?

- Aneurysm.
- Stroke.
- Paralysis of the extrinsic ocular muscles.
- Pituitary apoplexy.
- Tolosa-Hunt syndrome.

Explanation:

- Aneurysm [Is a cause in 6% of the cases].
- Stroke [Is a cause in 4% of the cases]
- Paralysis of the extrinsic ocular muscles (applies; is a clinical presentation).
- Pituitary apoplexy [Is a cause in 2% of the cases]
- Tolosa-Hunt syndrome [Is a cause in 2% of the cases]

Applies to articles: *Belotti F, Zanin L, Fontanella MM, Panciani PP. The oculomotor neurovascular conflict: Literature review and proposal of management. Clin Neurol Neurosurg. 2020 Aug;195:105920. doi: 10.1016/j.clineuro.2020.105920* and *Li A, Tandon A, Tsiouris AJ, Dinkin MJ, Oliveira C. Teaching NeuroImages: Pupil-sparing compression of oculomotor nerve by posterior cerebral artery vessel. Neurology. 2020 Mar 31;94(13):e1450-e1451. doi: 10.1212/WNL.00000000000009181.*

3 - Which of the following statements is true about oculomotor neurovascular conflict?

- Involvement of the oculomotor nerve is relatively common.
- The clinical presentation is blurry vision.
- Ischemic and metabolic factors affect the vasa nervorum in the central region of the nerve do not lead to muscular paralysis.
- Symptomatology plays a pivotal role in guiding toward the probable diagnosis.
- Anisocoria does not occurs in oculomotor neurovascular conflict.

Explanation:

- Involvement of the oculomotor nerve is relatively common [Involvement of the oculomotor nerve is relatively uncommon].
- The clinical presentation is blurry vision [The clinical presentation is ptosis and paralysis of the extrinsic ocular muscles].
- Ischemic and metabolic factors affect the vasa nervorum in the central region of the nerve do not lead to muscular paralysis [Ischemic and metabolic factors affect the vasa nervorum in the central region of the nerve, leading to muscular paralysis.
- Symptomatology plays a pivotal role in guiding toward the probable diagnosis (applies).
- Anisocoria does not occurs in oculomotor neurovascular conflict [anisocoria is only observed when compression occurs along the superomedial quadrant of the oculomotor nerve].

Applies to article: *Sivasubramaniyan KM, Nagarajan K, Rajeswari A, Sathiaprabhu A. A Case of Oculomotor Nerve Palsy caused by Neurovascular Compression by the Fetal Posterior*

Communicating Artery with a Review of Literature. Neurol India. 2019 Sep-Oct;67(5):1390-1392. doi: 10.4103/0028-3886.271270.

4 - What imaging techniques have been instrumental in identifying neurovascular conflicts?

- T1-weighted MR sequence.
- Dixon MR sequence.
- T1 FAT SAT with contrast MR sequence.
- ADC
- Advanced heavily T2-weighted MR sequences, such as CISS, FIESTA, or 3D T2-SPACE

Explanation:

- T1-weighted MR sequence [Advanced heavily T2-weighted MR sequences, such as CISS, FIESTA, or 3D T2-SPACE, along with MRA].
- Dixon MR sequence [Advanced heavily T2-weighted MR sequences, such as CISS, FIESTA, or 3D T2-SPACE, along with MRA].
- T1 FAT SAT with contrast MR sequence [Advanced heavily T2-weighted MR sequences, such as CISS, FIESTA, or 3D T2-SPACE, along with MRA].
- ADC [Advanced heavily T2-weighted MR sequences, such as CISS, FIESTA, or 3D T2-SPACE, along with MRA]
- Heavily T2-weighted MR sequences, such as CISS, FIESTA, or 3D T2-SPACE (applies)

Applies to article: *Sivasubramaniyan KM, Nagarajan K, Rajeswari A, Sathiaprabhu A. A Case of Oculomotor Nerve Palsy caused by Neurovascular Compression by the Fetal Posterior Communicating Artery with a Review of Literature. Neurol India. 2019 Sep-Oct;67(5):1390-1392. doi: 10.4103/0028-3886.271270.*

5 - Which vessels are not implicated in oculomotor neurovascular conflict?

- Collicular artery.
- Prominent posterior communicating artery.
- Superior cerebellar artery.
- Posterior cerebral artery.
- Tortous internal carotid artery

Explanation:

- Collicular artery (applies).
- Prominent posterior communicating artery [Is commonly implicated in oculomotor neurovascular conflict].
- Superior cerebellar artery [Is commonly implicated in oculomotor neurovascular conflict].
- Posterior cerebral artery [Is commonly implicated in oculomotor neurovascular conflict].
- Tortous internal carotid artery [Is commonly implicated in oculomotor neurovascular conflict].

DISCLOSURES

All the authors have indicated they have no financial relationships relevant to this article to disclose.

Authors' contributions

Mohammed Sabawi: conceptualization, clinical data, interpretation, writing and editing

Jacob A Schroeder: conceptualization, interpretation, writing and editing

Fausto Carlos Dier Melo: conceptualization, clinical data, interpretation, writing and editing

Márcio Luís Duarte: interpretation, writing and editing

Nitesh Shekhrjka: conceptualization, clinical data, interpretation, writing and editing

Leonardo Furtado Freitas: conceptualization, clinical data, interpretation, writing and editing

CONSENT

Did the author obtain written informed consent from the patient for submission of this manuscript for publication? Yes.

HUMAN AND ANIMAL RIGHTS

Disclosure the authors state that the procedures were followed according to the Declaration of Helsinki and the World Medical Association regarding human experimentation developed for the medical community.

REFERENCES

- Haller S, Etienne L, Kövari E, Varoquaux AD, Urbach H, Becker M. Imaging of Neurovascular Compression Syndromes: Trigeminal Neuralgia, Hemifacial Spasm, Vestibular Paroxysmia, and Glossopharyngeal Neuralgia. *AJNR Am J Neuroradiol*. 2016; 37(8): 1384-1392. PMID: 26892985.
- Silva EB Jr, Ramina R, Meneses MS, Kowacs PA, Silva EB. Bilateral oculomotor nerve palsies due to vascular conflict. *Arq Neuropsiquiatr*. 2010; 68(5): 819-821. PMID: 21049203.
- Belotti F, Zanin L, Fontanella MM, Panciani PP. The oculomotor neurovascular conflict: Literature review and proposal of management. *Clin Neurol Neurosurg*. 2020; 195: 105920. PMID: 32474258.
- Maher M, Adams C, Moonis G, Brooks SE. Neurovascular compression of the oculomotor nerve presenting with aberrant reinnervation. *Am J Ophthalmol Case Rep*. 2020; 21: 100972. PMID: 33426366.
- Sivasubramaniyan KM, Nagarajan K, Rajeswari A, Sathiaprabhu A. A Case of Oculomotor Nerve Palsy caused by Neurovascular Compression by the Fetal Posterior Communicating Artery with a Review of Literature. *Neurol India*. 2019; 67(5): 1390-1392. PMID: 31744989.
- Zhang J, Wei ZJ, Wang H, Yu YB, Sun HT. Microvascular decompression for a patient with oculomotor palsy caused by posterior cerebral artery compression: A case report and literature review. *World J Clin Cases*. 2022; 10(20): 7138-7146. PMID: 36051142.
- Li A, Tandon A, Tsiouris AJ, Dinkin MJ, Oliveira C. Teaching NeuroImages: Pupil-sparing compression of oculomotor nerve by posterior cerebral artery vessel. *Neurology*. 2020; 94(13): e1450-e1451. PMID: 32152130.
- Chavhan GB, Babyn PS, Jankharia BG, Cheng HL, Shroff MM. Steady-state MR imaging sequences: physics, classification, and clinical applications. *Radiographics*. 2008; 28(4): 1147-1160. PMID: 18635634.
- Blitz AM, Macedo LL, Chonka ZD, et al. High-resolution CISS MR imaging with and without contrast for evaluation of the upper cranial nerves: segmental anatomy and selected pathologic conditions of the cisternal through extraforaminal segments. *Neuroimaging Clin N Am*. 2014; 24(1): 17-34. PMID: 24210310.
- Suzuki K, Muroi A, Kujiraoka Y, Takano S, Matsumura A. Oculomotor palsy treated by microvascular decompression. *Surg Neurol*. 2008; 70(2): 210-212. PMID: 18262620.
- Tocco P, Fenzi F, Cerini R, Monaco S. Adult-onset migraine-related ophthalmoplegia and omolateral fetal-type posterior cerebral artery. *BMJ Case Rep*. 2011; 2011: bcr1020114930. PMID: 22674608.
- Boecher-Schwarz HG, Bruehl K, Kessel G, Guenther M, Pernecky A, Stoeter P. Sensitivity and specificity of MRA in the diagnosis of neurovascular compression in patients with trigeminal neuralgia. *Neuroradiology*. 1998; 40(2): 88-95. PMID: 9541918.
- Stockman AC, Dieltiens M, Janssens H, et al. Ocular Neuromyotonia: Case Reports and Literature Review. *Strabismus*. 2018; 26(3): 133-141. PMID: 29693497.

FIGURES

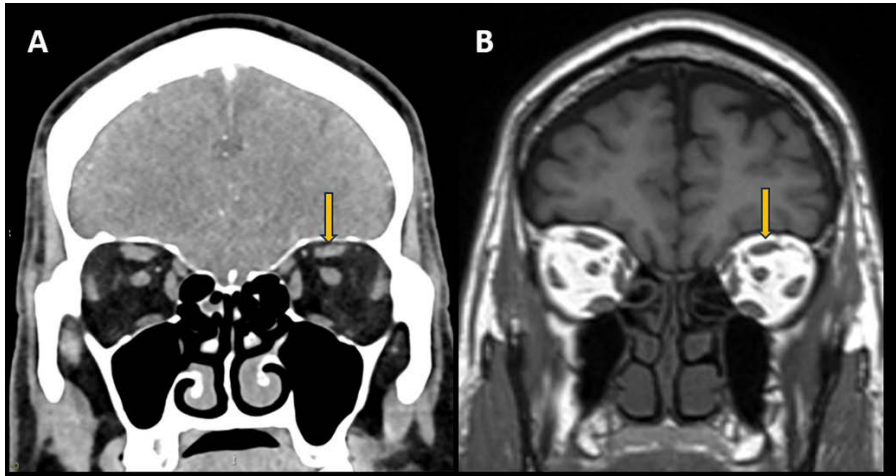


Figure 1: 54-year-old male presenting with oculomotor neurovascular conflict. Orbits CT post-contrast (A) and MR T1-weighted pre contrast image (B) on coronal view. Mild atrophy of the left *levator palpebrae superioris*/superior rectus muscles, due to chronic denervation caused by ipsilateral oculomotor nerve compression.

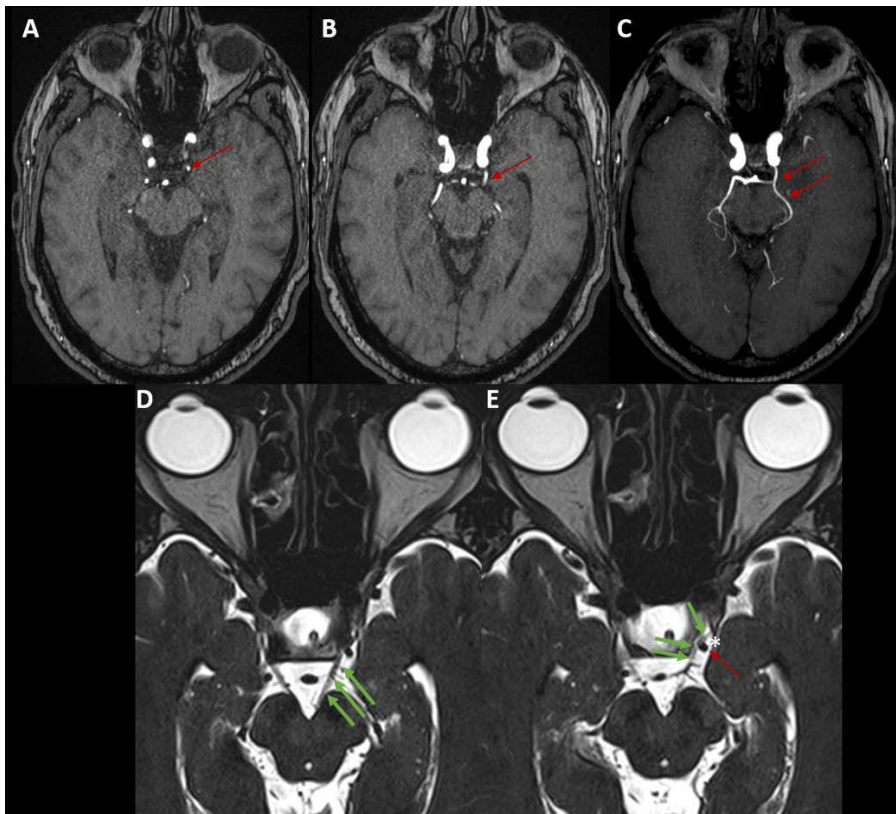


Figure 2: 54-year-old male presenting with oculomotor neurovascular conflict. Brain MRA on axial 3D-TOF sequence (A-C) and orbits MRI on axial 3D-CISS sequence (D and E). Fetal left PCA (red arrows) with prominent P-Com artery, better seen on the Maximum Intensity Projecting (MIP) reconstruction (C). On the bottom, greater conspicuity of the left-sided neurovascular conflict, between the medially displaced distal cisternal oculomotor nerve (green arrows) at the cavernous sinus entrance and the fetal left PCA, along the superolateral aspect of the nerve. The left oculomotor cistern was also slightly distended (*).

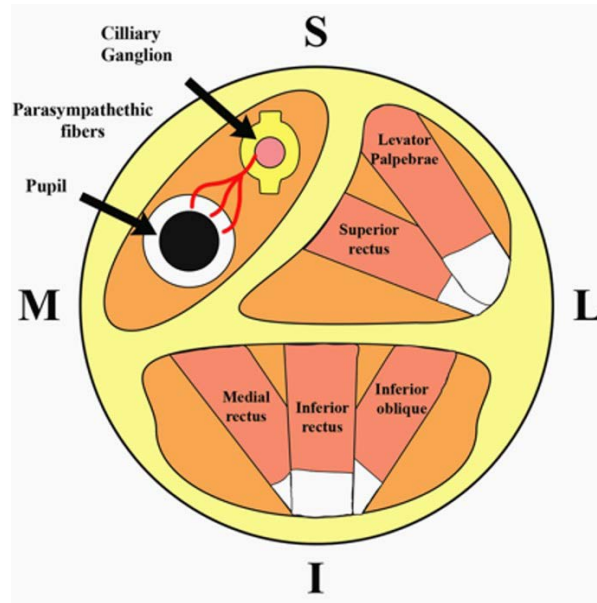


Figure 3: Schematic drawing of the oculomotor nerve on axial section. Somatotopic organization, with emphasis on the parasympathetic fibers in the superomedial quadrant. The others are responsible for innervating the extraocular muscles, as detailed (S: superior / I: inferior / M: medial / Lateral: lateral). *Modified from Li A et al. [4]*

KEYWORDS

Magnetic Resonance Imaging; Magnetic Resonance Angiography; Neurovascular Conflict; Oculomotor Nerve

ABBREVIATIONS

3D = Three-Dimensional
CIDP = Chronic Inflammatory Demyelinating Polyneuropathy
CISS = Constructive Interference In Steady State
FIESTA = Fast Imaging Employing Steady-State Acquisition
HIV = Human Immunodeficiency Virus
ICA = Internal Carotid Artery
MR = Magnetic Resonance
MRA = Magnetic Resonance Angiography
MRI = Magnetic Resonance Imaging
MVD = Microvascular Decompression
ONM = Oculomotor Neuromyotonia
PCA = Posterior Cerebral Artery
Pcom = Prominent Posterior Communicating Artery
SCA = Superior Cerebellar Artery

Online access

This publication is online available at:
www.radiologycases.com/index.php/radiologycases/article/view/5404

Peer discussion

Discuss this manuscript in our protected discussion forum at:
www.radiolopolis.com/forums/JRCR

Interactivity

This publication is available as an interactive article with scroll, window/level, magnify and more features.
Available online at www.RadiologyCases.com

Published by EduRad



www.EduRad.org