


# Trigeminal Neuralgia in the Context of an Undetectable Meckel's Cave: Case Report and MRI Findings

Jacob Schroeder<sup>1</sup>, Jack Kademian<sup>2</sup>, Leonardo Freitas<sup>2</sup>, Nitesh Shekhrajka<sup>2\*</sup>

<sup>1</sup>Roy J. and Lucille A. Carver College of Medicine, Iowa City, USA

<sup>2</sup>Department of Radiology, University of Iowa Hospitals and Clinics, Iowa City, USA

\*Correspondence: Nitesh Shekhrajka, University of Iowa Hospitals and Clinics, 200 Hawkins Dr, Iowa City, IA 52242, USA

 nitesh-shekhrajka@uiowa.edu

Radiology Case. 2024 June; 18(6):43-48 :: DOI: 10.3941/jrcr.5384

## ABSTRACT

Trigeminal neuralgia is a painful mononeuropathy most commonly caused by neurovascular conflict or structural lesion which can frequently be identified on magnetic resonance imaging of the brain. In this case report we describe the presentation and imaging findings of a 29-year-old woman with right-sided trigeminal neuralgia with ipsilateral absence or undetectable Meckel's cave without any other identifiable cause of symptoms on her magnetic resonance imaging.

## CASE REPORT

### INTRODUCTION

Trigeminal neuralgia (TN) is a disorder in which an individual experiences short recurrent episodes of unilateral shocking pain in the sensory distribution of the trigeminal nerve. The pains are frequently triggered by light stimuli or temperature changes [1].

### CASE REPORT

A 29-year-old female without any previous significant medical history was referred to our neurology clinic with an 8-month history of brief, intense, and recurrent daily pain on the right side of her face. She describes the sensation as an "electric shock" whenever she tried to open her mouth, drinks anything that is hot or cold, or brushes her teeth. Her dental workup was negative. The neurological exam was significant for decreased sensation in the V1 and V2 distribution of the right trigeminal nerve with some asymmetric fullness on the right lower 2/3 of her face. She underwent hypercoagulability work up to rule out cerebral venous sinus thrombosis or other causes of increased intracranial pressure which was negative. She received a magnetic resonance imaging (MRI) scan of her brain which found no neurovascular conflict or compressive lesion involving the right trigeminal nerve. However, the right Meckel's cave was undetectable on MRI and there was severe atrophy of the right cisternal trigeminal nerve MRI (Figures 1-4). The diagnosis of trigeminal neuralgia (TN) secondary to severe atrophy of the right cisternal trigeminal nerve and undetectable Meckel's cave was made based on the patient's clinical presentation and MRI findings. Her pain has been refractory to medical treatment with carbamazepine 150 BID, gabapentin 300 mg QID, lamotrigine 100 mg BID, and Botox injections. At her last appointment with the neurology clinic, she was started on indomethacin 50

mg TID. Since that appointment, she has undergone gamma knife stereotactic radiosurgery with a dose of 80 Gy to her right trigeminal nerve without any complications, and she has yet to be seen for follow up.

### DISCUSSION

#### Etiology & demographics

It is estimated that around 80 to 90% of cases of TN are caused by neurovascular conflict (compression of the trigeminal nerve root by a vein or artery), classically the superior cerebellar artery [1,2]. Structural lesions of the brainstem such as meningioma, squamous cell carcinoma, lymphoma, and schwannoma can also present with TN if in contact with the trigeminal nerve during its course [3]. One of the most infrequently reported causes of TN is absent or undetectable Meckel's cave with 13 other cases reported all of which have been women with an average age of presentation of 38 years [4-9]. Trigeminal nerve atrophy is reported in 9 of the 13 cases of undetectable Meckel's cave [4-9]. TN is a rare condition that has a prevalence of <0.1%, becomes more common with age, and tends to affect females more frequently than males [10,11].

#### Clinical & imaging findings

TN is an entity that severely impacts the quality of life of those affected. It is generally diagnosed clinically through the identification of recurrent painful episodes in the trigeminal nerve distribution classically with very light stimuli bringing on symptoms [1]. Our patient presented with typical TN symptomology and triggers. MRI of the brain is valuable in detecting if there is compression of the trigeminal nerve by an adjacent vessel or structural lesion with reported sensitivity of 97% and specificity of 50% [7].

In our patient there were no findings of vascular conflict or compressive structural lesion, however there was undetectable Meckel's cave on the ipsilateral side of the TN symptoms which has previously been associated with TN in the literature [5]. The pathophysiology behind the absent or undetectable Meckel's cave is not clearly understood. There are two theories that propose an explanation, the first being the congenital failure of the CSF-containing subarachnoid space in Meckel's cave to form with TN presenting later with age due to progressive compression of the Gasserian ganglion. The second is that the Meckel's cave collapses in some individuals. The flow of CSF within the Meckel's cave aids in the removal of inflammatory markers such as TNF-alpha surrounding the trigeminal nerve and when lost could contribute to damage to Schwann cells and demyelination [4]. Collapse of the Meckel cave can occur in spontaneous intracranial hypotension when there's a decrease in cerebrospinal fluid (CSF) volume. Facial pain and dysesthesia often accompany in these cases suggesting that the diminished CSF in the Meckel cave might lead to increased sensitivity of the trigeminal nerve, similar to the proposed second theory [5].

Meckel's cave is a CSF filled space in the posteromedial section of the middle cranial fossa that is a passage for the trigeminal nerve located between the prepontine cistern and cavernous sinus it contains the Gasserian ganglion and the proximal rootlets of the trigeminal nerve. It is an important area to evaluate for perineural spread of head and neck neoplasms and in the evaluation of TN [12].

### Treatment & prognosis

The treatment plan for TN depends on the etiology. First line medical therapy for pain associated with TN is carbamazepine or oxcarbazepine with gabapentin and lamotrigine occasionally used as alternatives **or adjuncts** [7]. Surgical microvascular decompression is sometimes done to remove or separate various vascular structures from the trigeminal nerve [13]. Gamma knife radiosurgery is also occasionally used to target the trigeminal root with focused radiation to cause axonal degeneration and necrosis of the **trigeminal nerve** [14]. In our patient's case she had symptoms that were refractory to medical management which was also the case in 8 of the 13 reported cases [4-9]. Our patient underwent gamma knife stereotactic radiosurgery with a dose of 80 Gy. In prior reports patients with TN attributed to undetectable Meckel's cave have had positive responses following gamma knife surgery and balloon decompression [5,7].

### Authors' contributions

1. JS: chart review, writing, editing, figures
2. JK: writing, editing, figures
3. LF: writing, editing, figures
4. NS: writing, editing, figures

**Ethical statement:** we confirm that this report is consistent with ethical guidelines.

**Consent:** This retrospective case report doesn't require approval from the institutional review board.

### TEACHING POINT

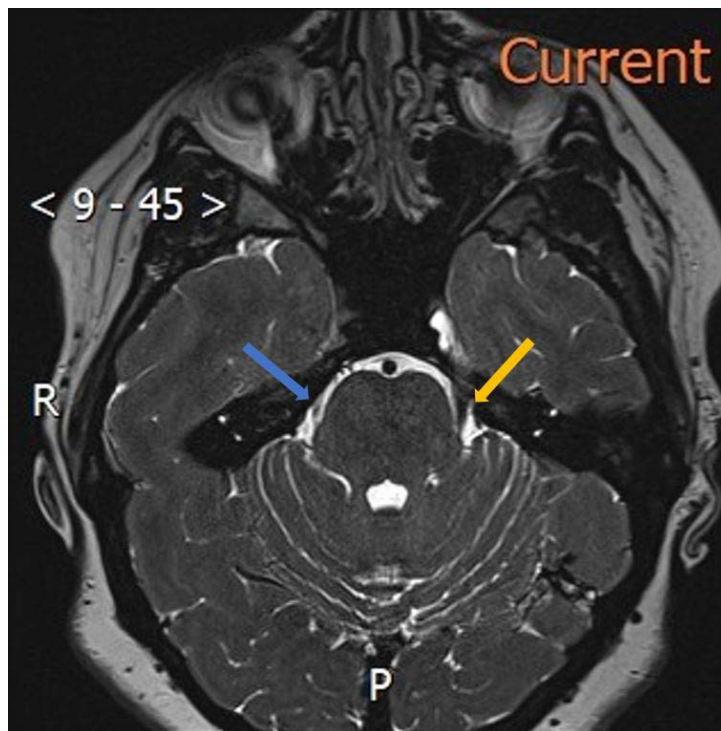
Trigeminal neuralgia secondary to undetectable Meckel's cave is a rare entity, which may frequently be refractory to medical management. There is a lack of literature on this condition and further investigation is needed to determine how to best aid these patients.

### REFERENCES

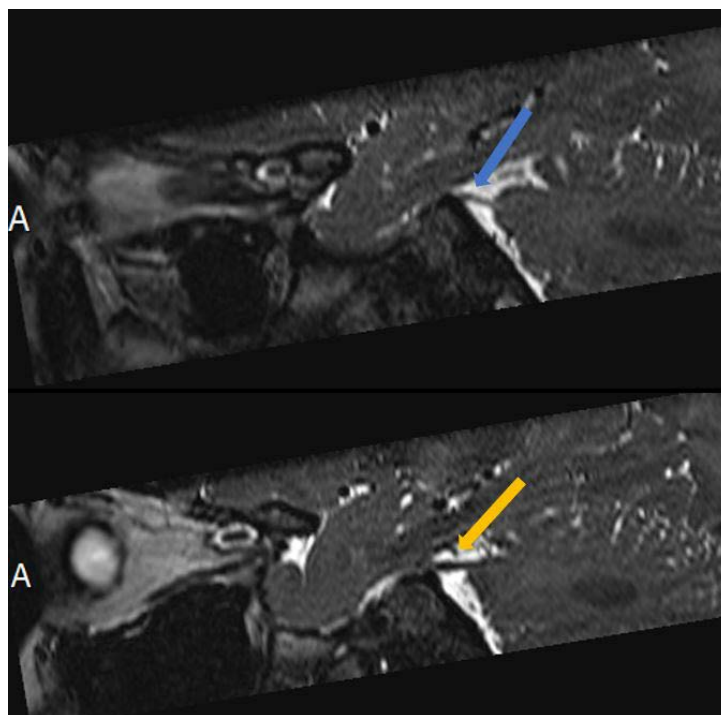
1. Headache Classification Committee of the International Headache Society (IHS) The International Classification of Headache Disorders, 3rd edition. *Cephalalgia*. 2018; 38(1):1-211. PMID: 29368949.
2. Hamlyn PJ. Neurovascular relationships in the posterior cranial fossa, with special reference to trigeminal neuralgia. 2. Neurovascular compression of the trigeminal nerve in cadaveric controls and patients with trigeminal neuralgia: quantification and influence of method. *Clin Anat*. 1997; 10(6): 380-388. PMID: 9358968.
3. Ghislain B, Rabinstein AA, Braksick SA. Etiologies and Utility of Diagnostic Tests in Trigeminal Neuropathy. *Mayo Clin Proc*. 2022; 97(7): 1318-1325. PMID: 35787858.
4. Al-Smair A, Mahmoud MM, Haj-Ahmad LM, Younes S, Saadeh A, Kakish E. Absent Meckel's cave as a possible cause of trigeminal neuralgia: A case report. *Radiol Case Rep*. 2023; 18(4): 1482-1484. PMID: 36747907.
5. Jain A, Muneer MS, Okromelidze L, et al. Absence of Meckel Cave: A Rare Cause of Trigeminal Neuralgia. *AJNR Am J Neuroradiol*. 2021; 42(9): 1610-1614. PMID: 34244131.
6. AlHatmi A, Al-Qassabi A, Raniga SB, Al Ajmi E. Absence of Meckel's Cave with Trigeminal Neuralgia: A Case Report. *Indian J Radiol Imaging*. 2022; 33(1):124-128. PMID: 36855729.
7. Cleary DR, Handwerker J, Ansari H, Ben-Haim S. Three Cases of Trigeminal Neuralgia with Radiographic Absence of Meckel's Cave. *Stereotact Funct Neurosurg*. 2019; 97(4): 249-254. PMID: 31661697.
8. Sundararajan S, Loevner LA, Mohan S. Mandibular Myalgia and Miniscule Meckel's Caves. *ORL J Otorhinolaryngol Relat Spec*. 2018; 80(2): 103-107. PMID: 29996129.
9. Shadani K, Kumar A, Rehan B, Banhwar IA. Absent Meckel's cave in MRI, in a clinically diagnosed case of trigeminal neuralgia. *A very rare case report*. 2020; 30(04): 293-295. PMID: 36747907.
10. MacDonald BK, Cockerell OC, Sander JW, Shorvon SD. The incidence and lifetime prevalence of neurological disorders in a prospective community-based study in the UK. *Brain*. 2000; 123 ( Pt 4): 665-676. PMID: 10733998.

11. Maarbjerg S, Gozalov A, Olesen J, Bendtsen L. Trigeminal neuralgia--a prospective systematic study of clinical characteristics in 158 patients. *Headache*. 2014; 54(10): 1574-1582. PMID: 25231219.
12. Malhotra A, Tu L, Kalra VB, et al. Neuroimaging of Meckel's cave in normal and disease conditions. *Insights Imaging*. 2018; 9(4): 499-510. PMID: 29671218.
13. Jannetta PJ. Microsurgical management of trigeminal neuralgia. *Arch Neurol*. 1985; 42(8): 800. PMID: 4026617.
14. Nurmikko TJ, Eldridge PR. Trigeminal neuralgia--pathophysiology, diagnosis and current treatment. *Br J Anaesth*. 2001; 87(1): 117-132. PMID: 11460800.

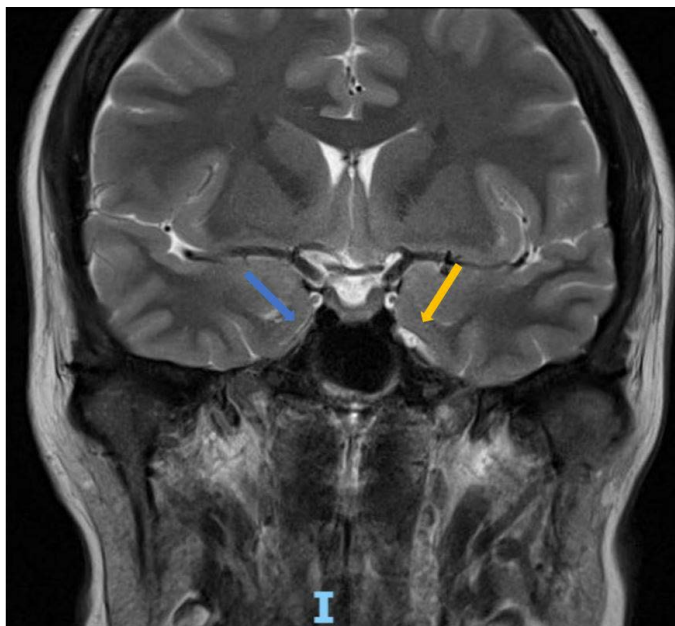
FIGURES



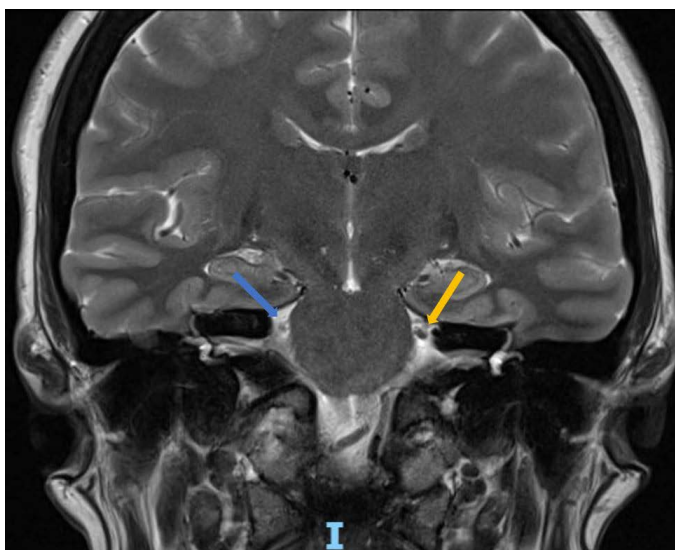
**Figure 1:** FINDINGS: Axial 3D SPACE sequence through pons demonstrates non visualization the right Meckel's Cave (blue arrow) and a normal left Meckel's cave (yellow arrow).



**Figure 2:** FINDINGS: Sagittal T2 SPACE MRI of the brain demonstrates atrophy of right cisternal trigeminal nerve (blue arrow) and a normal left trigeminal nerve (yellow arrow).



**Figure 3:** FINDINGS: Coronal T2 MRI of the brain demonstrates non-visualization of the right Meckel's Cave (blue arrow) and a normal left Meckel's cave (yellow arrow).



**Figure 4:** FINDINGS: Coronal T2 MRI of the brain demonstrates atrophy of the right cisternal trigeminal nerve (blue arrow) and a normal left trigeminal nerve (yellow arrow).

**SUMMARY TABLE**

Etiology	• Unknown, possibility congenital or acquired
Incidence	• 13 reported cases
Gender ratio	• All cases have been women
Age predilection	• Average age of 38
Risk factors	• Unknown
Treatment	• Medical pain management, microvascular surgery, gamma knife
Prognosis	• Waxing and waning pain until definitive treatment
Findings on imaging	• Undetectable Meckel's cave on MRI with atrophy of the trigeminal nerve on the ipsilateral side of TN symptoms

**KEYWORDS**

Trigeminal neuralgia; MRI; Meckel's Cave; Neurovascular conflict; Radiosurgery

**Online access**

This publication is online available at:  
[www.radiologycases.com/index.php/radiologycases/article/view/5384](http://www.radiologycases.com/index.php/radiologycases/article/view/5384)

**Peer discussion**

Discuss this manuscript in our protected discussion forum at:  
[www.radiolopolis.com/forums/JRCR](http://www.radiolopolis.com/forums/JRCR)

**Interactivity**

This publication is available as an interactive article with scroll, window/level, magnify and more features.  
Available online at [www.RadiologyCases.com](http://www.RadiologyCases.com)

Published by EduRad



[www.EduRad.org](http://www.EduRad.org)