

Retained Barium but not Gold Caused Delayed Appendicitis: A Case Report

Guo-Bao Wang, Ph.D^{2#}, Pengdu Cai, MBBS^{1#}, Junxi Xue, M.D¹, Priya Pahilajani, MBBS¹, Geng Yang, M.D¹, Keying Song, M.D, Ph.D^{1*}

¹Shanghai Yosemite Clinic & Hospital, Shanghai, China

²Tongji Hospital, Tongji University School of Medicine, Shanghai, China

[#]Equal Contribution

*Correspondence: Keying Song, M.D, Ph.D, General Surgeon, Founder of Shanghai Yosemite Clinic & Hospital, 118 Fumin Rd, Shanghai, 200040, China, Tel: 86-13661676812,

✉ song.keying@yosemiteclinic.com

Radiology Case. 2024 June; 18(6):28-33 :: DOI: 10.3941/jrcr.5374

ABSTRACT

Background: Delayed appendicitis caused by “metallic” fecaliths is clinically rare, with a few reported cases. This case is from an Asian patient who consumed edible gold-leaf food and also had a history of yearly upper gastrointestinal barium meal fluoroscopy investigation. In order to identify the content in the fecaliths, samples were sent for Energy Dispersive X-ray Spectroscopy (EDX) for analysis.

Case presentation: A 61-year-old, Chinese female presented with suspected appendicitis and was admitted for treatment. CT revealed four 5mm metal density objects (CT value 2000-3000 Hu) within the cavity. The surgery proceeded smoothly. After surgery, the specimen was cut open longitudinally and 2-soft granular fecaliths stuck in the lumen were seen. Immediate postoperative abdominal X-ray showed the other 2 high density nodules which had fallen into the ascending colon. The abdominal X-ray was repeated in the 1-week postoperative follow-up, which revealed no abnormal findings, indicating the remaining 2 foreign bodies had been passed out through normal defecation.

Conclusion: Results of the EDX indicated the primary component to be barium oxide (BaO 54.518%), followed by silicon (SiO₂ 25.064%), calcium (CaO 10.583%), and sulfur (SO₃ 6.282%), with no presence of gold elements (Au 0.000%). The results confirmed that the fecaliths weren't gold but barium. Barium appendicitis should be paid attention to in clinical practice.

CASE REPORT

CASE REPORT

A case of acute appendicitis was seen in a 61-year-old Chinese female patient who presented with typical migrating right lower abdominal pain for 1.5 days, with aggravating pain for 4 hours upon admission. Clinical presentation comprised of fixed, persistent right lower quadrant pain rated 7/10 on the pain scale, no radiating pain, but there was nausea, vomiting, and fever. Physical examination revealed a fever of 37.9°C, a flat abdomen with slight percussion tenderness on McBurney's point, indicating a localized peritonitis. There was muscle tension in the right lower abdomen. No masses were palpated, Murphy's sign was negative. Urgent examination of the complete blood count revealed a white blood cell count of $14.11 \times 10^9/L$, and a neutrophil percentage of 89.1%. The biochemical parameters and liver and kidney function tests showed no significant abnormalities.

An emergency abdominal CT scan revealed a thickened appendix with a diameter of approximately 10 mm, slight wall thickening, and the presence of four 5 mm metal density objects (CT value 2000-3000 Hu) within the cavity (Figures 1,2A). Small patches of blurred objects were noted in the surrounding fat spaces and multiple small scattered lymph nodes at the root of the mesentery. The thickening of the appendix wall and four metal density objects within the cavity, seen on the CT imaging, indicated appendicitis.

Such high density of “four metal objects” description in the CT report immediately raised the team's attention. Further inquiry into the medical history revealed that the patient had normal dietary habits recently and no ingestion of metallic objects. But when deliberately asked about possible past “metallic objects intake history”, she brought up a history of consuming edible gold-leaf ice cream named Kinkaku Soft Ice

Cream in Kyoto, Japan 6 months ago. This type of ice cream has been attracting travelers globally and is famous world-wide. In addition to this, the team also retrieved her past history of having undergone an upper gastrointestinal barium meal X-ray three and a half months ago in Tokyo, Japan.

The patient was promptly admitted with the diagnosis of acute appendicitis, along with four possible ‘metallic’ fecaliths obstructing the appendix. Laparoscopic appendectomy was performed under general anesthesia. Intra-operative finding confirmed the appendicitis diagnosis. The appendix was enlarged and inflamed with surface congestion and pus exudate in the surrounding area. The surgery proceeded smoothly, first the appendiceal stump was clamped, then an endoloop closure was done.

After surgery, the specimen was immediately cut open longitudinally; two granular soft fecaliths stuck in the lumen were suspicious of the “metallic objects” seen in the CT image. No extra hard or metallic foreign bodies were found inside the appendix (Figure 3). Immediate postoperative abdominal X-ray displayed the other 2 high-density nodules which had already fallen into the ascending colon region (Figure 2B). Patient had a speedy recovery, passed flatus 5 hours after surgery and got discharged the next day. During the regular postoperative 1-week outpatient follow-up, a repeat abdominal X-ray was done, which revealed no abnormal findings. This indicated that the remaining 2 metallic foreign bodies had been passed out through normal defecation. (Figure 2C).

To further analyze the contents of fecaliths, the samples were sent to the SHIMADZU China lab center, using Energy Dispersive X-Ray Spectroscopy (EDX), for qualitative and semi-quantitative analysis. Spectroscopy results indicated the primary component to be barium oxide (BaO 54.518%), followed by silicon (SiO₂ 25.064%), calcium (CaO 10.583%), and sulfur (SO₃ 6.282%), with no presence of gold elements (Au 0.000%) (Table 1, Figure 4).

DISCUSSION

Despite of it being an appendicitis case, which is quite common, this case sparked curiosity in the whole surgical team and the patient herself. “Did the gold-leaf ice cream I ate cause an acute appendicitis after so many months? It is a gold poop?”, were some of the questions the patient had for the team. The patient resides in China and has been traveling to Japan often. Gold has been demonstrated as one of the most stable and dense metals and considered safe to be added into food. The question of “Could edible gold trigger a delayed appendicitis?” motivated the surgical team to analyze further.

Patient goes to Japan for regular yearly health checkups. Upper gastrointestinal barium meal fluoroscopy is a routine exam included in the health checkups in Japan. This procedure is widely utilized in clinical practice to screen for diseases in

the esophagus, stomach, and duodenum. In her yearly checkup report, upper gastrointestinal barium meal fluoroscopy was done but presented to be completely normal. Barium has the nature of blocking X-rays, and presents to be metal-like under X-ray. A case report reports of barium leading to appendicitis however, the barium fecaliths mentioned are whiteish in color.^[1] In the case of this 61-year-old Chinese female, fecaliths were regular yellowish. The question of what exactly is in these fecaliths arises, is it gold or barium?

It’s the first case for SHIMADZU China lab center to analyze fecalith contents, EDX was used to analyze the fecalith contents. EDX, offers unique advantages in sample element analysis and material characterization, allows for a rapid and accurate determination of sample components. EDX works by analyzing the characteristic X-ray wavelengths and intensities emitted by the sample, enabling the identification of elements present in the sample based on the distinct X-ray wavelengths associated with each element. The elemental content within the sample can be determined by comparing the intensities of different elemental spectral lines^[2]. With this method, it was precisely concluded that it was barium, not gold which caused delayed appendicitis in the patient.

After 3 and half months of the patient taking barium meal X-ray, the onset of appendicitis symptoms started. Generally, barium meal would be expelled within days of intake, but in this case, the residual barium accumulated and constituted majority of the fecalith contents deposited in the appendix. This led to the obstruction of the appendiceal lumen, ultimately triggering the occurrence of acute appendicitis.

This presentation is clinically rare, with a few reported cases [3-7], though as early as the 1950s and 1960s, physicians had already observed and introduced the concept of Barium appendicitis in clinical settings [8,9]. A review clinical experience with barium appendicitis at a single institution showed that measurement of the CT scan radiodensity of material in the appendix may differentiate barium appendicitis from routine appendicitis^[10]. Moreover, the distribution among patients demonstrates considerable variability, with the interval between barium meal examination and onset ranging from a few days to six months. Therefore, the extended interval between the barium meal radiography and the onset of symptoms complicates the definitive diagnosis of the causative factor [1]. The experience gained from this case emphasizes that CT scans reveal high-density entities, surpassing even the density of metal, a barium granule aggregation, post barium meal ingestion, culminating in the formation of fecaliths were seen on a CT scan.

CT value reflects the density of human tissues, typically expressed in Hounsfield units (Hu). The CT value of air approximates around -1000Hu, while bone measures about +1000Hu; metals generally fall within the range of 2000-

3000Hu. In this instance, the detected granules exhibiting a maximum CT value of 3069Hu surpasses CT values of metal clasps on women's bra that accidentally get captured and also the CT value of her bone in the same background (Figurer 2A). Generally, fecaliths consist of undigested food residues and items such as husk, wood chips, sand, fruit seeds, parasites and other indigestible or low digestible fibers. However, this barium-containing fecalith reporting was a rare one.

In surgery, generally, the appendiceal stump is clamped before ligation, which would expel the fecalith contents. The translocation of fecaliths from the appendix into the intestinal lumen could be due to this.

The analysis of fecalith by EDX methods confirmed that there was no gold. This resolved the patient's concern about consuming gold in her ice cream and also the team's suspect of the fecaliths containing gold. Results from the Energy Dispersive X-ray Spectroscopy method supported that the fecaliths consisted mainly of barium and appendicitis caused by barium should be paid attention to in clinical practice.

AUTHORS STATEMENT

The work described in this manuscript is original and has not been submitted to other journals. All authors have read and approved the submitted manuscript, the manuscript has not been submitted elsewhere nor published elsewhere in whole or in part. All authors have contributed to this study and approved this document and its submission to your journal.

Sources of Funding

This work was supported by the National Natural Science Foundation of China (82202803 [Guo-Bao Wang]).

Disclosures

None. No figures have been previously published in this manuscript and no potential conflicts are reported.

REFERENCES

- [1] Saigusa S, Ohi M, Oki S, et al. Delayed Awareness of the History of Barium Examination: Perforated Barium Appendicitis. *Case Rep Gastrointest Med.* 2017; 2017: 6316175. PMID: 28487783.
- [2] Wyroba E, Suski S, Miller K, Bartosiewicz R. Biomedical and agricultural applications of energy dispersive X-ray spectroscopy in electron microscopy. *Cell Mol Biol Lett.* 2015; 20(3): 488-509. PMID: 26208393.
- [3] Harada T, Watari T. A Short Report on Single-Center Survey in Diagnosing of Barium Acute Appendicitis. *J Epidemiol.* 2024; PMID: 38281746.
- [4] Omura D, Yunoki N, Otsuka Y, et al. Barium appendicitis. *Clin Case Rep.* 2021; 9(7): e04583. PMID: 27721929.
- [5] Shen G, Sun K, Fan Z. Barium Appendicitis 6 Weeks After Upper Gastrointestinal Imaging. *Front Pediatr.* 2020; 8: 535. PMID: 32984229.
- [6] Gachabayov M, Latifi R. Barium Appendicitis: An Unusual Complication of Barium Enema. *Am Surg.* 2019. 85(3): e160-e161. PMID: 30947796.
- [7] Fujii T, Toda S, Inoshita N, et al. Appendiceal mucinous neoplasm with myxoglobulosis occurring 3 years after perforated barium appendicitis: a case report. *Surg Case Rep.* 2019. 5(1): 107. PMID: 31267369.
- [8] Gubler JA, Kukral AJ. Barium appendicitis. *J Int Coll Surg.* 1954; 21(31): 379-384. PMID: 13143262.
- [9] Beck WC, Winter FS. Acute Appendicitis and Retained Barium. *Guthrie Clin Bull.* 1964; 33: 103-107. PMID: 6974465.
- [10] Katagiri H, Lefor AK, Kubota T, Mizokami K. Barium appendicitis: A single institution review in Japan. *World J Gastrointest Surg.* 2016; 8(9): 651-655. PMID: 27721929.

FIGURES

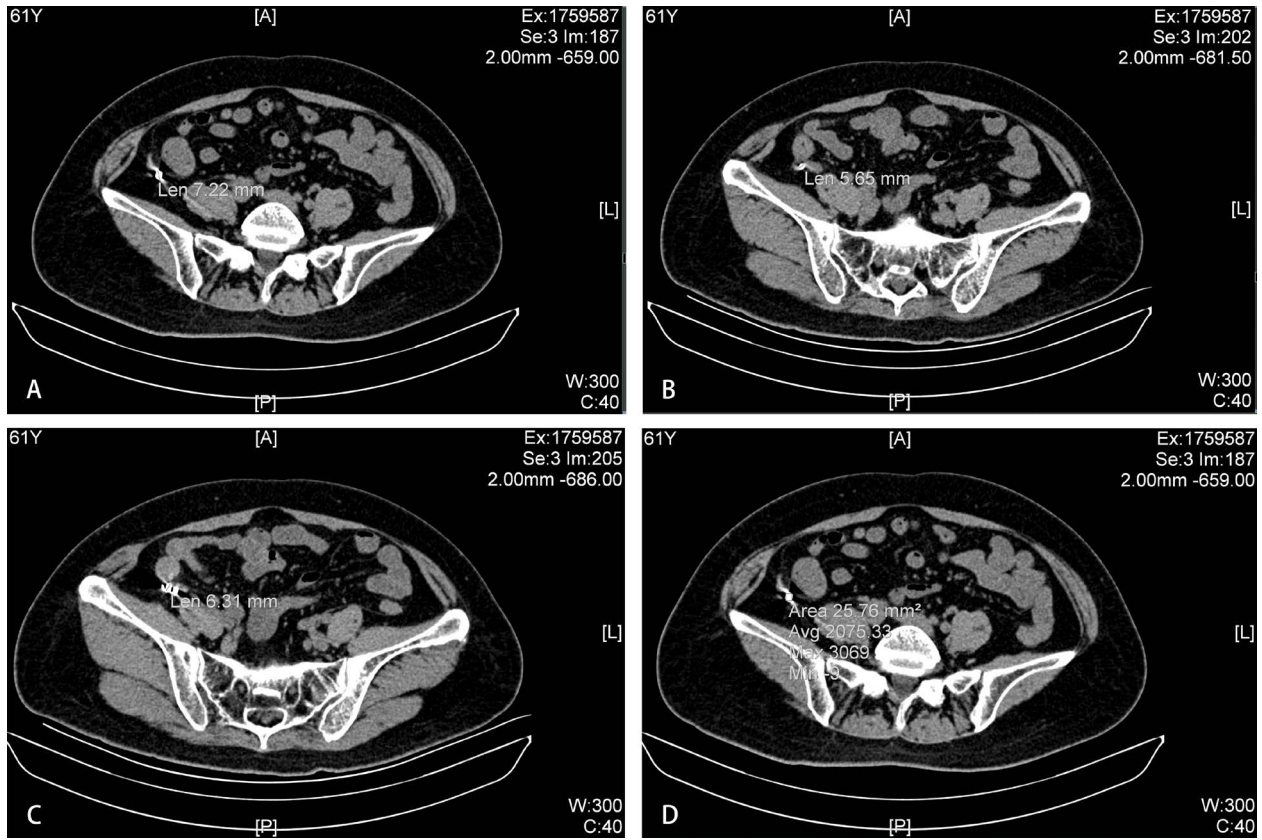


Figure 1: The preoperative CT scan revealed the presence of four metal-density objects within the appendix cavity of approximately (A 7.22mm, B 5.65mm, C 6.31mm and D 5.00mm in diameter with CT values between 2000-3000 Hu).

Journal of Radiology Case Reports

www.RadiologyCases.com

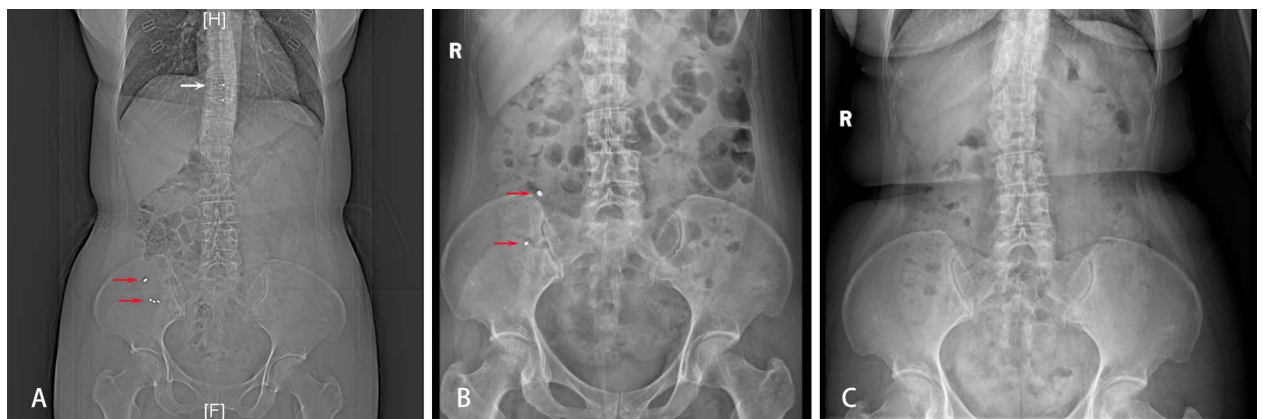


Figure 2: The movement of four high-density objects in the patient’s abdominal X-rays, captured preoperatively (A), immediately after the surgery (B), and one-week postoperative follow-up (C) respectively.

A: Before the surgery, four metal-density objects were detected in the appendix cavity (Red arrow). And the metal clasps on her bra which accidentally got captured in the X-ray (White arrow). B: Postoperatively, an abdominal plain film examination revealed the presence of two nodular high-density objects (Red arrow) that had entered the colonic lumen in the ascending colon region. C: During the outpatient follow-up one week later, a repeat abdominal X-ray revealed no abnormal radiographic findings, indicating the spontaneous passage of the fecaliths.

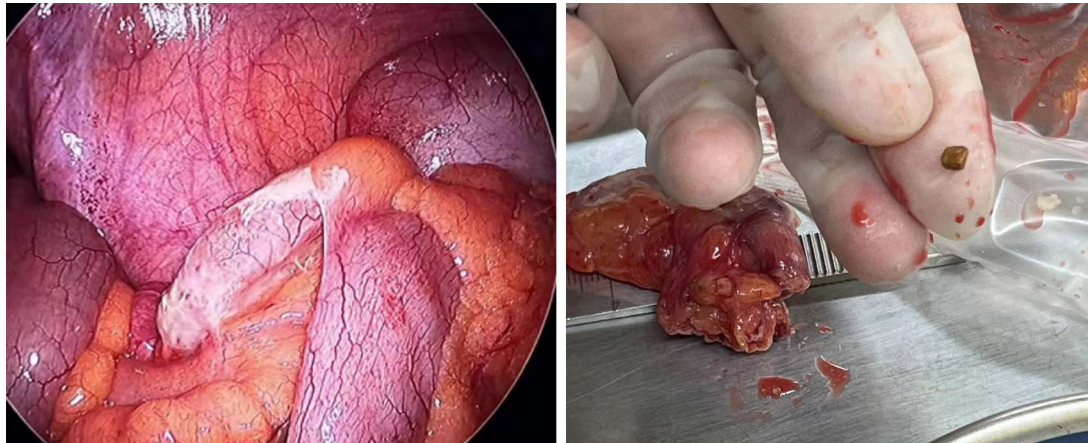


Figure 3: During the surgery, an emergency laparoscopic appendectomy was performed. The appendix was found to be enlarged with a covering of purulent exudate. Two granular objects were retrieved from the appendix cavity and they were yellowish in color. Upon sectioning the appendiceal specimen, it was confirmed that there were no remaining foreign bodies within the appendix.

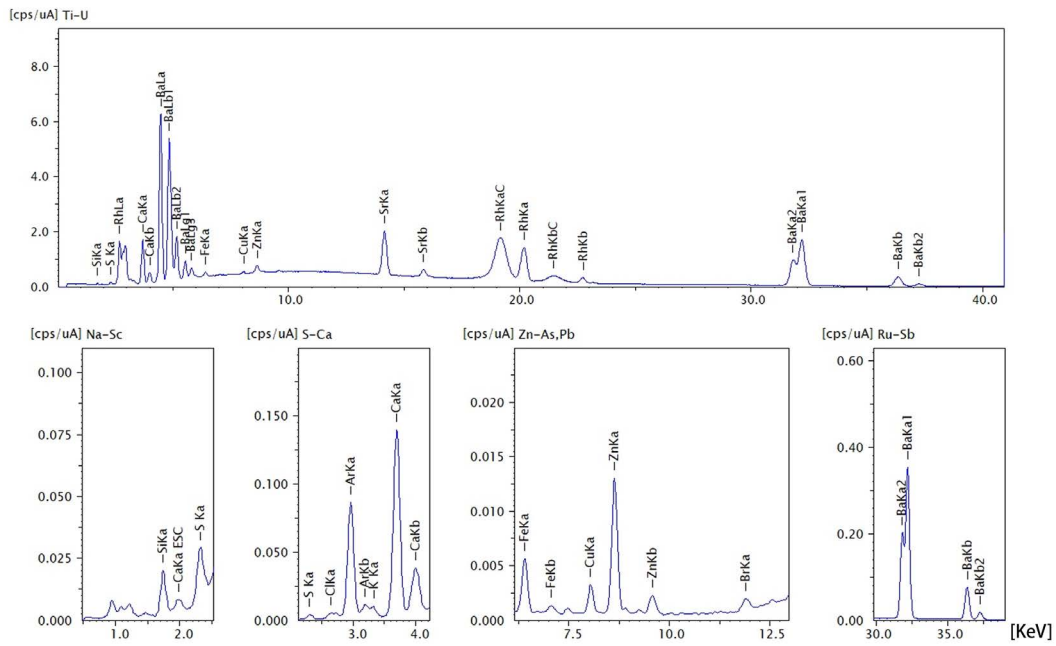


Figure 4: The EDX spectrum. EDX, Energy Dispersive X-Ray Spectroscopy.

Table 1: The results of the EDX analysis

| Oxide compounds | BaO | SiO ₂ | CaO | SO ₃ | SrO | Cl | K ₂ O | Fe ₂ O ₃ | ZnO | CuO | Br |
|----------------------|--------|------------------|--------|-----------------|-------|-------|------------------|--------------------------------|-------|-------|-------|
| Content percentage % | 54.518 | 25.064 | 10.583 | 6.282 | 1.067 | 1.056 | 0.648 | 0.393 | 0.287 | 0.097 | 0.006 |

EDX: Energy Dispersive X-Ray Spectroscopy

KEYWORDS

Delayed appendicitis; Gold; Barium; Energy Dispersive X-ray Spectroscopy (EDX); Computed Tomography (CT)

Online access

This publication is online available at:
www.radiologycases.com/index.php/radiologycases/article/view/5374

Peer discussion

Discuss this manuscript in our protected discussion forum at:
www.radiopolis.com/forums/JRCR

Interactivity

This publication is available as an interactive article with scroll, window/level, magnify and more features.
Available online at www.RadiologyCases.com

Published by EduRad



www.EduRad.org