

Urachal Liposarcoma: A Radiologic Case Report and Literature Review of Malignant Urachal Neoplasms

Muhammad Nurhakim^{1*}, Edmond Lim Yan Shan², Ngo Nye Thane³, Tay Kae Jack⁴, Law Yan Mee²

¹*Yong Loo Lin School of Medicine, National University of Singapore, Singapore, Singapore*

²*Department of Diagnostic Radiology, Singapore General Hospital, Singapore, Singapore*

³*Department of Anatomical Pathology, Singapore General Hospital, Singapore, Singapore*

⁴*Department of Urology, Singapore General Hospital, Singapore, Singapore*

*Correspondence: YMuhammad Nurhakim, NUS Yong Loo Lin School of Medicine, 10 Medical Dr, Singapore, Singapore, 117597

✉ e0663686@u.nus.edu

Radiology Case. 2024 September; 18(9):15-24 :: DOI: 10.3941/jrcr.5364

ABSTRACT

Malignant urachal neoplasms account for less than 1% of all bladder cancers. An aggressive disease with a poor prognosis, adenocarcinoma is the commonest histologic subtype, the majority of which are mucin producing. We present the first known case of urachal dedifferentiated liposarcoma in a 59-year-old male, who presented with a hard and painful suprapubic mass without significant urinary symptoms. We showcase the confounding CT and MRI findings of this exceedingly rare disease at initial presentation and the CT appearance of disease recurrence at surveillance in our patient. We aim to contribute to the sparse literature on urachal liposarcoma, highlighting the diagnostic intricacies of this remote disease entity alongside its potential prognostic implications.

CASE REPORT

CASE REPORT

A 59-year-old Chinese male presented in May 2019 with 1-week history of a hard and painful abdominal mass. He was otherwise asymptomatic, denying any associated urinary, bowel or constitutional symptoms. Physical examination revealed a mildly tender and hard suprapubic mass. Laboratory investigations, which included blood, and urine chemistries as well as serum tumor markers, were unremarkable.

Contrast enhanced CT of the abdomen and pelvis was performed and revealed a heterogeneous and lobulated mass measuring 14.8 x 11.2 x 14.5 cm inseparable from and indenting the anterior and superior urinary bladder dome (Figure 1A,1C), at the expected location of the urachus. The mass was predominantly hypodense containing multiple thick septae and irregular nodular enhancement. There was associated mild left hydronephrosis due to compression of the distal left ureter. An indeterminate lesion of fat attenuation was seen contiguous with the mass (Figure 1B), bounded by the left gonadal vessels and psoas muscle, attributed to perivascular tumor infiltration along the gonadal vessels. There was no accompanying ascites, lymphadenopathy, or evidence of distant metastasis in the abdomen and pelvis. Further CT imaging of the thorax as part of staging was negative for metastasis.

MRI pelvis, performed for local staging prior to surgical resection, revealed a multilocular and septated complex predominantly T2-weighted hyperintense suprapubic mass

measuring approximately 15.3 x 10 x 17.3 cm arising from the anterior superior urinary bladder dome distorting the urinary bladder outline (Figure 2B). The extensive septations show areas of restricted diffusion (Figure 2F) and nodular enhancement (Figure 2H). Areas of hyperintensity on precontrast T1-weighted images indicated the presence of mucinous or hemorrhagic products (Figure 2A). The lateral extent of the mass abutted bilateral pelvic side walls and external iliac vessels, with compression of the left distal ureter and resultant hydronephrosis. Contiguous infiltration of fat and abnormal enhancement along the left gonadal vessels in the left iliac fossa was interpreted as perivascular tumor infiltration. Adjacent colon and small bowel loops were displaced with no MRI evidence of tumor infiltration. Radiological diagnosis of urachal mucinous adenocarcinoma was proposed due to the possible presence of mucinous components within the complex cystic mass.

Prior to definitive surgical resection, the patient underwent rigid cystoscopy to evaluate the urinary bladder mucosa. Cystoscopy revealed extrinsic compression of the anterior urinary bladder dome by a large suprapubic mass, concordant with CT and MRI findings. The urinary bladder mucosa, bilateral ureteric orifices and bladder capacity were normal.

The patient subsequently underwent partial cystectomy with bilateral pelvic lymph node dissection. Intraoperatively, there was a large urachal mass indenting the urinary bladder. The mass was resected en-bloc together with the anterior urinary

bladder and the left ureteric orifice was transected. The urinary bladder was repaired, and the distal left ureter was reimplanted at the bladder dome.

Histopathologic analysis of the resected specimen revealed a solid-cystic lesion that was 16 cm in maximum dimension. The lesion had a predominantly dedifferentiated component which showed diffuse sheets of pleomorphic spindle cells with areas of cystic change and necrosis (Figure 3A). There was also a smaller well-differentiated liposarcoma component composed of variably sized adipocytes with hyperchromatic nuclei (Figure 3B). An extensive panel of immunohistochemical stains was performed, including cytokeratins, GATA3, SMA, S100, CD34, caldesmon, CD117, myoD1, and myogenin, which was negative. Fluorescence in situ hybridization (FISH) for MDM2 was positive, confirming the diagnosis of dedifferentiated liposarcoma.

Post-surgery recovery was uneventful, and the patient was discharged 4 days following major abdominal surgery. The patient was not offered adjuvant systemic therapy in light of negative surgical margins. Regular quarterly CT scan surveillance was performed.

The 1st CT surveillance 4 months post-surgery revealed a normal urinary bladder and complete resection of urachal mass. However, the fatty lesion in the left iliac fossa extending along the left gonadal vessels was persistent. In light of the pathological diagnosis of dedifferentiated liposarcoma, the possibility of residual liposarcoma in the left hemipelvis was raised. As the patient was recovering from major abdominal surgery, the patient and surgical team elected for active surveillance rather than repeat resection.

The patient remained well, and surveillance CT imaging revealed neither distant metastasis nor progression 3 years post-surgery. However, in the 4th year of surveillance, routine CT revealed increased nodular enhancement within the area of fat infiltration in the left iliac fossa, measuring approximately 1.8 cm (Figure 4A,4B). This was concerning for disease progression. The patient subsequently underwent interval laparotomy, adhesiolysis and resection of the left retroperitoneal mass in January 2023. Histopathologic analysis of the resected specimen correlated with radiologic interpretation, revealing a well-differentiated sclerosing liposarcoma (Figure 5A), measuring approximately 7 cm, with a focus of low grade dedifferentiated liposarcoma (Figure 5B), measuring approximately 1.8 cm. The patient had an uneventful recovery and remains well to date.

DISCUSSION

Etiology & Demographics

Malignant urachal neoplasms are rare. Urachal carcinoma accounts for less than 1% of all bladder cancers, with an estimated annual incidence of 1 in 5 million [1]. It has a notable predilection for males [2]. The median age at diagnosis, as reported by a population-based study utilizing the Surveillance,

Epidemiology, and End Results (SEER) database, is 59 years [3]. Cases of urachal carcinoma are predominantly defined by adenocarcinoma histology and mucin production [4]. Nonglandular urachal carcinomas, such as urothelial and squamous cell carcinomas, are documented sporadically, with a reported incidence of 4-27% in case series [5]. The incidence of urachal cancers of nonepithelial origin is even lower, with only 5 cases of urachal leiomyosarcoma and 13 cases of urachal rhabdomyosarcoma reported since 1981 [6] and 1930 [7] respectively. To our knowledge, this case introduces the first known instance of urachal liposarcoma.

The pathogenesis of urachal cancer remains largely enigmatic. Urachal carcinoma is postulated to result from metaplastic and malignant transformation of the transitional epithelium lining the urachus [8]. Another hypothesis specific to adenocarcinomas is the aberrant presence of embryologic cloacal remnants or enteric rests [9]. Genetic predisposition and environmental factors are not known risk factors for the development of urachal carcinoma [10]. Drawing parallels with urachal leiomyosarcoma [11] and rhabdomyosarcoma [7], mesenchymal cells within the urachus may be the origin of urachal liposarcoma. In light of sparse literature, the risk factors for urachal cancers of nonepithelial origin are unknown.

Clinical & Imaging Findings

Being extraperitoneal, malignant urachal neoplasms proliferate asymptotically within the space of Retzius and are often only diagnosed at advanced stages of local invasion and metastasis [12]. When patients with urachal carcinoma do present with symptoms, hematuria is most commonly seen (58-82%), followed by abdominal pain and dysuria (12-14%), mucusuria (10%), and nonspecific constitutional symptoms such as nausea, loss of appetite, and weight loss [13]. A retrospective analysis comparing the clinical characteristics of 30 patients with urachal carcinoma to 17 patients with benign urachal neoplasms found that carcinoma produced a higher incidence of hematuria, whereas abdominal pain and urinary symptoms were more significantly associated with benign etiologies [14]. As urachal carcinoma is highly aggressive, a meta-analysis comprising 24 studies analyzing a total of 1,010 cases demonstrated that 136 patients presented with distant metastasis at first presentation [15].

The classical CT finding of urachal adenocarcinoma is a heterogeneous, midline mass anterosuperior to the dome of the bladder, with calcifications and low attenuation components representing mucinous contents [16]. The latter is correlated on MRI by the presence of internal, focal areas of high signal intensity on T2-weighted images [17]. Mucinous tumors are frequently T1-weighted hypointense although high concentration of mucin may result in T1 shortening and hyperintense T1-weighted signal. This imaging presentation complements the diagnosed criteria for urachal carcinoma outlined by Gopalan et al., which are defined by the identification of an anterior wall or bladder dome mass with a bladder wall epicenter, absence of cystitis cystica

and glandularis beyond the anterior wall of the bladder, as well as exclusion of a known primary cancer elsewhere [18]. Besides conventional CT and MRI examinations for diagnostic workup and local staging, 18F-fluorodeoxyglucose positron emission tomography (18F-FDG PET-CT) may be employed for distant staging, identifying metastasis that may be occult on conventional imaging modalities [19].

Raised serum tumor marker levels may also be seen in urachal carcinoma. In a literature review comprising 319 studies for a total of 1984 cases, serum elevations in carcinoembryonic antigen (CEA), CA 125, and CA 19-9 levels were reported in over 50% of patients in some studies [20]. Notably, raised serum CEA and CA 19-9 levels were associated with worse overall survival (OS) and progression-free survival (PFS). These serum biomarkers were not elevated in our patient. Cystoscopy is mandatory for patients with suspected diagnosis of urachal mass as it allows assessment of urothelial abnormalities for biopsy and reliably identifies the location of the mass with respect to the urinary bladder [21].

Reported presenting symptoms of patients with urachal leiomyosarcomas include hematuria, lower urinary tract symptoms (LUTS), as well as suprapubic mass and pain [6]. 2 cases of intraperitoneal hemorrhage secondary to tumor rupture have also been reported [22]. Literature reporting the incidence of distant metastasis at first presentation is lacking. Contrast enhanced CT imaging may demonstrate central areas of low attenuation representing necrosis [23]. MRI can suggest the diagnosis by demonstrating a mass with relatively low signal intensity on T2-weighted images [24], with embedded areas of high signal representing necrosis [6, 23]. In comparison, a retrospective analysis of 8 cases of urachal rhabdomyosarcoma reported that 6 patients had metastatic disease at the time of diagnosis, 5 with peritoneal tumor extension including 1 with vertebral and sacral metastasis, and 1 with isolated distant iliac lymph node involvement [25]. Rhabdomyosarcoma has low signal intensity on T1-weighted images and high signal intensity on T2-weighted images [17].

Despite the mass considerably large size, our patient exhibited no signs of locoregional or distant metastasis at presentation. This unique clinical presentation might suggest that urachal liposarcoma diverges from the typical symptomatology associated with the malignant urachal neoplasms previously discussed. This case also illustrates that urachal liposarcoma possesses distinct imaging characteristics, more closely mirroring the features typically associated with liposarcomas than those of malignant urachal neoplasms.

A histologically diverse group of tumors, liposarcoma may be designated into 3 major categories based on molecular biology and genetic mapping, 1 of which includes atypical lipomatous tumors, well-differentiated liposarcoma, and dedifferentiated liposarcoma [26]. While identification of intratumoral macroscopic fat in a soft tissue tumor suggests the diagnosis, macroscopic fat may be absent in certain subtypes due to

inherent histologic heterogeneity. Well-differentiated subtypes contain a greater number of adipocytes; hence, their radiologic appearance will approach that of fatty tissue. Nonlipomatous soft tissue mass often suggests the dedifferentiated component of liposarcoma [27]. The dedifferentiated component accounted for over 90% of the resected mass in our patient, explaining the predominantly cystic appearance on MRI, devoid of macroscopic fat. This rendered the diagnosis of liposarcoma elusive. The extensive hemorrhage within the mass on histology accounts for the T1-weighted hyperintense areas on MRI. In the surveillance of patients with liposarcoma, it is critical to be attentive to nonlipomatous tumor components as they suggest tumor progression. The development of nonlipomatous soft tissue in our patient at routine surveillance was a cause for concern. Indeed, this area corresponded to dedifferentiated component of sclerosing well-differentiated liposarcoma at repeat resection 4 years after the initial diagnosis.

Treatment & Prognosis

Surgery is the primary treatment for malignant urachal neoplasms. For localized disease, this includes wide local excision of the urachus, umbilicus, and perivesical soft tissue, combined with partial or radical cystectomy and bilateral pelvic lymphadenectomy [28]. A retrospective analysis of 39 patients with urachal carcinoma found that umbilectomy was an important prognostic factor for OS and PFS, with patients failing to undergo umbilectomy having poorer survival rates [29]. In contrast, there is a lack of consensus in the necessity of pelvic lymph node dissection, but its benefits include improved tumor staging and removal of lymph nodes with micrometastases [30]. Radical cystectomy offers no additional survival benefit as compared to partial cystectomy [3]. For urachal carcinoma, chemotherapy may be considered reasonable in the neoadjuvant setting to achieve surgical consolidation with a negative margin resection for unresectable disease, and in the adjuvant setting for patients at high risk of relapse due to positive surgical margins, node positive disease, or peritoneal involvement [31]. A retrospective analysis of 274 patients with metastatic disease found that overall mortality and cancer-specific mortality were lower in patients exposed to chemotherapy [32]. Radiotherapy is rarely employed in the management of urachal carcinoma, suggesting limited efficacy [28]. The role of chemotherapy and radiotherapy in the treatment of urachal leiomyosarcoma and rhabdomyosarcoma is less clear due to the lack of data.

Malignant urachal neoplasms are associated with a devastating prognosis. A cohort analysis of 203 urachal carcinoma patients reported a 5 year OS, cancer-specific survival (CSS), and recurrence-free survival (RFS) of 38%, 35.2%, and 28.4% respectively when lymph node involvement or distant metastasis was present [33]. Another retrospective analysis of 163 patients with urachal carcinoma reported a postoperative recurrence rate of 41.7% and a 1 year, 3 year, and 5 year post recurrence survival rate of 42%, 10%, and 5% respectively [34]. Median survival time after recurrence was only 9.91 months. Similarly, in a retrospective analysis of 8 patients with urachal

rhabdomyosarcoma, 4 patients had disease recurrence in a median time of 2.5 months, including 2 with distant metastasis, and 7 died between 18 and 57 months after diagnosis [25]. Studies investigating the prognosis of urachal leiomyosarcomas are lacking.

On the contrary, despite recurrence of disease 4 years after the initial surgical intervention, the patient's overall clinical trajectory has been notably favorable, showing no evidence of advanced regional or distant metastasis on follow-up imaging. This slower progression marks urachal liposarcoma as potentially less aggressive despite the presence of a significant dedifferentiated component compared to other types of malignant urachal neoplasms, which are typically characterized by rapid advancement and a dismal prognosis. These observations suggest that urachal liposarcoma may exhibit distinct biological characteristics that result in a milder clinical course compared to other urachal malignancies, raising the possibility of devising customized surveillance and management strategies for this rare tumor subtype.

Differential Diagnoses

The differential diagnosis for a urachal mass comprises a variety of benign and malignant entities. Imaging plays a pivotal role in the characterization of the lesion, with a definitive diagnosis often attainable when typical radiologic features are present. Patient demographics and clinical history are also crucial in narrowing down the differential diagnosis. We outline below a few main differentials to consider when evaluating a urachal mass and their distinguishing features on imaging.

Urachal adenocarcinoma

The highest incidence of urachal adenocarcinoma is observed in males in their 5th to 6th decades of life [35]. Ultrasound (US) is often the initial imaging modality, revealing a midline soft tissue mass with complex echogenicity and calcifications [36]. The typical CT appearance of urachal adenocarcinoma is a heterogeneous, midline mass anterosuperior to the dome of the bladder with a prominent extravesical component [17]. Mixed solid and cystic components are often seen due to underlying mucin production [23]. Calcifications occur in 50-70% of cases and are considered nearly diagnostic for urachal adenocarcinoma when present in a midline supravescical mass [37]. MRI can suggest the diagnosis by demonstrating a T2-weighted hyperintense mass [24].

Malignant mesenchymal tumors (e.g. leiomyosarcoma, rhabdomyosarcoma)

Urachal cancers of mesenchymal origin such as leiomyosarcoma and rhabdomyosarcoma occur less commonly than urachal carcinoma and are predominantly seen in children [11,25]. On CT, leiomyosarcoma may demonstrate central areas of nonenhancement following contrast administration, representing necrosis [23]. It is typically T2-weighted hypointense [24], but heterogeneous signal intensity may be seen with embedded areas of high T2 signal representing

necrosis [6, 23]. Rhabdomyosarcoma is typically T1-weighted hypointense and T2-weighted hyperintense on MRI [17].

Benign tumors (e.g. adenoma, cystadenoma)

Benign tumors are exceptionally rare with only a few cases being described in the literature. The commonest benign tumors are adenomas and cystadenomas, followed by fibromas, fibromyomas, fibroadenomas, and hamartomas [36]. No specific imaging findings have been described in case reports, and diagnosis is usually made at histopathologic analysis after resection.

Urachal Cyst

Urachal cysts may be visualized on US and CT as a homogeneous, fluid-filled structure along the theoretical course of the urachus [36]. In the setting of infection, imaging findings may mimic those of urachal carcinoma due to heterogenous attenuation, a thickened and enhancing wall, as well as variable enhancement and inflammatory responses in and around the lesion [38]. However, the diagnosis may be suggested by leukocytosis and an elevated C-reactive protein (CRP), as well as a positive response to antibiotics.

TEACHING POINT

Urachal liposarcoma is an exceptionally rare entity that resembles traditional liposarcomas more than other malignant urachal neoplasms in its imaging characteristics. Despite being a challenging diagnosis, it potentially exhibits a more favorable prognosis compared to malignant urachal adenocarcinoma.

QUESTIONS

1. What is the commonest histological subtype of malignant urachal neoplasms?
 - A) Leiomyosarcoma
 - B) Rhabdomyosarcoma
 - C) Adenocarcinoma (applies)
 - D) Squamous cell carcinoma
 - E) Liposarcoma
2. Which imaging characteristic is typical for urachal carcinoma?
 - A) A well-defined mass with high fat content
 - B) A homogeneous, midline mass without calcifications
 - C) A heterogeneous, midline mass anterosuperior to the bladder dome with calcifications (applies)
 - D) A small, encapsulated mass with minimal enhancement
 - E) A diffuse, infiltrative growth pattern without a clear origin
3. Which of the following is not a common symptom of urachal carcinoma?

- A) Hematuria
 B) Abdominal pain
 C) Dysuria
 D) Mucusuria
 E) Hematochezia (applies)
4. What does the presence of a nonlipomatous soft tissue component on imaging typically suggest in liposarcoma?
- A) Calcification
 B) Well-differentiated liposarcoma
 C) Dedifferentiated liposarcoma (applies)
 D) Mucinous degeneration
 E) Hemorrhage
5. What is the primary treatment approach for localized malignant urachal neoplasms?
- A) Chemotherapy only
 B) Radiotherapy only
 C) Wide local excision combined with partial or radical cystectomy (applies)
 D) Chemotherapy and radiotherapy
 E) Hormonal therapy

Authors' contributions

MN contributed to the writing and editing of the manuscript. ELYS and LYM were involved in the interpretation of the radiologic findings and contributed to the writing and editing of the manuscript. NNT was involved in the interpretation of the histologic findings. TKJ provided the surgical data required.

Acknowledgements

Nil

Disclosures

Nil

Consent

Yes

Human and animal rights

Nil

REFERENCES

- Sheldon CA, Clayman RV, Gonzalez R, Williams RD, Fraley EE. Malignant urachal lesions. *J Urol*. 1984; 131(1): 1-8. PMID: 6361280.
- Johnson DE, Hodge GB, Abdul-Karim FW, Ayala AG. Urachal carcinoma. *Urology*. 1985; 26(3): 218-221. PMID: 4035835.
- Mylonas KS, O Malley P, Ziogas IA, El-Kabab L, Nasioudis D. Malignant urachal neoplasms: A population-based study and systematic review of literature. *Urol Oncol*. 2017; 35(1): 33.e11-33.e19. PMID: 27592530.
- Dhillon J, Liang Y, Kamat AM, et al. Urachal carcinoma: a pathologic and clinical study of 46 cases. *Hum Pathol*. 2015; 46(12): 1808-1814. PMID: 26364859.
- Paner GP, Barkan GA, Mehta V, et al. Urachal carcinomas of the nonglandular type: salient features and considerations in pathologic diagnosis. *Am J Surg Pathol*. 2012; 36(3): 432-442. PMID: 22301493.
- Yan J, Li H, Yan G, et al. Primary urachal leiomyosarcoma: a case report and literature review of clinical, pathological, and medical imaging features. *Front Oncol*. 2023; 13: 1228178. PMID: 37664058.
- Karray A, Sahli S, Rahal Z, Aziza B, Jouini R. Urachal rhabdomyosarcoma: A case report of an extremely rare localization. *Urol Case Rep*. 2022; 43: 102109. PMID: 35600805.
- Tsiouris A, Ahmed HU, Kumar N, Kaisary AV. Urachal tumour: clinical and radiological features of a poorly understood carcinoma. *Ann R Coll Surg Engl*. 2007; 89(6): W17-W18. PMID: 18201467.
- Upadhyay V, Kukkady A. Urachal remnants: an enigma. *Eur J Pediatr Surg*. 2003; 13(6): 372-376. PMID: 14743323.
- Kumar R, Harilal S, Abdelgawad MA, Ghoneim MM, Kumar A, Mathew B. Urachal carcinoma: The journey so far and the road ahead. *Pathol Res Pract*. 2023; 243: 154379. PMID: 36821941.
- Noyes D, Vinson RK. Urachal leiomyosarcoma. *Urology*. 1981; 17(3): 279-280. PMID: 7210383.
- Jiang JY, Kang C, Jackson S, et al. A rare case of urachal mucinous adenocarcinoma detected by 18F-FDG PET/CT and MRI. *Radiol Case Rep*. 2022; 17(4): 1231-1235. PMID: 35198084.
- Claps M, Stellato M, Zattarin E, et al. Current Understanding of Urachal Adenocarcinoma and Management Strategy. *Curr Oncol Rep*. 2020; 22(1): 9. PMID: 31989430.
- Bi X, Wu Z, Han H, Zhou F. Clinical comparison of patients with benign urachal masses versus urachal carcinomas. *Chin J Cancer*. 2017; 36(1): 2. PMID: 28061801.
- Szarvas T, Módos O, Niedworok C, et al. Clinical, prognostic, and therapeutic aspects of urachal carcinoma-A comprehensive review with meta-analysis of 1,010 cases. *Urol Oncol*. 2016; 34(9): 388-398. PMID: 27267737.
- Monteiro V, Cunha TM. Urachal carcinoma: imaging findings. *Acta Radiol Short Rep*. 2012; 1(1): arsr.2011.110018. PMID: 23986824.

17. Wong-You-Cheong JJ, Woodward PJ, Manning MA, Sesterhenn IA. From the Archives of the AFIP: neoplasms of the urinary bladder: radiologic-pathologic correlation. *Radiographics*. 2006; 26(2): 553-580. PMID: 16549617.
18. Gopalan A, Sharp DS, Fine SW, et al. Urachal carcinoma: a clinicopathologic analysis of 24 cases with outcome correlation. *Am J Surg Pathol*. 2009; 33(5): 659-668. PMID: 19252435.
19. Das JP, Vargas HA, Ghafoor S, Goh AC, Ulaner GA. Clinical Utility of 18F-FDG PET/CT for Staging and Treatment Planning in Urachal Adenocarcinoma. *J Nucl Med*. 2021; 62(5): 643-647. PMID: 32948680.
20. Reis H, Krafft U, Niedworok C, et al. Biomarkers in Urachal Cancer and Adenocarcinomas in the Bladder: A Comprehensive Review Supplemented by Own Data. *Dis Markers*. 2018; 2018: 7308168. PMID: 29721106.
21. Shao G, Xu C, Liu J, et al. Clinical, Pathological, and Prognostic Analysis of Urachal Carcinoma. *Urol Int*. 2022; 106(2): 199-208. PMID: 34515250.
22. Tong S, Jia Z. Primary urachal leiomyosarcoma: A rare case report and literature review. *Urol Case Rep*. 2022; 44: 102143. PMID: 35812467.
23. Mouli S, Casalino DD, Nikolaidis P. Imaging features of common and uncommon bladder neoplasms. *Radiol Clin North Am*. 2012; 50(2): 301-316. PMID: 22498444.
24. Mallampati GK, Siegelman ES. MR imaging of the bladder. *Magn Reson Imaging Clin N Am*. 2004; 12(3): 545-555. PMID: 15271370.
25. Cheikhelard A, Irtan S, Orbach D, et al. Urachal rhabdomyosarcoma in childhood: a rare entity with a poor outcome. *J Pediatr Surg*. 2015; 50(8): 1329-1333. PMID: 25913896.
26. O'Regan KN, Jagannathan J, Krajewski K, et al. Imaging of liposarcoma: classification, patterns of tumor recurrence, and response to treatment. *AJR Am J Roentgenol*. 2011; 197(1): W37-W43. PMID: 21700993.
27. Murphey MD, Arcara LK, Fanburg-Smith J. From the archives of the AFIP: imaging of musculoskeletal liposarcoma with radiologic-pathologic correlation. *Radiographics*. 2005; 25(5): 1371-1395. PMID: 16160117.
28. Loizzo D, Pandolfo SD, Crocerossa F, et al. Current Management of Urachal Carcinoma: An Evidence-based Guide for Clinical Practice. *Eur Urol Open Sci*. 2022; 39: 1-6. PMID: 35309098.
29. Jia Z, Chang X, Li X, Wang B, Zhang X. Urachal Carcinoma: Are Lymphadenectomy and Umbilectomy Necessary? *Med Sci Monit*. 2020; 26: e927913. PMID: 32958737.
30. Duan F, Zhai W, Zhang B, Guo S. Urachal carcinoma: Impact of recurrence pattern and lymphadenectomy on long-term outcomes. *Cancer Med*. 2020; 9(12): 4166-4174. PMID: 32329250.
31. Siefker-Radtke A. Urachal adenocarcinoma: a clinician's guide for treatment. *Semin Oncol*. 2012; 39(5): 619-624. PMID: 23040259.
32. Flammia RS, Chierigo F, Würnschimmel C, et al. Survival benefit of chemotherapy in a contemporary cohort of metastatic urachal carcinoma. *Urol Oncol*. 2022; 40(4): 165.e9-165.e15. PMID: 34686429.
33. Yu YD, Ko YH, Kim JW, et al. The Prognosis and Oncological Predictor of Urachal Carcinoma of the Bladder: A Large Scale Multicenter Cohort Study Analyzed 203 Patients With Long Term Follow-Up. *Front Oncol*. 2021; 11: 683190. PMID: 34136407.
34. Ke C, Xu L, Wang M, et al. Treatment options and prognostic risk factors for urachal carcinoma: A multicenter retrospective study. *Urol Oncol*. 2023; 41(1): 50.e1-50.e9. PMID: 36283930.
35. Benjamin DJ, Shrestha A, Fellman D, Cress RD, Kalebasty AR. Association of Sociodemographic Characteristics With Survival Among Patients With Urachal Cancer in California From 1988 to 2019. *JAMA Oncol*. 2022; 8(10): 1505-1507. PMID: 36089818.
36. Parada Villavicencio C, Adam SZ, Nikolaidis P, Yaghmai V, Miller FH. Imaging of the Urachus: Anomalies, Complications, and Mimics. *Radiographics*. 2016; 36(7): 2049-2063. PMID: 27831842.
37. Yu JS, Kim KW, Lee HJ, Lee YJ, Yoon CS, Kim MJ. Urachal remnant diseases: spectrum of CT and US findings. *Radiographics*. 2001; 21(2): 451-461. PMID: 11259707.
38. Marzouki S, Geerts B, Marrannes J. Infected Urachal Cyst Mimicking Urachal Carcinoma: A Rare Cause of Lower Abdominal Tenderness. *J Belg Soc Radiol*. 2023; 107(1): 9. PMID: 36817568.
39. Binh MB, Sastre-Garau X, Guillou L, et al. MDM2 and CDK4 immunostainings are useful adjuncts in diagnosing well-differentiated and dedifferentiated liposarcoma subtypes: a comparative analysis of 559 soft tissue neoplasms with genetic data. *Am J Surg Pathol*. 2005; 29(10): 1340-1347. PMID: 16160477.

FIGURES

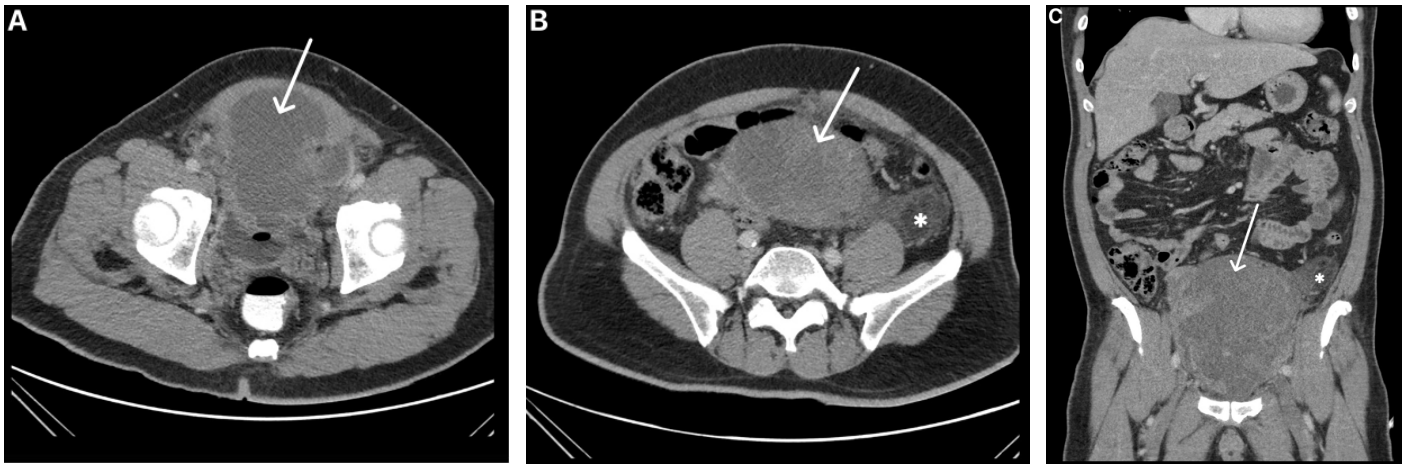


Figure 1: 59-year-old male with urachal liposarcoma
Findings: (A, B) Axial and (C) coronal contrast-enhanced CT shows a lobulated, predominantly hypodense extraperitoneal mass at the anterosuperior aspect of the urinary bladder dome (white arrows) containing multiple thick septations and irregular nodular enhancement, suspicious for urachal malignancy. A fatty lesion is seen in the left iliac fossa (white asterisks) contiguous to the mass and extending along the left gonadal vessels, suggestive of perivascular tumor infiltration.
Technique: Axial and coronal contrast-enhanced CT, 149 mAs, 120 kV, 3 mm slice thickness, 80 ml of intravenous Omnipaque 350.

Journal of Radiology Case Reports

www.RadiologyCases.com

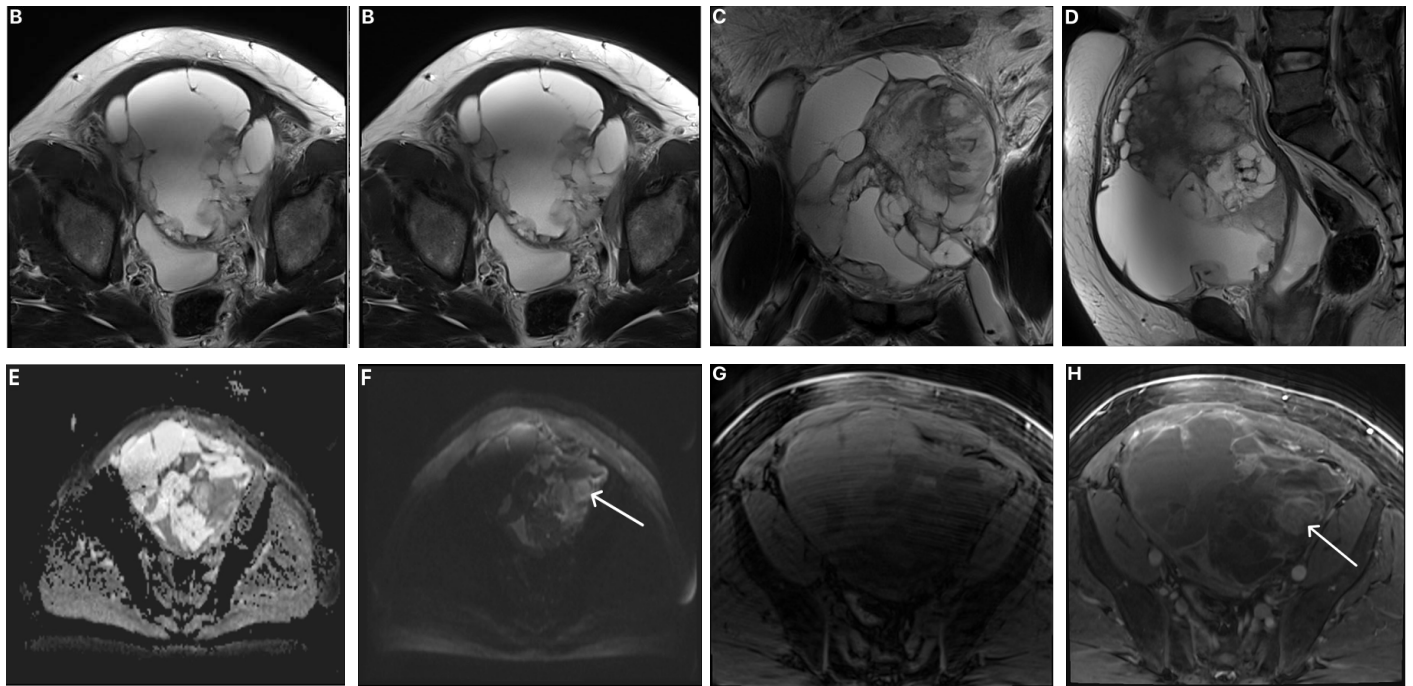


Figure 2: 59-year-old male with urachal liposarcoma
Findings: MRI pelvis, (A) axial T1-weighted VIBE FS without contrast, (B) axial T2-weighted, (C) coronal T2-weighted, (D) sagittal T2-weighted, (E) ADC, (F) DWI, (G) T1-weighted VIBE FS without contrast, and (H) T1-weighted VIBE FS with contrast. The known urachal mass appears as a complex multiloculated, predominantly T2-weighted hyperintense mass with multiple septations showing areas of restricted diffusion and nodular enhancement (white arrows). T1-weighted hyperintense foci within the mass (white asterisk) indicated the presence of mucinous or hemorrhagic products.
Technique: 3 Tesla MRI scanner, 16 ml of intravenous Dotarem. Please refer to Table 2 for additional specifics.

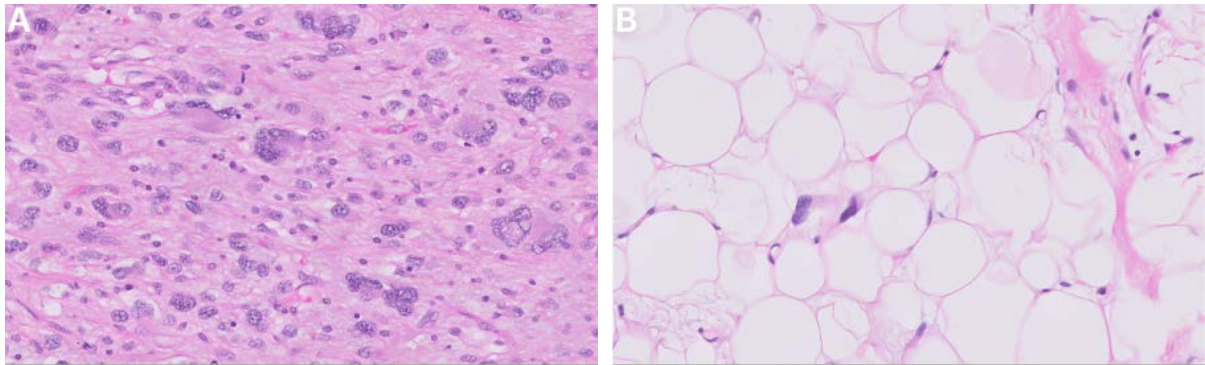


Figure 3: 59-year-old male with urachal liposarcoma
Findings: Histopathologic analysis of the urachal mass resected at partial cystectomy revealed (A) a dedifferentiated component exhibiting diffuse sheets of pleomorphic spindle cells with areas of cystic change and necrosis, as well as (B) a well-differentiated liposarcoma component composed of variably sized adipocytes with hyperchromatic nuclei.
Technique: H&E staining at 20x magnification.

Journal of Radiology Case Reports

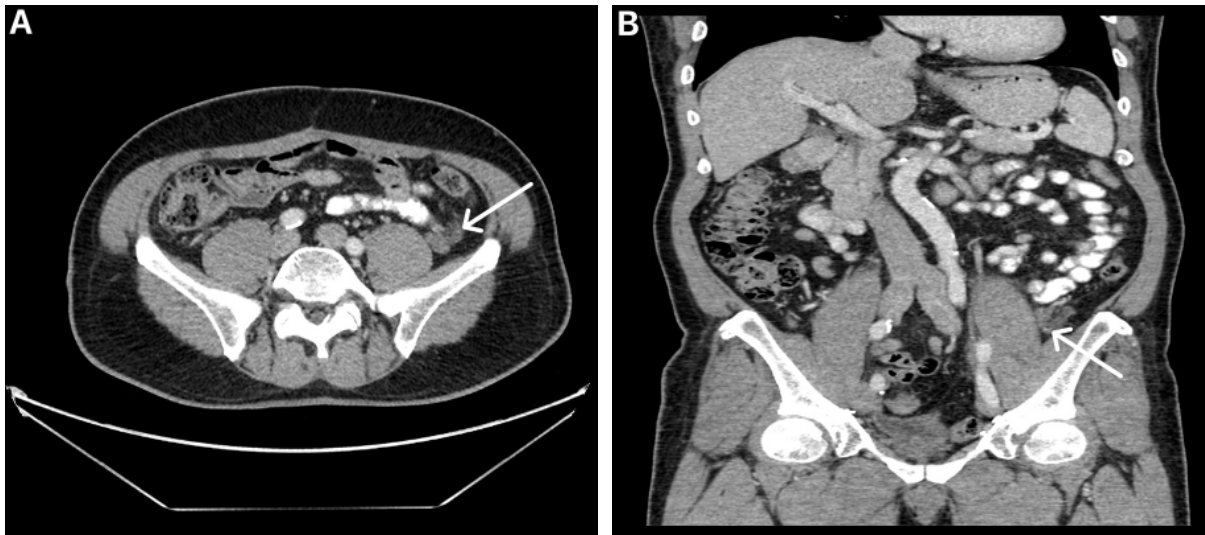


Figure 4: 59-year-old male with urachal liposarcoma. 4th year postoperative surveillance CT.
Findings: (A) Axial and (B) coronal contrast-enhanced CT shows increased nodular enhancing areas within the area of fat infiltration in the left iliac fossa (white arrows), suspicious for disease progression.
Technique: Axial and coronal contrast-enhanced CT, 129 mAs, 120 kV, 3 mm slice thickness, 90 ml of intravenous Omnipaque 350.

www.RadiologyCases.com

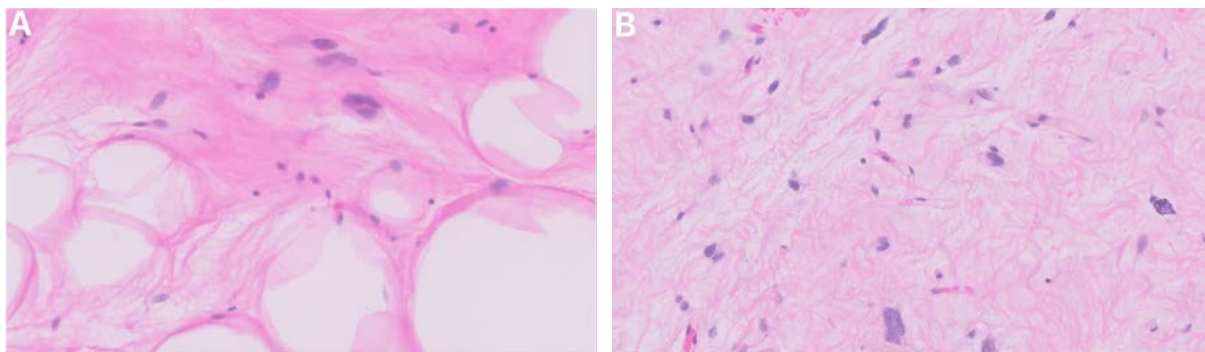


Figure 5: 59-year-old male with urachal liposarcoma
Findings: Histopathologic analysis of the left retroperitoneal mass resected at interval laparotomy revealed (A) a well-differentiated sclerosing liposarcoma with a focus of (B) low grade dedifferentiated liposarcoma.
Technique: H&E staining at 20x magnification.

Table 1: Summary of urachal liposarcoma

Etiology	Unknown; similar to other nonepithelial malignant urachal neoplasms, urachal liposarcoma may originate from mesenchymal cells within the urachus
Incidence	This is the first known instance of urachal liposarcoma
Gender ratio	Unknown; similar to other malignant urachal neoplasms, urachal liposarcoma may have a predilection for males
Age predilection	Unknown; similar to urachal adenocarcinoma, urachal liposarcoma may predominantly affect males in their 5 th to 6 th decades of life
Risk factors	Unknown
Treatment	Wide local excision of the urachus, umbilicus, and perivesical soft tissue; combined with partial or radical cystectomy and bilateral pelvic lymphadenectomy; with or without chemotherapy
Prognosis	Unknown; possibly more favourable than other malignant urachal neoplasms
Findings on imaging	Well-differentiated liposarcoma is primarily characterized by fatty tissue; dedifferentiation is suggested by a focal nodular nonlipomatous component larger than 1 cm

Table 2: MRI technical parameters

	FOV	Slice thickness	Gap	TR	TE	Voxel size	Matrix
DWI	360	3.0	30%	3400	66	1.9 x 1.9 x 3.0	192 x 100
T2 Sag	200	3.0	10%	3000	98	0.6 x 0.6 x 3.0	320 x 100
T2 Cor	200	3.0	10%	4650	87	0.6 x 0.6 x 3.0	320 x 100
T2 Tra	200	3.0	10%	3800	98	0.6 x 0.6 x 3.0	320 x 100
Tra T1 VIBE	200	3.0		3.56	1.4	0.8 x 0.8 x 3.0	205 x 256
Tra T1 VIBE+C	200	3.0		3.56	1.4	0.8 x 0.8 x 3.0	205 x 256

KEYWORDS

Urachal Liposarcoma; Malignant Urachal Neoplasms, Bladder; Computed Tomography; Magnetic Resonance Imaging

ABBREVIATIONS

CT = Computed Tomography
MRI = Magnetic Resonance Imaging
US = Ultrasound
OS = Overall survival
PFS = Progression-Free Survival

Online access

This publication is online available at:
www.radiologycases.com/index.php/radiologycases/article/view/5364

Peer discussion

Discuss this manuscript in our protected discussion forum at:
www.radiolopolis.com/forums/JRCR

Interactivity

This publication is available as an interactive article with scroll, window/level, magnify and more features.
Available online at www.RadiologyCases.com

Published by EduRad



www.EduRad.org