

# CBCT imaging and root canal treatment for taurodontism in mandibular second molar - A case report and literature review

Xiufen Tian<sup>1,2</sup>, Junxia Qiao<sup>1</sup>, Na Guo<sup>2#\*</sup>, Kun Liu<sup>2#\*</sup>, Keyi Li<sup>2#\*</sup>

<sup>1</sup>Department of Endodontics, Liaocheng People's Hospital, Shandong People's Republic of China

<sup>2</sup>Department of Stomatology, Liaocheng People's Hospital, Shandong, People's Republic of China

\*Correspondence: Kun Liu, Department of Stomatology, Liaocheng People's Hospital, Liaocheng, 252000, Shandong, China

✉ LK2307@163.com

Radiology Case. 2023 Nov; 17(11):1-7 :: DOI: 10.3941/jrcr.v17i11.5212

## ABSTRACT

The mandibular second molar exhibits a wide range of intricate root canal variations, which can present challenges and difficulties in achieving successful root canal treatment. This report focuses on two specific cases involving a root canal variation in a typical taurodontism of the mandibular second molar. To provide a comprehensive analysis and illustration of the anatomical structure of intraoral taurodontism and the important considerations for root canal treatment, we utilized advanced imaging techniques such as cone beam computed tomography (CBCT) and a dental microscope. By combining these tools, we were able to gain a deeper understanding of the complex root canal system and make informed decisions during the treatment process.

## CASE REPORT

### CASE REPORT

#### CASE 1

A 30-years-old male patient visited our hospital with chief complaints of cold-stimulated dentalgia in the mandibular left posterior tooth for 3 weeks. Intraoral examination revealed a carious lesion near the pulp in the distal surface of mandibular left second molar. The temperature test revealed that the patient experience persistent pain upon cold. A periapical radiograph revealed a radiolucent lesion near the pulp in the distal surface of the mandibular second molar, indicating its proximity to the pulp cavity. The pulp chamber was thin and lengthy, with a short and curved root (Figure 1a). A CBCT scan was performed to confirm the root canal variation, and the CBCT image and 3- dimensional (3D) reconstruction showed an increased size of the pulp chamber vertically and severely curved proximal roots (Figure 1b-1g).

The right mandibular second molar (#47) was anesthetized with 2% lidocaine and epinephrine at a ratio of 1: 80,000, and access to the pulp cavity was obtained under rubber dam isolation (Coltène, Switzerland). One proximal and one distal root canal were explored, with the proximal root canal showing severe curvature (Figures 2a,2b). Working length was determined using an electronic apex locator (Root ZX; J Morita), and the root canal was initially prepared with a hand-use 15# stainless steel file, followed by further shaping using a rotary instrument. A 25/04 file was used for the proximal root canal and a 30/04 file for the distal root canal. The root canal was irrigated with 2.5% sodium hypochlorite, 8% EDTA aqueous solution, and

3% hydrogen peroxide. After drying the canal with sterile paper points, calcium hydroxide medication was sealed in the canal (Figure 1h). The patient returned to the clinic after 1 week, reporting no symptoms and a dry canal. The canal was irrigated with sodium hypochlorite to remove calcium hydroxide paste, and the canal was filled using thermoplasticized gutta-percha filling techniques (BeeFill Pack; VDW) and sealed with a bioceramic sealer (iRoot SP) (Figure 2c-2e). The pulp cavity was cleaned and restored with a composite resin for permanent restoration (Figure 2f). After root canal treatment, a periapical film was used to confirm the complete seal of the root canal (Figure 2g,2h).

#### CASE 2

A 40-year-old female patient was referred to the Department of Endodontics for root canal treatment of her lower right second molar tooth (tooth #47). due to chief complaint of occlusal pain in the right mandibular molar area. Clinical examination revealed composite resin fillings on the occlusal surface of the left mandibular second molar, with evidence of secondary caries at the restoration margins. The periapical radiograph revealed deep cavities on the distal aspect of tooth #47, with evidence of inadequate root canal fillings and apical cementum resorption (Figure 3a). Combined with the above examination findings, the diagnosed was chronic periapical periodontitis.

The patient underwent endodontic retreatment, and after the access cavity was prepared, the teeth were isolated with rubber dam. The dental microscope revealed that the pulp chamber

floor was not visible, and only one root orifice was identified (Figure 3b and c). The previous fillings in the pulp chamber and root canal were removed, and the pulp cavity was irrigated with 2.5% sodium hypochlorite. Working lengths were detected with an electronic apex locator, and root canal preparation was performed using rotary files. Calcium hydroxide was placed as an intracanal medication and removed after 1 week. The canal was alternately irrigated with 8% EDTA and 2.5% sodium hypochlorite, and then dried. The thermos-compaction technique combined with hot gutta percha injection was used for root canal filling (Figure 3d). Dental restoration was completed with composite resin (Figure 3e). The final periapical radiograph confirmed that the root canal was filled to a predetermined length (Figure 3f). The patient reported no discomfort during telephone follow-up, and the long-term effectiveness of the root canal therapy will continue to be monitored.

## DISCUSSION

In this paper, we present two cases of taurodontism in mandibular second molars. The first case exhibits hypertaurodontism, with a taurodontism index (TI) is 55.56%, while the second case presents with pyramidal taurodontism [1]. Additionally, we have compiled a review of the existing dental literature on taurodontism in mandibular second molars, aiming to assist dentists in early diagnosis and appropriate treatment planning.

## ETIOLOGY & DEMOGRAPHICS

Taurodontism is an abnormal development of tooth morphology, characterized by non-contraction of the cemento-enamel junction, vertical elongation of the pulp cavity, and displacement of the pulp chamber towards the apex [2]. It most commonly affects mandibular second molars and can occur unilaterally or bilaterally [3]. Numerous studies have evaluated the prevalence of taurodontism in mandibular second molars using different methods. The prevalence rates vary due to differences in statistical methods and tooth types used in the studies. However, in general, the prevalence of taurodontism in mandibular second molars is the highest among all molars, with reported prevalence rates ranging from 0.1%-18.8%. please refer to (Table 1) for the prevalence in various countries. Additionally, (Table 2) provides a summary of reported cases of taurodontism in mandibular second molars by dentists in different regions.

## CLINICAL & IMAGING FINDINGS

Taurodontism is a root deformity caused by a genetic disorder in the process of tooth morphogenesis. It is characterized by the enlargement of the pulp cavity, which may be close to the apex of the root, with the bifurcation possibly only a few millimeters above the apex [4]. Under normal conditions, taurodontism generally does not present any clinical symptoms and is often only discovered accidentally during dental X-rays. The identification of taurodontism is primarily based on the special features visible on X-ray images. By measuring the distance from the pulp chamber apex to the root bifurcation

and the length of the root, the Taurodontism index (TI) can be calculated to distinguish the severity of taurodontism, which can be classified as hypopotaurodontism, mesopotaurodontism and hypertaurodontism [5]. The taurodontism index involves dividing the distance between the lowest point of the pulp cavity roof and the highest point of the pulpal floor by the distance between the lowest point of the pulp cavity roof and the root apex, and then multiplying the result by 100 [6]. prior to oral intervention, carefully observation of radiological images is crucial for identifying and diagnosing taurodontism in order to enhance the effectiveness of dental treatment.

## TREATMENT & PROGNOSIS

The presence of taurodontism in teeth requiring dental treatment introduces additional complexities and challenges, including tooth extraction [7], orthodontic treatment [8], restorative procedures, and periodontal therapy, particularly in the context of endodontic treatment [9,10]. Despite its relative rarity, taurodontism poses inherent risks to various dental interventions due to its unique tooth morphology and anatomical structure. Accurate preoperative diagnosis is crucial for the successful management of taurodontism. Careful operation techniques, such as minimizing the risk of tooth fracture during tooth extraction, meticulous removal of infected pulp tissue, and precise root canal filling during endodontic therapy, are essential. Similarly, minimizing the movement of taurodontism teeth during orthodontic treatment and ensuring regular postoperative follow-up are important measures to prevent potential complications.

## DIFFERENTIAL DIAGNOSES

Through medical history, clinical manifestations, particularly radiological examination, taurodontism can be distinguished from other tooth deformities. Taurodontism may occur in isolation, in conjunction with other tooth development abnormalities, or as part of certain hereditary syndromes. Its differential diagnosis primarily includes:

**Type I dentin dysplasia (DD-I):** Type I dentin dysplasia (DD-I) is a rare hereditary disease, which can be autosomal dominant or recessive, and carries a risk of late or long-term misdiagnosis. In comparison to other degenerative dentin diseases, the crown of teeth is partially normal, but exhibits features such as deletion, cone-shaped, pointed root or blockage of the pulp canal at the root level [11,12].

**Immature permanent teeth:** X-ray films of young permanent teeth exhibit characteristics such as a large pulp chamber, high pulp angle, and thin pulp cavity walls; The root canal is thick, and the apical foramen is large. Additionally, the pulp floor of deciduous molars is situated close to the root bifurcation, and there are numerous auxiliary root canals at the pulp floor of deciduous molars.

The syndromes associated with taurodontism, such as hair bone syndrome, osteogenesis imperfecta, Down's syndrome, ectodermal developmental disorder, Klinefelter's

syndrome, Mohr's syndrome, Vanderward's syndrome (VWS), nonsyndromic cleft palate (NSCP), and others. Apart from taurodontism, the primary distinguishing factor of these syndromes lies in the characteristic signs of each syndrome.

### SUMMARY

Taurodontism is an uncommon abnormality in tooth development characterized by the apical displacement of the root bifurcation and enlargement of the pulp chamber. The purpose of this case report is to elucidate the endodontic treatment of two mandibular second molars affected by taurodontism. Additionally, this report aims to provide a summary of the existing research on taurodontism in mandibular second molars

### TEACHING POINT

The report examines the imaging manifestations and successful endodontic treatment of two cases of taurodontism in mandibular second molar. Through preoperative clinical and radiological examinations, early detection and diagnosis can lead to the development of effective treatment plans, thereby effectively preventing adverse prognosis associated with the condition.

### AUTHORS' CONTRIBUTIONS

LY, LK and GN contributed equally to this work, LY, GN and LK were responsible for the study concept and design. Drafting of the manuscript was performed by TF and QX. All authors contributed to the article and approved the final manuscript.

### ACKNOWLEDGEMENTS

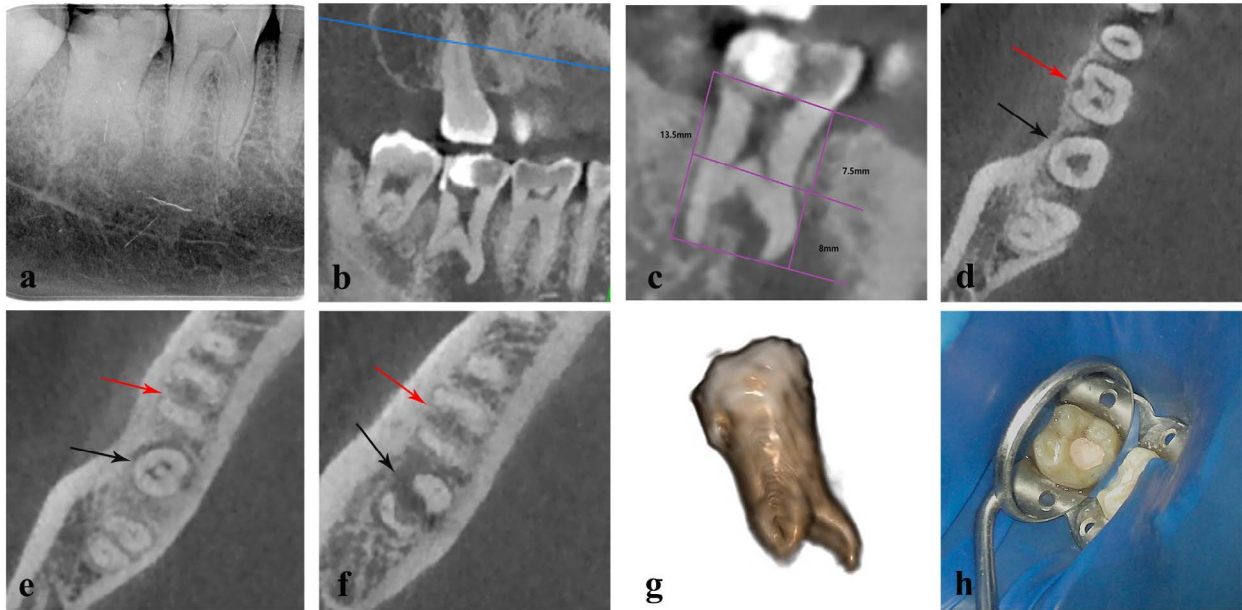We appreciate Dr. Chen Jiantao's consent to publish this case report regarding his teeth.

### REFERENCES

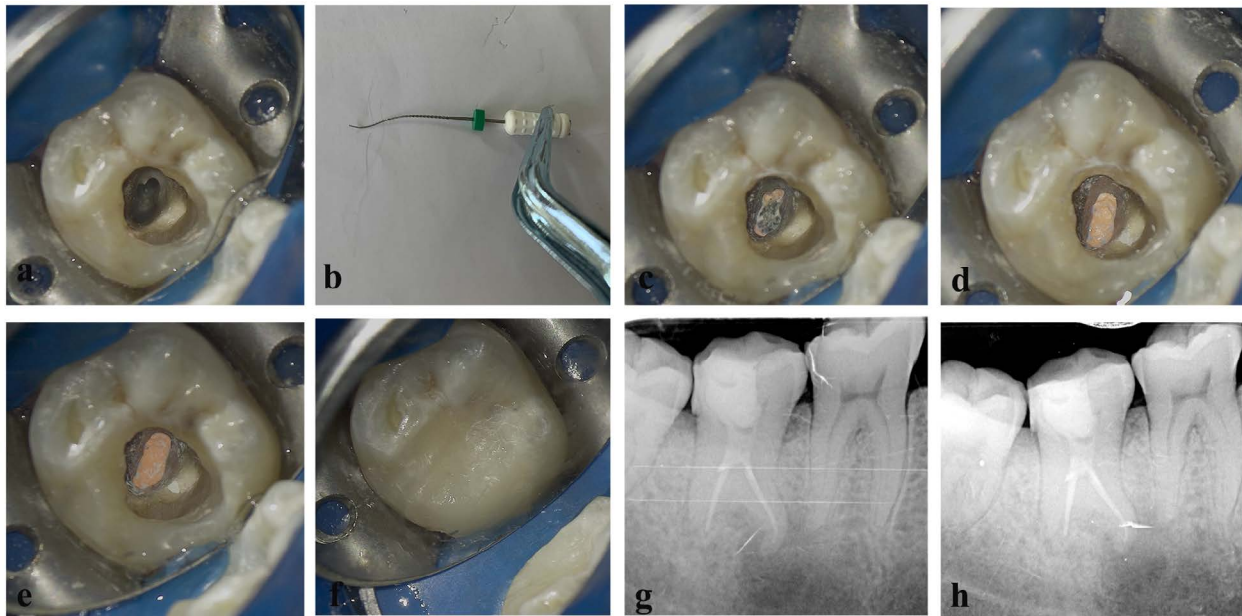
1. Aydın H, Mobaraki S. Comparison of root and canal anatomy of taurodont and normal molar teeth: A retrospective cone-beam computed tomography study. *Arch Oral Biol.* 2021; 130: 105242. PMID: 34411883.
2. Jafarzadeh H, Azarpazhooh A, Mayhall JT. Taurodontism: a review of the condition and endodontic treatment challenges. *Int Endod J.* 2008; 41(5): 375-388. PMID: 18363703.
3. Kulkarni G, Rajeev KG, Ambalavanan P, Kidiyoor KH. Successful endodontic management of hypo, meso and hypertaurodontism: Two case reports. *Contemp Clin Dent.* 2012; 3(2): S253-S256. PMID: 23230375.
4. Şen Yavuz B, Sezer B, Kaya R, Tuğcu N, Kargül B. Is there an association between molar incisor hypomineralization and developmental dental anomalies? A case-control study. *BMC Oral Health.* 2023; 23(1): 776.
5. Chetty M, Roomaney IA, Beighton P. Taurodontism in dental genetics. *BDJ Open.* 2021; 7(1): 25. PMID: 34244468.
6. Pach J, Regulski PA, Tomczyk J, Strużycka I. Clinical implications of a diagnosis of taurodontism: A literature review. *Adv Clin Exp Med.* 2022; 31(12): 1385-1389. PMID: 36000881.
7. Su J, Shao LM, Wang LC, et al. Concrescence of maxillary second molar and impacted third molar: A case report. *World J Clin Cases.* 2022; 10(28): 10286-10292. PMID: 36246819.
8. Drenski Balija N, Aurer B, Meštrović S, Lapter Varga M. Prevalence of Dental Anomalies in Orthodontic Patients. *Acta Stomatol Croat.* 2022; 56(1): 61-68.
9. Dineshshankar J, Sivakumar M, Balasubramaniam AM, Kesavan G, Karthikeyan M, Prasad VS. Taurodontism. *J Pharm Bioallied Sci.* 2014; 6(1): S13-S15.
10. Li D, Zhang JP, Zhang C, Hou BX, Su Z. [Mandibular first premolar with hyper-taurodont and C3 root canal: a case report]. *Zhonghua Kou Qiang Yi Xue Za Zhi.* 2022; 57(11): 1173-1176. PMID: 36379898.
11. Putrino A, Caputo M, Galeotti A, Marinelli E, Zaami S. Type I Dentin Dysplasia: The Literature Review and Case Report of a Family Affected by Misrecognition and Late Diagnosis. *Medicina (Kaunas).* 2023; 59(8): 1477. PMID: 37629767.
12. Storoni S, Celli L, Zhytnik L, et al. Novel pathogenic variants in SPARC as cause of osteogenesis imperfecta: Two case reports. *Eur J Med Genet.* 2023; 66(11): 104857. PMID: 37758164.
13. Jabali AH, Chourasia HR, Wasli AS, et al. Taurodontism in maxillary and mandibular molars using cone beam computed tomography in a dental center in Saudi Arabia. *Ann Saudi Med.* 2021; 41(4): 232-237. PMID: 34420397.
14. Bronoosh P, Haghnegahdar A, Dehbozorgi M. Prevalence of taurodontism in premolars and molars in the South of Iran. *J Dent Res Dent Clin Dent Prospects.* 2012; 6(1): 21-24. PMID: 22991630.
15. Gupta SK, Saxena P. Prevalence of taurodontism and its association with various oral conditions in an Indian population. *Oral Health Prev Dent.* 2013; 11(2): 155-160. PMID: 23534039.
16. Da Y, Wang C, Zhang L, et al. High prevalence of taurodontism in North China and its relevant factors: a retrospective cohort study. *Oral Radiol.* 2023; 39(2): 266-274.
17. Li Y, Qian F, Wang D, Wang Y, Wang W, Tian Y. Prevalence of taurodontism in individuals in Northwest China determined by cone-beam computed tomography images. *Heliyon.* 2023; 9(4): e15531. PMID: 37128323.
18. Shifman A, Chananel I. Prevalence of taurodontism found in radiographic dental examination of 1,200 young adult Israeli patients. *Community Dent Oral Epidemiol.* 1978; 6(4): 200-203. PMID: 278704.
19. Toure B, Kane AW, Sarr M, Wone MM, Fall F. [Prevalence of taurodontism at the level of the molar in the black Senegalese population 15 to 19 years of age]. *Odontostomatol Trop.* 2000; 23(89): 36-39. PMID: 11372146.

20. Patil S, Doni B, Kaswan S, Rahman F. Prevalence of taurodontism in the North Indian population. *J Clin Exp Dent*. 2013; 5(4): e179-e182. PMID: 24455077.
21. Chaparro González NT, Leidenz Bermudez JS, González Molina EM, Padilla Olmedillo JR. Multiple bilateral taurodontism. A case report. *J Endod*. 2010; 36(11): 1905-1907. PMID: 20951311.
22. Celikten B, Yalniz H, Huang Y. Endodontic management of taurodontism with a complex root canal anatomy in mandibular posterior teeth. *BMJ Case Rep*. 2017; 2017: bcr2017222563. PMID: 29269370.
23. Viana FLP, Souza TA, Sampieri MBS, Vasconcelos BC. Endodontic treatment of hypertaurodontic teeth with anatomical variations: case reports. *Gen Dent*. 2021; 69(2): 64-68. PMID: 33661118.
24. Hayashi Y. Endodontic treatment in taurodontism. *J Endod*. 1994; 20(7): 357-358.
25. Marques Fernandes M, Ferreira Silva R, De Lucena Botelho T, Ribeiro Tinoco RL, Fontanella V, Nogueira de Oliveira R. Taurodontism and its forensic value: a case report. *J Forensic Odontostomatol*. 2018; 36(2): 40-43. PMID: 30712030.
26. Janani M, Rahimi S, Shahi S, Aghbali A, Zand V. Endodontic treatment of a hypertaurodont mandibular second molar: a case report. *Iran Endod J*. 2011; 6(3): 133-135. PMID: 23130066.
27. Jamshidi D, Adl A, Sobhnamayan F, Bolurian M. Root canal treatment of a hypertaurodont mandibular second molar: a case report. *J Dent Res Dent Clin Dent Prospect*. 2015; 9(1): 57-59. PMID: 25973157.
28. Lim A, Le Clerc J. Endodontic treatment of a hypertaurodontic mandibular left second molar in a patient with many taurodonts combined with multiple pulp stones. *Aust Endod J*. 2019; 45(3): 414-419. PMID: 30113740.

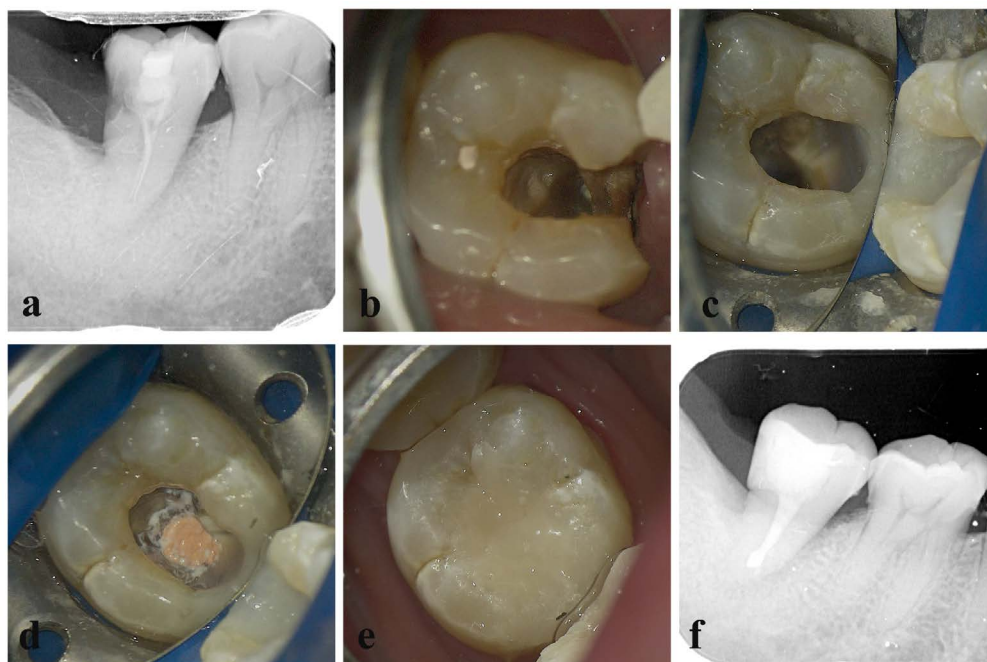
FIGURES



**Figure 1:** (a) Initial pretreatment radiograph illustrates extensive decay in the right mandibular second molar and abnormal root morphology. (b) Sagittal plane of CBCT image demonstrates taurodontism in mandibular second molar. (c) Measurement data indicates a taurodontism index of 55.56% (calculated as  $7.5/13.5 \times 100\%$ ). (d) Cross-sectional CBCT image displays furcation involvement in tooth #46, while the pulp cavity is still visible in tooth #47. (e) Cross-sectional CBCT image displays mesial and distal roots in tooth #46, with only root bifurcation visible in tooth #47. (f) Cross-sectional CBCT image reveals two variant roots in tooth #47, contrasting with those in tooth #46. (g) 3-dimensional reconstruction views highlight the extended pulp cavity and the short and curved root. (h) Intraoral photograph showing dental dam placement, with teeth labeled by arrows. The red arrow indicates tooth #46, and the black arrow indicates tooth #47.



**Figure 2:** (a) Intraoral photograph showing the pulp chamber. (b) K file illustrating the curvature of the mesial root. (c) Root canal filling below the root bifurcation. (d,e) Root canal filling above the root bifurcation. (f) Complete root canal treatment with resin restoration. (g) Post-obturation radiography. (h) Follow-up radiography.



**Figure 3:** (a) Initial pretreatment radiograph indicating a single root canal in the mandibular second molar. (b) Intraoral photograph showing the canal orifice. (c) Intraoral photograph demonstrating the use of rubber dam isolation. (d) Root canal filling using thermo-coagulation technique (e) Complete root canal treatment with resin restoration. (f) Post-obturation radiography.

**Table 1:** Summary of prevalence of taurodontism in mandibular second molar

Study	Population	N	Taurodontism, n (%)	Method of study
Jabali AH et al. [13]	Saudi Arabia	287	13 (4.3)	CBCT
Bronoosh P et al. [14]	South of Iran	7022	19 (0.1)	panoramic radiographs
Gupta SK et al. [15]	Indian	118	32 (0.27)	periapical radiographs
Aydn H et al. [1]	Turkey	1763	47 (2.67)	CBCT
Da Y et al. [16]	North China	1907	199 (10.4)	CBCT
Li Y et al. [17]	Northwest China	1074	38 (0.03)	CBCT
Shifman A et al. [18]	Israeli	10204	1 (0.1)	radiographs
Toure B et al. [19]	Senegalese			panoramic radiograph
Patil S et al. [20]	North Indian	32	6 (18.8)	panoramic radiographs

**Table 2:** Summary of case reports of taurodontism of mandibular second molar

Study	Country	Age	Gender	Tooth	TIs	diagnostic
Chaparro González NT et al. [21]	Venezuela	13	female	47	41.7	Hypertaurodontism
				37	36.7	Mesotaurodontism
Celikten B et al. [22]	Turkey	19	male	47	NA	NA
Kulkarni G et al. [3]	India	18	female	37	23	Hypotaurodontism
				23	65	Hypertaurodontism
Viana FLP et al. [23]	Brazil					
Hayashi Y et al. [24]	Japan	16	female	31	NA	Typical taurodontism
Marques Fernandes M et al. [25]	Brazil	27	male	37	NA	NA
Janani M et al. [26]	Iran	28	male	37	NA	NA
Jamshidi D et al. [27]	Iran	24	male	47	NA	NA
Lim A et al. [28]	France	20	male	37	NA	Hypertaurodontism
				47	NA	Hypertaurodontism

## ABBREVIATIONS

CBCT: Cone Beam Computed Tomography; 3D: 3-Dimensional; Tis: Taurodontic Index; No.: Number; N: Numbers of Teeth Detected; DD-I: Type I Dentin Dysplasia; VWS: Vanderward's Syndrome; NSCP: Nonsyndromic Cleft Palate

## KEYWORDS

Mandibular secondary molar; Root canal treatment; Taurodontism; Root canal anatomical variation; Cone beam computed tomography

**Online access**

This publication is online available at:

[www.radiologycases.com/index.php/radiologycases/article/view/5212](http://www.radiologycases.com/index.php/radiologycases/article/view/5212)

**Peer discussion**

Discuss this manuscript in our protected discussion forum at:

[www.radiopolis.com/forums/JRCR](http://www.radiopolis.com/forums/JRCR)

**Interactivity**

This publication is available as an interactive article with scroll, window/level, magnify and more features.

Available online at [www.RadiologyCases.com](http://www.RadiologyCases.com)

Published by EduRad



[www.EduRad.org](http://www.EduRad.org)