

Hodgkin's Lymphoma and Cardiac Tamponade: Management and Perioperative Imaging

Karan Bir Singh MD^{1*}, Muhammad Areeb Ashfaq MD¹, Krithika Muthyala MD¹, Sagar Kumar MD², Samuel McQuiston MD³, Omar Alkharabsheh MD⁴


¹Department of Internal Medicine, University of South Alabama, USA

²Division of Pulmonary and Critical Care Medicine, University of South Alabama, USA

³Department of Radiology, University of South Alabama, USA

⁴Division of Medical Oncology, Mitchell Cancer Institute, University of South Alabama, USA

*Correspondence: Karan Bir Singh, M.D., Department of Internal Medicine, University of South Alabama, Alabama, 36617, USA

 karansingh_21@hotmail.com

Radiology Case. 2024 Feb; 18(2):21-26 :: DOI: 10.3941/jrcr.v18i2.5209

CASE REPORT

INTRODUCTION

Classical Hodgkin's lymphoma (cHL) is characterized by a neoplastic growth of lymph nodes. Histologically characterized by Reed-Sternberg cell and clinically presents commonly with painless lymphadenopathy and constitutional symptoms such as fever, chills, weight loss and or night sweats [1]. Uncommonly, this disease can affect extralymphatic organs such as pericardium. In normal healthy adults, approximately 10 to 50 mL of pericardial fluid surrounds the heart. This fluid is an ultrafiltrate from epicardial blood vessels and cushions the heart during systole and diastole. Pericardial effusions are most commonly seen in viral etiologies and occur in 4-6% of patient's with cHL with pericardial tamponade being exceedingly rare and reported only in case reports [2-6]. Typically, 20% of patient's at the time of diagnosis have pericardial effusions with 6% being moderate or large [6]. Pericardial effusions can be subclassified into an acute (<7 days) or subacute (7-90 days) or chronic (>90 days) based on the onset of symptoms. In the United States, majority of cases are presumed viral pericarditis, whereas, tuberculosis is the leading cause in developing countries [7]. Common symptoms of pericardial effusions include dyspnea, shortness of breath, and chest pain in cases of pericarditis. Cardiac tamponade should be suspected in patients with Beck's triad (jugular venous distension, muffled heart sounds, and hypotension) as well as classic diastolic collapse of the right ventricle on echocardiogram. Malignant pericardial effusions can be small (<10 mm), moderate (10-20 mm), or large (>20 mm) based on echocardiographic findings [8]. In terms of clinical presentation, a systemic review determined shortness of breath, edema, and constitutional symptoms occurring in 94%, 38%, and 35% of patients respectively. We hereby describe large pericardial effusion complicated by tamponade as initial presentation of advanced HL [9].

CASE PRESENTATION

A 29-year-old male with a medical history of low-grade neuroendocrine tumor of the appendix (pT2N1Mx) with

subsequent right hemicolectomy, presented to the emergency department for worsening shortness of breath over the prior 2 weeks. Physical exam revealed an enlarged right neck mass (>6cm) that was nontender, slightly firm and nonmobile along with diffuse cervical and submandibular lymphadenopathy. Electrocardiogram demonstrated low voltage QRS on extremity leads. Chest x-ray (CXR) demonstrated large right pleural effusion (Figure 1) and chest computed tomography (CT) demonstrated significant mediastinal lymphadenopathy with mass effect creating significant stenosis of the neck vessels, a large pleural, and a pericardial effusion (Figure 2-11). Two-dimensional (2D) echocardiogram demonstrated features of impending tamponade (Figure 12) such as circumferential pericardial effusion with inversion of right ventricular wall and plethoric inferior vena cava with minimal change on respiration. The patient underwent a bilateral thoracostomy tube placement (Figure 13) and a pericardial window with subsequent drainage of 3,000mL and 500mL of fluid, respectively. His pericardial fluid analysis appeared slightly orange and cloudy with a lactate dehydrogenase of 523 u/L, protein 4.3g/dL, white blood cells 421 cells/mcL and 95% lymphocytes on differentials. His fluid was classified as exudative based on Light's criteria. Lymph node biopsy confirmed nodular sclerosis type cHL and classified as stage IV cHL after bone marrow aspirate revealing extensive involvement. He received chemotherapy with A-AVD regimen that includes brentuximab, doxorubicin, vinblastine, and dacarbazine.

DISCUSSION

Clinical:

cHL is a relatively common disease in the United States accounting for approximately 9,000 new cases diagnosed each year [10]. The most common manifestation of cHL is a painless, enlarged (>2cm), firm lymph node in the cervical neck (61%) area followed by mediastinal (20%) and inguinal (8%) lymphadenopathy [1]. Involvement of the pericardium occurs infrequently and is a sign of infiltration into the pericardium, cardiac metastasis, autoimmune effusion secondary to immunosuppressants, and idiopathic effusions [11].

Two case reports described symptomatic large pericardial effusion in young adults with evidence of tamponade and subsequently managed with ABVD chemotherapy (doxorubicin bleomycin vinblastine and dacarbazine) for stage IIB cHL [2,11]. If initial chemotherapy fails and remains chemo-sensitive with subsequent salvage, stem cell transplantation is the standard of care in young and fit patients as noted in a case of a 21 year old male presenting with large symptomatic pericardial effusion. In this case, the patient had subsequent relapse for which he received newer cHL treatment such as brentuximab vedotin and nivolumab [3]. Another way of disease related tamponade is direct malignant infiltration from the mediastinal adenopathy as described by Retter et al in a 33 year old woman who experienced relapsed cHL [5].

Radiological diagnosis (CT/echo):

The 3 most common tests obtained in a patient with a clinical manifestation of pericardial effusion with or without tamponade are 2D echocardiogram, CXR, and CT of the chest. The most common features in 2D echocardiogram were pericardial effusion and right atrial collapse and in CXR and CT chest were cardiomegaly, pericardial effusion, and +/- pleural effusion [9]. Echocardiogram reigns as the gold standard in diagnosis of pericardial effusion as well as life-threatening tamponade. The main strengths include non-ionizing radiation, being portable, and readily available at the bedside. However, in patient's benefit from adjunct imaging modalities such as CT scans to delineate secondary causes of effusions, perioperative planning, assess Hosenfeld units (HU), and diagnostic in cases where echocardiography is equivocal. Effusions on CT scans can help radiologists and clinicians categorize effusions by attenuation. In summary, effusions with <10 HU suggest transudates, >10 HU suggests exudates, and -60 to -80 HU suggest chylopericardium [12]. In fact, additional imaging other than echocardiography is indicated when effusions are: complex, loculated, or clot present. In these instances, cardiac MRI (CMRI) or CT scans are equally effective.

Treatment:

Treatment involves a multi-disciplinary approach with cardiology, hematology-oncology, radiation-oncology, cardiovascular & thoracic surgery, and radiology. Patient's with life-threatening massive cardiac effusions urgently require pericardiocentesis followed by systemic chemotherapy if malignancy is suspected. Due to high chances of recurrence, pericardial window can safely be performed. Earlier stages of HL (i.e. stages 1 and 2) are commonly managed with ABVD chemotherapy in the United States [3,13,14]. Advanced HL (stage 3 and 4) are treated brentuximab-AVD in USA and many countries in Europe use intensified regimen (escBEACOPP) in younger patients. Recently, a randomized control trial, SWOG S1826, demonstrated nivolumab-AVD to be superior to brentuximab-AVD [15].

CONCLUSION

In patients with a previous cancer diagnosis that present with persistent lymphadenopathy, clinicians should consider

malignancy until proven otherwise. Expedited tissue biopsy and short-term glucocorticoids should be given if lymphoma is suspected followed by cytoreductive chemotherapy based on the underlying pathology. In cHL, patients have subacute or chronic effusions can lead to clinical tamponade but are exceedingly rare. Gold standard diagnostic modality of choice is echocardiogram. Instances where echocardiogram is equivocal or when perioperative imaging is required, other modalities such as CT and cardiac MR imaging can be obtained. On CT, HUs can determine if the etiology is transudative (<10 HU) or exudative (>10 HU). Emergent pericardial window or pericardiocentesis can be considered as treatment options in select patients.

REFERENCES:

- Gallamini A, Hutchings M, Ramadan S. Clinical presentation and staging of Hodgkin lymphoma. *Semin Hematol.* 2016; 53(3): 148–154. PMID: 27496305.
- Adam C Adler, Cesar Cestero. Symptomatic pericardial effusion in Hodgkin's lymphoma: a rare occurrence. Case report and review of the literature. *Tumori.* 2012; 98(2): 50e-52e. PMID: 22678004.
- Chango Azanza JJ, Vredenburg J. An Unusual Hodgkin's Lymphoma Journey: Cardiac Tamponade, Primary Refractoriness, Immune Thrombocytopenia, and Post-Traumatic Stress Disorder. *Cureus.* 2021; 13(5): e15341. PMID: 34235020.
- Gabryś K, Nowicka J, Usnarska-Zubkiewicz L, et al. Massive pericardial effusion during the course of hematological diseases. *Pol Arch Med Wewn.* 1997; 98(7): 26–32. PMID: 9499205.
- Retter A, Ardeshna KM, O'Driscoll A. Cardiac tamponade in Hodgkin lymphoma. *Br J Haematol.* 2007; 138(1): 2–2. PMID: 17451407.
- Marks LJ, McCarten KM, Pei Q, et al. Pericardial effusion in Hodgkin lymphoma: a report from the Children's Oncology Group AHOD0031 protocol. *Blood.* 2018; 132(11): 1208–11. PMID: 30061157.
- Lazaros G, Vlachopoulos C, Lazarou E, Tsioufis K. New Approaches to Management of Pericardial Effusions. *Curr Cardiol Rep.* 2021; 23(8): 106-106. PMID: 34196832.
- Adler Y, Charron P, Imazio M, et al. 2015 ESC Guidelines for the diagnosis and management of pericardial diseases. *Eur Heart J.* 2015; 36(42): 2921–2964. PMID: 26320112.
- Shareef MA, Eshaq AM, Alshawaf R, et al. Case study-based systematic review of literature on lymphoma-associated cardiac tamponade *Contemp Oncol (Pozn).* 2021; 25(1): 57–63. PMID: 33911983.
- SEER [Internet]. [cited 2023 Jul 16]. Hodgkin Lymphoma - Cancer Stat Facts. Available from: <https://seer.cancer.gov/statfacts/html/hodg.html>.
- Hajra A, Bandyopadhyay D, Layek M, Mukhopadhyay S. Cardiac Tamponade as Initial Presentation of Hodgkin Lymphoma. *J Clin Imaging Sci.* 2015; 5: 67. PMID: 26900491.

12. Klein AL, Abbara S, Agler DA, et al. American Society of Echocardiography Clinical Recommendations for Multimodality Cardiovascular Imaging of Patients with Pericardial Disease. *Journal of the American Society of Echocardiography*. 2013; 26(9): 965-1012. PMID: 23998693.
13. Ansell SM. Hodgkin lymphoma: 2018 update on diagnosis, risk-stratification, and management. *Am J Hematol*. 2018; 93(5): 704–715. PMID: 29634090.
14. Ansell SM. Non-Hodgkin Lymphoma: Diagnosis and Treatment. *Mayo Clin Proc*. 2005; 80(8): 1087–1097. PMID: 16092591.
15. Herrera AF, LeBlanc ML, Castellino SM, et al. SWOG S1826, a randomized study of nivolumab(N)-AVD versus brentuximab vedotin(BV)-AVD in advanced stage (AS) classic Hodgkin lymphoma (HL). *JCO*. 2023; 41(17_suppl): LBA4–LBA4.

FIGURES

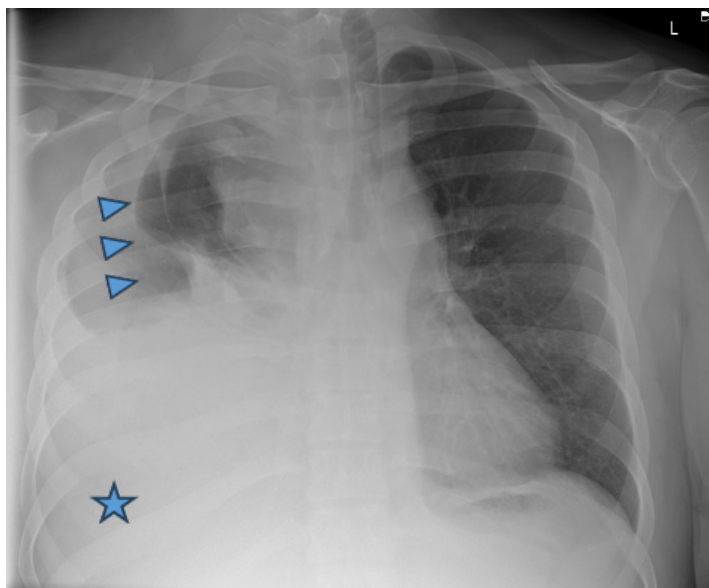
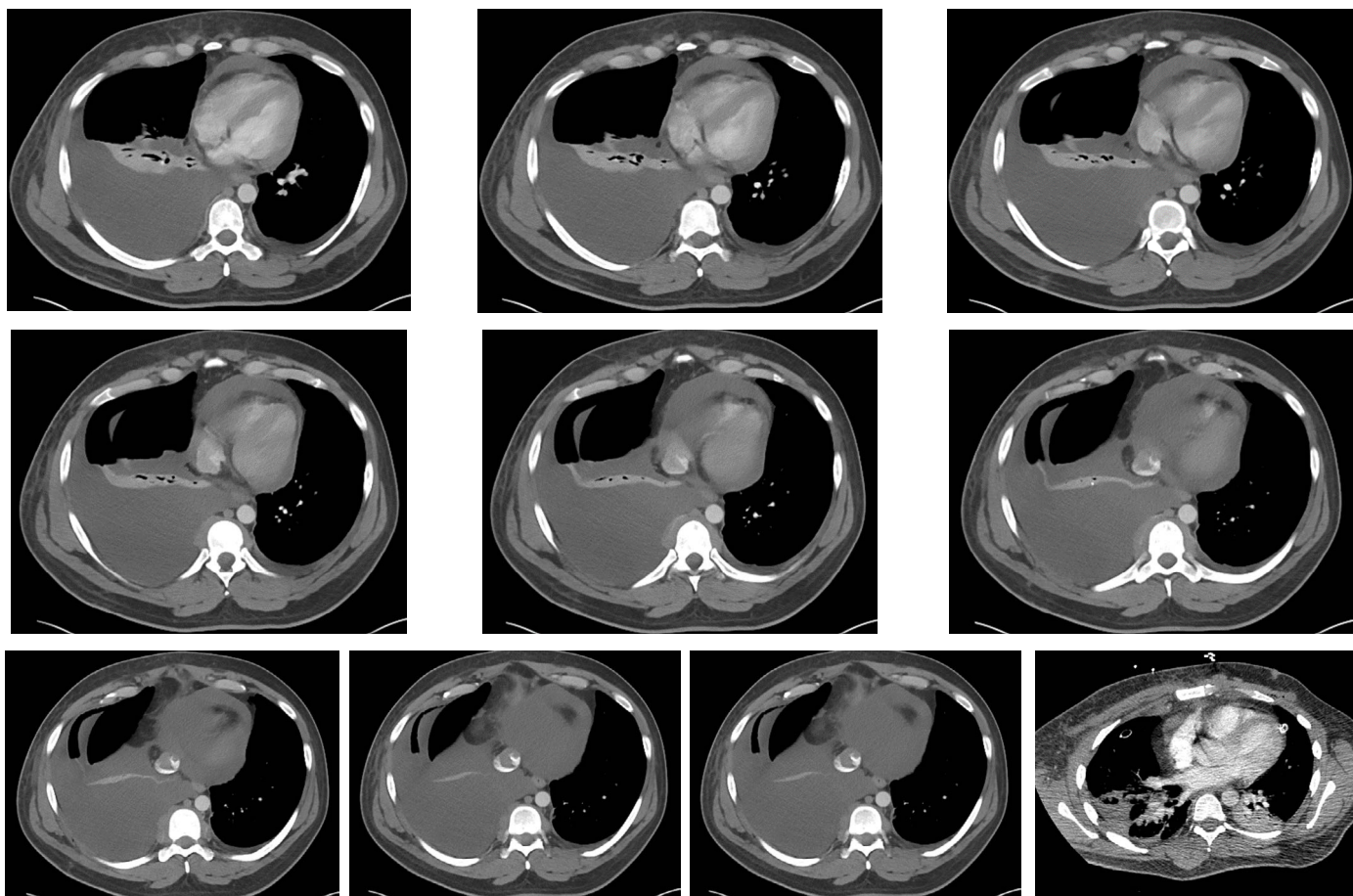


Figure 1: Single front view chest radiograph demonstrating large pleural effusion (star) with fluid tracking along the lateral chest wall (arrow heads) and subtotal atelectasis of the lung. Right hemidiaphragm is obscured in comparison to the left side.



Figures 2-11: Stack of images of axial nongated helical computed tomography of the chest with intravenous iodinated contrast in mediastinal window that shows a pericardial effusion of 1.56 cm with an 8.30 HU and 10cm right pleural effusion with -0.22 HU.

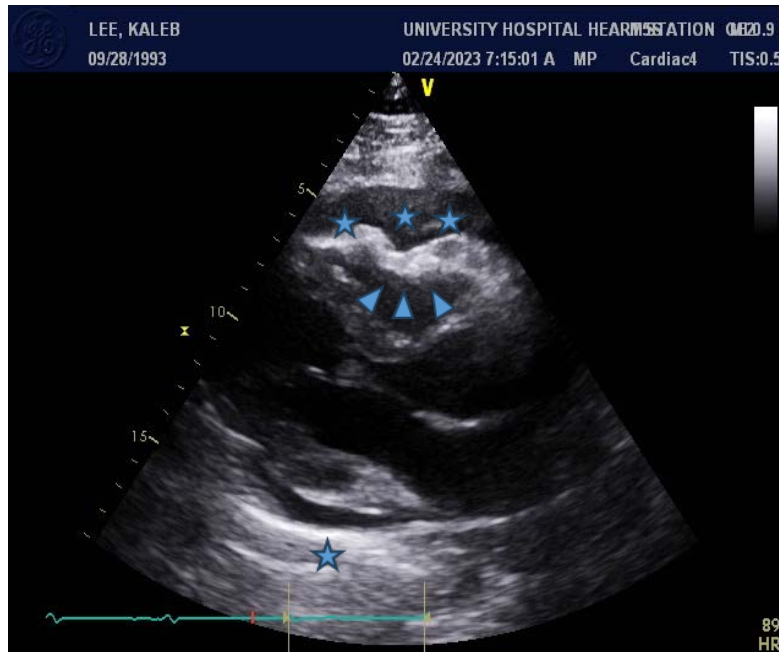


Figure 12: Parasternal long axis 2D echocardiogram with corresponding 1 lead EKG demonstrating circumferential moderate pericardial effusion (stars) with inversion of right ventricular wall (arrowheads) during diastole.

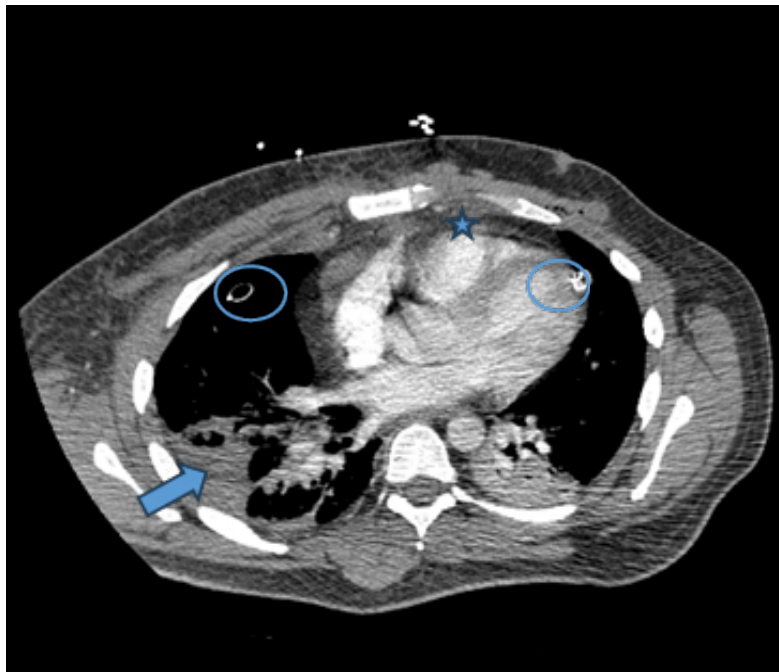


Figure 13: Axial nongated helical computed tomography of the chest with intravenous iodinated contrast in mediastinal window demonstrating near complete resolution of the right pleural effusion (arrow) and pericardial effusion (star). Scattered bilateral pulmonary infiltrates which may represent atelectasis and/or pneumonia with interval placement of bilateral thoracotomy tubes (circles).

Online access

This publication is online available at:
www.radiologycases.com/index.php/radiologycases/article/view/5209

Peer discussion

Discuss this manuscript in our protected discussion forum at:
www.radiopolis.com/forums/JRCR

Interactivity

This publication is available as an interactive article with scroll, window/level, magnify and more features.
Available online at www.RadiologyCases.com

Published by EduRad



www.EduRad.org