


Pericardial hydatid cyst: The water lily sign as a classical sign in a nonclassical location

Israa Alsulami^{1*}, Reem Alwasiah¹, Mohammed Alsalman¹, Abdulmohsen Alyousef²

¹Department of Radiology, King Abdulaziz Medical City, National Guard Hospital, Riyadh, Saudi Arabia

²Department of Adult Cardiology, National Guard Health Affairs, Riyadh, Saudi Arabia

*Correspondence: Israa Alsulami, Department of Radiology, King Abdulaziz Medical City, National Guard Hospital, Riyadh, Saudi Arabia.

 alsulamiisraa@gmail.com

Radiology Case. 2023 Sep; 17(9):15-21 :: DOI: 10.3941/jrcr.v17i9.5152

ABSTRACT

Hydatid disease is a parasitic infection that usually targets the liver and is rarely seen affecting the heart. Herein, we present an incidentally diagnosed cardiac hydatid cyst with a pathognomonic radiological feature of a water lily sign.

CASE REPORT

CASE REPORT

The patient was a 40-year-old obese man (body mass index, 31 kg/m²), a smoker, and had no remarkable medical findings. The patient presented with sudden onset of central chest pain that was stabbing in nature and associated with a single episode of non-projectile vomiting, followed by shortness of breath and orthopnea for 1 day.

The patient denied any history of fever, weight loss, gastrointestinal, genitourinary, or neurological symptoms, as well as any history of medication use or allergies.

On examination, the patient appeared to be in mild respiratory distress. He was conscious and oriented. He was vitally stable and had the following characteristics of vital signs: oxygen saturation, 95% on nasal cannula; heart rate, 100–110 bpm; blood pressure, 110/70 mm Hg; and temperature, 37.8 °C.

Chest auscultation revealed bi-basilar crackles, with decreased air entry mainly on the right side. There were no other remarkable results.

Laboratory data showed highly elevated levels of troponin (855.1 pg/mL; normal, < 34.1 pg/mL), brain natriuretic peptide (107.9 pmol/L; normal, < 28.9 pmol/L), and white blood cell count (13 x 10⁹; normal range, 4–11 x 10⁹). Liver and renal function tests yielded normal results.

On electrocardiography, there was a wave inversion in the lead II, augmented vector foot, and subtle elevation of the posterior leads; hence, inferior infarction was suspected.

Chest x-ray showed bilateral atelectasis of the lower lobes with pleural effusion (Figure 1).

Initially, in the emergency room, transthoracic echocardiography was performed; there was a large mass/collection in the pericardial space at the left atrioventricular (AV) groove, causing compression of the mitral valve

(MV) annulus and, subsequently, mild-to-moderate mitral regurgitation; a small pericardial effusion was seen. There were no echocardiographic signs of cardiac tamponade.

The left ventricle was normal in size, with normal left ventricular wall thickness and motion. Left ventricular systolic function was normal. The ejection fraction was ≥ 55 mL. Transesophageal echocardiography and computed tomography (CT) were decided to be performed for better assessment. (Figure 2).

Chest CT scan shows a complex cystic-like cardiac lesion difficult to delineate from the left ventricular free wall measuring 6.4 x 5 cm with peripheral enhancement and an enhanced internal membrane, giving the characteristic appearance of a water lily sign. The lesion was in close proximity to the posterior mitral valve/annulus, though there was no evidence of left atrial dilation. A mild mass effect was exerted on the left ventricular free wall, and a trace of pericardial effusion was detected. There was no intrathoracic lymphadenomegaly. Moreover, there was more bilateral lower subsegmental atelectasis on the right side than on the left side. A small right-sided pleural effusion was also seen (Figure 3).

This prompted the authors to evaluate the rest of the body for other hydatid cysts. Abdomen CT demonstrated a few well-defined complex hepatic cysts with thin septation and some with mural calcification. The largest of these cysts were in segment II, measuring 4 x 5 x 4.8 cm (Figure 4).

However, the patient was not eligible for our healthcare service; the consensus was to give albendazole for 3 weeks and subsequently advised to undergo surgery for pericardial hydatid cyst evacuation if eligible. In case of emergency, the patient was advised to proceed to the emergency room immediately.

DISCUSSION

Hydatid disease is a parasitic infection caused by *Echinococcus granulosus* that can infect any organ in the body, and 75% of all hydatid cases involve the liver [1]. Although

cardiac involvement is rare at an incidence of 0.5–2%, it is potentially fatal.

Cardiac hydatid cyst commonly involves the left ventricle [2]; however, any component of the heart can be involved, and involvement depends on the location, size, and integrity of the cyst [3,4]. The pressure from the cyst over the myocardium can cause ventricular dysfunction, valvular obstruction, abnormal cardiac rhythm, and displacement of the coronary vasculature. Clinical presentation varies from chest pain, dyspnea, palpitations, cough, cardiogenic shock, and sudden cardiac death [5]. Therapy for cardiac echinococcosis depends on the size and location of the cysts and overall patient health; it involves surgery along with pharmacotherapy [6,7].

Herein, we present a case of an incidentally detected left ventricular wall hydatid cyst in which multiple hydatid cysts in the liver were then detected. As mentioned above, the clinical manifestations of cardiac hydatid disease depend on the size and site of cardiac involvement.

The most common location of myocardial hydatid cyst is in the left ventricular free wall (60%), followed by the right ventricle (15%), interventricular septum (9%), left atrium (8%), right atrium (4%), and interatrial septum (2%) [8].

The hydatid cyst grossly appears as three layers: the outermost layer is the pericyst, which is made by the reaction of the host tissue that encases the parasite, the middle is the laminated layer (ectocyst), and the innermost is the germinal layer (endocyst), which has the potential to germinate into daughter cysts [9,10]. If the laminated membrane is detached from the ectocyst, it will appear as a floating curvilinear structure within an intact pericyst, a phenomenon called the “water lily sign” [11].

An international ultrasound classification on echinococcosis proposed by the World Health Organization (WHO)-Informal Working Group on Echinococcosis (IWGE) based on morphology and activity (Figure 5) demonstrates the phases of a hydatid cyst from active (CE1) to inactive (CE5) [12].

Imaging techniques, including echocardiography, CT, and magnetic resonance imaging (MRI) scans, are essential for diagnosing hydatid cysts [10,13,14].

The initial and preferred modality to identify the numbers and borders of cardiac hydatid cysts is echocardiography, whereas CT or MRI scans can be used for mediastinal or visceral extension [15].

The findings of chest radiographs are usually nonspecific. Such lesions occasionally demonstrate cardiomegaly based on their size and location.

The hydatid cyst can be single, multiple, unilocular, multilocular, and thin or thick-walled. Occasionally, it may degenerate into solid masses, making it difficult to differentiate from cardiac tumors. There are findings characteristic of hydatid cysts, including the presence of daughter cysts, mural calcifications, and sloughed membrane [10,13,16]. The characteristic finding seen in our case is the visualization of

the membrane detachment called the “water lily sign.” The presence of the “water lily sign” is classified as a “transitional stage infection” between active and inactive disease based on the WHO-IWGE (Figure 5) [16].

Cardiac hydatid cysts need to be treated as soon as they are diagnosed to prevent lethal complications.

TEACHING POINT

A left ventricular wall lesion was diagnosed as a hydatid cyst with the presence of the pathognomonic water lily sign and other hydatid cysts in the liver. Cardiac hydatid cysts need to be treated as soon as they are diagnosed to prevent lethal complications.

KEYWORDS

Water lily sign; Cardiac hydatid cyst; Liver; Cardiac involvement; Echocardiography

ABBREVIATIONS

AV: Atrioventricular Groove; MV: Mitral Valve; CT: Computed Tomography; MRI: Magnetic Resonance Imaging

QUESTIONS

Question 1

Q1: What is the most commonly affected organ by hydatid cysts?

Answer choice 1: Heart

Answer choice 2: Brain

Answer choice 3: Colon

Answer choice 4: Liver (applies)

Answer choice 5: Gallbladder

Explanation for question 1:

Hydatid disease is a parasitic infection caused by *Echinococcus granulosus* that can infect any organ in the body, and 75% of all hydatid cases involve the liver.

Q2: Which cardiac chamber do hydatid cysts commonly involve?

Answer choice 1: Left ventricle (applied)

Answer choice 2: Right ventricle

Answer choice 3: Right atrium

Answer choice 4: Left atrium

Answer choice 5: Atrioventricular groove

Explanation for question 2: Cardiac hydatid cyst commonly involves the left ventricle; however, it may involve any chamber according to the size of the cyst.

Q3: Water lily sign is:

Answer choice 1: Mural calcification

Answer choice 2: Detachment of the laminated membrane from the ectocyst (applied)

Answer choice 3: Nodular peripheral enhancement

Answer choice 4: Detachment of the ectocyst from the pericyst

Answer choice 5: Thick peripheral enhancement

Explanation of question 3:

If the laminated membrane is detached from the ectocyst, it will appear as a floating curvilinear structure within an intact pericyst, a phenomenon called the “water lily sign.”

Q4: What is the initial modality of choice for the evaluation of cardiac hydatid cysts?

Answer choice 1: Echocardiogram (applied)

Answer choice 2: CT

Answer choice 3: MRI

Answer choice 4: PET scan

Answer choice 5: Chest x-ray

Explanation for question 4: The initial and preferred modality to identify the numbers and borders of cardiac hydatid cysts is echocardiography, whereas CT or MRI scans can be used for mediastinal or visceral extension.

Q5: Which of the following statements are true:

1. Cardiac hydatid cysts can be managed conservatively.
2. Cardiac hydatid cysts can be lethal and should be managed promptly (applied).
3. Cardiac hydatid cysts are not as serious as hepatic hydatid cysts.
4. Cardiac hydatid cysts are only dangerous if they affect the right atrium.
5. Cardiac hydatid cysts are not worrisome and watchful waiting can be done.

Explanation for question 5: Although cardiac involvement is rare at an incidence of 0.5–2% it is potentially fatal. The pressure from the cyst over the myocardium can cause ventricular dysfunction, valvular obstruction, abnormal cardiac rhythm, and displacement of the coronary vasculature. Clinical presentation varies from chest pain, dyspnea, palpitations, cough, cardiogenic shock, and sudden cardiac death.

AUTHOR CONTRIBUTIONS

Israa Alsulami: Review of literature and case presentation.

Reem Alwasiah: Gathering and editing the diagnostic medical imaging.

Mohammed Alsalman: Discussion and supervision of the case report.

Abdulmohsen Alyousef: Editing the echocardiogram.

HUMAN AND ANIMAL RIGHTS

This case report was conducted in accordance with the ethical standards of the Helsinki Declaration of 1975, as revised in 2000.

REFERENCES

1. Hegde N, Hiremath B. Primary peritoneal hydatidosis. *BMJ Case Rep.* 2013; 2013(bcr2013200435).
2. Shojaei E, Yassin Z, Reza Hosseini O. Cardiac hydatid cyst: a case report. *Iran J Public Health.* 2016; 45(11): 1507-1510.
3. Bogdanovic A, Radojkovic M, Tomasevic RJ, et al. Presentation of pericardial hydatid cyst as acute cardiac tamponade. *Asian J Surg.* 2017; 40(2): 175-177. PMID: 24393813.
4. Agha RA, Fowler AJ, Rajmohan S, Barai I, Orgill DP, PROCESS group. The PROCESS statement: preferred reporting of case series in surgery. *Int J Surg.* 2016; 36(Pt A): 319-323. PMID: 27770639.
5. El Boussaadani B, Regragui H, Bouhdadi H, et al. Primary cardiac hydatid cyst presenting with massive pericardial effusion: a case report. *Egypt Heart J.* 2020; 72(1): 51. PMID: 32804331.
6. Gula G, Luisi VS, Machado F, Yacoub M. Hydatid cyst of the heart. Clinical and surgical implications. *Thorac Cardiovasc Surg.* 1979; 27(6): 393-396. PMID: 542947.
7. Firouzi A, Neshati Pir Borj M, Alizadeh Ghavidel A. Cardiac hydatid cyst: a rare presentation of echinococcal infection. *J Cardiovasc Thorac Res.* 2019; 11(1): 75-77. PMID: 31024677.
8. Aswani Y, Hira P. Cardiac hydatid cyst. *Pol J Radiol.* 2018; 83: e160.
9. Yaliniz H, Tokcan A, Salih OK, Ulus T. Surgical treatment of cardiac hydatid disease: a report of 7 cases. *Tex Heart Inst J.* 2006; 33(3): 333-339. PMID: 17041691.
10. Moghul D, Hamidi H. Incidental finding of cardiac hydatid cysts, report of two cases. *BMC Med Imaging.* 2018; 18(1): 22. PMID: 30103678.
11. Dursun M, Terzibasoglu E, Yilmaz R, et al. Cardiac hydatid disease: CT and MRI findings. *AJR Am J Roentgenol.* 2008; 190(1): 226-232. PMID: 18094316.
12. Durr-e-Sabih SZ, Sabih Z, Khan AN. “Congealed waterlily” sign: a new sonographic sign of liver hydatid cyst. *J Clin Ultrasound.* 1996; 24(6): 297-303.
13. WHO. IWGE. Puncture, aspiration, injection, re-aspiration: an option for the treatment of cystic echinococcosis, whqlibdoc.who.int/hq/2001/WHO_CDS_CSRAPH_2001.6.pdf; 2001. Available from: WHO/CDS/CSR/APH/2001.6. Geneva: WHO.
14. Mehra S, Garga UC. Left ventricular myocardial hydatid cyst. *Appl Radiol.* 2018; 47(6): 36-38.
15. Di Bello et al., 1964; Tefera et al., 2017; Fennira et al., 2019; Wadhawa et al. Alis and Turna, 2018; Agarwal et al., 2018
16. Petik B, Hazirolan T, Uysal G, Erturk SM. Cardiac hydatid cysts: computed tomography and magnetic resonance imaging findings of the 5 cases. *J Comput Assist Tomogr.* 2015; 39(5): 816-819. PMID: 26196344.

FIGURES

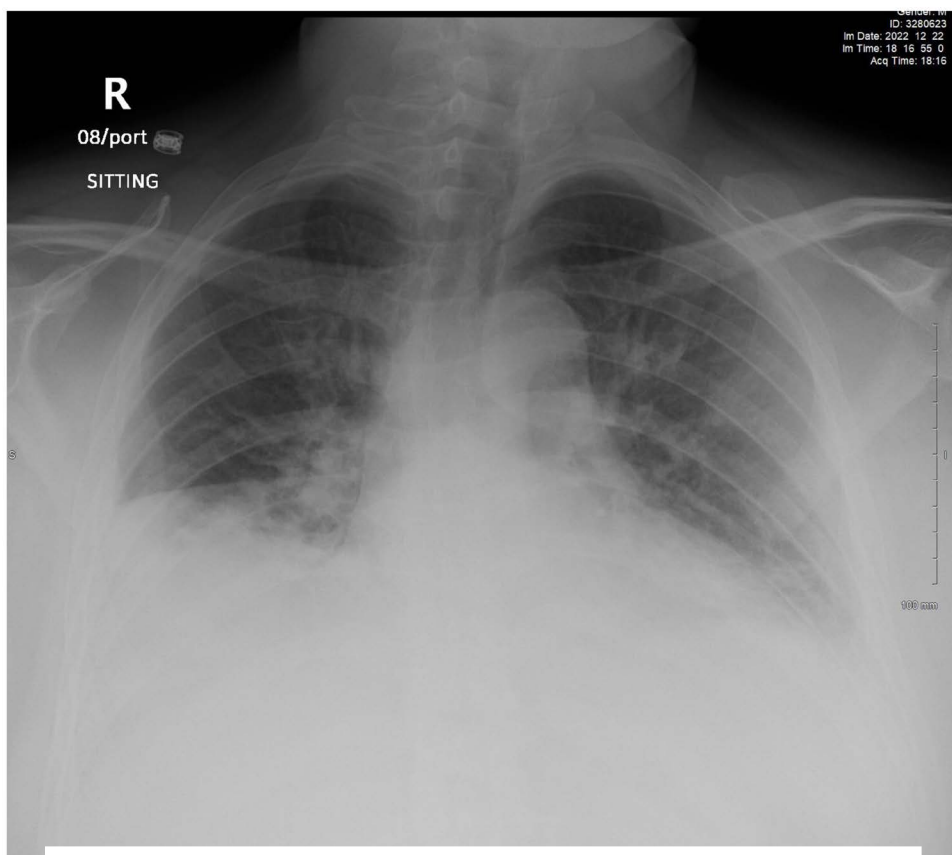


Figure 1. Chest X-ray shows bilateral lower lobes atelectasis with pleural effusion

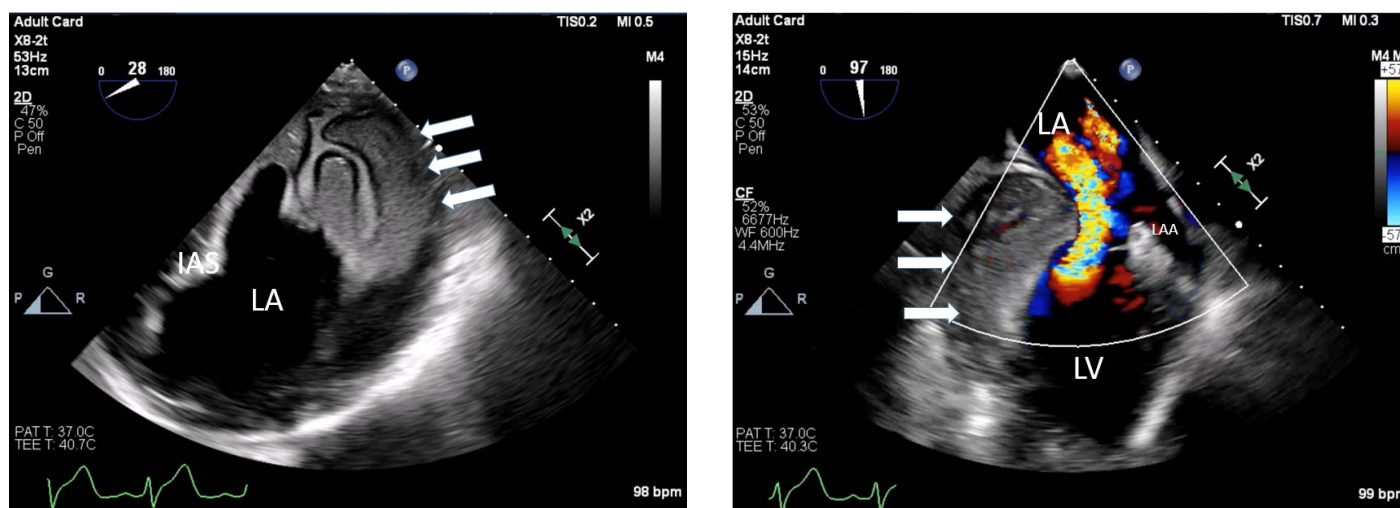


Figure 2. Transesophageal echocardiography (A and B) shows a collection in the pericardial space at the left atrioventricular (AV) groove compressing the posterior mitral valve (MV) annulus, causing distortion of the MV and moderate-to-severe eccentric mitral regurgitation.

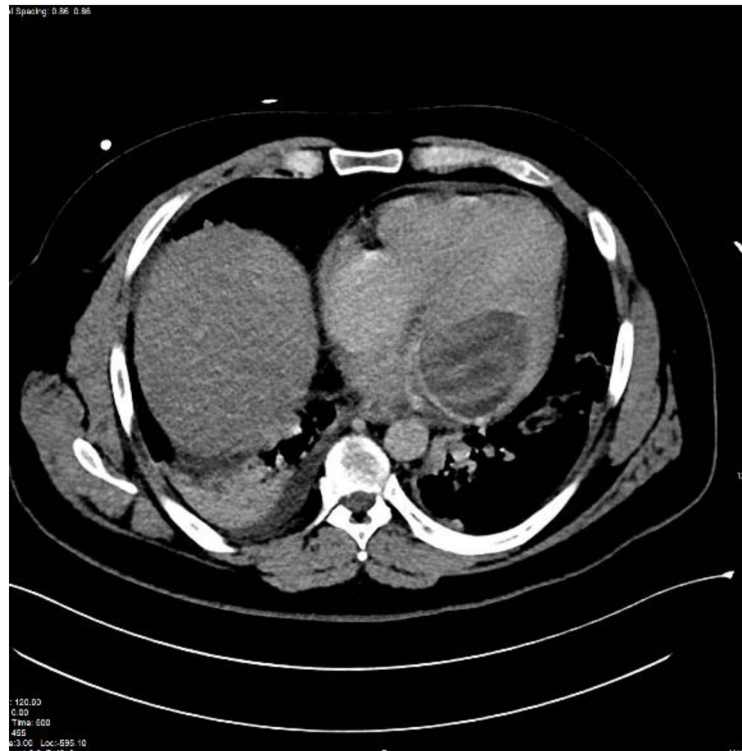


Figure 3. Contrast-enhanced computed tomography imaging of the chest
Cross-sectional imaging on axial view shows a complex cystic lesion in the left ventricular free wall, with peripheral enhancement and an internal detached membrane, giving the appearance of a water lily sign. Bilateral lower sub-segmental atelectasis was seen more on the right side than on the left side. A small right-sided pleural effusion is seen as well.

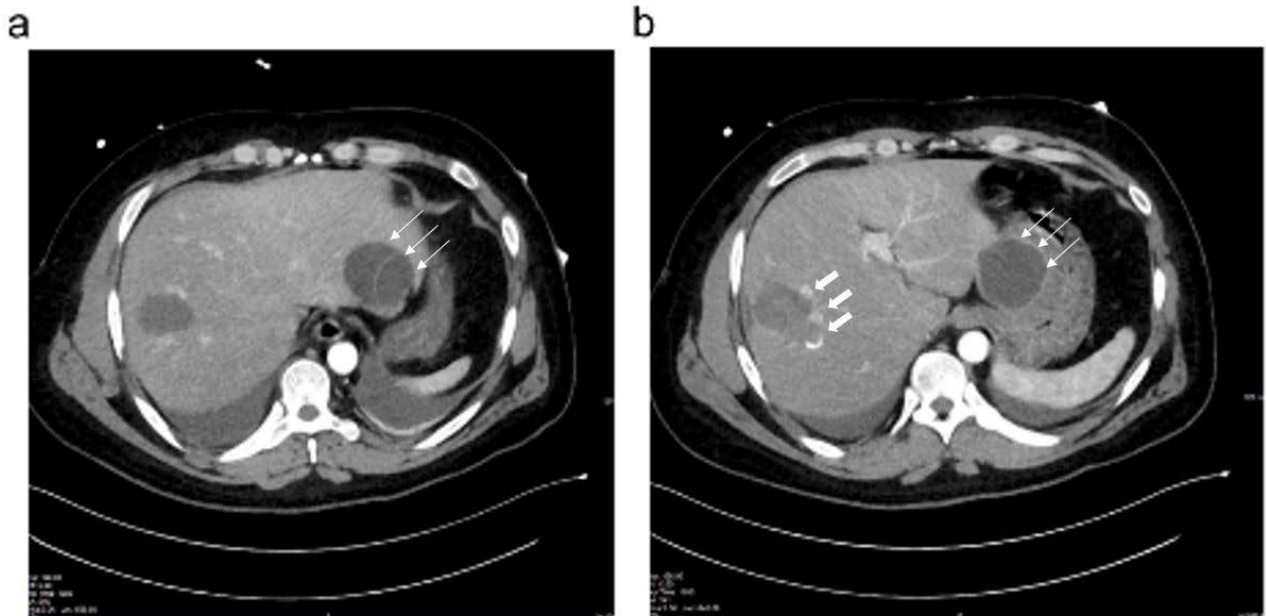


Figure 4. Contrast-enhanced computed tomography of the abdomen
Cross-sectional imaging on axial view demonstrates multiple well-defined complex hepatic cysts, with thin septation (arrow) and some with mural calcification (block arrow).

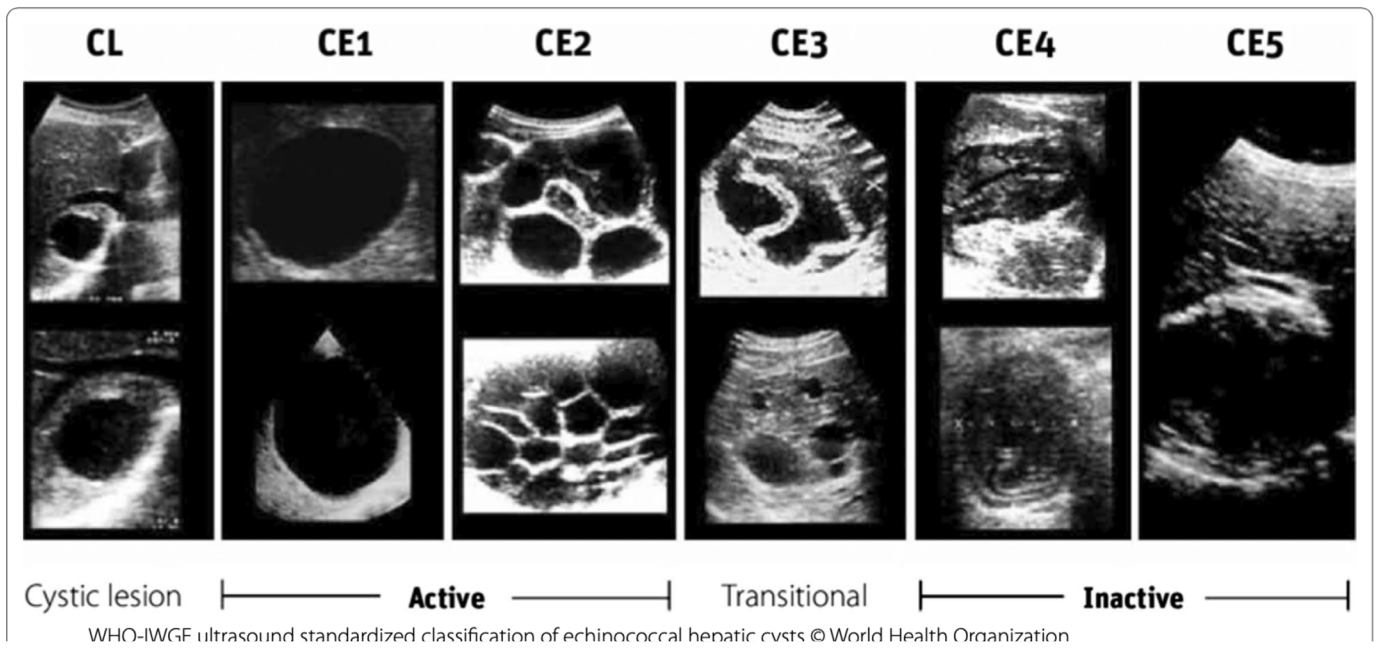


Figure 5. WHO-IWGE ultrasound standardized classification of echinococcal hepatic cysts
WHO-IWGE, World Health Organization-Informal Working Group on Echinococcosis

Online access

This publication is online available at:
www.radiologycases.com/index.php/radiologycases/article/view/5152

Peer discussion

Discuss this manuscript in our protected discussion forum at:
www.radiopolis.com/forums/JRCR

Interactivity

This publication is available as an interactive article with scroll, window/level, magnify and more features.
Available online at www.RadiologyCases.com

Published by EduRad



www.EduRad.org