

Descending necrotizing mediastinitis secondary to retropharyngeal abscess

Sarah M. Nwia, MS*, Christian D. Huebner, MD, Jeremy B. Nguyen, MD, FACR

1. Department of Radiology, Tulane University School of Medicine, New Orleans, USA

*Correspondence: Sarah Nwia, Tulane University School of Medicine, 1430 Tulane Ave, #8654, New Orleans, LA 70112, USA

✉ snwia@tulane.edu

Radiology Case. 2023 Aug; 17(8):21-28 :: DOI: 10.3941/jrcr.v17i8.5095

ABSTRACT

We report a case of descending necrotizing mediastinitis (DNM) in a 68-year-old male who presented in acute respiratory distress accompanied with anterior cervical neck swelling and pain with swallowing. Contrast enhanced computed tomography (CECT) of the neck demonstrated a large, peripherally enhancing retropharyngeal fluid and air collection that appeared to communicate with a fluid and air collection within the mediastinum. CECT of the chest demonstrated punctate foci of air and fat stranding along the anterior and superior mediastinum. Radiological evidence and the presence of necrosis on surgical debridement of the retropharyngeal abscess established the diagnosis of DNM. This case emphasizes the role of computed tomography (CT) in the diagnosis of DNM and demonstrates the utility of chest imaging in a high-risk patient who presents with a retropharyngeal abscess.

CASE REPORT

CASE REPORT

Initial presentation

A 68-year-old male with a past medical history of laryngeal cancer status post radiation therapy and resection, glaucoma, and hypertension presented to the emergency room with a six-day history of anterior neck swelling. He was initially diagnosed at another hospital with a laryngeal abscess and discharged on oral clindamycin.

Subsequent developments

When his symptoms did not improve, he returned with complaints of neck pain and pain with swallowing (odynophagia). Laryngoscope exam showed decreased left true vocal fold mobility and pooling of secretions. Computed tomography (CT) showed a progressive fluid and air collection along the anterior and posterior thyroid cartilage. He was started on intravenous antibiotics and steroids before he underwent translaryngeal drainage of the fluid collection. The patient left the hospital against medical advice the following day.

Final Presentation

After four days, he returned to the emergency room in acute respiratory distress with worsening anterior neck swelling. Physical exam showed posterior pharyngeal edema and stridor, in addition to subcutaneous emphysema along the

neck. Laboratory values were significant for a white blood cell count of 41.4. Laryngoscope exam demonstrated diffuse pharyngeal swelling and pooling of secretions. He was taken to the operating room for emergent tracheostomy and incision and drainage, during which diffuse necrosis was noted.

CT images of the head and neck demonstrated extensive air and soft tissue fluid collections adjacent to the tracheostomy. These collections involved the perivertebral spaces, the retropharyngeal space, and the deep spaces of the neck with extension downward into the anterior and middle mediastinum. Considering the mediastinal involvement of the infection, cardiothoracic surgery was consulted and determined that surgical intervention was not necessary at the time.

DISCUSSION

Clinical Presentation and Epidemiology

Descending necrotizing mediastinitis was first described by Pearse in 1938 as an infection of the head or neck that courses inferiorly along the fascial planes into the mediastinum [1]. Its incidence has been difficult to characterize, and there are no definitive studies demonstrating age and sex predilection. The most commonly presenting symptoms include odynophagia, cervical pain, cervical swelling, and dyspnea. Nonspecific signs of inflammation are also typically present, such as fever,

chills, and tachycardia. Physical exam findings might include Hamman's sign and stridor. Hamman's sign is a crunching sound that accompanies each heartbeat and stridor indicates that there is a risk for airway compromise [2]. Laboratory findings are typically nonspecific but include an increased white blood cell count (leukocytosis) and elevated inflammatory markers. There may be a progressive decrease in the platelet count (thrombocytopenia) and signs of disseminated intravascular coagulation present [3]. The patient described in this case presented with all the most common symptoms - odynophagia, cervical pain, cervical swelling, and respiratory distress. On physical exam, Hamman's sign was not appreciated, but stridor was present, likely secondary to laryngeal edema.

Risk factors beyond sternotomy include immunocompromised state, diabetes, oral glucocorticoid use, and reduced tissue oxygenation [4]. This patient had undergone radiation therapy in the past, which has several long-term complications that serve as risk factors for his presentation. For example, radiation therapy can cause irreversible damage to salivary gland cells causing a permanent loss of salivary gland function and a reduction in local immune function. Saliva serves as a physical barrier and secretes IgA, which helps fight mucosal infections. Without it, dental carries and local infections are more likely to occur. Another long-term complication of radiation therapy includes tissue fibrosis, which can lead to reduced vascularity and decreased tissue oxygenation [5]. Finally, the extended duration of the infection and incomplete intravenous antibiotic course during his second admission may have contributed to the spread of the infection into the mediastinum.

The most common etiologies of DNM include odontogenic infections, pharyngitis, and trauma. Lymph from these infection sites drains into the retropharyngeal lymph nodes, which can rupture and create an abscess. Retropharyngeal abscesses present an increased risk of DNM due to their proximity to the danger space, which is a potential space posterior to the ala fascia that communicates with the upper mediastinum [6]. The abscesses are typically polymicrobial, containing both aerobic and anaerobic bacteria [7-9]. If the patient presentation suggests DNM, imaging studies are a useful diagnostic tool.

Imaging Features

Imaging studies can better characterize and grade DNM, while providing information for surgical planning. Grading is based on the local spread of the infection and consists of three types. Type I is localized above the carina. Type IIa extends into the anterior mediastinum, and Type IIb extends into both the anterior and posterior mediastinum [10]. Plain radiograph findings are typically nonspecific, with the most common finding being mediastinal widening, which is more prominent at the superior aspect. In some cases, air can be visualized in the mediastinum and subcutaneous tissue. Pleural effusions may or may not be present, as well [11]. Contrast-enhanced computed tomography (CECT) is the gold standard for diagnosing DNM as it is highly sensitive and specific. CT findings can include lymphadenopathy, fluid collections with an enhancing wall, gas

locules, and signs of inflammation such as fat stranding and edema [11,12]. For this patient, there was evidence of infection in the anterior and superior mediastinum, classifying this as a Type IIa DNM. Neck imaging may demonstrate a descension of the infection into the mediastinum, as seen in this case.

Differential Diagnosis

Although imaging studies are critical to diagnosing DNM, diagnosis also requires clinical evidence of a serious oropharyngeal infection, evidence of necrosis during surgery or autopsy, and a relationship between the mediastinitis and oropharyngeal infection [13]. In this case, the retropharyngeal abscess and the descension of the emphysema and fluid into the mediastinum on CECT of the neck was an important indicator that the mediastinitis was caused by a descending infection. Severe necrosis was noted on incision and drainage of the retropharyngeal abscess, further strengthening the diagnosis. In the absence of a history of cardiac surgery, the differential diagnosis of acute mediastinitis includes esophageal perforation.

1. Esophageal Perforation:

Esophageal perforation is another rare, but life-threatening cause of acute mediastinitis that is estimated to affect about 3.1/million people annually [14]. The classic presentation is a male over the age of 60 who presents with the Mackler's triad: vomiting, chest pain, and subcutaneous emphysema. The most common etiologies are iatrogenic, particularly when an esophageal dilation procedure has been performed, and intense vomiting, known as Boerhaave's syndrome. Other less common etiologies include trauma and other activities that increase intraabdominal pressure. Risk factors associated with perforation during upper endoscopy include advanced age, a history of difficult intubation, and the presence of large cervical osteophytes [15]. Plain radiographs show similar nonspecific findings to DNM, including pneumomediastinum, subcutaneous emphysema, mediastinal widening, pleural effusions, and abscess formation. CECT of the chest can demonstrate esophageal thickening, signs of inflammation, and, if oral contrast can be tolerated, contrast extravasation. Treatment can be either surgical repair or medical management of mediastinal inflammation and infection, and mortality rates are estimated to be about 20% [16,17].

In this case, the patient's primary complaint upon initial presentation was cervical swelling and odynophagia, rather than chest pain, and he denied any recent history of forceful vomiting. He was previously diagnosed with a laryngeal abscess and radiological studies showed descension of the infection into the mediastinum. Additionally, significant necrosis was noted on retropharyngeal incision and drainage, which further strengthened the diagnosis of DNM.

Prognosis and Treatment

Once the diagnosis of DNM is established, expeditious treatment is critical to optimize prognosis. Even with advances in care such as IV antibiotics and surgical debridement, one meta-analysis estimated that the mortality of DNM to be 17.5%

[18]. Prognosis depends heavily on time to diagnosis and drainage, age, and DNM grade.

The two goals of treatment include source control and surgical debridement. Currently, there are no guidelines for antibiotic treatment, but empiric treatment with aerobic and anaerobic coverage is usually accomplished with a third-generation cephalosporin and metronidazole or piperacillin/tazobactam and clindamycin [18,19]. The surgical approach used is dependent on the grade and severity of the infection. Incision and drainage of the causative lesion and upper mediastinum requires cervicotomy, which is an anterior approach through the neck. Involvement of the anterior mediastinum is an indication for a median sternotomy or anterolateral thoracotomy. The posterior mediastinum can be accessed via a posterolateral thoracotomy, but a clamshell thoracotomy exposes the entire mediastinum and both pleural cavities and serves as a better option for Type IIb DNM [20]. An early tracheotomy protects the airway and opens the fascial planes in the neck, encouraging resolution of the infection [21]. The patient described in this case report had a complicated hospital course which included two additional incision and drainage procedures and a gastrostomy tube placement. Cardiothoracic surgery deferred mediastinal debridement and the patient received a course of IV antibiotics. Biopsies of a suspicious lesion taken during the repeat procedure demonstrated invasive laryngeal cancer. The patient received a course of Zosyn and elected to be discharged home while awaiting a total laryngectomy with pectoralis flap. Before discharge, his symptoms and laboratory work demonstrated improvement of the infection.

This case demonstrates the utility of CT imaging in diagnosing DNM and encourages the consideration of chest imaging in a high-risk patient who presents with a retropharyngeal abscess. Radiographic evidence can help characterize the infection and identify a connection between the retropharyngeal and mediastinal foci, which is a key component of diagnosis. Determining if the retropharyngeal infection has infiltrated the mediastinum is critical information that helps guide the treatment approach.

Teaching Point

Descending necrotizing mediastinitis is a life-threatening condition that presents as respiratory distress, odynophagia, cervical pain and swelling, and subcutaneous emphysema. Chest imaging should be considered in patients that present with retropharyngeal abscesses, particularly if they are at increased risk for developing DNM. Expedient diagnosis and treatment can be facilitated by CECT, which typically shows lymphadenopathy, signs of inflammation, fluid collections, pneumomediastinum, and evidence of communication with a head or neck infection.

QUESTIONS

Question: Which of the following has not been demonstrated to increase a person's risk for developing descending necrotizing mediastinitis?

1. Uncontrolled HIV infection
2. Prednisone use
3. Previous abdominal surgery (applies)
4. Sternotomy
5. Diabetes Mellitus

Explanation:

[Risk factors beyond sternotomy include immunocompromised state, diabetes, oral glucocorticoid use, and reduced tissue oxygenation [4].]

Question: Which of the following are typically components of DNM antimicrobial therapy?

6. Gentamicin
7. Metronidazole (applies)
8. Piperacillin/Tazobactam (applies)
9. Clindamycin (applies)
10. Third Generation Cephalosporins (applies)

Explanation:

[Currently, there are no guidelines for antibiotic treatment, but empiric treatment with aerobic and anaerobic coverage is usually accomplished with a third-generation cephalosporin and metronidazole or piperacillin/tazobactam and clindamycin [18,19].]

Question: Which of the following imaging findings are more characteristic of esophageal perforation than DNM?

1. Esophageal thickening (applies)
2. Pleural effusions
3. Pneumomediastinum
4. Oral contrast extravasation (applies)
5. Fat stranding

Explanation:

1. Esophageal thickening (applies) *[[With esophageal perforation]* CECT of the chest can demonstrate esophageal thickening, signs of inflammation, and, if oral contrast can be tolerated, contrast extravasation.]
2. Pleural effusions *[[With DNM,]* Plain radiograph findings are typically nonspecific... Pleural effusions may or may not be present, as well [11].] *[[With esophageal perforation]* Plain radiographs show similar nonspecific findings to DNM, including pneumomediastinum, subcutaneous emphysema, mediastinal widening, pleural effusions, and abscess formation.]
3. Pneumomediastinum *[Plain radiographs show similar nonspecific findings to DNM, including pneumomediastinum, subcutaneous emphysema, mediastinal widening, and abscess formation.]*
4. Oral contrast extravasation *[[With esophageal perforation]* CECT of the chest can demonstrate esophageal thickening, signs of inflammation, and, if oral contrast can be tolerated, contrast extravasation.]
5. Fat stranding *[[With DNM,]* CT findings can include lymphadenopathy, fluid collections with an enhancing wall, gas locules, and signs of inflammation such as fat stranding and edema [11,12].] *[[With esophageal perforation,]* CECT of the chest can demonstrate esophageal thickening, signs of inflammation, and, if oral contrast can be tolerated, contrast extravasation.]

Question: What are the four criteria outlined by Estrera et al. that are required to make a diagnosis of descending necrotizing mediastinitis?

1. Serious oropharyngeal infection (applies)
2. Evidence of necrosis during surgery or autopsy (applies)
3. Mediastinal abscess formation
4. Characteristic findings on diagnostic imaging (applies)
5. A relationship between the mediastinitis and oropharyngeal infection (applies)

Explanation: [Diagnosis of DNM requires clinical evidence of a serious oropharyngeal infection, evidence of necrosis during surgery or autopsy, characteristic findings on diagnostic imaging, and relationship between the mediastinitis and oropharyngeal infection.]

Question: Which of the following statements is false?

1. The mortality rate of DNM is estimated to be over 15%, even with medical intervention.
2. Patients typically present with odynophagia, dyspnea, and neck swelling.
3. Physical findings in DNM might include Hamman's sign and stridor.
4. Plain radiograph findings in descending necrotizing mediastinitis are diagnostic. (applies)
5. Mackler's triad consists of vomiting, chest pain, and subcutaneous emphysema.

Explanation:

1. The mortality rate of DNM is estimated to be over 15%, even with medical intervention. [Even with advances in care such as IV antibiotics and surgical debridement, one meta-analysis estimated that the mortality of DNM to be 17.5% [18].]
2. Patients typically present with odynophagia, dyspnea, and neck swelling. [The most commonly presenting symptoms include odynophagia, cervical pain, cervical swelling, and dyspnea.]
3. Physical findings in DNM might include Hamman's sign and stridor. [Physical exam findings might include Hamman's sign and stridor. Hamman's sign is a crunching sound that accompanies each heartbeat and stridor indicates that there is a risk for airway compromise [2].]
4. Plain radiograph findings in descending necrotizing mediastinitis are diagnostic. [Plain radiograph findings are typically nonspecific, with the most common finding being mediastinal widening, which is more prominent at the superior aspect.]
5. Mackler's triad consists of vomiting, chest pain, and subcutaneous emphysema. [The classic presentation [for Boerhaave syndrome] is a male over the age of 60 who presents with the Mackler's triad: vomiting, chest pain, and subcutaneous emphysema.]

AUTHORS' CONTRIBUTIONS

The authors confirm contribution to the paper as follows: study conception: C. Huebner, data analysis: C. Huebner, J. Nguyen, manuscript preparation: S. Nwia, C. Huebner. All

authors reviewed the results and approved the final version of the manuscript.

DISCLOSURES

No disclosures to declare.

CONSENT

Consent was not obtained by the patient. No identifying information accompanies the case report.

REFERENCES

1. Pearse HE. MEDIASTINITIS FOLLOWING CERVICAL SUPPURATION. *Ann Surg.* 1938; 108(4): 588-611. PMID: 17857255.
2. Ridder GJ, Maier W, Kinzer S, Teszler CB, Boedeker CC, Pfeiffer J. Descending necrotizing mediastinitis: contemporary trends in etiology, diagnosis, management, and outcome. *Ann Surg.* 2010; 251(3): 528-534. PMID: 19858699.
3. Vieira F, Allen SM, Stocks RMS, Thompson JW. Deep Neck Infection. *Otolaryngologic Clinics of North America.* 2008; 41(3): 459-483. PMID: 18435993.
4. Pastene B, Cassir N, Tankel J, et al. Mediastinitis in the intensive care unit patient: a narrative review. *Clin Microbiol Infect.* 2020; 26(1): 26-34. PMID: 31306791.
5. Brook I. Late side effects of radiation treatment for head and neck cancer. *Radiat Oncol J.* 2020; 38(2): 84-92. PMID: 33012151.
6. Guidera AK, Dawes PJD, Fong A, Stringer MD. Head and neck fascia and compartments: No space for spaces. *Head Neck.* 2014; 36(7): 1058-1068. PMID: 23913739.
7. Celakovsky P, Kalfert D, Smatanova K, et al. Bacteriology of deep neck infections: analysis of 634 patients. *Aust Dent J.* 2015; 60(2): 212-215. PMID: 25988277.
8. Har-El G, Aroesty JH, Shaha A, Lucente FE. Changing trends in deep neck abscess. A retrospective study of 110 patients. *Oral Surg Oral Med Oral Pathol.* 1994; 77(5): 446-450. PMID: 8028865.
9. Wang LF, Kuo WR, Tsai SM, Huang KJ. Characterizations of life-threatening deep cervical space infections: A review of one hundred ninety-six cases. *Am J Otolaryngol.* 2003; 24(2): 111-117. PMID: 12649826.
10. Endo S, Murayama F, Hasegawa T, et al. Guideline of surgical management based on diffusion of descending necrotizing mediastinitis. *Jpn J Thorac Cardiovasc Surg.* 1999; 47(1): 14-19. PMID: 10077888.
11. Akman C, Kantarci F, Cetinkaya S. Imaging in mediastinitis: a systematic review based on aetiology. *Clin Radiol.* 2004; 59(7): 573-585. PMID: 15208062.
12. Exarhos DN, Malagari K, Tsatalou EG, et al. Acute mediastinitis: spectrum of computed tomography findings. *Eur Radiol.* 2005; 15(8): 1569-1574. PMID: 15627194.

13. Estrera AS, Landay MJ, Grisham JM, Sinn DP, Platt MR. Descending necrotizing mediastinitis. *Surg Gynecol Obstet.* 1983; 157(6): 545-552. PMID: 6648776.
14. Vidarsdottir H, Blondal S, Alfredsson H, Geirsson A, Gudbjartsson T. Oesophageal perforations in Iceland: a whole population study on incidence, aetiology and surgical outcome. *Thorac Cardiovasc Surg.* 2010; 58(8): 476-480. PMID: 21110271.
15. Das A, Sivak MV, Chak A. Cervical esophageal perforation during EUS: A national survey. *Gastrointest Endosc.* 2001; 53(6): 599-602. PMID: 11323585.
16. Søreide JA, Viste A. Esophageal perforation: diagnostic work-up and clinical decision-making in the first 24 hours. *Scand J Trauma Resusc Emerg Med.* 2011; 19: 66. PMID: 22035338.
17. Wei CJ, Levenson RB, Lee KS. Diagnostic Utility of CT and Fluoroscopic Esophagography for Suspected Esophageal Perforation in the Emergency Department. *AJR Am J Roentgenol.* 2020; 215(3): 631-638. PMID: 22035338.
18. Prado-Calleros HM, Jiménez-Fuentes E, Jiménez-Escobar I. Descending necrotizing mediastinitis: Systematic review on its treatment in the last 6 years, 75 years after its description. *Head Neck.* 2016; 38Suppl 1: E2275-E2283. PMID: 26829352.
19. Gunaratne DA, Tseros EA, Hasan Z, et al. Cervical necrotizing fasciitis: Systematic review and analysis of 1235 reported cases from the literature. *Head Neck.* 2018; 40(9): 2094-2102. PMID: 29934952.
20. Son HS, Cho JH, Park SM, Sun K, Kim KT, Lee SH. Management of descending necrotizing mediastinitis using minimally invasive video-assisted thoracoscopic surgery. *Surg Laparosc Endosc Percutan Tech.* 2006; 16(6): 379-382. PMID: 17277652.
21. Abu-Omar Y, Kocher GJ, Bosco P, et al. European Association for Cardio-Thoracic Surgery expert consensus statement on the prevention and management of mediastinitis. *Eur J Cardiothorac Surg.* 2017; 51(1): 10-29. PMID: 28077503.

FIGURES

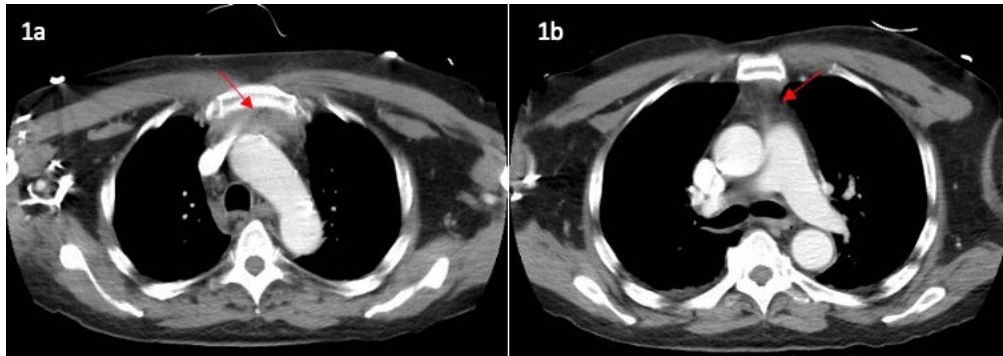


Figure 1: 68-year-old male with descending necrotizing mediastinitis.
FINDINGS: Axial CT of the chest demonstrating (1a) punctate foci of air along the anterior/superior mediastinum with (1b) fat stranding noted in the anterior mediastinum without evidence of a discrete fluid collection.
TECHNIQUE: Axial CT Chest, 557 mAs, 120 kV, 5.0 mm slice thickness, 85 mL ISOVUE-300

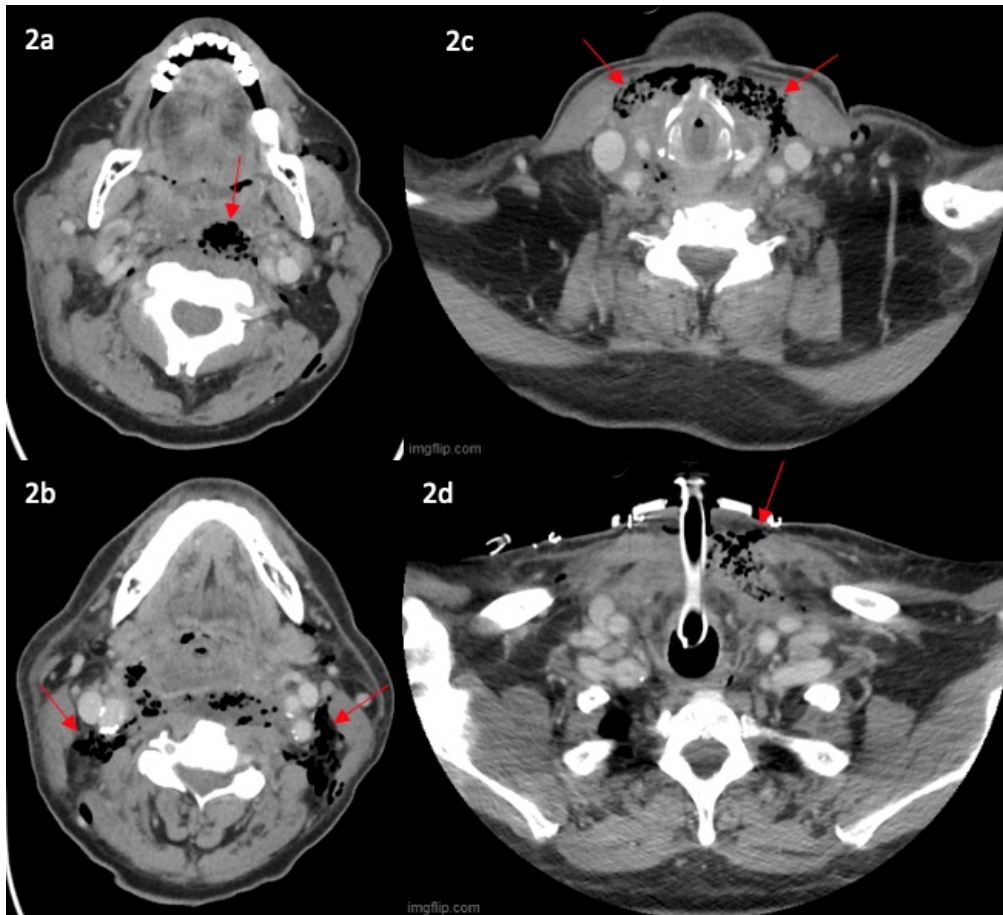


Figure 2: 68-year-old male with descending necrotizing mediastinitis.
FINDINGS: A. Axial CT of the neck demonstrating (2a) a large peripherally enhancing fluid and air-filled collection in the retropharyngeal space measuring 7.0 x 2.1 x 3.4 cm, (2b) extensive subcutaneous emphysema tracking inferolaterally along the posterior cervical spaces, parotid spaces, and masticator spaces, left greater than right, and (2c) a 7.5 x 6.4 x 1.6 cm collection of fluid and gas posterior to the platysma muscles bilaterally and (2d) in the location of recent tracheostomy, which appears to communicate with the retropharyngeal collection with communication into the anterior mediastinum.
TECHNIQUE: Axial CT Neck, 282 mAs, 120 kV, 2.5 mm slice thickness, 85 mL ISOVUE-300

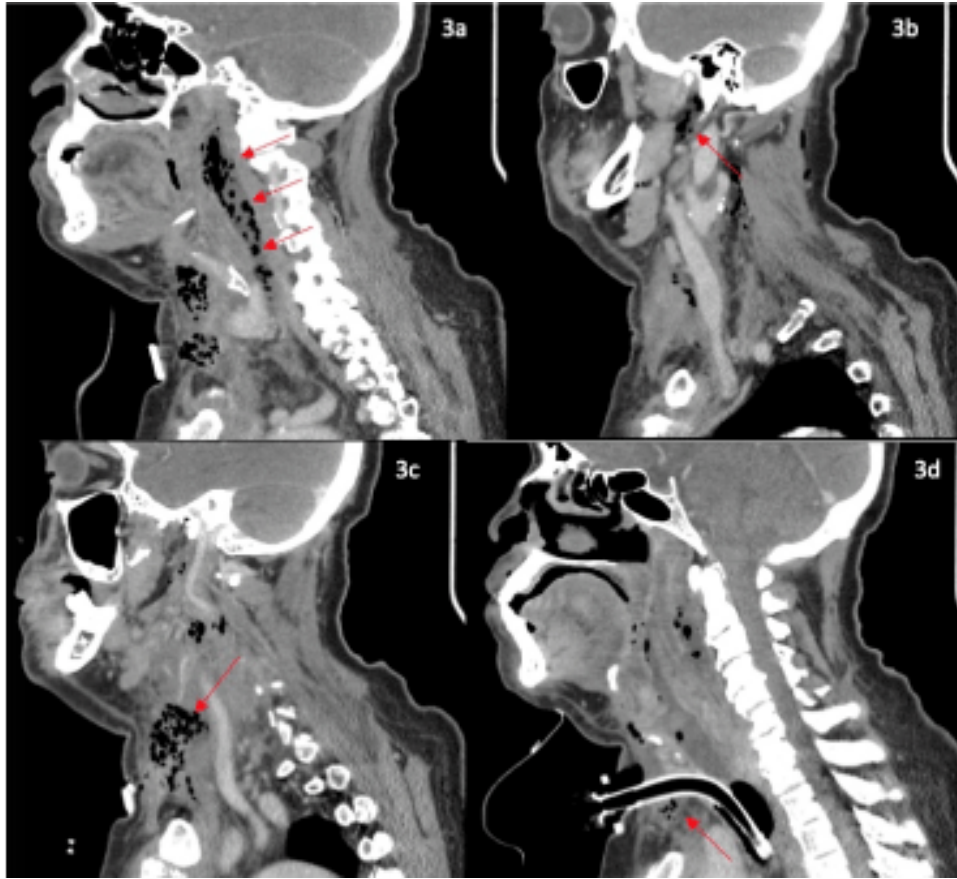


Figure 3: 68-year-old male with descending necrotizing mediastinitis.
FINDINGS: Sagittal contrast enhanced CT of the neck demonstrating (3a) a large peripherally enhancing fluid and air-filled collection in the retropharyngeal space measuring 7.0 x 2.1 x 3.4 cm, (3b) extensive subcutaneous emphysema tracking inferolateral along the posterior cervical spaces, parotid spaces, and masticator spaces, left greater than right, (3c) a 7.5 x 6.4 x 1.6 cm collection of fluid and gas posterior to the platysma muscles bilaterally and (3d) in the location of recent tracheostomy, which appears to communicate with the retropharyngeal collection with communication into the anterior mediastinum.
TECHNIQUE: Sagittal CT Neck, reconstruction, 1.25 mm slice thickness

Journal of Radiology Case Reports

www.RadiologyCases.com

Summary table:

Etiology	Odontogenic infection, pharyngitis, trauma
Incidence	Unknown
Gender Ratio	Unknown
Age Predilection	Unknown
Risk Factors	immunocompromised state, diabetes, oral glucocorticoid use, sternotomy, reduced tissue oxygenation
Treatment	Antibiotics, surgical drainage
Prognosis	Fair
Imaging Findings	Xray: superior mediastinal widening, pneumomediastinum, subcutaneous emphysema, pleural effusions CECT: lymphadenopathy, fluid collections with an enhancing wall, gas locules, fat stranding, edema

Differential table:

Diagnosis	Risk Factors	Xray Findings	CT Findings
Descending Necrotizing Mediastinitis	immunocompromised state, diabetes, oral glucocorticoid use, sternotomy, reduced tissue oxygenation	superior mediastinal widening, pneumomediastinum, subcutaneous emphysema, pleural effusions	lymphadenopathy, fluid collections with an enhancing wall, gas locules, fat stranding, edema
Esophageal Perforation	Advanced age, history of difficult intubation, presence of large cervical osteophytes	pneumomediastinum, subcutaneous emphysema, mediastinal widening, abscess formation	esophageal thickening, contrast extravasation if oral contrast administered

ABBREVIATIONS

CT = computed tomography

DNM = descending necrotizing mediastinitis

CECT = contrast enhanced computed tomography

KEYWORDS

descending necrotizing mediastinitis; retropharyngeal abscess; acute mediastinitis; mediastinum; thorax; danger space

Online access

This publication is online available at:

www.radiologycases.com/index.php/radiologycases/article/view/5095

Peer discussion

Discuss this manuscript in our protected discussion forum at:

www.radiopolis.com/forums/JRCR

Interactivity

This publication is available as an interactive article with scroll, window/level, magnify and more features.

Available online at www.RadiologyCases.com

Published by EduRad



www.EduRad.org