

Monro Unveiled


Kai-hung Fung, MBBS, FRCR

Radiology Department, Pamela Youde Nethersole Eastern Hospital, 3 Lok Man Road, Chai Wan, Hong Kong, China

✉ khfung@ha.org.hk

Radiology Case. 2010 Jun; 4(6):39-40 :: DOI: 10.3941/jrcr.v4i6.507

INTERESTING IMAGE



Monro Unveiled © Kai-hung Fung, 2010

This virtual ventriculoscopic view created from MRI data using three-dimensional Constructive Interference in Steady State Sequences (3D-CISS) shows a view inside the right lateral ventricle looking towards the frontal horn. The colorful bulge on the bottom right is the head of the caudate nucleus. The straight black structure on the left is the septal vein. Below is the foramen of Monro represented by the round structure. The curved black structure represents the columns of fornix. Above this is the colorful septum pellucidum. The head of caudate nucleus on the contralateral side can be seen through this septum. The black structure on top right is the corpus callosum.

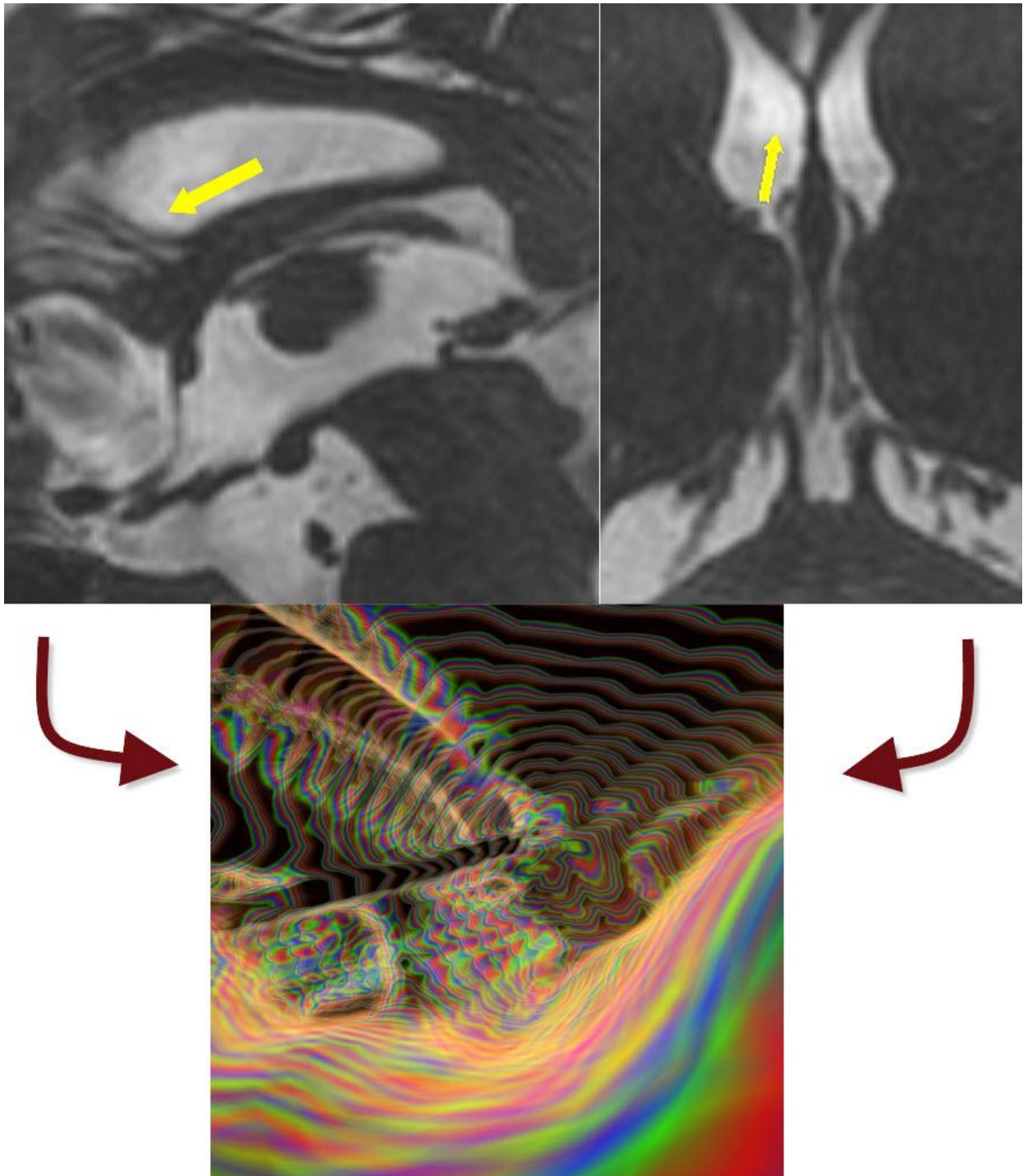


Figure 2: Original sagittal and axial MR image employing 3D constructive interference in steady state (3D CISS) pulse sequence (top) showing the view point by the arrow.

The artistically rendered 3D magnetic resonance imaging showing virtual ventriculscopy with visualization of the right lateral ventricle looking towards the frontal horn (bottom).

URL of this article:
www.radiologycases.com/index.php/radiologycases/article/view/507

Published by EduRad



www.EduRad.org