

Preoperative Transcatheter Arterial Embolization for Spontaneous Rupture of Huge Amebic Liver Abscess with Massive Intraoperative Hemorrhage

Koesbandono^{1,2}, Raditya Utomo², Benyamin Lukito³, Jusef Treser⁴, Nyoman Aditya Sindunata^{5*}

1.Department of Radiology, Siloam Hospitals Lippo Village, Tangerang, Indonesia

2.Department of Radiology, Faculty of Medicine at Pelita Harapan University, Tangerang, Indonesia

3.Department of Internal Medicine, Siloam Hospitals Lippo Village, Tangerang, Indonesia

4.Department of Digestive Surgery, Siloam Hospitals Lippo Village, Tangerang, Indonesia

5.Radiology Resident, Faculty of Medicine at Pelita Harapan University, Tangerang, Indonesia

*Correspondence: Nyoman Aditya Sindunata, Radiology Resident, Faculty of Medicine at Pelita Harapan University, Tangerang, Banten 15810, Indonesia

✉ sindunata.aditya@gmail.com

Radiology Case. 2023 Aug; 17(8):38-48 :: DOI: 10.3941/jrcr.v17i8.4837

ABSTRACT

An 18-year-old male developed a huge liver abscess with severe anemia over the course of 2 weeks. Abdominal contrast enhanced computed tomography showed ruptured huge liver abscess in the right liver lobe with signs of active hemorrhage (contrast extravasation). Serology examination confirmed amoeba as the suspected pathogen of cause. Angiography was performed followed by transcatheter arterial embolization to localize and control the hemorrhage. Embolization using a combination of polyvinyl alcohol and gelfoam successfully controlled the active hemorrhage. Exploratory laparotomy was performed to evacuate and debride the huge abscess. Metronidazole was given and showed good results. Huge liver abscess size is a predictor of conservative management failure and requires a gradual step-up intervention. The purpose of this paper is to explain the importance of imaging in detecting liver abscess and active hemorrhage along with the role of interventional radiology in this case.

CASE REPORT

CASE REPORT

An 18-year-old man presented to our institution with right upper quadrant abdominal pain, enlarged abdomen, fever, and general fatigue in the past 2 weeks which worsens over the past week. He has no significant medical nor surgical history, including alcohol consumption, diabetes, and immunosuppression. One week after the onset of his symptoms, he visited another hospital and underwent ultrasound (US) examination then referred to another hospital for abdominal non-enhanced computed tomography (NECT). He was then admitted in the second hospital for 7 days to improve his overall condition and finally transferred to our hospital.

Physical examination revealed high blood pressure (140/100 mmHg), tachycardia (120 beats/min), tachypnea (30 times/min), and fever (37.9°C). The patient appeared icteric and pale. Abdominal examination revealed markedly enlarged abdomen, tenderness on right upper quadrant, and no signs of peritoneal irritation.

Laboratory results showed anemia (previously 5.0 g/dL of hemoglobin, 8.1 g/dL on admission; normal range 13.2-

17.3), decreased hematocrit (27%; normal range 40-50%), reduced erythrocyte cells (2.71 million/ μ L; normal range 4.4-5.9), leukocytosis (21,960/ μ L; normal range 3,800-10,600), normal thrombocyte (428,000/ μ L; normal range 150,000-440,000), prolonged erythrocyte sedimentation rate (130 mm/hour; normal range 0-15), bilirubinemia (3.86 mg/dL of total bilirubin, normal range 0.2-1.2; 3.63 mg/dL of direct bilirubin, normal range 0-0.5; 0.23 mg/dL of indirect bilirubin, normal range 0-0.7), decreased kidney function (54.9 mL/min/1.73m² of eGFR, normal range \geq 90; 158 mg/dL of ureum, normal range <50; 1.81 mg/dL of creatinine, normal range 0.5-1.3), increased liver enzymes (59 U/dL of ALT, normal range 0-41; 69 mg/dL of AST, normal range 0-40), increased protein (8.74 g/dL; normal range 6.4-8.3), hypoalbuminemia (2.57 g/dL; normal range 3.5-5.2), elevated C-reactive protein (34 mg/L; normal range 0-5), and positive amoeba serology test (seramoeba 39.97 NTU; normal range <9). Paracentesis showed dark red fluid with no clot, cytological examination revealed acute inflammation with hemorrhage.

Abdominal US and NECT were previously performed in prior hospital. US showed a poorly demarcated heterogenous hypoechoic mass with internal echoes in right liver lobe (Figure

1A). NECT showed huge heterogenous hypodense mass with slight hyperdense irregular area inside the mass (Figure 1B). The mass was suspected as liver abscess with suspicion of internal hemorrhage.

Further imaging evaluation was performed in our hospital. Abdominal contrast enhanced computed tomography (CECT) showed hepatomegaly and huge heterogenous multiloculated irregular cystic mass with enhancing thick wall measuring 11.2 x 15.5 x 21.8 cm in right liver lobe (Figure 2). There was a small slightly hyperdense irregular area inside the mass with visible defect in the inferior aspect of the mass. Massive intraperitoneal free fluid was visualized. Ruptured liver abscess was suspected based on CECT findings. Based on the gathered information, suspicion towards ruptured liver abscess with suspected active hemorrhage was raised so the patient was planned for digital subtraction angiography (DSA) to detect active arterial hemorrhage followed by transcatheter arterial embolization (TAE) and prepared for exploratory laparotomy.

Digital subtraction angiography through celiac trunk catheterization using 5F Yashiro diagnostic catheter (Figure 3A) followed by selective catheterization using Renegade STC 18 microcatheter of branches of right hepatic artery showed huge avascular area in right liver lobe with hypervascular edges and contrast blushing (extravasation) from branches of right hepatic artery (segment VIII) (Figure 3B-3D). Superselective catheterization was performed on distal branches of right hepatic artery (segment VIII) followed by TAE using 300-500 microns of polyvinyl alcohol (PVA) and gelfoam. Contrast blushing was significantly decreased after embolization (Figure 3E). Hemorrhage was controlled and patient improved significantly after TAE, so he was prepared for surgery. Hemoglobin remains stable before and after TAE, 9.7 g/dL and 9.9 g/dL respectively indicating the procedure had successfully controlled the active hemorrhage without any significant complications after TAE.

Three days after the patient underwent TAE, exploratory laparotomy was performed. Intraoperative findings showed massive red fluid collection (almost 4 L) mixed necrotic tissues, omental walling off, small bowel and colon adhesions (Figure 4). Debridement of liver abscess and adhesiolysis were performed. Postoperative pathology study confirmed the diagnosis of liver abscess with hemorrhagic rupture. Based on the findings, the diagnosis was ruptured amebic liver abscess (ALA) with massive intraperitoneal hemorrhage.

After surgery, the patient was treated conservatively with metronidazole given 3 x 500 mg intravenously for 10 days, continued by metronidazole given 3 x 500 mg orally for the following 2 months and metronidazole given 2 x 500 mg orally for the following 1 month. Metronidazole treatment showed good response and he did not experience any significant adverse effects. He was discharged 9 days after the surgery. Vital signs were within normal limits. He was well during discharge and denied any significant pain or symptoms related

to the surgical wound. Laboratory results showed improvement including gradually improving hemoglobin (8.6 g/dL on discharge, 10.9 g/dL in 2 weeks after surgery; normal range 13.2-17.3), normal leukocyte (previously 21,960/ μ L, 18,120/ μ L in 2 days after surgery, 6,350/ μ L on discharge; normal range 3,800-10,600), decreased bilirubinemia (previously 3.86 mg/dL of total bilirubin, 0.97 mg/dL on discharge, normal range 0.2-1.2; previously 3.63 mg/dL of direct bilirubin, 0.74 mg/dL on discharge, normal range 0-0.5; previously 0.23 mg/dL of indirect bilirubin, 0.23 mg/dL on discharge, normal range 0-0.7), and gradual decrease in liver enzymes (previously 59 U/dL of ALT, 27 U/dL immediately after surgery, 10 U/dL on 2 weeks after surgery, normal range 0-41; previously 69 U/dL of AST, 73 U/dL immediately after surgery, 18 on 2 weeks after surgery, normal range 0-40).

Abdominal US during 5 months follow-up showed no evidence of abscess formation in right liver lobe (Figure 5). Patient denied any significant symptoms related to ALA and surgical complications.

DISCUSSION

Etiology & Demographics:

Amebiasis (gastrointestinal infection) is caused by *Entamoeba histolytica*, a protozoan most commonly causing intestinal parasite infection in travelers which is globally distributed with higher rates of infection in low middle income countries [1]. The most common extra-intestinal manifestation of amebiasis is liver abscess which is associated with significant morbidity and mortality [1,2]. The trophozoites that breach the colonic mucosa reach the liver via the portal system and induce abscess formation [3]. The incidence of ALA is highest in Asia, reaching 21 per 100,000 inhabitants per year, predominantly affecting men (male : female ratio 4-10:1) [4] in the age between 30 and 60 years [1]. Risk factors for ALA including alcohol consumption, malnutrition (low body mass index and hypoalbuminemia), diabetes, and immunosuppression [1,5].

Clinical & Imaging Findings:

Patients with ALA usually present with fever and right upper quadrant tenderness which our patient experienced along with progressive abdomen enlargement. Common laboratory findings including leukocytosis, raised inflammatory markers (e.g. C-reactive protein), increased alkaline phosphatase and abnormal liver function tests are usually present [1]. Liver abscess formation in this patient is thought to be caused by this mechanism as evident in positive amoeba serology test. Amebic serology is highly sensitive (>94%) and highly specific (>95%) for the diagnosis of ALA [1,2,5]. Several inflammatory markers were elevated in our patient including leukocyte, ESR and CRP supporting infectious etiology. He also had increased liver enzymes (AST and ALT), bilirubinemia (high direct bilirubin with normal indirect bilirubin, indicating intrahepatic cause of jaundice) and hypoalbuminemia indicating liver dysfunction. Hemoglobin was severely decreased (5.0 g/dL) indicating severe anemia and suspicion of active hemorrhage confirmed by

findings of paracentesis and cytological examination. Dark red fluid from paracentesis and cytological examination revealed it to be acute inflammation with hemorrhage.

The first modality of choice in suspected liver abscess cases is abdominal US which has the sensitivity of 70-90% for detecting liver abscess [4]. ALA most commonly occurs as a single lesion in the right lobe [1]. On US, abscesses are discrete hypoechoic lesions with acoustic through transmission, possibly with internal echoes or air within the cavity seen as echogenic foci with reverberation artifacts [4]. They less commonly appear as ill-defined areas of distorted parenchymal echogenicity and larger abscess may be hypoechoic or hyperechoic [1,4]. A negative US may not exclude the diagnosis of liver abscess due to the limited visualization of several blind spots and further investigation through CECT may be warranted.

Contrast-enhanced CT is an excellent imaging for liver abscess with sensitivity higher than 95% [1,4,5]. Besides that, CECT also facilitates planning of interventions and other invasive procedures in complex cases. A microabscess is typically a well-defined hypodense lesion with faint rim enhancement and perilesional edema, multiple lesions may coalesce to aggregate into a single larger cavity known as the cluster sign [4]. Larger lesions can be seen as smooth walled unilocular or complex multilocular septated lesions [4,5]. CECT of our patient showed hepatomegaly and huge heterogenous multiloculated irregular cystic mass with thick wall with largest diameter of 21.8 cm in right liver lobe. Slight hyperdense area inside the mass and defect in the inferior aspect of the mass in CECT strongly suggest ruptured liver abscess with possibly active hemorrhage. CECT will show the classical double target rim enhancement with the inner rim showing early persistent enhancement and the outer edema showing delayed enhancement [4]. Air inside the abscess cavity is occasionally encountered as air-fluid level or small bubble. Although imaging especially CECT can clearly visualize liver abscess, but it cannot distinguish pathogen type hence not possible to distinguish amebic or pyogenic liver abscess [1,3].

Bleeding of hepatic arteries is an uncommon complication of liver abscess caused by pseudoaneurysm or inflammation [6]. DSA is the gold standard for detecting active hemorrhage. When obscured by large amounts of hemoperitoneum, DSA does not reliably demonstrate contrast extravasation [7]. Generally, the rate of bleeding must exceed 1 ml/min to be detected on DSA and contrast extravasation is visualized in less than 20% of cases [7]. In patient without active contrast extravasation on DSA, determining the site for TAE can be based on CT localization through visualized contrast leakage or hyperdense hematoma which was crucial for TAE planning [7,8].

Differential Diagnosis:

Amebic liver abscess is classically unilocular and solitary in the right lobe [1,4,5]. Although ALA cannot be differentiated from pyogenic liver abscess (PLA) on imaging [1,3], there are suggestive sonographic signs: round or oval shape, absence of wall echoes, homogenous low-level internal echoes, acoustic

through transmission, and contiguity with hepatic capsule. CECT shows well-defined hypodense rounded lesions with thick enhancing walls and perilesional edema [4]. The cavity may have septation, air, debris level, or hemorrhage [4]. Bleeding of hepatic arteries is an uncommon complication of liver abscess caused by pseudoaneurysm or inflammation [6]. DSA is the gold standard for detecting active hemorrhage. Abscess will appear as an avascular area with hypervascular edge.

Pyogenic liver abscess and ALA may be indistinguishable on clinical and imaging features but differ in terms of epidemiology and medical management [1,3,4]. PLA are usually seen in 5th or 6th decade with no gender predilection [4]. PLA may appear as either single or multiple lesions that may involve any lobe [1]. Abscesses are discrete hypoechoic lesions with acoustic through transmission possibly with internal echoes or air within the cavity, less commonly present as ill-defined areas of distorted parenchymal echogenicity [4,5]. Larger lesions may be hyperechoic or hypoechoic [4]. CECT will show a well-defined hypodense lesion with faint rim enhancement and perilesional edema, when multiple may coalesce [4,5]. Larger lesions may be smooth walled unilocular or complex multilocular septated lesions [4]. CECT will show the classical double target rim enhancement with the inner rim showing early persistent enhancement and the outer edema showing delayed enhancement [4,5].

Necrotic neoplasm is difficult to differentiate from phlegmonous abscess. Different from abscesses, neoplasms seldom have layered appearance and segmental enhancement [4]. Other findings specific to tumor type can help differentiating them from abscess. Tumor usually has thick irregular wall with nodularity and arterial enhancement [4].

Tubercular abscess is a complex appearing lesion that may not have a distinct wall at all, may have circumferential hyperechoic wall, or as a solid lesion. CECT may show multiple hypodense nodules with or without peripheral enhancement, single hypodense mass with central hypoattenuation, conglomerate mass with honeycomb appearance, or fluid collection with enhancing thick walls [4].

Cysts will appear as well-defined anechoic lesions with posterior acoustic enhancement on US. They lack surrounding edema and rim enhancement on CECT [4]. On DSA, cyst will appear similar to abscess as an avascular area without hypervascular edge.

Treatment & Prognosis:

The standard medical treatment for ALA is 1.5 to 2 g/day of metronidazole given orally or intravenously for 10 days [1,5,9]. The alternative is 1.5 g/day of tinidazole or ornidazole given for 5 days [5,9]. Medical treatment is usually sufficient [1], but complicated cases require minimally invasive methods or even surgery.

Our patient was diagnosed with ruptured huge ALA and require immediate management due to the patient's worsening

condition. Huge hematoma creates mass effect and provides some degree of tamponade effect to hemorrhaging blood vessels. This puts us in a dilemma because huge liver abscess requires surgical evacuation and debridement but doing so puts the patient in a life-threatening condition. Surgical approach may seem the best option for our patient, but going straight to surgery may put the patient at risk of surgical complications and delayed recovery due to his poor overall condition. Thus, interventional radiologist has crucial role in controlling hemorrhage by means of endovascular intervention (TAE). The decision to follow invasive approach is due to the huge size of the abscess (maximum diameter of >7.7 cm) as a predictor of failure of conservative management and warrants more aggressive treatment approach, a gradual step-up with interventions is safe and effective as mentioned in several studies [6,10,11].

When active bleeding of liver tumor is visualized on DSA, TAE is recommended over surgery unless there is severe hemodynamic instability [8]. Initial common hepatic artery DSA using 5F Yashiro diagnostic catheter demonstrates huge avascular area in right liver lobe with hypervascular edges. Selective catheterization of branches of right hepatic artery (segment VIII) using Renegade STC 18 microcatheter demonstrates contrast blushing (extravasation) indicating active hemorrhage which correlates with the previous CECT. Superselective catheterization was performed on distal branches of right hepatic artery (segment VIII) followed by embolization using 300-500 microns of PVA and gelfoam. These two embolic agents are very effective in controlling hemorrhage, significant decrease of contrast blushing/no extravasation was achieved after embolization without any significant complications after TAE. TAE is effective with a higher rate of achieving hemostasis [7]. Patient improved significantly after TAE and active hemorrhage was controlled as evident in increased hemoglobin, so he was prepared for surgery. Selective TAE is a minimally invasive procedure owing to the development of microcatheters that lowers the risk of concomitant ischemic damage of liver parenchyma. Complications of TAE are rare and mostly consist of complications of angiographic procedure, contrast medium, and postembolization syndrome. The syndrome, consists of pain, fever, and nausea, is self-limiting so it hardly requires intervention [12].

Exploratory laparotomy was performed and confirmed the diagnosis of ruptured huge ALA. Intraoperative findings showed massive red fluid collection (almost 4 L) mixed necrotic tissues, omental walling off, small bowel and colon adhesions. Debridement of liver abscess and adhesiolysis were performed. Postoperative pathology study confirmed the diagnosis of liver abscess with hemorrhagic rupture. After surgery the patient was administered metronidazole given 3 x 500 mg intravenously for 10 days, continued by oral metronidazole for the following 3 months and showed good response without any significant side effects experienced. Based on several studies, metronidazole is the mainstay of treatment for ALA given 1.5 to 2 g/day orally or intravenously for 10 days, but patients not responding to medical treatment or large abscess (>10 cm in diameter) should undergo

drainage or surgery [1,5,9]. The side effects of metronidazole are usually mild to moderate, including nausea, abdominal pain, and diarrhea. Serious neurotoxicity, including encephalopathy, optic neuropathy, and peripheral neuropathy, is rarely reported [3,13].

He was discharged 9 days after the surgery. Vital signs were within normal limits. He was well during discharge and denied any significant pain or symptoms related to the surgical wound. Laboratory results showed improvement including gradually improving hemoglobin, decreased bilirubinemia, and gradual decrease in liver enzymes following surgery and normal in 5 months follow-up. During 5 months follow-up, abdominal US showed no evidence of abscess formation in right liver lobe indicating no recurrence. Patient denied any significant symptoms related to ALA and surgical complications.

The prognosis of ALA depends on the time of diagnosis and treatment. ALA is progressive and uniformly fatal if left untreated. Outcome is favorable when treatment is given in a timely manner [1,5,9]. Increased mortality is associated with complex or ruptured abscess.

TEACHING POINT

Arteriography may accurately localize the source of active bleeding in ruptured amebic liver abscess. Transcatheter arterial embolization is effective and, if applicable to the case, should be considered in controlling active hemorrhage as a minimally invasive technique prior to surgery.

QUESTIONS

Question 1: Which is the classic appearance of amebic liver abscess?

1. Unilocular solitary lesion in the left liver lobe.
2. Unilocular solitary lesion in the right liver lobe. (applies)
3. Multiple lesions in the left liver lobe.
4. Multiple lesions in the right liver lobe.
5. Multiple lesions in both liver lobes.

Explanation:

1. Commonly involving the right liver lobe. [Amebic liver abscess is classically unilocular and solitary in the right lobe.]
2. Amebic liver abscess commonly manifest as a unilocular solitary lesion in the right liver lobe. [Amebic liver abscess is classically unilocular and solitary in the right lobe.]
3. Multiple lesions is commonly seen in pyogenic liver abscess, involving any liver lobe. [PLA may appear as either single or multiple lesions that may involve any lobe.]
4. Multiple lesions is commonly seen in pyogenic liver abscess, involving any liver lobe. [PLA may appear as either single or multiple lesions that may involve any lobe.]
5. Multiple lesions is commonly seen in pyogenic liver abscess, involving any liver lobe. [PLA may appear as either single or multiple lesions that may involve any lobe.]

Question 2: Which of the following sonographic signs are found in amebic liver abscess?

1. Round or oval shape. [applies]
2. Absence of wall echoes. [applies]
3. Homogenous low-level internal echoes. [applies]
4. Acoustic through transmission. [applies]
5. Contiguity with hepatic capsule. [applies]

Explanation:

1. Round or oval shape is a suggestive sonographic sign found in amebic liver abscess. [Although ALA cannot be differentiated from PLA on imaging there are suggestive sonographic signs: round or oval shape, absence of wall echoes, homogenous low-level internal echoes, acoustic through transmission, and contiguity with hepatic capsule.]
2. Absence of wall echoes is a suggestive sonographic sign found in amebic liver abscess. [Although ALA cannot be differentiated from PLA on imaging there are suggestive sonographic signs: round or oval shape, absence of wall echoes, homogenous low-level internal echoes, acoustic through transmission, and contiguity with hepatic capsule.]
3. Homogenous low-level internal echoes is a suggestive sonographic sign found in amebic liver abscess. [Although ALA cannot be differentiated from PLA on imaging there are suggestive sonographic signs: round or oval shape, absence of wall echoes, homogenous low-level internal echoes, acoustic through transmission, and contiguity with hepatic capsule.]
4. Acoustic through transmission is a suggestive sonographic sign found in amebic liver abscess. [Although ALA cannot be differentiated from PLA on imaging there are suggestive sonographic signs: round or oval shape, absence of wall echoes, homogenous low-level internal echoes, acoustic through transmission, and contiguity with hepatic capsule.]
5. Contiguity with hepatic capsule is a suggestive sonographic sign found in amebic liver abscess. [Although ALA cannot be differentiated from PLA on imaging there are suggestive sonographic signs: round or oval shape, absence of wall echoes, homogenous low-level internal echoes, acoustic through transmission, and contiguity with hepatic capsule.]

Question 3: Which modality is suggested for initial imaging examination?

1. X-ray.
2. Ultrasound. [applies]
3. Non-enhanced computed tomography.
4. Contrast enhanced computed tomography.
5. Digital subtraction angiography.

Explanation:

1. X-ray will not provide adequate visualization of liver pathology. [The first modality of choice in suspected liver abscess cases is abdominal US which has the sensitivity of 70-90% for detecting liver abscess.]
2. Abdominal ultrasound is the initial choice due to its relatively high sensitivity and availability. [The first modality of choice in suspected liver abscess cases is abdominal US which has the sensitivity of 70-90% for detecting liver abscess.]
3. Although non-enhanced computed tomography provides

better visualization, ultrasound remains the initial choice. [The first modality of choice in suspected liver abscess cases is abdominal US which has the sensitivity of 70-90% for detecting liver abscess.]

4. Although contrast enhanced computed tomography provides superior visualization, ultrasound remains the initial choice. [The first modality of choice in suspected liver abscess cases is abdominal US which has the sensitivity of 70-90% for detecting liver abscess.]

5. Digital subtraction angiography is used mainly to locate active hemorrhage source and provide endovascular treatment options. [The first modality of choice in suspected liver abscess cases is abdominal US which has the sensitivity of 70-90% for detecting liver abscess.]

Question 4: What are the signs of active hemorrhage found in contrast enhanced computed tomography?

1. Contrast leakage. [applies]
2. Cluster sign.
3. Double target rim.
4. Hypodense hematoma.
5. Hyperdense hematoma. [applies]

Explanation:

1. Contrast leakage is one of the signs of active hemorrhage. [In patient without active contrast extravasation on DSA, determining the site for TAE can be based on CT localization through visualized contrast leakage or hyperdense hematoma which was crucial for TAE planning.]

2. Cluster sign is one of the features found in amebic liver abscess on CT. [A microabscess is typically a well-defined hypodense lesion with faint rim enhancement and perilesional edema, multiple lesions may coalesce to aggregate into a single larger cavity known as the cluster sign]

3. Double target rim is the classic sign of amebic liver abscess on CECT. [CECT will show the classical double target rim enhancement with the inner rim showing early persistent enhancement and the outer edema showing delayed enhancement.]

4. Active hemorrhage will cause contrast leakage into the hematoma and create a hyperdense hematoma, not hypodense hematoma. [CECT will show the classical double target rim enhancement with the inner rim showing early persistent enhancement and the outer edema showing delayed enhancement.]

5. Hyperdense hematoma is one of the signs of active hemorrhage. [In patient without active contrast extravasation on DSA, determining the site for TAE can be based on CT localization through visualized contrast leakage or hyperdense hematoma which was crucial for TAE planning.]

Question 5: What findings can reliably help active hemorrhage localization when no contrast extravasation is visible on digital subtraction angiography?

1. Double target rim enhancement.
2. Air-fluid level.

3. Arterial enhancement.
4. Honeycomb appearance.
5. Contrast leakage or hyperdense hematoma. (applies)

Explanation:

1. This sign indicates the presence of liver abscess. [CECT will show the classical double target rim enhancement with the inner rim showing early persistent enhancement and the outer edema showing delayed enhancement.]
2. The presence of air inside the cavity indicates abscess. [Air inside the abscess cavity is occasionally encountered as air-fluid level or small bubble.]
3. Arterial enhancement is typically found in tumor. [Tumor usually has thick irregular wall with nodularity and arterial enhancement.]
4. Honeycomb appearance is typically found in tubercular abscess. [CECT may show multiple hypodense nodules with or without peripheral enhancement, single hypodense mass with central hypoattenuation, conglomerate mass with honeycomb appearance, or fluid collection with enhancing thick walls.]
5. Either contrast leakage or hyperdense hematoma can reliably localize the source of active hemorrhage. [In patient without active contrast extravasation on DSA, determining the site for TAE can be based on CT localization through visualized contrast leakage or hyperdense hematoma which was crucial for TAE planning.]

AUTHORS' CONTRIBUTIONS

- Conceptualization: Koesbandono, Raditya Utomo
 Writing – original draft: Koesbandono, Nyoman Aditya Sindunata
 Writing – review & editing: Koesbandono, Raditya Utomo, Benyamin Lukito, Jusef Treser, Nyoman Aditya Sindunata

DISCLOSURES

The author declares that he has no relevant or material financial interests that relate to the research described in this paper.

CONSENT

Did the author obtain written informed consent from the patient for submission of this manuscript for publication? Yes

HUMAN AND ANIMAL RIGHTS

This paper is not a report of human or animal subject experiment.

REFERENCES

1. Khim G, Em S, Mo S, Townell N. Liver abscess: Diagnostic and management issues found in the low resource setting. *Br Med Bull.* 2019; 132(1): 45-52. PMID: 31836890.
2. Sarda AK, Mittal R, Basra BK, Mishra A, Talwar N. Three cases of amoebic liver abscess causing inferior vena cava obstruction, with a review of the literature. *Korean J Hepatol.* 2011; 17(1): 71-75. PMID: 21494081.
3. Kouzu K, Einama T, Nishikawa M, Fukumura M, Nagata H, Iwasaki T. Successful surgical drainage with intraoperative ultrasonography for amoebic liver abscess refractory to metronidazole and percutaneous drainage: A case report. *BMC Surg.* 2020; 20: 1-6. PMID: 32448287.
4. Kalantri A, Gupta P, Sharma V, Mandavdhare H, Samanta J, Sinha SK. Hepatic Infections: A Comprehensive Imaging Review. *J Gastrointest Infect.* 2019; 9: 38-49.
5. Lardièrre-Deguelte S, Ragot E, Amroun K, et al. Hepatic abscess: Diagnosis and management. *J Visc Surg.* 2015; 152(4): 231-243. PMID: 25770745.
6. Satoh M, Kogure T, Koizumi A, et al. A Gas-forming Liver Abscess with Massive Bleeding into the Abscess Cavity Due to a Ruptured Inferior Phrenic Artery. *Intern Med.* 2021; 60(24): 3913-3919. PMID: 34911874.
7. Kung C Te, Liu BM, Ng SH, et al. Transcatheter arterial embolization in the emergency department for hemodynamic instability due to ruptured hepatocellular carcinoma: analysis of 167 cases. *AJR Am J Roentgenol.* 2008; 191(6): 231-239. PMID: 19020209.
8. Imagami T, Takayama S, Maeda Y, Sakamoto M, Kani H. Transcatheter arterial embolization for hemorrhagic rupture of a simple hepatic cyst: a case report. *Radiol Case Rep.* 2021; 16(8): 1956-1960. PMID: 34149982.
9. Jindal A, Pandey A, Sharma MK, et al. Management Practices and Predictors of Outcome of Liver Abscess in Adults: A Series of 1630 Patients from a Liver Unit. *J Clin Exp Hepatol.* 2021; 11(3): 312-320. PMID: 33994714.
10. Kale S, Nanavati AJ, Borle N, Nagral S. Outcomes of a conservative approach to management in amoebic liver abscess. *J Postgrad Med.* 2017; 63(1): 16-20. PMID: 27652983.
11. Kim NS, Chun HR, Jung H II, Kang JK, Park SK, Bae SH. Spontaneous rupture of pyogenic liver abscess with subcapsular hemorrhage mimicking ruptured hepatocellular carcinoma: A case report. *Medicine (Baltimore).* 2021; 100(15): e25457. PMID: 33847652.
12. Erdogan D, Van Delden OM, Busch ORC, Gouma DJ, Van Gulik TM. Selective transcatheter arterial embolization for treatment of bleeding complications or reduction of tumor mass of hepatocellular adenomas. *Cardiovasc Intervent Radiol.* 2007; 30(6): 1252-1258. PMID: 17605070.
13. Hernández Ceruelos A, Romero-Quezada LC, Ruvalcaba Ledezma JC, López Contreras L. Therapeutic uses of metronidazole and its side effects: an update. *Eur Rev Med Pharmacol Sci.* 2019; 23(1): 397-401. PMID: 30657582.

FIGURES

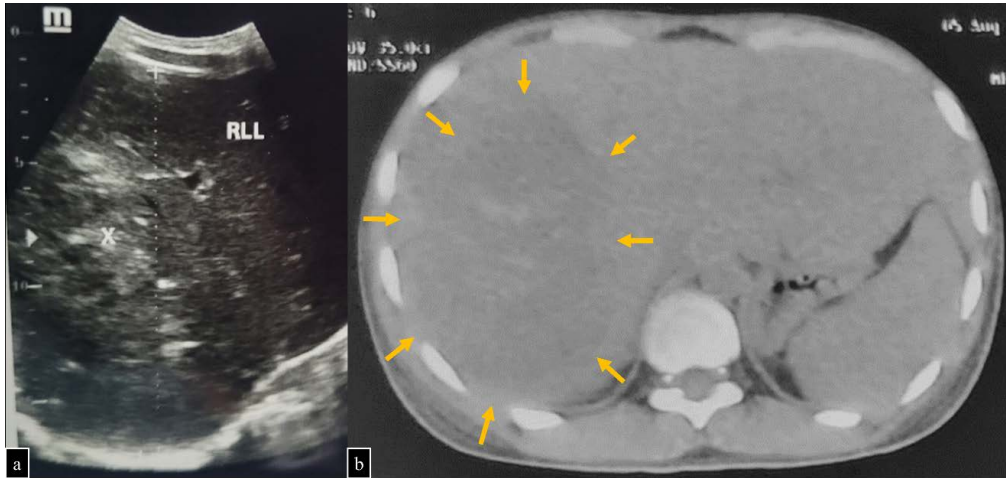


Figure 1: 18-year-old male with huge amebic liver abscess.

FINDINGS: Initial imaging. (a) Abdominal US showing a poorly demarcated heterogenous hypoechoic mass with internal echoes in right liver lobe (x). (b) Abdominal NECT showing huge heterogenous hypodense mass with slight hyperdense irregular area inside the mass (arrow).

TECHNIQUE: (a) Abdominal ultrasound using 1-6 MHz curvilinear transducer, (b) Axial CT abdomen/pelvis without contrast, 144mAs, 120kV, 5.0mm slice thickness.

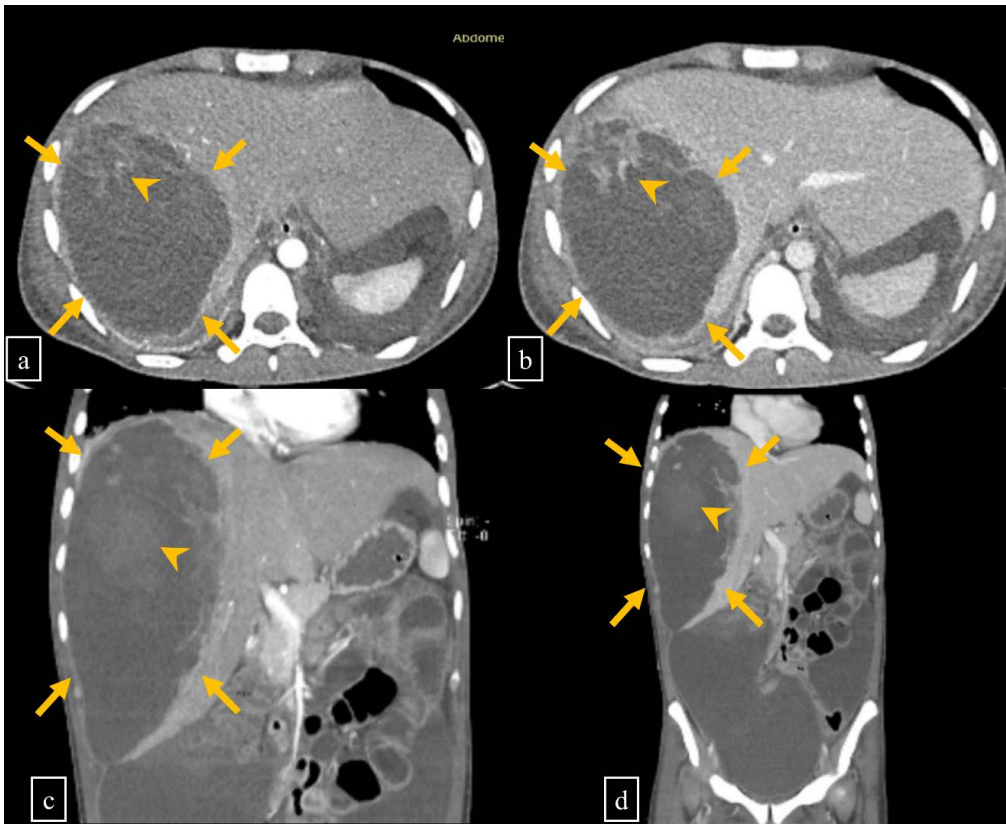


Figure 2: 18-year-old male with spontaneous rupture of huge amebic liver abscess.

FINDINGS: Abdominal CECT showing hepatomegaly and huge inhomogenous multiloculated irregular cystic mass with enhancing thick wall in right liver lobe (arrow). (a, c) Arterial phase and (b, d) venous phase showing contrast extravasation inside the mass suspected as active arterial hemorrhage (arrowhead).

TECHNIQUE: Axial CT abdomen/pelvis, 222mAs, 90kV, 0.75mm slice thickness, 70 ml of Iopamiro 370.

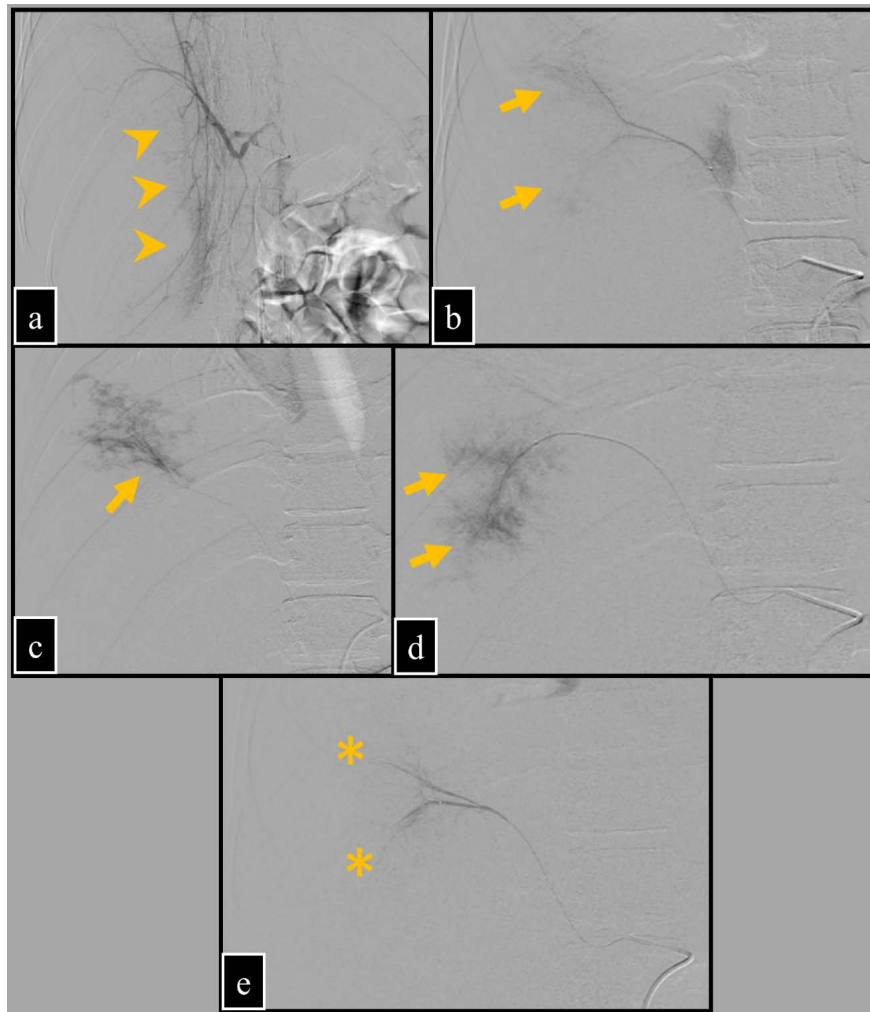


Figure 3: 18-year-old male with spontaneous rupture of huge amebic liver abscess.
FINDINGS: (a) DSA of common hepatic artery showing massive avascular area in right liver lobe with hypervascular edges (arrowhead). (b, c, d) Selective arteriography of right hepatic artery (segment VIII) showing contrast blushing (extravasation) (arrow). (e) Arteriography after TAE showing significantly decreased contrast blushing (no extravasation) (asterisk).
TECHNIQUE: Anteroposterior digital subtraction angiography using 100 ml of Iopamiro 370.

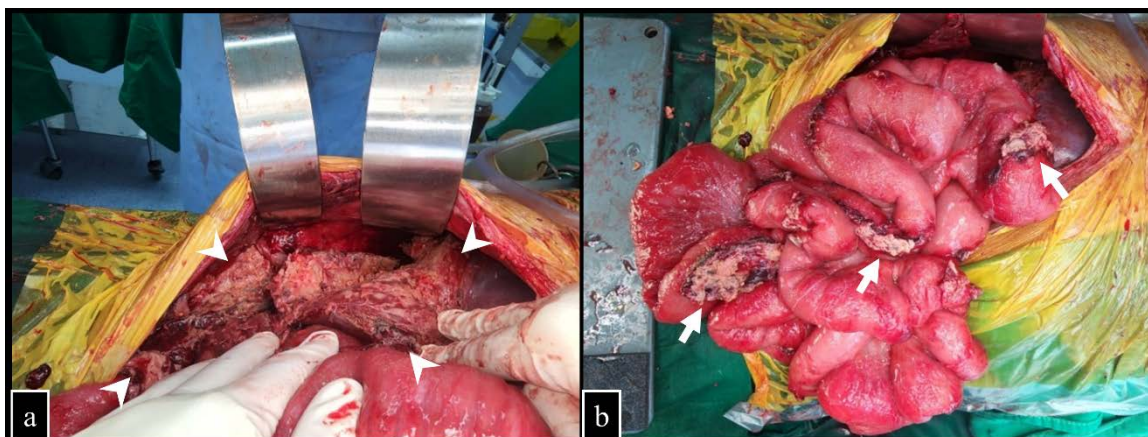


Figure 4: 18-year-old male with spontaneous rupture of huge amebic liver abscess.
FINDINGS: Intraoperative findings showing (a) ruptured huge liver abscess (arrowhead), (b) omental walling off (arrow), small bowel and colon adhesions.
TECHNIQUE: Exploratory laparotomy intraoperative findings.

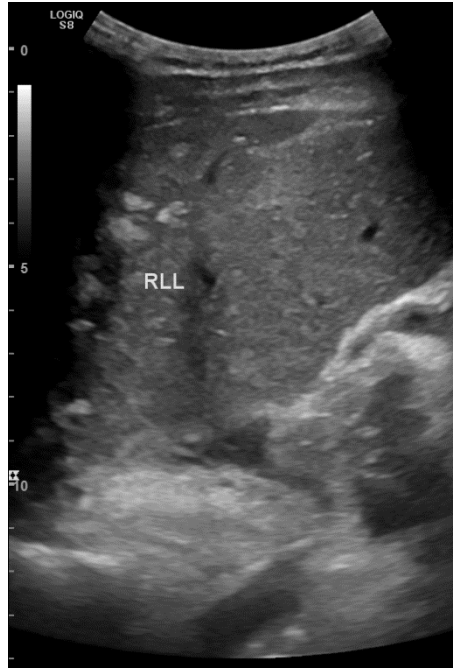


Figure 5: 18-year-old male with spontaneous rupture of huge amebic liver abscess. **FINDINGS:** Five months follow-up after surgery and conservative treatment. Abdominal US showing no evidence of abscess formation in right liver lobe. **TECHNIQUE:** Abdominal ultrasound using 1-6 MHz curvilinear transducer.

Etiology	<i>Entamoeba histolytica</i> .
Incidence	Highest in Asia, as high as 21 per 100,000 inhabitants per year.
Gender ratio	More common in males, male to female ratio 4-10:1.
Age predilection	Most common in 30-60 years of age.
Risk factors	Alcohol consumption, malnutrition.
Treatment	<ul style="list-style-type: none"> - Metronidazole is usually sufficient. - Percutaneous drainage in co-infection or impending rupture. - Surgery in complicated cases.
Prognosis	<ul style="list-style-type: none"> - Progressive and uniformly fatal if left untreated. - Favorable outcome when treatment is given in a timely manner.
Imaging findings	<p>Classically unilocular and solitary in the right liver lobe.</p> <p>US:</p> <ul style="list-style-type: none"> - Discrete hypoechoic lesions, less commonly appear as ill-defined areas of distorted parenchymal echogenicity. - Larger abscess may be hypoechoic or hyperechoic. - Suggestive signs: round or oval shape, absence of wall echoes, homogenous low-level internal echoes, acoustic through transmission, and contiguity with hepatic capsule. <p>CECT:</p> <ul style="list-style-type: none"> - Well-defined hypodense rounded lesions with thick enhancing walls and perilesional edema. - Cluster sign: a single larger cavity formed by coalescence of multiple lesions. - Larger lesion: smooth walled unilocular or multilocular septated lesions. - Air inside the cavity seen as air-fluid level or small bubble. - Hemorrhage: contrast extravasation or hyperdense hematoma. <p>DSA:</p> <ul style="list-style-type: none"> - Active hemorrhage: contrast extravasation or blushing.

Table 1: Summary table of amebic liver abscess.

	US	CT	DSA
Amebic liver abscess	<ul style="list-style-type: none"> - Discrete hypoechoic lesions, less commonly appear as ill-defined areas of distorted parenchymal echogenicity. - Suggestive signs: round or oval shape, absence of wall echoes, homogenous low-level internal echoes, acoustic through transmission, and contiguity with hepatic capsule. 	<ul style="list-style-type: none"> - Well-defined hypodense rounded lesions with thick enhancing walls and perilesional edema. - Coalescence of multiple lesions. - Smooth walled unilocular or multilocular septated lesions. - Air-fluid level or small bubble in the cavity. - Hemorrhage: contrast extravasation or hyperdense hematoma. 	<ul style="list-style-type: none"> - Avascular area with hypervascular edge. - Active hemorrhage: contrast extravasation or blushing.
Pyogenic liver abscess	<ul style="list-style-type: none"> - Single or multiple lesions that may involve any lobe. - Features are indistinguishable from amebic liver abscess. 	<ul style="list-style-type: none"> - Single or multiple lesions that may involve any lobe. - Features are indistinguishable from amebic liver abscess. 	<ul style="list-style-type: none"> - Features are indistinguishable from amebic liver abscess. - Active hemorrhage: contrast extravasation or blushing.
Neoplasms	<ul style="list-style-type: none"> - Variable appearance. - Increased vascularization on Doppler. 	<ul style="list-style-type: none"> - Seldom shows the layered appearance and segmental enhancement. - Thick irregular wall with nodularity and arterial enhancement. 	<ul style="list-style-type: none"> - Variable enhancement based on type. - Active hemorrhage: contrast extravasation or blushing.
Tubercular abscess	<ul style="list-style-type: none"> - Complex appearing lesion that may not have a distinct wall at all, - May have circumferential hyperechoic wall, or - Solid lesion. 	<ul style="list-style-type: none"> - Multiple hypodense nodules with or without peripheral enhancement, - Single hypodense mass with central hypoattenuation, - Conglomerate mass with honeycomb appearance, or - Fluid collection with enhancing thick walls. 	<ul style="list-style-type: none"> - Similar features to amebic liver abscess. - Active hemorrhage: contrast extravasation or blushing.
Cysts	<ul style="list-style-type: none"> - Well-defined anechoic lesions with posterior acoustic enhancement. 	<ul style="list-style-type: none"> - Well-defined cystic lesion. - Lacks surrounding edema and rim enhancement. 	<ul style="list-style-type: none"> - Avascular area without hypervascular edge. - Active hemorrhage: contrast extravasation or blushing.

Table 2: Differential diagnosis table for amebic liver abscess.

ABBREVIATIONS

ALA = amebic liver abscess, CECT = contrast enhanced computed tomography, CT = computed tomography, DSA = digital subtraction angiography, NECT = non-enhanced computed tomography, PLA = pyogenic liver abscess, TAE = transcatheter arterial embolization, US = ultrasound

KEYWORDS

ruptured amebic liver abscess, active hemorrhage, computed tomography, digital subtraction angiography, transcatheter arterial embolization, liver, parasite

Online access

This publication is online available at:

www.radiologycases.com/index.php/radiologycases/article/view/4837

Peer discussion

Discuss this manuscript in our protected discussion forum at:

www.radiopolis.com/forums/JRCR

Interactivity

This publication is available as an interactive article with scroll, window/level, magnify and more features.

Available online at www.RadiologyCases.com

Published by EduRad



www.EduRad.org