

# Trigeminal Lipomatosis: A Rare Cause of Intractable Neuralgia

Apoorva Sehgal<sup>1</sup>, Jyoti Kumar<sup>1\*</sup>, Ishwar Singh<sup>2</sup>, Ashish Gopal<sup>2</sup>

<sup>1</sup>Department of Radio-diagnosis, Maulana Azad Medical College, New Delhi, India

<sup>2</sup>Department of E.N.T, Maulana Azad Medical College, New Delhi, India

\*Correspondence: Dr. Jyoti Kumar, Director- Professor, Department of Radio-diagnosis, Maulana Azad Medical College, New Delhi, India

✉ drjyotikumar@gmail.com

Radiology Case. 2023 Aug; 17(8):49-56 :: DOI: 10.3941/jrcr.v17i8.4709

## ABSTRACT

Lipomatosis of nerve, earlier known as fibrolipomatous hamartoma is a rare condition which predominantly affects peripheral nerves, cranial nerve involvement being extremely uncommon. Preoperative consideration of this entity is of paramount importance as its inadvertent complete surgical resection may inevitably result in significant neurological deficit. We report a case of trigeminal lipomatosis in a young patient with trigeminal neuralgia.

## CASE REPORT

### CASE REPORT

A 23-year-old female presented with left sided facial pain radiating to jaw and neck for three years, involving the territories of all three divisions of trigeminal nerve, namely the ophthalmic, maxillary and mandibular divisions. There was no neurological deficit on clinical examination.

The patient was referred for Contrast-enhanced Magnetic Resonance Imaging (MRI) of the head and neck to look for the cause of trigeminal neuralgia. MRI revealed a non-enhancing well-circumscribed fatty lesion appearing hyperintense on T1 weighted images with signal drop on fat suppressed images in left Meckel's cave involving the trigeminal ganglion. The lesion measured~ 1.8 (anteroposterior) x 1.9 (transverse) x 2.3 (craniocaudal) cm and was seen extending along the distal mandibular nerve via the foramen ovale into the left infratemporal fossa. A small proximal extension of the lesion was seen along the left main trigeminal nerve into the prepontine cistern. The lesion showed few punctate and serpiginous hypointense areas within on T1 and T2 weighted images representing the prominent nerve fascicles and fibrotic component of the lesion respectively. The punctate hypointense nerve fibres within the hyperintense lesion resulted in the 'co-axial cable' appearance. The lesion appeared hyperintense as compared to subcutaneous fat on diffusion weighted images with signal drop on corresponding apparent diffusion coefficient map suggestive of diffusion restriction (Figure 1A, 1B and 1C).

Computed Tomography (CT) was performed to evaluate the status of the bony foramen and adjacent skull base. CT reiterated the presence of a dumb-bell shaped lesion of fat attenuation involving the left Meckel's cave extending across

the widened left foramen ovale into the infratemporal fossa. There was smooth scalloping of the left lateral wall of sphenoid sinus with no obvious bony destruction (Figure 2).

A diagnosis of lipomatosis of the trigeminal nerve was made and patient was started on Tablet Gabapentin 300 mg (brand name-Neurontin) three times a day which presently provided symptomatic relief with the aim to gradually titrate the dose over 6-9 months depending upon patient's symptomatology and drug tolerability. The patient is on regular follow-up in the outpatient department and is symptom-free till date.

## DISCUSSION

### INTRODUCTION

Lipomatosis of nerve, previously known by several names such as fibrolipomatous hamartoma, neural fibrolipoma and hamartomatous lipomatosis is a rare entity that most commonly involves the peripheral forearm nerves, median nerve being the most common [1,2].

### ETIOLOGY, PATHOPHYSIOLOGY AND DEMOGRAPHICS

Based on etiology, trigeminal neuralgia is classified as idiopathic, classic and secondary. Idiopathic neuralgia is characterized by an unknown cause, classic trigeminal neuralgia is due to neurovascular compression in the trigeminal root entry zone which causes nerve root atrophy or displacement while secondary neuralgia may be caused by an underlying disease such as neoplasm, cyst, demyelination etc [3]. Lipomatosis is an extremely uncommon cause of secondary trigeminal neuralgia.

Lipomatosis of trigeminal nerve is distinct from Meckel's cave lipoma as lipomatosis is the infiltration of the epineurium and perineurium by adipose and fibrous tissue with consequent enlargement of the trigeminal nerve causing neuralgia due to compression on nerve fascicles while lipoma is a benign neoplasm of mature adipocytes that arises as a result of abnormal persistence and maldifferentiation of the meninx primitiva into lipomatous elements. Meckel's cave lipoma does not infiltrate the trigeminal nerve causing only extrinsic neural compression [1,4]. Thus, lipomatosis is described as a hamartoma and not a neoplasm. The exact etiology is unclear. Few authors consider lipomatosis to be the result of chronic nerve irritation or previous trauma while others consider the condition to be congenital [5].

The condition mostly affects children and young adults with most patients presenting before third to fourth decades of life with no obvious gender predilection. White population has higher predisposition for developing neural lipomatosis [5]. These lesions grow rapidly in childhood with growth continuing even after skeletal maturation. However, it usually slows down in late adulthood [6].

### CLINICAL AND IMAGING FINDINGS

Patients most commonly present with pain, paraesthesia, tingling, numbness and focal neurological deficit. About one-third of the patients with peripheral nerve lipomatosis also develop macrodystrophia lipomatosa, the overgrowth of all mesenchymal elements of a digit or extremity along the territory of the affected nerve [2,5].

MRI is the imaging modality of choice for diagnosis of this entity. The presence of thickened nerve fascicles (hypointense on T1 and T2-weighted sequences) surrounded by tissue with signal characteristics of fat (hyperintense on T1-weighted and intermediate signal intensity on T2-weighted sequences with signal drop on fat-suppressed images) giving coaxial-cable-like appearance on axial and spaghetti-like appearance on coronal plane of the nerve is considered pathognomonic [1,7]. Axial sections may show thin T1 and T2 hypointense septae consistent with the characteristic pathological findings of thickened perineurium due to perineural fibrosis. These characteristic imaging findings obviate the need for biopsy [8]. Very few studies have described diffusion characteristics in neural lipomatosis. Sarp et al [9] described the absence of diffusion restriction in their case report on sciatic nerve lipomatosis contrary to our case.

Sonography reveals hypoechoic neural fascicles encased by hyperechoic fat contained in the expanded nerve sheath [7]. However, sonography cannot be used to assess cranial nerve lipomatosis.

CT shows a fat density lesion extending along the course of the nerve [10].

### TREATMENT AND PROGNOSIS

First-line medical management of trigeminal neuralgia includes carbamazepine and oxcarbazepine which were not

tolerated by our patient. Pregabalin, gabapentin, phenytoin, lamotrigine and/or baclofen are other drugs approved for conservative management of trigeminal neuralgia [3]. Our patient responded well to 900mg/day oral gabapentin and is currently being monitored for adverse effects of long-term gabapentin therapy which include dizziness, somnolence, ataxia, confusion, asthenia, deficits in visual field, myopathy, self-harm behavior and suicidal tendency [11].

Subcutaneous injection of botulinum toxin in the affected regions of facial pain also provided symptomatic relief in many studies [3].

Surgical excision of the lesion is usually not recommended because of the risk of neurological deficit and post-operative neurogenic pain [5]. Limited arachnoid adhesiolysis may be done only if the patient has disabling neurologic symptoms [12].

### DIFFERENTIAL DIAGNOSIS

#### Lipoma

Lipomas are benign fat containing neoplasms that appear homogeneously hyperintense on T1 with signal suppression on fat suppressed images with or without thin septae (measuring < 2mm in thickness). They lack the characteristic co-axial cable or spaghetti-like appearance of lipomatosis due to lack of neural elements within [6].

#### Dermoid

Dermoids are heterogeneous masses commonly located along the midline. Variable MRI appearance of dermoids can be attributed to the varying amounts of intralesional fat, epidermal debris, hair etc. They are usually hyperintense on T1 (due to cholesterol), heterogeneous on T2 weighted images with or without calcification and rim enhancement along its wall. Enhancing solid component within the lesion may indicate malignant transformation [13]. The characteristic co-axial cable appearance is not seen due to the absence of neural elements.

#### Neurofibroma

Features favouring neurofibroma include a positive family history, bilaterality and cutaneous stigmata of neurofibromatosis. The presence of fat within the nerve sheath on MRI rules out neurofibroma [14].

#### Degenerated schwannoma

Schwannomas are encapsulated, eccentric neurogenic tumors that typically appear iso-to-hyperintense (compared to muscle) on T1 and hyperintense with central hypointensity giving 'target sign' on T2-weighted images. These tumors often show diffuse contrast enhancement. Larger lesions can undergo degeneration and show large non-enhancing cystic or hemorrhagic areas. Calcifications and bone erosions may be present [15].

### TEACHING POINT

- Lipomatosis of trigeminal nerve is a rare cause of trigeminal neuralgia.

- It closely mimics lipoma which causes extrinsic compression on the nerve and can be surgically removed. However, surgical attempt to excise the lesion can lead to significant neurological deficit in case of neural lipomatosis.
- Radiologists must be aware of this rare explanation of trigeminal neuralgia with characteristic imaging findings to prevent any inadvertent biopsy or surgical resection.

#### QUESTIONS

**Question 1:** Which of these is not true about neural lipomatosis?

1. It is a cause of trigeminal neuralgia.
2. It causes extrinsic neural compression. (applies)
3. It is the infiltration of the epineurium and perineurium by adipose and fibrous tissue.
4. Median nerve is the most commonly involved nerve.
5. Peripheral nerve lipomatosis may be associated with macrodystrophia lipomatosa.

Explanation:

1. [Patients most commonly present with pain, paraesthesia, tingling, numbness and focal neurological deficit] [Lipomatosis of trigeminal nerve is a rare cause of trigeminal neuralgia].
2. [Lipomatosis of trigeminal nerve is distinct from Meckel's cave lipoma] [Meckel's cave lipoma does not infiltrate the trigeminal nerve causing only extrinsic neural compression].
3. [Lipomatosis is the infiltration of the epineurium and perineurium by adipose and fibrous tissue with consequent enlargement of the trigeminal nerve].
4. [Lipomatosis of nerve, previously known by several names such as fibrolipomatous hamartoma, neural fibrolipoma and hamartomatous lipomatosis is a rare entity that most commonly involves the peripheral forearm nerves, median nerve being the most common].
5. [About one-third of the patients with peripheral nerve lipomatosis also develop macrodystrophia lipomatosa, the overgrowth of all mesenchymal elements of a digit or extremity along the territory of the affected nerve].

**Question 2:** Which of these applies to trigeminal lipomatosis?

1. It is a disease affecting elderly.
2. Females are more commonly affected.
3. Surgery is the recommended treatment.
4. Computed Tomography is the imaging modality of choice.
5. The growth of these lesions usually slows down in late adulthood. (applies)

Explanation:

- 1 & 2. [The condition mostly affects children and young adults with most patients presenting before third to fourth decades of life with no obvious gender predilection].
1. [Surgical excision of the lesion is usually not recommended because of the risk of neurological deficit or neurogenic pain post-operatively].
2. [Magnetic resonance imaging is the imaging modality of choice for diagnosis of this entity].
3. [These lesions grow rapidly in childhood with growth

continuing even after skeletal maturation. However, it usually slows down in late adulthood].

**Question 3:** Which of these is not true about imaging features of trigeminal lipomatosis?

1. The presence of thickened nerve fascicles surrounded by fat is the pathognomonic imaging finding.
2. It gives co-axial cable appearance on coronal section of the nerve. (applies)
3. It gives co-axial cable appearance on axial images.
4. The hypointense septae in the lesion correspond to fibrosis on histopathology.
5. The pathognomonic imaging findings on MRI obviate the need for biopsy.

Explanation:

- 1, 2 & 3. [The presence of thickened nerve fascicles (hypointense on T1 and T2-weighted sequences) surrounded by tissue with signal characteristics of fat (hyperintense on T1-weighted and intermediate signal intensity on T2-weighted sequences with signal drop on fat-suppressed images) giving coaxial-cable-like appearance on axial and spaghetti-like appearance on coronal plane of the nerve is considered pathognomonic].
4. [Axial sections may show thin T1 and T2 hypointense septae consistent with the characteristic pathological findings of thickened perineurium due to perineural fibrosis].
5. [These characteristic imaging findings obviate the need for biopsy].

**Question 4:** Which of these is not an imaging differential diagnosis of trigeminal lipomatosis?

1. Meckel's cave lipoma
2. Meckel's cave dermoid
3. Trigeminal schwannoma
4. Trigeminal neurofibroma
5. Dural solitary fibrous tumor (applies)

Explanation:

1, 2, 3 & 4. All these lesions are the imaging differentials of trigeminal lipomatosis because of either intralésional fat (in case of lipoma and dermoid) or neurogenic origin of the lesion and thus its extension along the course of the nerve (in case of schwannoma and neurofibroma).

5. Dural solitary fibrous tumor is not an imaging differential for trigeminal lipomatosis because of the presence of flow voids, vivid enhancement, dural tail, calcification and bone erosions, all of which are not seen in lipomatosis. The co-axial cable appearance of neural lipomatosis is not seen in dural solitary fibrous tumor because of the lack of neural elements within.

**Question 5:** Which of these statements about trigeminal lipomatosis is false?

1. It is a hamartoma.
2. The condition is more common in white population.
3. Sonography can be done to assess the extent of the lesion. (applies)
4. Limited arachnoid adhesiolysis may be attempted in some cases.
5. Surgery may lead to post-operative pain and neurological deficit.

## Explanation:

1. [Lipomatosis of nerve, previously known by several names such as fibrolipomatous hamartoma, neural fibrolipoma and hamartomatous lipomatosis is a rare entity] [Lipomatosis is described as a hamartoma and not a neoplasm].

2. [White population has higher predisposition for developing neural lipomatosis].

3. [Sonography cannot be used to assess cranial nerve lipomatosis].

4 & 5. [Surgical excision of the lesion is usually not recommended because of the risk of neurological deficit or neurogenic pain post-operatively. Limited arachnoid adhesiolysis may be done only if the patient has disabling neurologic symptoms].

## REFERENCES

- 1). Maratos EC, Goicochea MT, Condomí-Alcorta S, Mormandi R, Salvat J, Cervio A. Lipomatosis of the trigeminal nerve causing trigeminal neuralgia: case report and literature review. *Skull Base*. 2010; 20(04): 293-299. PMID: 21311625.
- 2). Philp L, Naert KA, Ghazarian D. Fibrolipomatous Hamartoma of the nerve arising in the neck: a case report with review of the literature and differential diagnosis. *Am J Dermatopathol*. 2015; 37(7): e78-e82. PMID: 25033011.
- 3). Gambeta E, Chichorro JG, Zamponi GW. Trigeminal neuralgia: An overview from pathophysiology to pharmacological treatments. *Mol Pain*. 2020; 16: 1744806920901890. PMID: 31908187.
- 4). Truwit CL, Barkovich AJ. Pathogenesis of intracranial lipoma: an MR study in 42 patients. *Am J Neuroradiol*. 1990; 11: 665-674. PMID: 21510446.
- 5). Razzaghi A, Anastakis DJ. Lipofibromatous hamartoma: review of early diagnosis and treatment. *Can J Surg*. 2005; 48(5): 394-399. PMID: 16248139
- 6). Gupta P, Potti TA, Wuertzer SD, Lenchik L, Pacholke DA. Spectrum of fat-containing soft-tissue masses at MR imaging: the common, the uncommon, the characteristic, and the sometimes confusing. *Radiographics*. 2016; 36(3): 753-766. PMID: 27163592.
- 7). Toms AP, Anastakis D, Bleakney RR, Marshall TJ. Lipofibromatous hamartoma of the upper extremity: a review of the radiologic findings for 15 patients. *AJR Am J Roentgenol*. 2006; 186: 805-811. PMID: 16498111.
- 8). Senger JL, Classen D, Bruce G, Kanthan R. Fibrolipomatous hamartoma of the median nerve: a cause of acute bilateral carpal tunnel syndrome in a three-year-old child: a case report and comprehensive literature review. *Plast Surg (Oakv)*. 2014; 22(3): 201-206. PMID: 25332651
- 9). Sarp AF, Pekcevik Y. Giant lipomatosis of the sciatic nerve: unique magnetic resonance imaging findings. *Iran J Radiol*. 2016; 13(2): e20963. PMID: 27679695.
- 10). Torigian DA, Siegelman ES. CT findings of pelvic lipomatosis of nerve. *AJR Am J Roentgenol*. 2005; 184(3): S94-S96. PMID: 15728036.
- 11). Quintero GC. Review about gabapentin misuse, interactions, contraindications and side effects. *J Exp Pharmacol*. 2017; 9: 13-21. PMID: 28223849.
- 12). Sureka J, Panwar S, Jakkani RK. Lipoma of trigeminal nerve in a patient with severe trigeminal neuralgia. *Neurol Clin Pract*. 2011; 1(1): 78-79. PMID: 29443298.
- 13). Jacków J, Tse G, Martin A, Sasiadek M, Romanowski C. Ruptured intracranial dermoid cysts: a pictorial review. *Pol J Radiol*. 2018; 83: e465-e470. PMID: 30655926.
- 14). Yadav T, Mirza G, Khera PS, Garg P. Macrodystrophia lipomatosa with fibrolipomatous hamartoma of medial plantar nerve and lipomatosis of thigh. *Sudan J Paediatr*. 2020; 20(1): 62-67. PMID: 32528203.
- 15). Isobe K, Shimizu T, Akahane T, Kato H. Imaging of ancient schwannoma. *AJR Am J Roentgenol*. 2004; 183(2): 331-336. PMID: 15269020.

FIGURES

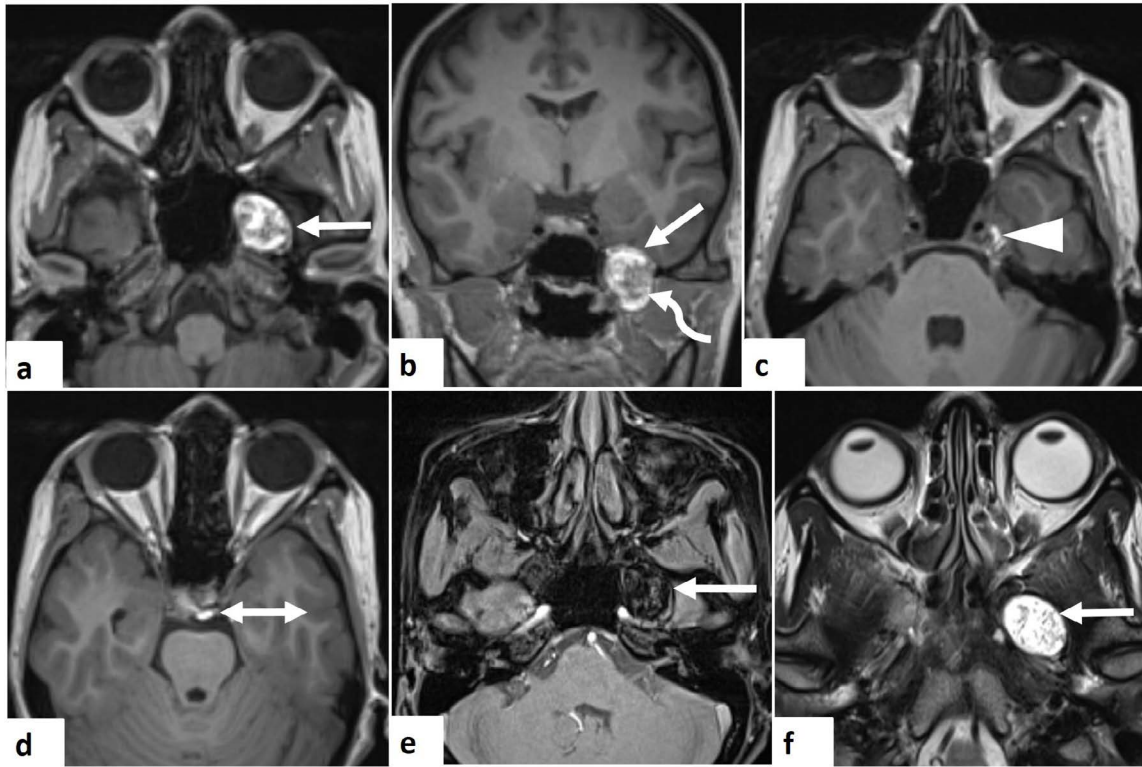


Figure 1A: 23-year-old female with left trigeminal nerve lipomatosis.

FINDINGS: Axial (a) and coronal (b) T1 weighted MPRAGE images depict a well-circumscribed hyperintense lesion with multiple punctate hypointense areas within in left Meckel’s cave involving the trigeminal ganglion (straight arrow in a, b) extending via the widened foramen ovale into left infratemporal fossa (curved arrow in b). A small proximal extension of the lesion is seen along the left main trigeminal nerve (arrowhead in c) into the prepontine cistern (double arrow in d). The lesion shows signal suppression on T1 VIBE FS image (arrow in e) suggestive of fat. On T2 weighted axial image (f), the lesion (arrow) appears hyperintense with hypointense areas within.

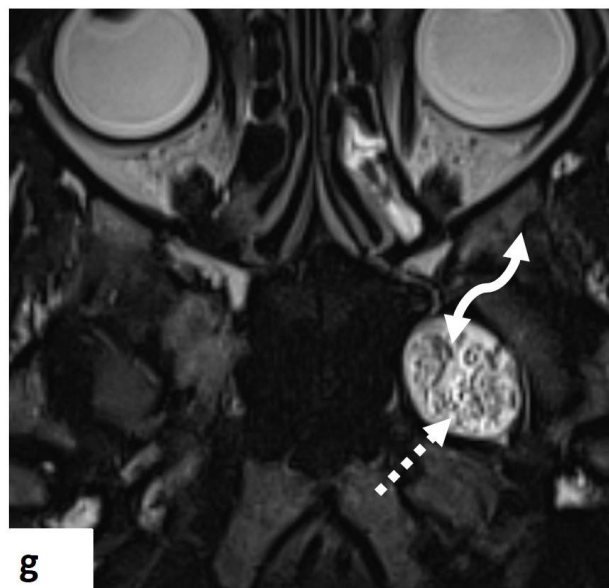
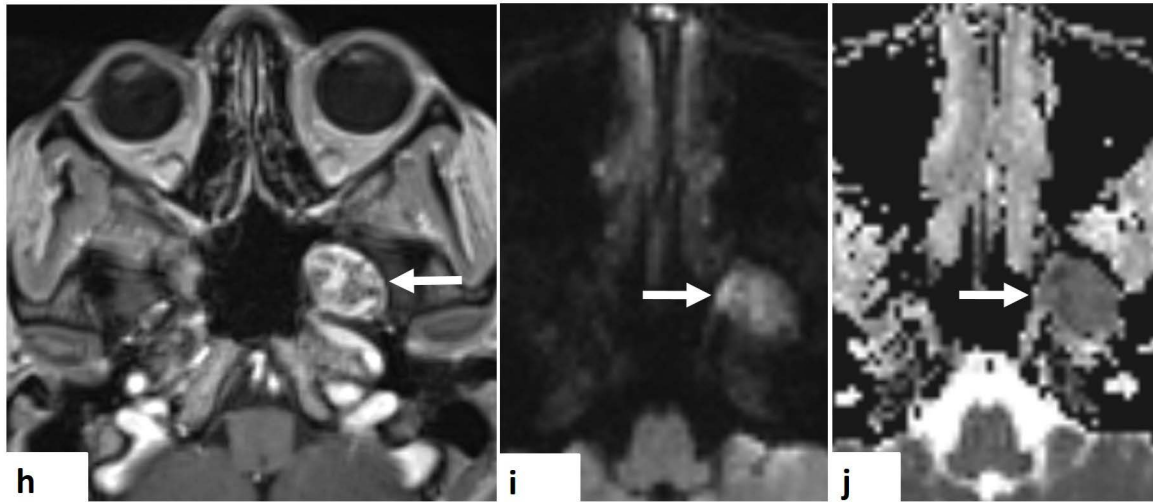


Figure 1B: 23-year-old female with left trigeminal nerve lipomatosis.

FINDINGS: Axial T2 SPACE MR image (g) better depicts the punctate and serpiginous hypointensities within the lesion. The punctate hypointensities (dashed arrow) represent prominent nerve fascicles giving the ‘co-axial cable’ appearance while the serpiginous hypointensities (curved double arrow) mark the fibrotic component of the lesion.



**Figure 1C: 23-year-old female with left trigeminal nerve lipomatosis.**

**FINDINGS:** The lesion does not show significant enhancement on post-contrast axial T1 MPRAGE MR image (h). Axial DWI (i) and corresponding ADC map (j) show diffusion restriction within the lesion.

**TECHNIQUE:** 3T MR scanner- MAGNETOM SKYRA (Siemens, Erlangen, Germany), images acquired in supine position using head coil.

Non-contrast T1W MPRAGE (Magnetization prepared Rapid Gradient echo) axial and coronal [TR : 1660ms, TE : 2.5ms],

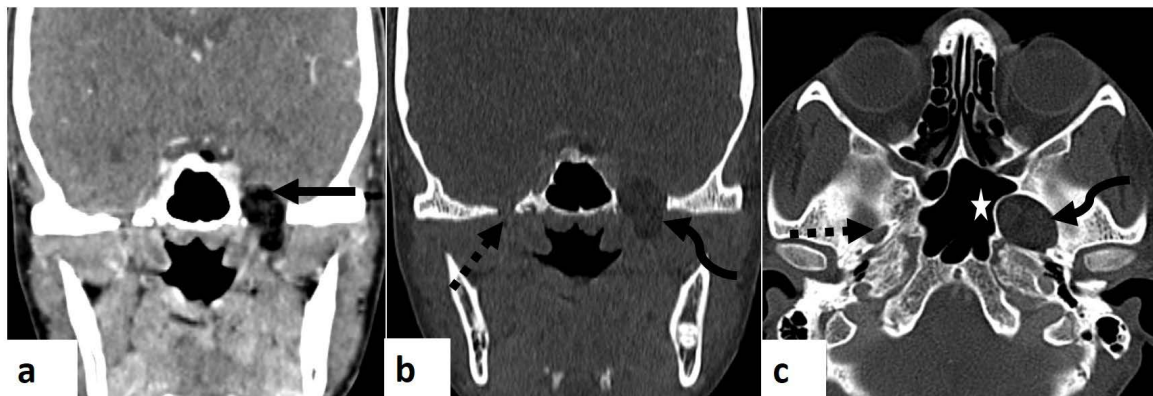
T1 VIBE FS (Volumetric interpolated breath-hold examination with fat saturation) axial [TR : 18ms, TE : 3.7ms],

T2W axial [TR : 3000ms, TE : 78ms ],

T2 SPACE (Sampling perfection with application-optimized contrasts using different flip angle evolution) axial [TR : 1000ms, TE : 125ms],

Contrast-enhanced axial T1W MPRAGE image acquired after intravenous 0.1 mmol/kg body weight of Gadopentetate dimeglumine (Magnascan, Unijules Life Sciences Ltd, India) [TR : 1660ms, TE : 2.5ms ],

DWI (Diffusion weighted image) and corresponding ADC (Apparent diffusion coefficient) map, Single Shot echoplanar sequence at b values- 0,1000 s/mm<sup>2</sup> [TR : 5580ms, TE : 59ms]



**Figure 2: 23-year-old female with left trigeminal nerve lipomatosis.**

**FINDINGS:** Coronal CECT image of skull base in soft tissue window (a) reveals a dumb-bell shaped lesion of fat attenuation in left Meckel's cave extending across left foramen ovale into the infratemporal fossa. Coronal (b) and axial (c) CT images in bone window show the widened left foramen ovale (curved arrow). Note the normal right foramen ovale (dashed arrow in b, c). Smooth scalloping of the left lateral wall of sphenoid sinus with no obvious bony destruction is appreciated in c (\*).

**TECHNIQUE:** 128 slice, SIEMENS SOMATOM Definition AS+, contrast-enhanced CT scan [165 mAs 120 kV, 1 mm slice thickness] acquired 60 seconds after intravenous contrast injection in the venous phase (60 mL of non-ionic contrast medium; Omnipaque 350mgI/mL, GE Healthcare, USA). Soft tissue window level: 50 and window width: 250. Bone window level: 450 and window width: 1500.

**Table 1: Summary table of trigeminal lipomatosis**

<b>Etiology</b>	Unclear; infiltration of the epineurium and perineurium by adipose and fibrous tissue with consequent enlargement of the trigeminal nerve
<b>Incidence</b>	Rare entity; with only very few case reports existing in literature
<b>Gender ratio</b>	No obvious gender predilection
<b>Age predilection</b>	Children and young adults, most patients presenting before 3 <sup>rd</sup> -4 <sup>th</sup> decades of life
<b>Risk factors</b>	Few case reports describe the condition to be more common in whites
<b>Treatment</b>	Conservative. Limited arachnoid adhesiolysis can be attempted only in case of disabling symptoms
<b>Prognosis</b>	Variable
<b>Findings on imaging</b>	<b>MRI:</b> Thickened nerve fascicles (hypointense on T1 and T2-weighted sequences) surrounded by fat (hyperintense on T1- and intermediate signal intensity on T2-weighted sequences with signal drop on fat-suppressed images) give coaxial-cable-like appearance on axial and spaghetti-like appearance on coronal plane of the nerve <b>CT:</b> Fat density lesion causing widening of foramen ovale

**Table 2: Differential diagnosis table for trigeminal lipomatosis**

<b>DIFFERENTIAL DIAGNOSIS</b>	<b>CT</b>	<b>MRI</b>
Trigeminal lipomatosis	Hypodense lesion of fat attenuation causing foraminal widening and extending along the course of the nerve	Hypointense nerve fascicles surrounded by fat giving co-axial cable or spaghetti like appearance to the enlarged nerve on axial and coronal images respectively
Meckel's cave lipoma	Hypodense lesion of fat attenuation in the meckel's cave, not extending along the course of the nerve	Extrinsic to the trigeminal nerve; absence of co-axial cable appearance due to lack of neural elements within
Meckel's cave dermoid cyst	Heterogeneous with variable amount of fat, fluid, calcification with or without enhancing solid component within, the latter pointing towards malignant transformation	Extrinsic to the trigeminal nerve; heterogeneous on T2 weighted images with absence of neural elements within
Trigeminal nerve neurofibroma	Extend across the course of the trigeminal nerve causing foraminal widening and remodelling; however lack fat density within the lesion	Show 'target sign' on T2 weighted images with absence of fat on T1 and T1 weighted fat suppressed images
Trigeminal nerve schwannoma	Extend across the course of the nerve; calcifications, cystic, hemorrhagic areas and bone erosions may be present	Heterogeneous on T2 weighted images and give 'target sign' with diffuse or heterogeneous post-contrast enhancement; cystic/hemorrhagic areas may be present

**ABBREVIATIONS**

MRI = Magnetic Resonance Imaging; CT = Computed Tomography

**KEYWORDS**

trigeminal neuralgia; lipomatosis; fibrolipomatous hamartoma; meckels cave; foramen ovale; magnetic resonance imaging; computed tomography

**Online access**

This publication is online available at:  
[www.radiologycases.com/index.php/radiologycases/article/view/4709](http://www.radiologycases.com/index.php/radiologycases/article/view/4709)

**Peer discussion**

Discuss this manuscript in our protected discussion forum at:  
[www.radiopolis.com/forums/JRCR](http://www.radiopolis.com/forums/JRCR)

**Interactivity**

This publication is available as an interactive article with scroll, window/level, magnify and more features.  
Available online at [www.RadiologyCases.com](http://www.RadiologyCases.com)

Published by EduRad



[www.EduRad.org](http://www.EduRad.org)