

Beyond the Outer Rim: A Case of Disseminated Peritoneal Leiomyomas

Victoria Reick-Mitrison¹, Karthik Padmanabhan, MD^{2,3*}, Mohammed Hussain, MD^{2,3}, Mohamed Jaber, MD², Kevin Carter, DO²

¹Kirkville College of Osteopathic Medicine, A.T. Still University, USA

²Department of Radiology, McLaren Oakland Hospital, USA

³Department of Radiology, Michigan State University, USA

*Correspondence: Karthik Padmanabhan, Department of Radiology, McLaren Oakland Hospital, 50 Perry St, Pontiac, MI 48342, USA

✉ karthik.padmanabhan@mclaren.org

Radiology Case. 2024 November; 18(11):24-33 :: DOI: 10.3941/jrcr.4708

ABSTRACT

Leiomyomatosis peritonealis disseminata (also known as disseminated peritoneal leiomyomas) is a rare disorder consisting of multiple soft tissue masses dispersed throughout the abdominal and pelvic peritoneum, histologically characterized by benign smooth muscle bundles without atypia or mitotic activity. Although more commonly confined to the uterine parenchyma (i.e. uterine fibroids), extension to surrounding structures may rarely occur. Such benign masses may be easily mistaken for more aggressive and malignant etiologies, and if mistaken, may cause psychological stress, time-consuming workup, and unnecessary cost to the patient. Given this possibility, it is important to consider this differential diagnosis among more worrisome pathologies such as lymphoma, metastatic ovarian cancer, or peritoneal carcinomatosis. We present the case of an adult female who initially presented with sharp epigastric abdominal pain, in which subsequent workup revealed the presence of multiple soft tissue lesions scattered throughout the abdomen and pelvis. These lesions were initially misconstrued to be malignant, however, subsequently biopsy-proven to be leiomyomatous tissue in origin.

CASE REPORT

CASE REPORT

A 43-year-old female with no pertinent past medical history presented to the emergency department with a chief complaint of acute-onset sharp epigastric abdominal pain and nausea. No significant weight loss, menorrhagia, or dysmenorrhea was reported. The patient reported no known pertinent family history and a remote history of 2 prior cesarean sections. She reported no recreational drug, tobacco, or excessive alcohol consumption. The patient was afebrile and normotensive. Physical exam showed no abdominal findings suggestive of peritonitis. A complete blood count, metabolic panel, and urinalysis were normal. However, a CT scan of her abdomen and pelvis revealed numerous rounded soft tissue lesions of similar morphology within the pelvis, right abdomen, and left lower abdomen – one such lesion was seen along the anterior uterus. There was subtle stranding of the left lower omental fat. Given the patient's presenting symptoms, an abdominal ultrasound was also performed, demonstrating findings indicative of acute cholecystitis. This was concordant with subsequent HIDA scan revealing a probable cystic duct obstruction.

Following surgical and oncologic consultations, the patient was admitted for further evaluation and treatment. Presenting symptoms significantly improved with conservative management and no acute surgical intervention was advised. She subsequently underwent a CT-guided biopsy of the largest lesion in the left lower abdomen. She was discharged pending biopsy results as well as a recommendation for elective laparoscopic cholecystectomy. Pathologic analysis of the tissue sample revealed the abundant presence of smooth muscle bundles without cytologic atypia with further immunohistochemistry staining supportive of a diagnosis of an intra-abdominal leiomyoma. The patient was informed of the non-malignant findings and was advised to follow-up with her primary care provider.

DISCUSSION

Etiology & Demographics

Uterine fibroids are the most common benign tumor of the female genital tract. Incidence has been reported to occur in approximately 20-70% of women, classically amongst premenopausal women, with a greater propensity amongst Black

women overall [1-3]. Extrauterine leiomyomas occur more rarely, and even less frequently when discovered at sites distant from the uterus within the peritoneum. Distal involvement is seen in less than 1 out of every one million, with approximately 130-150 cases documented in literature [4,5]. The precise etiology of fibroids is unknown, however association with hormonal levels has been implicated. Peritoneal spread has been hypothesized to be related to metaplasia of the peritoneal connective tissue due to hormonal stimulation [6,7]. Lesions may fluctuate in size based on hormonal exposure and can decrease in size after menopause.

Mutations in the gene encoding fumarate hydratase, a mitochondrial enzyme involved in the tricarboxylic acid cycle have also been implicated with fibroid syndromes such as hereditary leiomyomatosis and renal cell carcinoma [1]. Although the pathophysiology is not well understood, such mutations have been implicated in metabolic alterations due to accumulated fumarate interfering with various enzyme and signaling pathways which promote cell proliferation. Additionally, elevated fumarate has been associated with dysregulation of the hypoxia inducible factor pathway, resulting in a favorable microenvironment for tumor growth [8, 9].

Leiomyomas may spread intravenously to parametria, and subsequently the vena cava, with reports of lesions seen in the retroperitoneum, urinary bladder, urethra, vulva, and intraluminally within the intrauterine and systemic venous vasculature [10]. Dissemination has also rarely been reported in the literature on a post-operative basis and was also considered as a possible etiology in our patient, given her prior history of cesarian delivery [11].

Clinical & Imaging Findings

Clinical presentation is often nonspecific or may even be asymptomatic. Patients may exhibit a variety of symptoms such as abdominal pain, menorrhagia, or oligomenorrhea, as well as symptoms which result from mass effect on regional structures. Lesions are typically discovered incidentally, with US and CT often the initial imaging modalities. In our case, such modalities were chosen due to their relative ease of availability in the acute setting and as part of the emergent evaluation to exclude other pathologies such as pancreatitis, cholecystitis, ovarian torsion, or acute appendicitis. CT demonstrates the presence of smaller soft tissue nodularities or larger lesions along or within the peritoneal structures [12]. As with uterine fibroids, peritoneal lesions may appear as heterogenous or homogenous on contrast-enhanced studies, with similar appearing morphology. As in our patient, lesions appeared as similar circumscribed nodules and masses with relatively uniform density (HU 56-63) and no appreciable contrast enhancement compared to adjacent viscera. On ultrasound, fibroids may be detected on both transvaginal and transabdominal approaches as well-defined nodules or masses with variable echogenicity and posterior acoustic shadowing. Internal calcifications may be observed on all modalities, demonstrated sonographically as echogenic foci. It is important to note that isoechoic lesions may conceal the

diagnosis, with uterine contour abnormalities providing the only imaging clue [13].

PET-CT may be performed in which the lesions exhibit no increased FDG uptake, characterizing them from malignant processes [14]. Although not performed at our institution, T1 and T2 weighted MR imaging can demonstrate circumscribed lesions of low signal intensity similar to surrounding smooth and skeletal musculature – post-contrast imaging shows homogenous enhancement [2,12].

Treatment & Prognosis

Current treatment and prognosis of disseminated uterine fibroids is largely based on the patient's clinical presentation, location of the lesions, age, and desire for future fertility. Although lesions are characterized by benign features histologically, malignant sarcomatous transformation has been reported in the literature and due to this risk, some surgeons may opt for hysterectomy and oophorectomy with possible peritoneal debulking [15-17]. However, no current consensus exists regarding surgical intervention [18]. Lesions are often managed conservatively, however close surveillance is advised [12,19]. At this point, PET-CT may be considered to monitor for potential malignant transformation. Comorbid symptoms including vaginal bleeding and constipation have also been described and management may be guided by these factors as well [20]. Medical management may include contraceptives, tranexamic acid, nonsteroidal anti-inflammatories, or gonadotropin releasing hormone agonists. Given their association with hormonal levels, lesions may also regress following menopause. In our case, the patient experienced no further symptoms following interval cholecystectomy a few weeks after initial presentation and elected to undergo conservative oncologic surveillance, declining further surgical and medical intervention at this time.

DIFFERENTIALS

Peritoneal carcinomatosis:

Presentation may be similar to other malignancies, such as unintended weight loss, nausea, vomiting, and the presence of ascites. Determination of risk factors and pertinent past medical history is also helpful. CT images may feature thickening, nodularity, and contrast enhancement of the peritoneal reflections with possible loculated ascites, none of which were discernable in our case. Large amounts of peritoneal thickening may also result in plaquing such as omental caking. Involvement of the abdominal viscera can cause a scalloped appearance of the parenchymal surfaces.

Lymphoma:

Lymphomatous malignancy is another consideration, given the distribution of findings in our case. However, such etiologies would be more likely to include a clinical history of non-specific B-symptoms such as fevers, chills, night sweats, and unintended weight loss. Furthermore, cell count derangements are more likely, in contrast to our patient. Cross sectional imaging may

also show involvement of the retroperitoneal lymphatic chains; however, this was not apparent in our case.

Ovarian torsion:

Differential diagnosis was considered clinically in the setting of a premenopausal female presenting in the acute setting with abdominal pain. However, this diagnosis was deemed less likely in the setting of symptoms localizing to the epigastric abdomen with no significant findings on physical exam to suggest peritonitis. Furthermore, CT imaging demonstrated non enlarged adnexal soft tissue densities favored to relate to the ovaries without cystic changes, nor twisting of the ovarian vascular pedicle. No regional inflammatory changes of the adnexal fat planes were identified.

TEACHING POINT

Disseminated peritoneal leiomyomatosis is a rare benign condition, in which the precise etiology is not fully understood. Its discovery in the presenting patient may be misconstrued for more malignant etiologies. Although it is uncommon, it is important to include this diagnosis on the differential. Doing so may not only prevent misdiagnosis, but also prevent unnecessary psychological stress, extensive workup, and cost to the patient. Early detection may also guide more appropriate management, and while treatment largely rests on conservative management, medical and surgical interventions may be considered in the setting of the patient’s symptoms and history. Continued surveillance is advised due to the small but non-zero possibility of sarcomatous transformation.

QUESTIONS

1. Which of the following answer choices is false?

- 1. Uterine fibroids are the most common malignant tumor of the female genital tract.
- 2. Black women are more commonly affected by fibroids.
- 3. Hormonal stimulation of peritoneal connective tissue is linked to peritoneal spread of fibroids.
- 4. Fibroids are sensitive to hormones.
- 5. Extrauterine leiomyomas are rare.

Explanation

- 1. **Uterine fibroids are the most common malignant tumor of the female genital tract.** [Uterine fibroids are the most common tumor of the female genital tract.]
- 2. Black women are more commonly affected by fibroids. [Incidence has been reported to occur in approximately 20-70% of women, with a greater propensity amongst black women overall [3,8,9].]
- 3. Hormonal stimulation of peritoneal connective tissue is linked to peritoneal spread of fibroids. [Peritoneal spread has been hypothesized to be related to metaplasia of the peritoneal connective tissue due to hormonal stimulation.]
- 4. Fibroids have been shown to be associated with hormones. [The precise etiology of fibroids is unknown, however association with hormonal levels has been implicated.]

- 5. Extrauterine leiomyomas are rare. [Extrauterine leiomyomas occur more rarely, and even less frequently when discovered at sites distant from the uterus within the peritoneum.]

2. Choose the enzyme associated with fibroid syndrome.

- 1. Aminolevulinic acid synthetase
- 2. Carbonic anhydrase-3
- 3. Fumarate hydratase
- 4. Acetaldehyde dehydrogenase
- 5. Hexokinase

Explanation

- 1. Aminolevulinic acid synthetase [Cases of fibroid syndromes have also been associated with the gene encoding fumarate hydratase, a mitochondrial enzyme].
- 2. Carbonic anhydrase-3 [Cases of fibroid syndromes have also been associated with the gene encoding fumarate hydratase, a mitochondrial enzyme.]
- 3. **Fumarate hydratase** [Cases of fibroid syndromes have also been associated with the gene encoding fumarate hydratase, a mitochondrial enzyme.]
- 4. Acetaldehyde dehydrogenase [Cases of fibroid syndromes have also been associated with the gene encoding fumarate hydratase, a mitochondrial enzyme.]
- 5. Hexokinase [Cases of fibroid syndromes have also been associated with the gene encoding fumarate hydratase, a mitochondrial enzyme.]

3. Which of the following is true?

- 1. Fibroids are not radiotracer-avid on positron emission tomography.
- 2. Fibroids demonstrate posterior acoustic enhancement on ultrasound.
- 3. Treatment of disseminated uterine fibroids is based on positron emission tomographic-characteristics.
- 4. Fibroids are more commonly seen in post-menopausal women.
- 5. Fibroids have no potential for malignant transformation.

Explanation

- 1. **Fibroids are not radiotracer-avid on positron emission tomography.** [PET-CT may be performed in which the lesions exhibit no increased FDG uptake, characterizing them from malignant processes.]
- 2. Fibroids demonstrate posterior acoustic enhancement on ultrasound. [On ultrasound, fibroids may be detected on both transvaginal and transabdominal approaches as well-defined nodules or masses with variable echogenicity and posterior acoustic shadowing.]
- 3. Treatment of disseminated uterine fibroids is based on positron emission tomographic-characteristics. [Current treatment of multiple uterine fibroids is largely based on the patient’s clinical presentation, location of the lesions, age, and desire for future fertility.]

- Fibroids are more commonly seen in post-menopausal women. [Most often discovered in women of reproductive age.]
- Fibroids have no potential for malignant transformation. [Although lesions are characterized by benign features histologically, malignant sarcomatous transformation has been reported in the literature.]

4. Which of the following CT findings are sensitive for peritoneal carcinomatosis? (select all that apply)

- Peritoneal thickening and contrast enhancement
- Soft tissue plaques outlining the omentum
- Loculated ascites
- Encasement of vasculature
- Pneumoperitoneum

Explanation

- Peritoneal thickening and contrast enhancement.** [CT images may feature thickening, nodularity, and contrast enhancement of the peritoneal reflections with possible loculated ascites].
- Soft tissue plaques outlining the omentum.** [CT images may feature thickening, nodularity, and contrast enhancement of the peritoneal reflections with possible loculated ascites].
- Loculated ascites** [CT images may feature thickening, nodularity, and contrast enhancement of the peritoneal reflections with possible loculated ascites].
- Encasement of vasculature. [Encasement of vasculature is not a common finding of peritoneal carcinomatosis. This may be seen with other etiologies such as retroperitoneal fibrosis.]
- Pneumoperitoneum. [Pneumoperitoneum is caused by various etiologies such as trauma, recent surgery, or bowel ischemia. For peritoneal carcinomatosis, CT images may feature thickening, nodularity, and contrast enhancement of the peritoneal reflections with possible loculated ascites].

5. Which of the following treatments is not indicated for disseminated leiomyomatosis?

- Tranexamic acid
- Non-steroidal anti-inflammatory drugs
- Gonadotropin releasing hormone agonists
- Methotrexate
- Metformin

Explanation

- Tranexamic acid [Medical management may include contraceptives, tranexamic acid, nonsteroidal anti-inflammatories, or gonadotropin releasing hormone agonists.]
- Non-steroidal anti-inflammatory drugs [Medical management may include contraceptives, tranexamic acid, nonsteroidal anti-inflammatories, or gonadotropin releasing hormone agonists.]

- Gonadotropin releasing hormone agonists [Medical management may include contraceptives, tranexamic acid, nonsteroidal anti-inflammatories, or gonadotropin releasing hormone agonists.]
- Methotrexate** [Medical management may include contraceptives, tranexamic acid, nonsteroidal anti-inflammatories, or gonadotropin releasing hormone agonists.]
- Metformin [Medical management may include contraceptives, tranexamic acid, nonsteroidal anti-inflammatories, or gonadotropin releasing hormone agonists.]

AUTHOR CONTRIBUTIONS

- Lead author: Victoria Reick-Mitrisin
- Co-authors: Karthik Padmanabhan, Mohammed Hussain, Mohamed Jaber, Kevin Carter
- Supervising faculty: Mohamed Jaber, Kevin Carter

ACKNOWLEDGEMENTS

Yillian Li, MD – pathology specimen images

DISCLOSURES

There are no financial disclosures or competing interests.

CONSENT

Yes. Written informed consent was appropriately obtained from the patient.

REFERENCES

- Okolo S. Incidence, aetiology and epidemiology of uterine fibroids. *Best Pract Res Clin Obstet Gynaecol.* 2008; 22(4): 571-588. PMID: 18534913.
- Stewart EA, Cookson CL, Gandolfo RA, Schulze-Rath R. Epidemiology of uterine fibroids: a systematic review. *BJOG.* 2017; 124(10): 1501-1512. PMID: 28296146.
- Szklaruk J, Tamm EP, Choi H, Varavithya V. MR imaging of common and uncommon large pelvic masses. *Radiographics.* 2003; 23(2): 403-424. PMID: 12640156.
- Soni S, Pareek P, Narayan S. Disseminated peritoneal leiomyomatosis: an unusual presentation of intra-abdominal lesion mimicking disseminated malignancy. *Med Pharm Rep.* 2020; 93(1): 113-116. PMID: 32133455.
- Al-Talib A, Tulandi T. Pathophysiology and possible iatrogenic cause of leiomyomatosis peritonealis disseminata. *Gynecol Obstet Invest.* 2010; 69(4): 239-244. PMID: 20068330.
- Drake A, Dhundee J, Buckley CH, Woolas R. Disseminated leiomyomatosis peritonealis in association with oestrogen secreting ovarian fibrothecoma. *BJOG.* 2001; 108(6): 661-664. PMID: 11426907.

7. Tavassoli FA, Norris HJ. Peritoneal leiomyomatosis (leiomyomatosis peritonealis disseminata): a clinicopathologic study of 20 cases with ultrastructural observations. *Int J Gynecol Pathol.* 1982; 1(1): 59-74. PMID: 7184891.
8. Poon E, Harris AL, Ashcroft M. Targeting the hypoxia-inducible factor (HIF) pathway in cancer. *Expert Rev Mol Med.* 2009; 11: e26. PMID: 19709449.
9. Kerins MJ, Vashisht AA, Liang BX, et al. Fumarate Mediates a Chronic Proliferative Signal in Fumarate Hydratase-Inactivated Cancer Cells by Increasing Transcription and Translation of Ferritin Genes. *Mol Cell Biol.* 2017; 37(11): e00079-17. PMID: 28289076.
10. Barnaś E, Raś R, Skręt-Magierło J, et al. Natural history of leiomyomas beyond the uterus. *Medicine (Baltimore).* 2019; 98(25): e15877. PMID: 31232922.
11. Kumar S, Sharma JB, Verma D, Gupta P, Roy KK, Malhotra N. Disseminated peritoneal leiomyomatosis: an unusual complication of laparoscopic myomectomy. *Arch Gynecol Obstet.* 2008 Jul; 278(1): 93-95. PMID: 18193441.
12. Fasih N, Prasad Shanbhogue AK, Macdonald DB, et al. Leiomyomas beyond the uterus: unusual locations, rare manifestations. *Radiographics.* 2008; 28(7): 1931-1948. PMID: 19001649.
13. Woźniak A, Woźniak S. Ultrasonography of uterine leiomyomas. *Prz Menopauzalny.* 2017; 16(4): 113-117. PMID: 29483851.
14. Talebian Yazdi A, De Smet K, Antic M, Ilse B, Vandembroucke F, de Mey J. Leiomyomatosis peritonealis disseminata in a 50-year-old woman: imaging findings. *JBR-BTR.* 2010; 93(4): 193-195. PMID: 20957890.
15. Raspagliesi F, Quattrone P, Grosso G, Cobellis L, Di Re E. Malignant degeneration in leiomyomatosis peritonealis disseminata. *Gynecol Oncol.* 1996; 61(2): 272-274. PMID: 8626146.
16. Abulafia O, Angel C, Sherer DM, Fultz PJ, Bonfiglio TA, DuBeshter B. Computed tomography of leiomyomatosis peritonealis disseminata with malignant transformation. *Am J Obstet Gynecol.* 1993; 169(1): 52-54. PMID: 8333475.
17. Fulcher AS, Szucs RA. Leiomyomatosis peritonealis disseminata complicated by sarcomatous transformation and ovarian torsion: presentation of two cases and review of the literature. *Abdom Imaging.* 1998; 23(6): 640-644. PMID: 9922202.
18. Julien C, Bourgoignie S, Boudin L, Balandraud P. Disseminated Peritoneal Leiomyomatosis. *J Gastrointest Surg.* 2019; 23(3): 605-607. PMID: 29959641.
19. Hiremath SB, Benjamin G, Gautam AA, Panicker S, Rajan A. Disseminated peritoneal leiomyomatosis: a rare cause of enigmatic peritoneal masses. *BJR Case Rep.* 2016; 2(3): 20150252. PMID: 26243359.
20. Bayrak S, Pasaoglu E, Cakar E, et al. Disseminated peritoneal leiomyomatosis with chronic constipation: a case report. *J Med Case Rep.* 2014; 8: 114. PMID: 24708548.
21. Barnaś E, Książek M, Raś R, Skręt A, Skręt-Magierło J, Dmoch-Gajzlerska E. Benign metastasizing leiomyoma: A review of current literature in respect to the time and type of previous gynecological surgery. *PLoS One.* 2017; 12(4): e0175875. PMID: 285398563.
22. De La Cruz MS, Buchanan EM. Uterine Fibroids: Diagnosis and Treatment. *Am Fam Physician.* 2017; 95(2): 100-107. PMID: 28084714.
23. Pannu HK, Bristow RE, Montz FJ, Fishman EK. Multidetector CT of peritoneal carcinomatosis from ovarian cancer. *Radiographics.* 2003; 23(3): 687-701. PMID: 12740470.
24. Levy AD, Shaw JC, Sobin LH. Secondary tumors and tumorlike lesions of the peritoneal cavity: imaging features with pathologic correlation. *Radiographics.* 2009; 29(2): 347-73. PMID: 19325052.

FIGURES

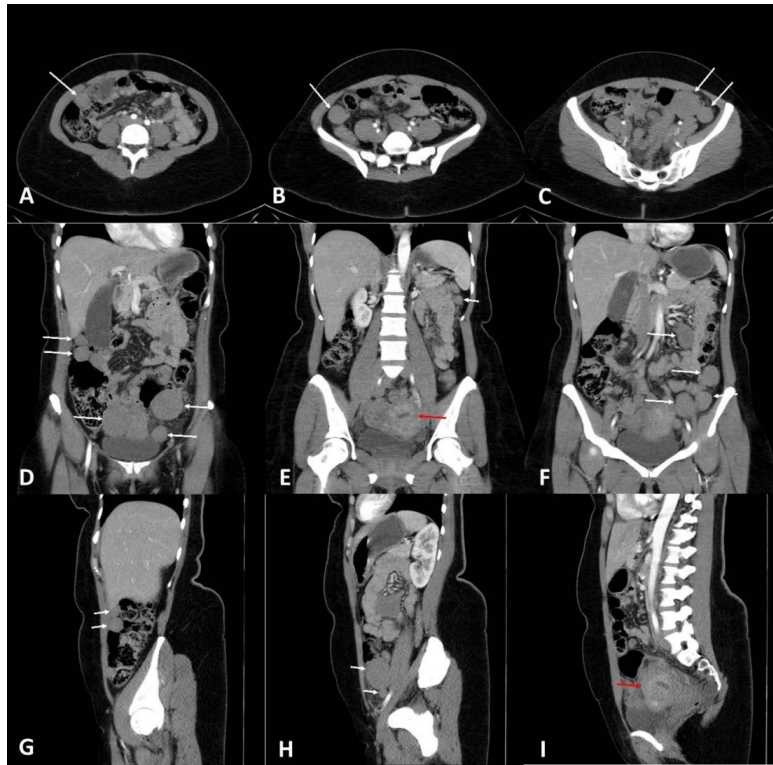

Figure 1: 43-year-old female with peritoneal soft tissue lesions. These lesions were biopsy-proven to be leiomyomatous in origin.

Technique: Contrast enhanced computed tomography (CECT) scan of the abdomen and pelvis obtained during arterial phase (Phillips, 128 mAs, 120 kV, CTDIvol: 8.4 mGy, DLP: 430.7 mGy*m. 5mm slice thickness, 100 mL Isovue 300).

Findings: Axial (A-C), coronal (D-F), and sagittal (G-I) images demonstrating innumerable homogenous rounded soft tissue lesions within the abdominal and pelvic peritoneal spaces with similar appearing morphology and density (white arrows). Of note, there is a globular and heterogenous appearance of the uterus (red arrows). Incidentally seen is a dilated gallbladder containing subtle hyperdense debris.

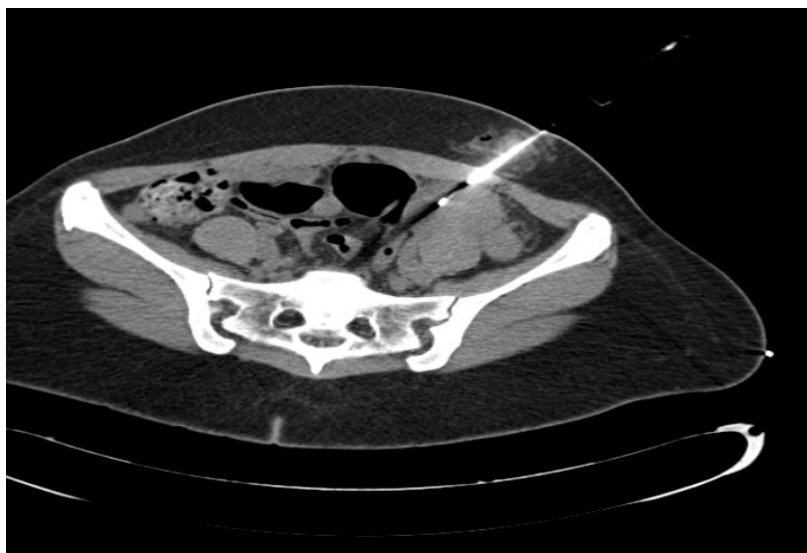

Figure 2: 43-year-old female with peritoneal soft tissue lesions found to be leiomyomatous in origin.

Technique: Intra-procedural axial non-contrast CT image of the lower abdomen (Siemens, 306 mAs, 120 kV, DLP: 1892 mGy*cm. 3mm slice thickness).

Findings: Successful CT-guided 18-gauge percutaneous core needle biopsy of the largest soft-tissue lesion, measuring 5.2 cm in the left lower abdomen

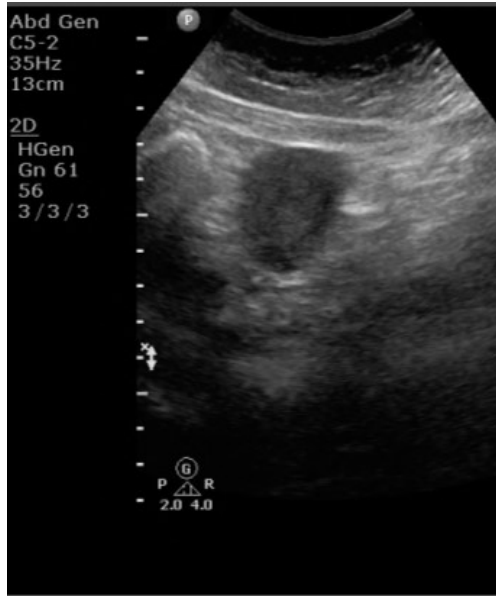

Figure 3: 43-year-old female with peritoneal soft tissue lesions found to be leiomyomatous in origin.

Technique: Abdominal ultrasound. 35 Mhz curvilinear transducer.

Findings: Grayscale longitudinally oriented image demonstrating a 4.1 cm circumscribed hypoechoic mass seen within the right upper abdomen with minimal posterior acoustic enhancement.

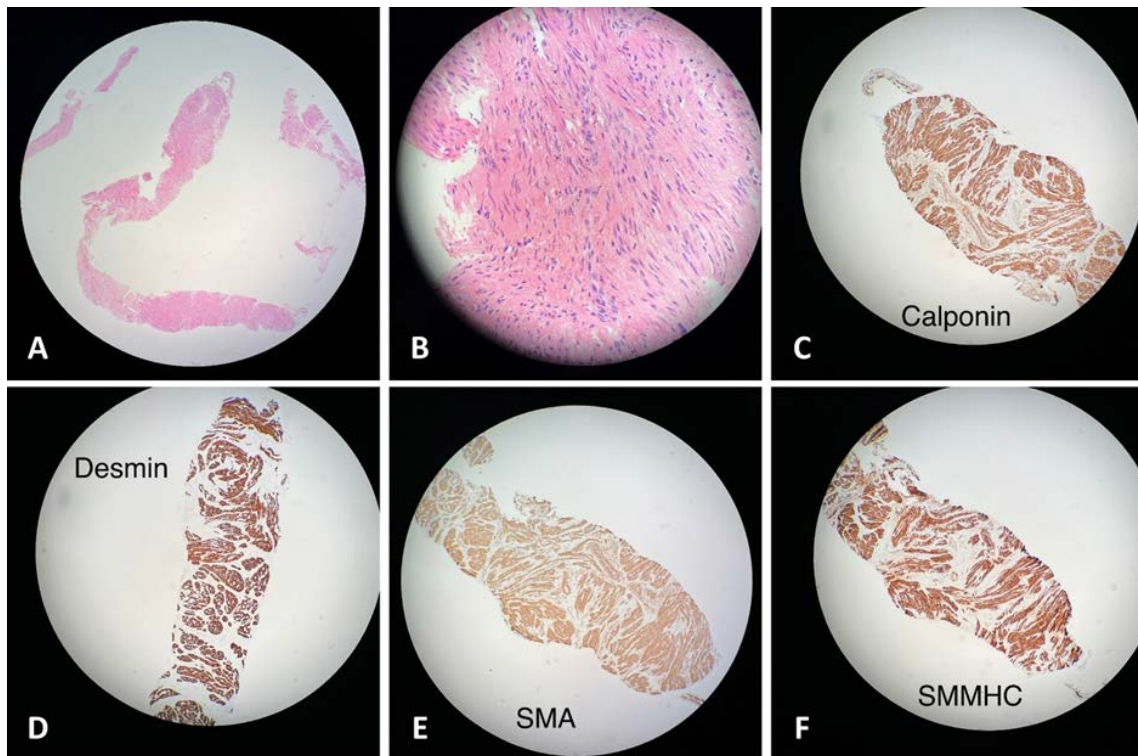


Figure 4: 43-year-old female with peritoneal soft tissue lesions found to be leiomyomatous in origin.

Findings: Histologic slides with H&E staining at low magnification (A) and high magnification (B) demonstrating abundant presence of smooth muscle bundles without cytologic atypia and focal myofibroblast proliferation in the long fascicles, suggestive of reactive changes. Additional histologic slides (C-F) demonstrated positive immunohistochemical staining for calponin, desmin, smooth muscle actin, and smooth muscle myosin heavy chain. The myofibroblasts stained negative for nuclear beta-catenin. Pan cytokeratin AE1/AE3 was negative. Based on this information, results were mostly likely indicative of a leiomyoma.

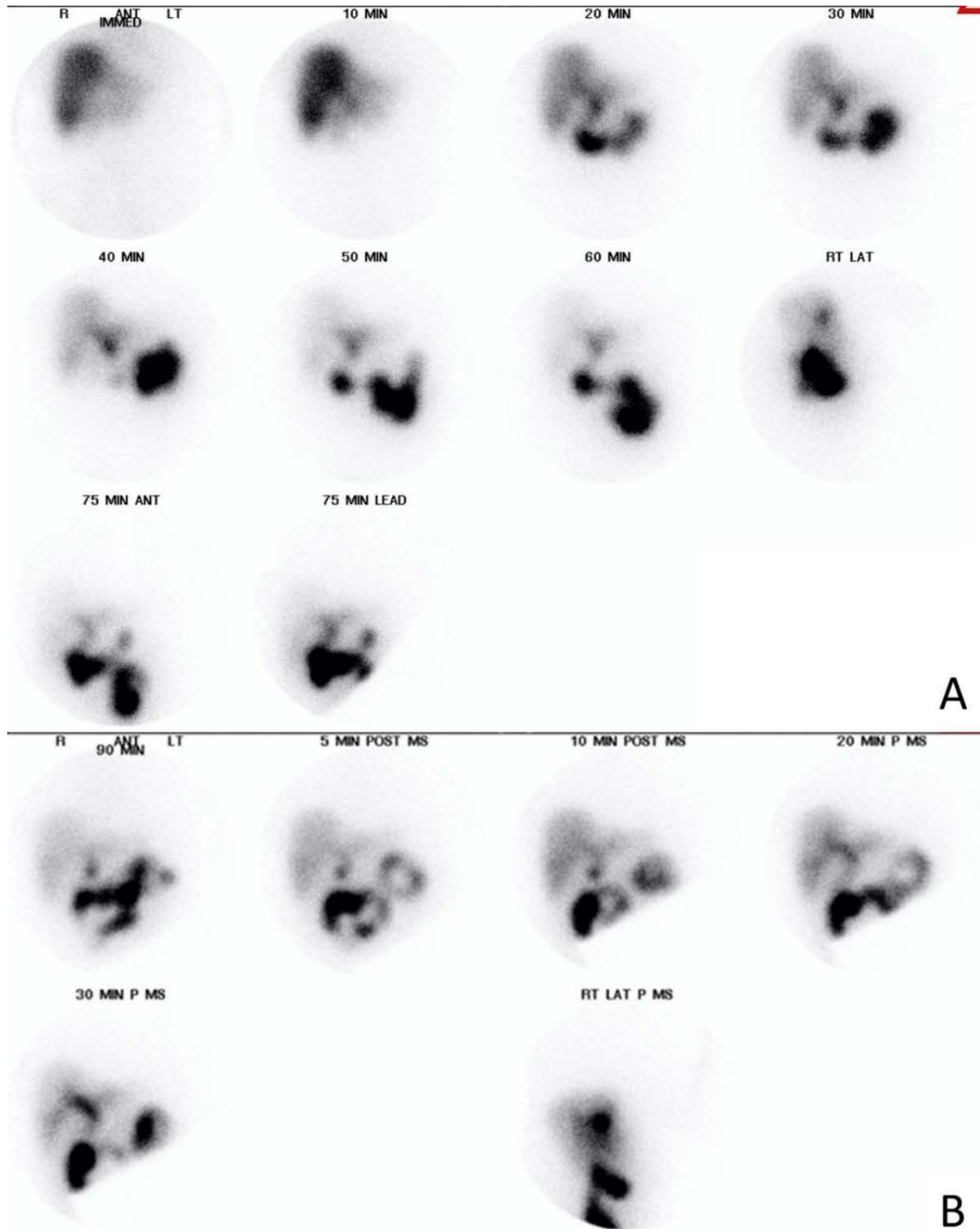


Figure 5: 43-year-old female with epigastric abdominal pain and peritoneal soft tissue lesions found to be leiomyomatous in origin.

Technique: Hepatobiliary iminodiacetic acid scintigraphy following the intravenous administration of 7 mCi of Technetium-99m mebrofenin. Dynamic planar and lateral images of the right upper abdomen were subsequently obtained 40 minutes after radiotracer administration at further 10 minute intervals. Additional frontal and lateral planar images obtained 30 minutes following intravenous administration of 0.04 mg/kg of morphine sulfate at 5 and 10 minute intervals.

Findings: (A) At 60 minutes after administration of radiotracer, the gallbladder is not visualized. However, there is normal distribution of radiotracer seen throughout the entire liver, common bile duct, and small bowel. (B) Following intravenous administration of morphine sulfate, the gallbladder remains non-visualized, concerning for cystic duct obstruction.

TABLES

Clinical characteristics of disseminated peritoneal leiomyomas	
Etiology	Precise etiology remains unknown, however association with hormonal levels has been implicated.
Incidence	Approximately 20-70% of women. Greater propensity amongst black women. Extrauterine involvement is less common. Distal involvement occurs in less than 1 out of every one million women.
Age Predilection	Most often discovered in women of reproductive age.
Imaging Findings	<ul style="list-style-type: none"> • CT: Small soft tissue nodularities or larger lesions along or within the peritoneal structures. Peritoneal lesions may appear as heterogenous or homogenous (contrast-enhanced studies) • US: Nodules or masses of variable echogenicity and posterior acoustics. Internal calcifications may be seen. Lesions may be detected as abnormal uterine contours, if intrauterine in location. • MRI: Circumscribed masses or nodules of low signal intensity on T1 and T2 weighted images, similar to surrounding smooth and skeletal musculature. Lesions homogeneously enhance on post-contrast images. • PET-CT: lesions exhibit no increased FDG uptake, differentiating them from malignant processes.
Complications	Abdominal pain, menorrhagia, or oligomenorrhea. Additional symptoms may be seen due to mass effect on regional structures.
Treatment	<ul style="list-style-type: none"> • Patient-specific. • Often conservative with close surveillance. • No definite consensus regarding hysterectomy and oophorectomy. Possible peritoneal debulking and/or PET-CT may be used to monitor progression/rule out malignant sarcomatous transformation. • Medical management: contraceptives, tranexamic acid, nonsteroidal anti-inflammatories, or gonadotropin releasing hormone agonists.
Prognosis	Lesions are likely to shrink in size after menopause. Patients rarely suffer from long-term sequelae.

Differential diagnosis for disseminated peritoneal leiomyomas

	CT	MRI	Histology
Peritoneal carcinomatosis	<ul style="list-style-type: none"> • Thickening, nodularity, and contrast enhancement of the peritoneal reflections • Possible loculated ascites 	<ul style="list-style-type: none"> • Areas of increased enhancement on post-contrast images. • Likely more sensitive than CT to detect this condition 	<ul style="list-style-type: none"> • Signs of malignant transformation present, including abnormal cellular replication and differentiation • Cells may be from various body systems in origin
Lymphoma	<ul style="list-style-type: none"> • Most used for diagnosis and staging • Enlarged soft tissue densities in the expected areas of various lymphatic chains. • Clinically correlated with “B-symptoms” • Increased radiotracer uptake within affected lymphatic chains on PET-CT 	<ul style="list-style-type: none"> • MRI is not typically used in the diagnosis or staging of lymphoma • It can be used for assessing cervical lymph nodes in certain cases in which CT is contraindicated 	<ul style="list-style-type: none"> • Malignant transformation of enhancing lymph nodes, specific for each lymphoma subvariant
Ovarian torsion	<ul style="list-style-type: none"> • Single or potentially bilaterally enlarged ovaries • Twisted appearance of vascular pedicle • Hemorrhagic components including intraovarian hematoma, hematosalpinx, or intraperitoneal blood product • Intraabdominal or intraovarian mass or cyst may act as a predisposing factor • Appearance of the bilateral ovaries in our case felt to be unremarkable 	<ul style="list-style-type: none"> • Not primary modality due to often acute presentation • T1 imaging may show hypointense ovarian tissue secondary to stromal edema with possible thin peripheral high signal due to hemorrhagic methemoglobin content • T2 signal potentially showing increased signal due to edema or dark signal due to infarcted and nonviable tissue 	<ul style="list-style-type: none"> • Enlarged and edematous ovary with areas of hemorrhage on gross pathology

KEYWORDS

Fibroids, Leiomyoma, Peritoneal, Metastasis, Dissemination, Pelvic Tumors, Uterine Masses, Benign

ABBREVIATIONS

CECT = Contrast-Enhanced Computed Tomography

CT = Computed Tomography

CTDI = Computed Tomography Dose Index

DLP = Dose Length Product

FDG = Fluorodeoxyglucose

H&E = Hematoxylin And Eosin

HIDA = Hepatobiliary Iminodiacetic Acid

HU = Hounsfield Unit

kV = Kilovoltage

mAs = Milliampere-Seconds

mCi = Millicurie

mGy*cm = Milligray-Centimeter

MRI = Magnetic Resonance Imaging

PET-CT = Positron Emission Tomography-Computed Tomography

SMA = Smooth Muscle Actin

SMMHC = Smooth Muscle Myosin Heavy Chain

US = Ultrasound

Online access

This publication is online available at:

www.radiologycases.com/index.php/radiologycases/article/view/4708

Peer discussion

Discuss this manuscript in our protected discussion forum at:

www.radiolopolis.com/forums/JRCR

Interactivity

This publication is available as an interactive article with scroll, window/level, magnify and more features.

Available online at www.RadiologyCases.com

Published by EduRad



www.EduRad.org