

Real time ultrasound diagnosis of ovarian and pelvic filariasis by filarial dance sign

Madhura Bayaskar^{1*}, Vikrant Bhende¹

1. Warora diagnostic Centre, Warora, Maharashtra, India

* Correspondence: Dr. Madhura Bayaskar, Consultant Radiologist, Warora diagnostic Centre, Warora, Maharashtra, India
(✉ madhura29.mb@gmail.com)

Radiology Case. 2023 Jul; 17(7):1-7 :: DOI: 10.3941/jrcr.v17i7.4675

ABSTRACT

Parasitic infestations of the ovary are quite rare with ovary being the least common site of infection in the female genital tract. Filariasis is a parasitic disease caused by filarial nematodes (*Wuchereria bancrofti*, *Brugia malayai*, *Brugia timori*). It causes lymphatic obstruction with resultant edema and increase in the size of the affected organ. We report a case of 24-year-old married female who presented to our radiology department for ultrasound evaluation with the main aim being to look for retained products of conception after the termination of early pregnancy. However on ultrasound examination ovarian filariasis was an incidental diagnosis with the classical twirling movement (filarial dance sign) seen in one of the follicles of the ovary. Ultrasound is the imaging modality of choice for detecting the adult filarial worm/microfilaria in the lymphatic system. Ovarian filariasis is a very rare diagnosis with only a handful of cases being reported in literature with most cases being diagnosed incidentally on histopathological examination of the post operative specimen.

CASE REPORT

CASE REPORT

A 24 year old married female with two children presented to our radiology centre for ultrasound evaluation with the main aim being to look for retained products of conception after the termination of early pregnancy. A transvaginal sonographic examination of the pelvis using a Samsung sonoace R7 scanner and a 4-9 MHz endovaginal probe was performed which revealed a normal sized uterus with normal endometrial thickness. The left ovary was normal in size and echotexture (volume 4 cc). The left adnexal region was normal. The right ovary was bulky with a volume of 23 cc and was heterogenous in echotexture (Figure 1A, B). One of the follicles in the right ovary showed few echogenic foci within showing twirling movement (filarial dance sign) on dynamic grey scale imaging

(Figure 2 A). Colour Doppler did not reveal any blood flow signal (Figure 2B). The colour doppler signals were non rhythmic, non-pulsatile and rapidly changing in size and position. Spectral Doppler trace showed characteristic pattern of irregular worm (Figure 2 C). The right adnexa revealed distended tortuous tubular structures adjacent to the right ovary representing distended lymphatics (Figure 3A,B).

A tentative diagnosis of filarial oophoritis with pelvic lymphangitis was made. Blood test was performed with differential leukocyte count revealing 22 % eosinophils. Giemsa staining showed microfilariae suggesting the diagnosis of ovarian filariasis. This confirmed the radiological diagnosis of filarial oophoritis with pelvic lymphangitis with classical filarial dance sign seen in the ovarian follicle.

The patient was then put on diethylcarbamazine 100 mg thrice daily for 21 days, which was followed for 3 weeks with a gap of 1 week in between. On follow up ultrasound the right ovary was normal in size and appearance with no evidence of filarial dance sign and no evidence of distended lymphatics in right adnexa.

DISCUSSION

Filariasis is a disease that generally affects the male genital tract and rarely involves the female genital tract(1). Ovarian filariasis is a very rare diagnosis with only a handful of cases being reported in literature with most cases being diagnosed incidentally on histopathological examination of the post operative specimen(2). When filariasis affects the female pelvic lymphatic system, it results in obstruction leading to inflammation and edema with enlargement of the affected organ(3).

Etiology & Demographics:

Lymphatic filariasis is a mosquito-borne parasitic disease caused by filarial nematodes –Wuchereria bancrofti, Brugia malayai, Brugia timori (4). The disease can be transmitted through the bites of any of the mosquito species, viz. Culex, Anopheles and Aedes(5).

It is a common tropical parasitic disease with over 120 million affected people with one third of them living in India. Other endemic regions include Africa, South Asia, the Pacific, and the America (1).

It affects males more than females with a M:F ratio-10:1(5). It affects young adults(6).

In endemic communities, 10-50 % of the men and upto 10% of the females can be affected (1). Chronic genital filariasis is more common in men involving the epididymis, spermatic cord and para testicular tissues. However, involvement of the female genital organs is quite rare with only a handful of cases of ovarian filariasis being described in literature(5).

Risk factors for filariasis are - Exposure to mosquitoes for long time with multiple mosquito bites, people residing in tropical or sub-tropical areas for a longer duration where the disease is common are at the greatest risk for infection, increased risk of filarial antigenemia is seen in people who used to hunt or fish. The risk of mosquito bites is increased by warm temperature and sweating(7,8).

Exact incidence and prevalence of ovarian filariasis is not known as ovarian filariasis is an extremely rare manifestation of lymphatic filariasis (2, 9).

Clinical & Imaging findings:

Filariasis causes elephantiasis, lymphedema and in men it causes hydrocele. It can cause swelling of the breast and genitals in females. The ovarian localization of lymphatic filariasis is rare. Other clinical manifestations can be pain in

abdomen, weight loss, anorexia, chyluria and infertility(2,3,5,6,10-12).

Ultrasound is the imaging modality of choice for detecting the adult filarial worm/microfilaria in the lymphatic system. The filarial dance sign i.e the twirling movement seen on dynamic grey scale imaging is characteristic of the filarial infestation. This sign was first described by Fernando Amaral from Brazil in 1994.

The ovary appears bulky and heterogenous with few echogenic foci within the follicle. These echogenic foci are suggestive of filarial worm nests either caused by adult filarial worm or microfilaria. Colour Doppler does not reveal any blood flow signal. The colour Doppler signals are non-rhythmic, non-pulsatile and rapidly changing in size and position on colour Doppler. Spectral Doppler trace shows characteristic pattern of irregular worm. The adnexa reveals dilated tortuous tubular structures adjacent to the ovary representing dilated lymphatics(3,11,12).

Treatment & Prognosis:

The diagnosis of filariasis can be made by drawing the blood from capillaries of finger tip at night and thick and thin smears made to identify microfilaria on Giemsa stain. The diagnosis of filarial infection can also be made by antigen testing using immunochromatographic filarial test. Demonstration of the adult worms on biopsy and fine needle aspiration are the means of definitive diagnosis of tissue filariasis(1-3,5,11,13).

Surgical and medical therapy are the main stay of treatment. In our case patient was put on diethylcarbamazine 100 mg thrice daily for 21 days, which was followed for 3 weeks with a gap of 1 week in between. DEC is very effective in killing adult worms and also a microfilaricidal(1-3).

The side effects of DEC are limited and depend on microfilarial count in the blood. The most common side effects are dizziness, nausea, fever, headache, or pain in muscles or joints (8).

Ultrasound is very useful in the follow up scan to document response of the worms to the drug. A complete absence of worm movements on follow up examination is taken as positive response(11).

The prognosis of this disease are usually favorable with treatment (14).

One of the limitations of the study is that, as it is based on a single case report the findings may not be generalizable to other cases of ovarian filariasis as most of the cases described in literature were diagnosed on histopathological examination who presented with other coexisting pelvic pathologies. Hence, further studies are needed to confirm the usefulness of ultrasound in the diagnosis of ovarian filariasis. This case report provides the short term follow up of the patient post treatment with follow up ultrasound demonstrating normal size and appearance of the ovary with no evidence of filarial dance sign and no evidence of distended lymphatics in the adnexa. Thus, the lack of long-term outcome of the patient, such as the

recurrence of the disease or the impact on the patient's fertility is another limitation of this case report. As ultrasound is subjective in nature, there can be a potential for observer variability in the interpretation of ultrasound findings.

Differential Diagnosis:

Usually, the filarial dance sign is characteristic of filarial infection, however other possible differential diagnosis can be as follows -

Hemorrhagic ovarian cyst – It is more common than ovarian filariasis with most common clinical presentation being pain in abdomen. On ultrasound it may present as a cyst with uniform internal echoes, reticular echoes or a heterogenous clot from hemorrhage and reticulations or septations.

On MRI - hemorrhagic cysts usually have a characteristic appearance of blood products with relatively high signal on T1 weighted imaging and intermediate to high signal intensity on T2 weighted images(15).

Pelvic inflammatory disease- It is the most common disease of the fallopian tubes which spreads by direct upward extension of the infection from the vagina and cervix to the peritoneal cavity. Its spectrum includes abnormalities comprising of salpingitis, pyosalpinx, and tubo-ovarian complex and abscess. It is usually caused by sexually transmitted microorganisms, particularly Chlamydia trachomatis, Neisseria gonorrhoeae, and Mycoplasma genitalium, as well as gram-negative bacteria and polymicrobial infections. Atypical pathogens such as TB and actinomycosis can also cause PID, but less frequently.

Risk factors include young age, multiple sexual partners, history of gynecologic surgery, and intrauterine device.

Clinical features include vaginal discharge, pelvic pain, fever, dyspareunia, and constitutional symptoms. Laboratory tests reveal leukocytosis. In some cases, PID may be asymptomatic and can be diagnosed at imaging only.

On ultrasound, salpingitis may or may not be apparent. It can manifest as a tortuous and diffusely thickened fallopian tube that measures greater than 5 mm in the axial plane and demonstrates a hyperemic wall at color Doppler ultrasound. Usually, no substantial tubal distention is seen at this stage. Free fluid can be seen in the cul-de-sac with echogenic fat due to inflammation.

On contrast enhanced CT and MR images, the tube is thickened and demonstrates mucosal enhancement(16).

Hydrosalpinx- Hydrosalpinx is a common entity that can be seen in isolation or as part of a more complex disease process and occurs due to obstruction in the secretions of the fallopian tube. The most common cause of distal tubal occlusion and hydrosalpinx is pelvic inflammatory disease, other causes being endometriosis, paratubal adhesions from prior surgical interventions, tubal neoplasm. Patients can present with recurrent lower abdominal pain or can be asymptomatic.

At cross-sectional imaging (ie, US, CT, and MRI), hydrosalpinx is characterized as a dilated fallopian tube

containing simple-appearing fluid and an imperceptible nonenhancing non-hyperemic wall with incomplete septae within giving cogwheel appearance on US images(16).

Dancing megasperm in the males - the ultrasound finding similar to filarial dance can be seen in men who have undergone scrotal surgery and who have no evidence of filarial infection. Dancing megasperm represents clusters of agglutinated spermatozoa within dilated epididymal tubules in patients with an obstruction of the spermatic duct. Dancing megasperm is defined as the ultrasound finding of moving, hyperechoic particles within cystic dilatations of an enlarged epididymis in a patient with spermatic duct obstruction.

However, this sign is still useful in filariasis endemic areas and is pathognomonic of filarial infection(5,17).

TEACHING POINT

Ovarian filariasis is a very rare diagnosis. Although filariasis affects males more commonly than females, the diagnosis should be considered in females and can have unusual presentations. Ultrasound is the imaging modality of choice for detecting the adult filarial worm/microfilaria in the lymphatic system and helps in early and correct diagnosis. It may sometimes mimic a pelvic mass.

REFERENCES

1. Wadhwa N, Raoot A. An unusual case of adult filarial oophoritis. International Journal of Gynecological Pathology. 2011 Nov;30(6):549-52. PMID: 21979591
2. Datta MR, Ghosh MD, Kumari V, Narayan R. Mosquito Bite and Adnexal Mass: The Unusual Diagnosis of Ovarian Filariasis. Cureus. 2021 Jul 31; PMID: 34354895
3. Panditi S, Shelke AG, Thummalakunta LNP. "Filarial dance sign" real-time ultrasound diagnosis of filarial oophoritis. Journal of Clinical Ultrasound. 2016 Oct 1;44(8):500-1. PMID: 27130361
4. World Health Organisation, Lymphatic Filariasis: the disease and its control. Fifth report of the WHO expert committee on filariasis, WHO Tech. Rep. Ser. 821 (1992) 1. PMID: 1441569
5. Goel P, Tandon R, Saha PK, Prabhakar S, Goel B, Kaur R, et al. A rare case of ovarian and pelvic filariasis. Trop Doct. 2013;43(3):108-9. PMID: 23820743
6. Vasantham V, Yadav SK, Sarin N, Singh S, Pruthi SK. Incidental detection of microfilaria in cyst fluid of Mucinous cystadenocarcinoma of ovary: A rare case report. Int J Surg Case Rep. 2020 Jan 1;70:56-9. PMID: 32416487
7. Chesnais CB, Missamou F, Pion SD, Bopda J, Louya F, Majewski AC, et al. A case study of risk factors for lymphatic filariasis in the Republic of Congo. Parasit Vectors. 2014 Jul 1;7(1). PMID: 24984769

8. Parasites - Lymphatic Filariasis. CDC. <https://www.cdc.gov/parasites/lymphaticfilariasis/epi.html>
Accessed on June 26, 2017.
9. Mondal S, Adhikari A, Chakraborty R, Mandal S. Ovarian filariasis presenting as tubo-ovarian mass: Report of a rare case. *CHRISMED Journal of Health and Research*. 2017;4(2):136.
10. Chakravarthy S, Chakravarty R. Diagnosis of tubo-ovarian filariasis with retroperitoneal extension: A radiological challenge. *J Family Med Prim Care*. 2019;8(6):2144. PMID: 31334196
11. Khanduri S, Nigam N, Khan M, Shukla A, Tyagi E, Imam TA, et al. Ovarian Follicle: Twirling Microfilaria's New Abode. *Journal of Obstetrics and Gynecology of India*. 2020 Apr 1;70(2):173-5. PMID: 32255958
12. Solanki R, Kavita K, Vaishnav U. Radiological Findings in Filariasis - A Case Series. *International Journal of Contemporary Medical Research [IJCMR]*. 2018 May;5(5). ISSN (Online): 2393-915X.
13. Sinha R, Sengupta S, Pal S, Adhikari A. Incidental diagnosis of filariasis in association with carcinoma of gall bladder: Report of a case evidenced on ultrasound-guided fine-needle aspiration cytology with review of the literature. *J Cytol*. 2014 Jul 1;31(3):174-5. PMID: 25538391
14. Brahim D, Alain Didier A, Gonat Serge Pacôme D, Nguissan Alphonse A, Abdoul K, Jean-Marie DMI. A Rare Case of Ovarian Filariasis in Abidjan. *Case Rep Pathol*. 2016;2016:1-2. PMID: 27313932
15. Wasnik AP. Multimodality imaging of ovarian cystic lesions: Review with an imaging based algorithmic approach. *World J Radiol*. 2013;5(3):113. PMID: 23671748
16. Revzin M v., Moshiri M, Katz DS, Pellerito JS, Gettle LM, Menias CO. Imaging evaluation of fallopian tubes and related disease: A primer for radiologists. *Radiographics*. 2020 Sep 1;40(5):1473-501. PMID: 32822282
17. Leenknecht B, Diss L, Sidhu PS. Dancing megasperm. Vol. 103, *Journal of the Belgian Society of Radiology*. Ubiquity Press; 2019. PMID: 30637371

FIGURES

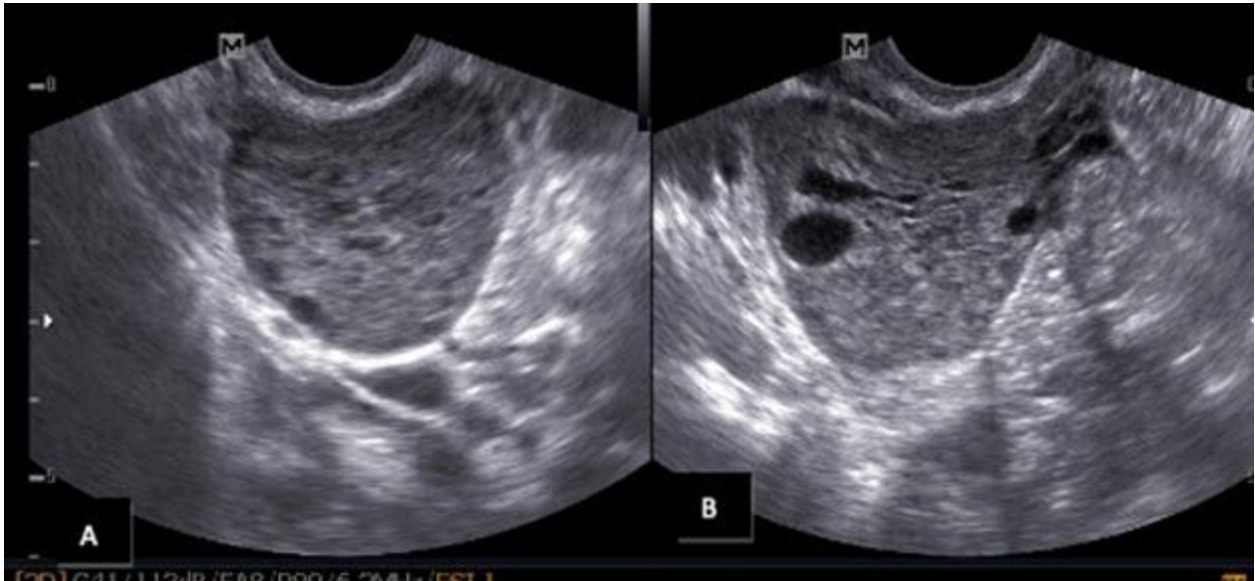


Figure 1: 24-year-old female with ovarian and pelvic filariasis

Findings: Transvaginal grey scale ultrasound images reveal bulky right ovary with heterogenous echotexture (A and B).

Technique: Real-time ultrasound images of the pelvis acquired on Samsung Sonoace R7 with 4-9 MHz transvaginal probe.

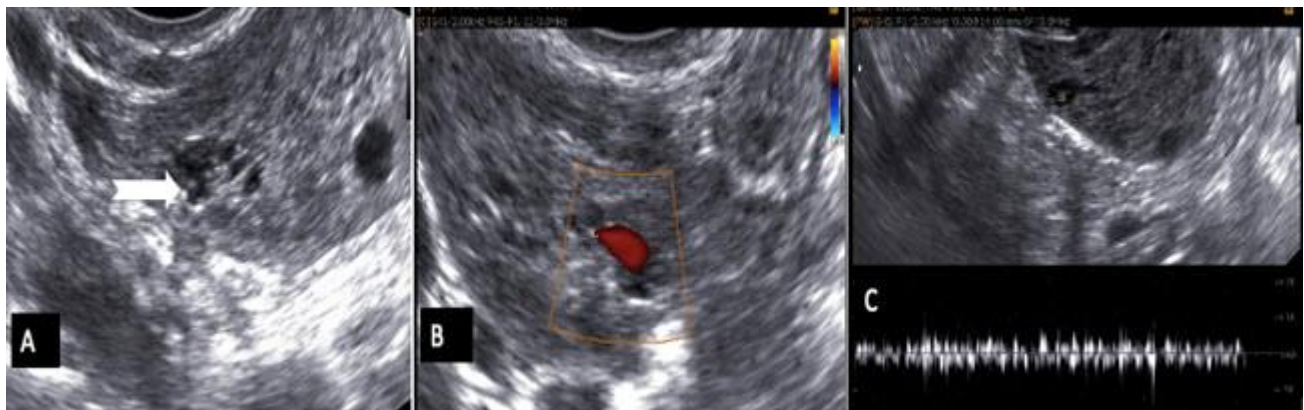

Figure 2: 24-year-old female with ovarian and pelvic filariasis

Findings - Transvaginal ultrasound images reveal few echogenic foci (notched arrow) in one of the ovarian follicle representing microfilariae (A). Colour doppler does not reveal any blood flow signal (B). Spectral Doppler trace shows characteristic pattern of irregular worm (C).

Technique- Real-time ultrasound images of the pelvis acquired on Samsung Sonoace R7 with 4-9 MHz transvaginal probe.

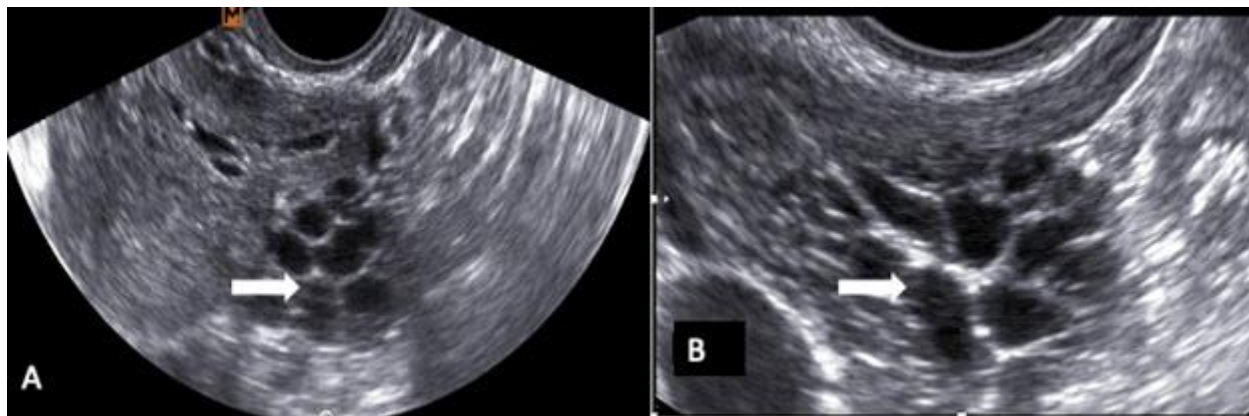


Figure 3: 24-year-old female with ovarian and pelvic filariasis

Findings: Transvaginal grey scale ultrasound images reveal distended tortuous tubular structure (block arrow) in the right adnexa abutting the right ovary representing distended lymphatics (A,B).

Technique: Real-time ultrasound images of the pelvis acquired on Samsung Sonoace R7 with 4-9 MHz transvaginal probe.

Etiology	Filariasis is caused by filarial nematodes –Wuchereria bancrofti, Brugia malayai, Brugia timori. The disease can be transmitted through the bites of any of the mosquito species, viz. Culex, Anopheles and Aedes.
Incidence	Filariasis is a common tropical parasitic disease with over 120 million affected people and one third of them living in India. Other endemic regions include Africa, South Asia, the Pacific, and America. Involvement of the female genital organs is quite rare with only a handful of cases of ovarian filariasis being described in literature.
Gender ratio	It affects males more than females. M:F ratio- 10:1 In endemic countries , 10-50 % of the men and up to 10% of the females can be affected
Age predilection	It affects young adults
Risk factors	<ul style="list-style-type: none"> • Exposure to mosquitoes for long time with multiple mosquito bites • People residing in tropical or sub-tropical areas for a longer duration where the disease is common are at the greatest risk for infection. • Increased risk of filarial antigenemia is seen in people who used to hunt or fish. • The risk of mosquito bites is increased by warm temperature and sweating.
Treatment	Medical therapy is the main stay of treatment. Diethylcarbamazine 100 mg thrice daily for 21 days, followed for 3 weeks with a gap of 1 week in between. The role of surgery seems to be very limited in the absence of secondary infection.
Prognosis	The prognosis of the disease is usually favorable with treatment
Findings on imaging	<p>Ultrasound is the imaging modality of choice for detecting the adult filarial worm/microfilaria in the lymphatic system.</p> <p>The filarial dance sign, i.e. the twirling movement seen on dynamic grey scale imaging is characteristic of the filarial infestation.</p> <p>The ovary appears bulky and heterogenous with few echogenic foci within the follicle. Colour Doppler does not reveal any blood flow signal. The Colour Doppler signals are non-rhythmic , non-pulsatile and rapidly changing in size and position on colour Doppler. Spectral Doppler trace shows characteristic pattern of irregular worm. The adnexa reveals dilated tortuous tubular structures adjacent to the ovary representing dilated lymphatics.</p>

Table 1: Summary table of ovarian and pelvic filariasis.

Ovarian filariasis	<p>Ultrasound is the imaging modality of choice for detecting the adult filarial worm/microfilaria in the lymphatic system.</p> <p>The filarial dance sign, i.e. the twirling movement seen on dynamic grey scale imaging is characteristic of the filarial infestation.</p> <p>The ovary appears bulky and heterogenous with few echogenic foci seen within the follicle . Colour Doppler does not reveal any blood flow signal.</p> <p>The colour Doppler signals are non-rhythmic, non-pulsatile and rapidly changing in size and position on colour Doppler . Spectral Doppler trace shows characteristic pattern of irregular worm.</p> <p>Dilated tortuous tubular structures in the adnexa adjacent to the ovary represent dilated lymphatics.</p>
Hemorrhagic ovarian cyst	<p>Ultrasound - it may present as cyst with uniform internal echoes, reticular echoes or a heterogenous clot from hemorrhage and reticulations or septations.</p> <p>MRI- hemorrhagic cysts usually have a characteristic appearance of blood products with relatively high signal on T1 weighted imaging and intermediate to high signal intensity on T2 weighted images.</p>
Pelvic inflammatory disease	<p>Ultrasound - salpingitis may or may not be apparent . It can manifest as tortuous and diffusely thickened fallopian tube that measures greater than 5 mm in the axial plane and demonstrates a hyperemic wall at color Doppler ultrasound. Usually, no substantial tubal distention is seen at this stage. Free fluid can be seen in the cul-de-sac with echogenic fat due to inflammation.</p> <p>Contrast enhanced CT and MR images- the tube is thickened and demonstrates mucosal enhancement</p>
Hydrosalpinx	<p>At cross-sectional imaging (i.e., US, CT, and MRI), hydrosalpinx is characterized as a dilated fallopian tube containing simple-appearing fluid and an imperceptible nonenhancing non-hyperemic wall with in-complete septae.</p> <p>Ultrasound - cogwheel appearance due to incomplete septae.</p>
Dancing megasperm in the males	<p>Dancing megasperm is defined as the ultrasound finding of moving, hyperechoic particles within cystic dilatations of an enlarged epididymis in a patient with spermatic duct obstruction.</p> <p>The ultrasound finding similar to filarial dance can be seen in men who have undergone scrotal surgery and who have no evidence of filarial infection.</p>

Table 2: Differential diagnosis table for ovarian/pelvic filariasis.

ABBREVIATIONS

CT = Computed tomography
 DEC = Diethylcarbamazine
 MRI = Magnetic resonance imaging
 US = Ultrasound

KEYWORDS

filariasis; filarial dance sign; ultrasound; ovary; pelvis

Online access

This publication is online available at:
www.radiologycases.com/index.php/radiologycases/article/view/4675

Peer discussion

Discuss this manuscript in our protected discussion forum at:
www.radiolopolis.com/forums/JRCR

Interactivity

This publication is available as an interactive article with scroll, window/level, magnify and more features.
 Available online at www.RadiologyCases.com

Published by EduRad



www.EduRad.org