

Infection of a venous port - beware of the Mycobacterium

Tseng Hui Heng^{1*}, Marcus Hin Yeung Loh¹, Ying Ying Chua², Bien Keem Tan³, Bien Soo Tan¹

1. Singapore General Hospital, Department of Vascular and Interventional Radiology, Singapore

2. Singapore General Hospital, Department of Infectious Diseases, Singapore

3. Singapore General Hospital, Department of Plastic, Reconstruction & Aesthetic Surgery, Singapore

* **Correspondence:** Tseng Hui Heng, Singapore General Hospital, Department of Vascular and Interventional Radiology, Singapore General Hospital, Outram Road, Singapore 169608, Singapore
(✉ tsenghui.heng@mohh.com.sg)

Radiology Case. 2022 Sep; 16(9):1-10 :: DOI: 10.3941/jrcr.v16i9.4587

ABSTRACT

An 84-year-old female with metastatic left breast cancer underwent a venous port insertion for chemotherapy. The port was inserted using standard techniques with image guidance under local anesthesia. She presented after 36 days with evidence of infection. A limited bedside ultrasound demonstrated free fluid surrounding the port. The port was subsequently removed the same day, at which time pus was expressed from the subcutaneous pocket. The culture from the pus grew Mycobacterium abscessus. She required removal of the port and wound debridement, wound dressings and a prolonged course of antibiotics. Mycobacterium abscessus is a group of rapidly growing, multidrug-resistant, non-tuberculous mycobacteria that are also relatively resistant to standard skin disinfectants. In recent years, this organism has been increasingly reported as the culprit in post-operative or post-procedural infections. Treatment is challenging due to multidrug resistance, and requires an extensive course of intravenous antimicrobial and macrolide-based combination therapy followed by oral antimicrobial therapy. Early treatment is essential as progression may result in disseminated infection. We discuss the peri-operative and post-operative care required in preventing and treating infection with this organism.

CASE REPORT

CASE REPORT

Our patient is an 84 year-old female with metastatic left breast cancer who was on follow up at our institution in Singapore. She required chemotherapy and attended our department for insertion of a venous port as a day procedure.

Preprocedure, she was well, with no fever. Her baseline investigations were unremarkable, with no evidence of

leukopaenia. Cleaning of the procedural site was performed using Chlorhexidine (Hexanol, Chlorhexidine Gluconate 2% w/v Isopropyl alcohol 70%v/v, ICM Pharma, Singapore) and standard aseptic technique was employed during the procedure. The procedure was performed under local anesthesia with 1% lignocaine and 2% lignocaine/1:80,000 adrenalin infiltrated around the subcutaneous pocket (a total 10 ml 1% lignocaine and 10 ml of 2% lignocaine/1:80,000 adrenalin administered). The right internal jugular vein was accessed with a single wall

puncture under ultrasound guidance. The entry site was slightly widened to 0.5 cm in length, to allow for blunt dissection of the subcutaneous tissue to accommodate the catheter. A subcutaneous pocket for the port was created superior to an incision on the right anterior chest wall (incision approximately 2 cm in length). After tunnelling through the port catheter, the venous port (PowerPort, Bard, Salt Lake City, USA) was placed within the subcutaneous pocket and its inferior apex anchored with a non-absorbable suture (Prolene 2-0, Ethicon, San Lorenzo, USA). The catheter was then measured externally with the aid of fluoroscopy and cut to appropriate length before insertion via a peel-away sheath within the right internal jugular vein. The anterior chest incision was then closed with absorbable sutures - interrupted 2-0 Vicryl (Ethicon, Diegem, Belgium) in the subcutaneous layer and 4-0 Vicryl (Ethicon, Diegem, Belgium) subcuticularly. Both the chest wall incision and the neck puncture site were further sealed with tissue glue (Dermabond, Ethicon, San Lorenzo, USA). The post-insertion image showed appropriate placement of the venous port with the catheter tip in the right atrium (figure 1). Minimal oozing of blood was seen at the neck insertion site, during and after application of tissue glue, which ceased at the end of the procedure. The patient was monitored for 6 hours and the wounds inspected before discharge home. Routine post-procedural care instructions were briefed to the patient and her caregiver. This included advice to not bathe in the subsequent 24 hours and to avoid wetting of the wounds.

Follow up reviews on post-operative day (POD) 2 and POD 8 were unremarkable. The wounds showed early healing without evidence of infection. On POD 11 and 12 mild erythema was seen over the subcutaneous pocket and there was mild dehiscence at the neck incision site. A single mattress stitch (3-0 Prolene, Ethicon, San Lorenzo, USA) was applied to facilitate healing at the neck incision. She was also prescribed a 10-day course of oral antibiotics (Clindamycin, PO, 450mg, Q6H). Instructions were also communicated for the port not to be used. Leading up to and during these visits, the patient was well with no fever or pain, and there was no pus seen at the incisions.

On POD 36, the patient returned with erythema and pruritus over the port site, but no fever. On clinical examination, there was erythema and swelling, as well as fluctuance and tenderness over the subcutaneous pocket of the port (figure 2). Limited bedside ultrasound showed a thin rim of hypoechoic fluid around the port. Further history taken from the patient revealed that while she did not bathe 24 hours after the procedure, she did wipe herself with a wet towel (using tap water) after returning home the evening after the procedure. She also did not take any other precautions to avoid wetting the incision sites. A decision was made to remove the port on the same day. No further imaging was performed as there was high clinical suspicion of infection and need for timely treatment. Upon reopening of the skin incision on the right chest wall, copious pus was expressed from the subcutaneous pocket (figure 3). The neck wound was also reopened and both sites were washed and irrigated with normal saline until clean (figure 4).

Cultures from the pus grew *Mycobacterium abscessus* (*M. abscessus*). Blood cultures showed no bacterial growth. The patient was referred to plastic surgery for wound care and infectious disease (ID) for treatment of the infection. She underwent incision and drainage (I&D) of the chest wound 5 days after the port removal, which showed turbid fluid on incision but a healthy and clean wound base. The subcutaneous pocket was curettaged and washed. A vacuum-assisted closure (VAC) dressing was applied to facilitate healing. ID recommended treatment with culture-directed intravenous antibiotics - Amikacin, Cefoxitin and Azithromycin, for a total of 6 weeks, which consisted of a regimen of Amikacin (IV, 700mg, once daily), Cefoxitin (IV, 1g, 4 hourly) and Azithromycin (PO, 500mg, once daily). A peripherally inserted central catheter was inserted for antibiotic administration. She also underwent a second I&D for a small pus-filled blister approximately 2 weeks after the first. Subsequent wound healing was good, without development of new collections or blisters. The patient remained on VAC dressing for 7 weeks before changing to an alginate (Kaltostat, Convatec, Reading, UK) dressing. After the 6 weeks of intravenous antibiotics, the patient was discharged on oral Clofazimine (PO, 100mg, once daily) and Azithromycin (PO, 500mg, once daily). The wound showed good healing before discharge. Oral antibiotics were continued for another 14 weeks. The patient was reviewed 3 months after stopping antibiotics, and the wound had healed without evidence of residual infection.

DISCUSSION

Venous port insertion for chemotherapy is a routine procedure in interventional radiology departments. A known complication is infection necessitating removal, which occurs with a reported incidence of 7 to 19% [1]. The common organisms include *Pseudomonas Aeruginosa* (15.4%), *Staphylococcus* species (13.4%) and *Candida* species (9.4%) [1]. *M. abscessus* infection of implanted devices, while rare, has been increasingly reported, especially in Asia. Treatment of *M. abscessus* infection is complex and requires multidisciplinary input. We discuss the epidemiology, likely cause of the infection in our case, as well as pre and post-operative care that could potentially decrease the rates of infection with this pathogen.

ETIOLOGY & DEMOGRAPHICS:

The incidence of venous port related infections varies between 0.9 and 10.1%, with most studies showing an incidence of around 5% [2], and is a leading cause of morbidity and catheter loss in patients with subcutaneous ports [3]. Venous port infections were shown to be almost evenly distributed between systemic (e.g. bacteremia) and local (tunnel and pocket) infections [3]. A higher incidence of venous port infections was seen in patients suffering from hematological as well as head and neck malignancies compared with other types of cancer [1]. Other factors that were shown to be independent risk factors for venous port related infections were leukopaenia, hypoalbuminemia and diabetes mellitus [4].

M. abscessus are among a group of multidrug-resistant rapidly growing non-tuberculous mycobacteria (NTM) [5]. They are ubiquitous in soil and water and have been known to colonize water reservoirs and plumbing systems, causing outbreaks. Urban living, especially in wet areas with dense populations, also increases the susceptibility to NTM infections [6]. Infection with this organism was previously rare, but has been increasingly reported in the healthcare setting, in particular in the post-operative/post-procedural setting due to its relative resistance to standard skin disinfectant [5]. Healthcare associated infections were also reported due to exposure to NTM contaminated tap water and topical skin solutions [7]. While any organ can be affected, the lung is the commonest site of infection (76%) [6]. Non-pulmonary sites of infection include skin and soft tissues (11%) as well as blood (11%) and lymph nodes (2%) [6]. Although NTM are not highly virulent or life threatening, they have a high predisposition to create biofilms and to colonize and infect intravascular catheters. Early detection and identification of specific species can help to estimate predictable antimicrobial susceptibility patterns [8].

In the United States, *M. abscessus* infections are secondary only to *Mycobacterium avium complex* (MAC) infections among NTM infections, comprising 2.6%–13.0% of all mycobacterial pulmonary infections across various study sites, with increasing prevalence [5]. *M. abscessus* is especially prevalent in East Asia. In Taiwan, *M. abscessus* comprises 17.2% of all clinical NTM isolates [5]. In Singapore, the most recent study published in 2019 [6] showed increasing incidence of NTM infections, with *M. abscessus* being the most common (49.9%), far surpassing the *Mycobacterium fortuitum* group (17%) and MAC (15.3%). The predominant site of infection was the lung (76%), with skin and soft tissue being the second most common (11%). These findings are supported by an earlier study [9]. It is postulated that high population density, a wet tropical urban environment, and an ageing population with a history of tuberculosis make the residents of Singapore particularly susceptible to NTM diseases [6]. The two major mechanisms for acquiring *M. abscessus* associated skin and soft tissue infections are by direct contact with contaminated material or water, through traumatic injury, surgical wound, or environmental exposure, and secondary involvement of skin and soft tissue during disseminated disease [5].

Infection of the subcutaneous pocket of a venous port with *M. abscessus* is infrequently reported. For example, in a case series of 8208 patients, only 27 instances of rapidly growing mycobacterial infection was detected. Out of these, *M. abscessus* was only responsible for one case of venous port subcutaneous pocket infection [10].

In our patient, the most likely point of infection was exposure of the incisions to tap water in the post-operative period. Infection perioperatively was deemed unlikely as the equipment was autoclaved or single-use and disposable. Perioperative equipment contamination usually occurs in heat sensitive equipment that is not amenable to autoclaving (e.g. some laparoscopic equipment) [11], which was not utilized.

Tissue glue has been shown to be less effective in sealing wounds once there is contact with blood, which can prevent adherence of tissue glue to skin [12]. In our patient there was

minimal blood oozing from the neck insertion site after tissue glue application. This may have disrupted the integrity of the tissue glue and weakened the seal. We postulate that wound contamination could have started from the neck incision after the patient wiped the incisions with a wet towel on POD 1, thereby introducing *M. abscessus* from tap water into the wound through the disrupted seal.

Suboptimal preprocedural skin disinfection is another consideration. Various studies have shown superiority of preprocedural skin cleansing of the patient's skin with alcohol-based Chlorhexidine over Povidone-Iodine (PI) for preventing vascular catheter infections and surgical site infections after clean-contaminated surgery [13]. This has resulted in a shift toward using alcohol-based Chlorhexidine over PI as the first-line skin antiseptic for a wide variety of procedures in the last decade [13]. However, most of these studies were based in the western world and showed a decrease in mostly bacterial (and in some cases *Candida* species) infections. Data on NTM were noticeably absent from most of the reports, probably due to either rarity or omission. More recent studies with an emphasis on NTM have shown that Chlorhexidine is less effective against NTM compared to PI and/or alcohol, with results showing clinically prevalent *M. abscessus* strains to be highly resistant to Chlorhexidine-alcohol and only partially susceptible to 10% Povidone-iodine-alcohol [14][15]. Cheng et al concluded that Chlorhexidine cleansing solution is insufficient to prevent infections with *M. abscessus* [14]. A combination of preprocedural skin disinfection with Chlorhexidine, PI and alcohol has been considered more effective [15].

CLINICAL & IMAGING FINDINGS:

Post-surgical/procedural infection with *M. abscessus* commonly presents in a delayed manner, usually weeks to months after the procedure (average 28-64 days, mean 36 days) [16]. This is postulated to be due to a combination of longer incubation time as well as relatively mild and indolent symptoms compared to pyogenic bacteria [17]. Routine swab cultures also regularly return sterile, further delaying diagnosis. Patients usually present with skin induration, erythema or a non-healing wound. Discharge through a sinus and microabscesses are also occasionally reported. Systemic manifestations with fever and chills are rare [17]. Biochemical markers that may be elevated include white blood cell count, erythrocyte sedimentation rate and C-reactive protein [18]. Diagnosis usually relies on a combination of clinical and biochemical findings, with subsequent cultures (from swab, pus or catheter) confirming the micro-organism. Infection may be difficult to diagnose in the absence of local signs and symptoms of infection, such as in severely immunocompromised patients [19].

Clinical features remain the mainstay of diagnosis of venous port infection. Imaging is utilized in some cases to delineate extent of disease or for troubleshooting purposes [20]. Imaging findings of port pocket infections, including that due to *M. abscessus*, are non-specific and follow general principles of soft tissue infections. Early infection appears similar to cellulitis, with skin thickening and subcutaneous oedema, associated with inflammatory changes [21]. Ultrasound imaging demonstrates subcutaneous edema with hypoechoic stranding between echogenic fat lobules, giving a cobblestone

appearance. Increased vascularity on color or power doppler ultrasound is more specific for the presence of an underlying inflammatory process [22]. Computed tomography (CT) demonstrates skin thickening, septation of subcutaneous fat, and thickening of the underlying superficial fascia [23]. Magnetic resonance (MR) imaging of cellulitis demonstrates diffuse linear or ill-defined soft-tissue thickening with hyperintensity on T2-weighted/STIR images, hypointensity on T1-weighted images and enhancement after contrast administration [22].

Abscesses can develop if early infection is not treated appropriately. Abscess cavities are usually round, though they can be irregularly shaped, and surrounded by inflammatory changes. On ultrasound they typically show anechoic or hypoechoic content due to a combination of purulent material and blood, with posterior acoustic enhancement and fluctuance [21]. Raised surrounding vascularity is often seen on Doppler imaging. Internal contents may appear isoechoic or hyperechoic due to loculations or dense fluid [21]. Well-demarcated single or multiple fluid collections with a peripheral pseudocapsule showing irregular peripheral rim enhancement on CT and MR imaging are characteristic of abscess formation [23]. On CT, internal content appears hypodense to isodense. On MR imaging, internal content shows iso to hypointensity on T1-weighted images and hyperintensity on T2-weighted images. Frequently there is hyperintense signal on diffusion-weighted imaging (DWI) and corresponding decreased signal intensity on apparent diffusion coefficient (ADC) maps in keeping with restricted diffusion, which is a highly specific finding for an abscess [18]. Gas locules can occasionally be seen within the collection, which can be related to recent operative procedures, communication with the skin surface, or rarely, a gas-producing organism [18]. Fluorodeoxyglucose (FDG) positron emission tomography (PET) was also shown to be of value in a small study, showing increased uptake at the infected port pocket (SUV 2.7-4.5) [24].

TREATMENT & PROGNOSIS:

Treatment of *M. abscessus* infection is challenging due to multidrug resistance. Source control is essential, and treatment often requires a long course of intravenous and macrolide-based antimicrobial combination therapy followed by oral antimicrobial therapy, based on the antimicrobial susceptibility of the isolate. Drug treatment is costly and is often associated with drug-related toxicities. Moreover, response rates are highly variable, with cure rates of only 30% to 50% [8]. If not treated early or appropriately, progression can be complicated by disseminated infection. A common feature of all NTM is their resistance to first line antituberculous agents. *M. abscessus* is deemed to be one of the most resistant species of NTM. It is generally shown to be susceptible to Amikacin and Clarithromycin (92.3%) [16], with variable susceptibility to Cefoxitin (7% to 75%) [8].

There are several considerations for decreasing the risk of infection with *M. abscessus* in the periprocedural and post-procedural settings. Our recommendations include a combination of Chlorhexidine, PI and alcohol for preprocedural skin preparation. Besides the choice of antiseptics, surgical site skin preparation technique according to the standards of practice is also important [25]. This includes antiseptic solution

to be allowed to dry naturally before insertion of catheter/port to achieve optimal antiseptic effect [26].

Preprocedural Chlorhexidine baths performed in some hospitals remains controversial but are likely to be ineffective given the resistance of *M. abscessus* to Chlorhexidine. Ensuring a dry wound with no bleeding during the application of tissue glue also ensures effective wound seal. Tissue glue should be removed if there is still bleeding and reapplied after ensuring cessation of bleeding and the wound is dry. In cases where bleeding is persistent, suturing is recommended and tissue glue should be avoided. Instructions to keep the wound dry 24 hours after the procedure should be routinely given.

Treating *M. abscessus* is complex and requires multidisciplinary management and input. Frequently, there is a need for hospital admission and subsequent treatment with a long course of antibiotics. Knowledge of this pathogen is essential and preventive measures are key in decreasing patient morbidity.

DIFFERENTIAL DIAGNOSES:

SEROMA

Seromas are fluid collections that accumulate at the site of surgery or procedure, usually developing between two and four weeks after surgery. They usually present as a soft tissue swelling with associated soft tissue induration, warmth and erythema close to the surgical site [27]. They vary in size and shape, with variation of internal fluid content [28]. Ultrasound reveals an anechoic or hypoechoic fluid collection. Presence of hyperechoic content can suggest the presence of hemorrhagic component [18]. On unenhanced CT scan, seromas appear as a hypodense focal fluid collection that is closely related to the surgical site. Rarely, a small hematocrit fluid-fluid level may be present [18]. Contrast enhanced CT images either demonstrate no enhancement or mild peripheral rim enhancement. MR imaging demonstrates internal content that shows low T1-weighted and high T2-weighted signal characteristics. A small hematocrit fluid-fluid level may also be observed; for which the signal characteristics will depend on the age of the blood product. The margin of a seroma may show uniform thin wall enhancement after administration of an intravenous gadolinium contrast agent [18]. In serial follow-up imaging, seromas generally decrease in size, but can be persistent or recurrent (up to 40%) [28].

HAEMATOMA

Hematomas are fluid collections consisting of blood product that are seen at the surgical or procedural site due to injury of the vascular structures (small veins, arteries and capillaries) due to intervention. They usually present within days of surgery with soft tissue swelling, soft tissue induration, warmth and erythema close to the surgical site, and may be associated with pain [27].

Imaging appearances of a hematoma are variable due to the differing appearance of blood products depending on age. Acute hemorrhage or hematoma appears as a hyperechoic collection with a poorly defined margin on ultrasound [29]. As the hematoma liquifies, it appears more hypoechoic and eventually becomes anechoic, with interspersed echogenic debris or septae that represent blood clots [29]. Compared with

pus from an abscess, which usually appears heterogeneously echogenic, clotted blood appears uniformly echogenic [21]. During a period that ranges from days to months, hemolysis may transform the hematoma into a serosanguinous cyst, which shows imaging appearances similar to a cyst. The wall of the hematoma gradually evolves from appearing vague to having a well-defined appearance, and the size also gradually decreases. Chronic non-resolving hematomas usually show a multilaminated concentric appearance [29].

The CT appearance of hematomas is variable depending on their age and location. Acute hemorrhage is hyperattenuating. With time, there is gradual decrease in attenuation to intermediate and eventually low attenuation. A thin hyperattenuating rim or thin peripheral enhancement may occasionally be observed, either due to hemosiderin deposition or reactive changes [18].

MR imaging signal intensity characteristics of blood product again varies depending on age. Signal changes on T1-weighted and T2-weighted sequences parallel the evolution of blood breakdown products. Subacute blood shows high T1-weighted signal due to presence of methemoglobin. Chronic blood breakdown and hemosiderin deposition shows a low-signal-intensity rim on all pulse sequences [22]. Generally, a hematoma appears as a heterogeneous hypointense to isointense fluid collection on T1-weighted sequences and a heterogeneous hypointense to hyperintense fluid collection on T2-weighted sequences. Gradient echo (GRE) sequences usually show foci of hypointensity. Delayed/chronic hematomas may show increased signal intensity on both T1-weighted and T2-weighted images. Thin peripheral enhancement may be observed after contrast administration [18].

TEACHING POINT

Interventional radiologists need to be aware of post-procedural infection with *M. abscessus*, which is increasingly being diagnosed particularly in Asian countries. Diagnosis of venous port pocket infection is largely based clinical and biochemical findings, with imaging utilized to delineate extent and troubleshoot. Treatment is challenging and prevention is key in decreasing patient morbidity from NTM and a high index of suspicion is required.

REFERENCES

1. Wang TY, Lee KD, Chen PT, Chen MC, Chen YY, Huang CE, Kuan FC, Chen CC, Lu CH. Incidence and risk factors for central venous access port-related infection in Chinese cancer patients. *J Formos Med Assoc.* 2015 Nov;114(11):1055-60. PMID: 26253646.
2. Akahane A, Sone M, Ehara S, Kato K, Suzuki M, Tanaka R, Suwabe A, Itabashi T, Masahiro K. Central venous port-related infection in patients with malignant tumors: an observational study. *Ups J Med Sci.* 2012 Aug;117(3):300-8. PMID: 22376242

3. Kuizon D, Gordon SM, Dolmatch BL. Single-lumen subcutaneous ports inserted by interventional radiologists in patients undergoing chemotherapy: incidence of infection and outcome of attempted catheter salvage. *Arch Intern Med.* 2001 Feb 12;161(3):406-10. PMID: 11280300.
4. Skummer P, Kobayashi K, DeRaddo JS, Blackburn T, Schoeneck M, Patel J, Jawed M. Risk Factors for Early Port Infections in Adult Oncologic Patients. *J Vasc Interv Radiol.* 2020 Sep;31(9):1427-1436. PMID: 32792279.
5. Lee MR, Sheng WH, Hung CC, Yu CJ, Lee LN, Hsueh PR. Mycobacterium abscessus Complex Infections in Humans. *Emerg Infect Dis.* 2015 Sep;21(9):1638-46. PMID: 26295364.
6. Zhang ZX, Cherng BPZ, Sng LH, Tan YE. Clinical and microbiological characteristics of non-tuberculous mycobacteria diseases in Singapore with a focus on pulmonary disease, 2012-2016. *BMC Infect Dis.* 2019 May 17;19(1):436. PMID: 31101082.
7. Tiwari TS, Ray B, Jost KC Jr, Rathod MK, Zhang Y, Brown-Elliott BA, Hendricks K, Wallace RJ Jr. Forty years of disinfectant failure: outbreak of postinjection Mycobacterium abscessus infection caused by contamination of benzalkonium chloride. *Clin Infect Dis.* 2003 Apr 15;36(8):954-62. PMID: 12684906.
8. El Helou G, Viola GM, Hachem R, Han XY, Raad II. Rapidly growing mycobacterial bloodstream infections. *Lancet Infect Dis.* 2013 Feb;13(2):166-74. PMID: 23347634.
9. Tang SS, Lye DC, Jureen R, Sng LH, Hsu LY. Rapidly growing mycobacteria in Singapore, 2006-2011. *Clin Microbiol Infect.* 2015 Mar;21(3):236-41. PMID: 25658536.
10. Apiwattankul N, Flynn PM, Hayden RT, Adderson EE. Infections Caused by Rapidly Growing Mycobacteria spp in Children and Adolescents With Cancer. *J Pediatric Infect Dis Soc.* 2015 Jun;4(2):104-13. PMID: 26407409
11. Ghosh R, Das S, Kela H, De A, Haldar J, Maiti PK. Biofilm colonization of Mycobacterium abscessus: New threat in hospital-acquired surgical site infection. *Indian J Tuberc.* 2017 Jul;64(3):178-182. PMID: 28709485.
12. Yamamoto LG. Preventing adverse events and outcomes encountered using dermabond. *Am J Emerg Med.* 2000 Jul;18(4):511-5. PMID: 10919558.
13. Allegranzi B, Bischoff P, de Jonge S, Kubilay NZ, Zayed B, Gomes SM, Abbas M, Atema JJ, Gans S, van Rijen M, Boermeester MA, Egger M, Kluytmans J, Pittet D, Solomkin JS; WHO Guidelines Development Group. New WHO recommendations on preoperative measures for surgical site infection prevention: an evidence-based global perspective. *Lancet Infect Dis.* 2016 Dec;16(12):e276-e287. PMID: 27816413.
14. Cheng A, Sun HY, Tsai YT, Wu UI, Chuang YC, Wang JT, Sheng WH, Hsueh PR, Chen YC, Chang SC. In Vitro Evaluation of Povidone-Iodine and Chlorhexidine against Outbreak and Nonoutbreak Strains of Mycobacterium

abscessus Using Standard Quantitative Suspension and Carrier Testing. *Antimicrob Agents Chemother.* 2017 Dec 21;62(1):e01364-17. PMID: 29061748

15. Wu CH, Thong HY, Huang CC, Chen PH. Report of two cases of cutaneous Mycobacterium abscessus infection complicating professional decorative tattoo. *Dermatol Sinica* 2017;35:40-3.

16. Ghosh R, Das S, De A, Kela H, Saha ML, Maiti PK. Port-site infections by nontuberculous mycobacterium: A retrospective clinico-microbiological study. *Int J Mycobacteriol.* 2017 Jan-Mar;6(1):34-37. PMID: 28317802.

17. Kannaiyan K, Rangunathan L, Sakthivel S, Sasidar AR, Muralidaran, Venkatachalam GK. Surgical site infections due to rapidly growing mycobacteria in puducherry, India. *J Clin Diagn Res.* 2015 Mar;9(3):DC05-8. PMID: 25954616.

18. Jain NK, Dao K, Ortiz AO. Radiologic evaluation and management of postoperative spine paraspinal fluid collections. *Neuroimaging Clin N Am.* 2014 May;24(2):375-89. PMID: 24792615.

19. Hughes WT, Armstrong D, Bodey GP, Bow EJ, Brown AE, Calandra T, Feld R, Pizzo PA, Rolston KV, Shenep JL, Young LS. 2002 guidelines for the use of antimicrobial agents in neutropenic patients with cancer. *Clin Infect Dis.* 2002 Mar 15;34(6):730-51. PMID: 11850858.

20. Theodorou DJ, Theodorou SJ, Kakitsubata Y, Sartoris DJ, Resnick D. Imaging characteristics and epidemiologic features of atypical mycobacterial infections involving the musculoskeletal system. *AJR Am J Roentgenol.* 2001 Feb;176(2):341-9. PMID: 11159070.

21. Squire BT, Fox JC, Anderson C. ABSCESS: applied bedside sonography for convenient evaluation of superficial soft tissue infections. *Acad Emerg Med.* 2005 Jul;12(7):601-6. PMID: 15995090.

22. Hayeri MR, Ziai P, Shehata ML, Teytelboym OM, Huang BK. Soft-Tissue Infections and Their Imaging Mimics: From Cellulitis to Necrotizing Fasciitis. *Radiographics.* 2016 Oct;36(6):1888-1910. PMID: 27726741

23. Fayad LM, Carrino JA, Fishman EK. Musculoskeletal infection: role of CT in the emergency department. *Radiographics.* 2007 Nov-Dec;27(6):1723-36. PMID: 18025514

24. Miceli MH, Jones Jackson LB, Walker RC, Talamo G, Barlogie B, Anaissie EJ. Diagnosis of infection of implantable central venous catheters by [18F]fluorodeoxyglucose positron emission tomography. *Nucl Med Commun.* 2004 Aug;25(8):813-8. PMID: 15266176.

25. O'Grady NP, Alexander M, Burns LA, Dellinger EP, Garland J, Heard SO, Lipsett PA, Masur H, Mermel LA, Pearson ML, Raad II, Randolph AG, Rupp ME, Saint S; Healthcare Infection Control Practices Advisory Committee (HICPAC). Guidelines for the prevention of intravascular

catheter-related infections. *Clin Infect Dis.* 2011 May;52(9):e162-93. PMID: 21460264

26. Maki DG, Ringer M, Alvarado CJ. Prospective randomised trial of povidone-iodine, alcohol, and chlorhexidine for prevention of infection associated with central venous and arterial catheters. *Lancet.* 1991 Aug 10;338(8763):339-43. PMID: 1677698.

27. Smith D, Berdis G, Singh V, Caughran A, Bullock M. Postoperative Fluid Collections in Total Joint Arthroplasty: A Narrative Review. *Orthop Res Rev.* 2022 Feb 19;14:43-57. PMID: 35221733.

28. Park SY, Kim EY, Park HK, et al. Computed Tomographic Findings of Postoperative Seroma in Breast Cancer Patients. *J Breast Dis.* 2014;2(2):64-68.

29. Cho KH, Park BH, Yeon KM. Ultrasound of the adult hip. *Semin Ultrasound CT MR.* 2000 Jun;21(3):214-30. PMID: 10994690.

FIGURES

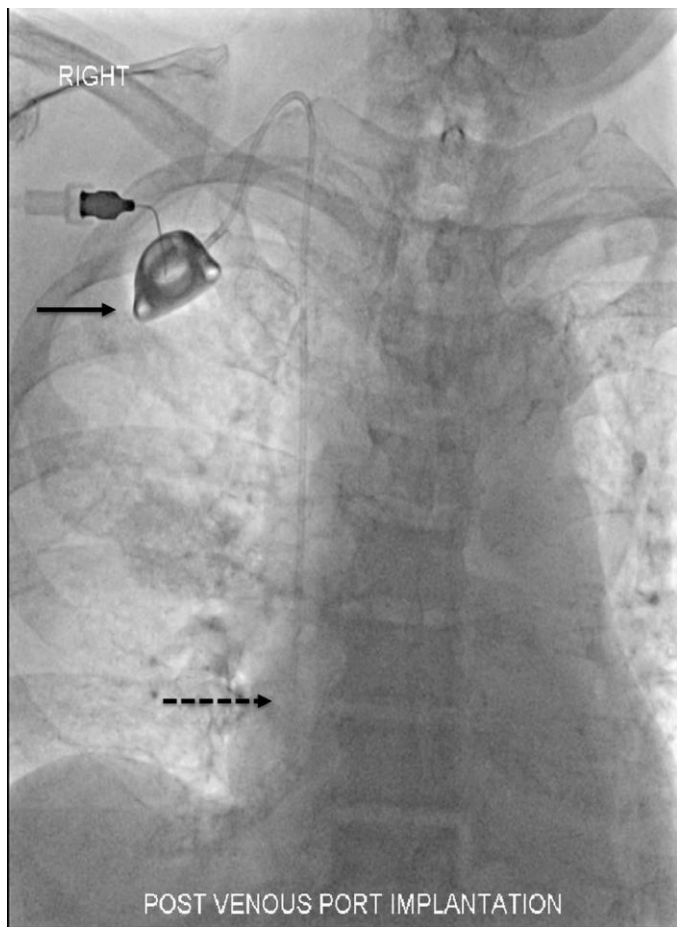


Figure 1: 84 y/o female with Mycobacterium abscessus infection of a venous port. Uncomplicated venous port insertion

Findings: Frontal chest radiograph performed after implantation of the right internal jugular vein venous port. Venous port is projected over the right chest wall (solid arrow). Appropriate position of the tip, projected over the right atrium (dashed arrow).

Technique: Supine frontal Chest Radiograph (Siemens AXIOM-Artis Interventional system): kVp: 73 and mAs: 91

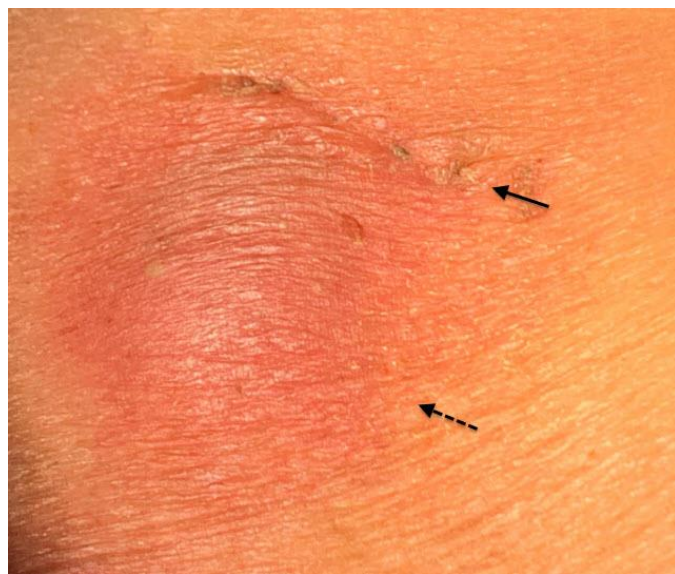

Figure 2: 84 y/o female with Mycobacterium abscessus infection of a venous port. Suspected infection of Venous port.

Findings: Photograph taken on POD 36 of the right anterior chest wall subcutaneous pocket (dashed arrow) and incision (solid arrow), showing erythema and swelling.

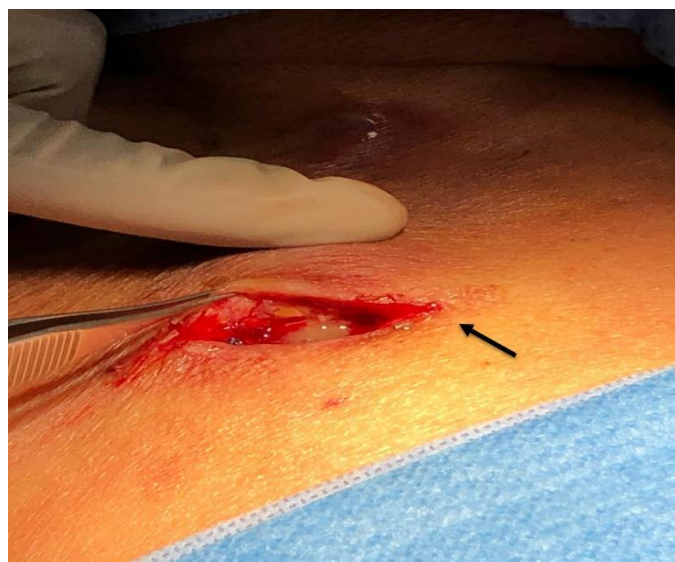

Figure 3: 84 y/o female with Mycobacterium abscessus infection of a venous port. Confirmed infection of Venous port, with pus seen.

Findings: Photograph taken upon reopening of the skin incision on the right chest wall (solid arrow), showing copious pus expressed from the subcutaneous pocket

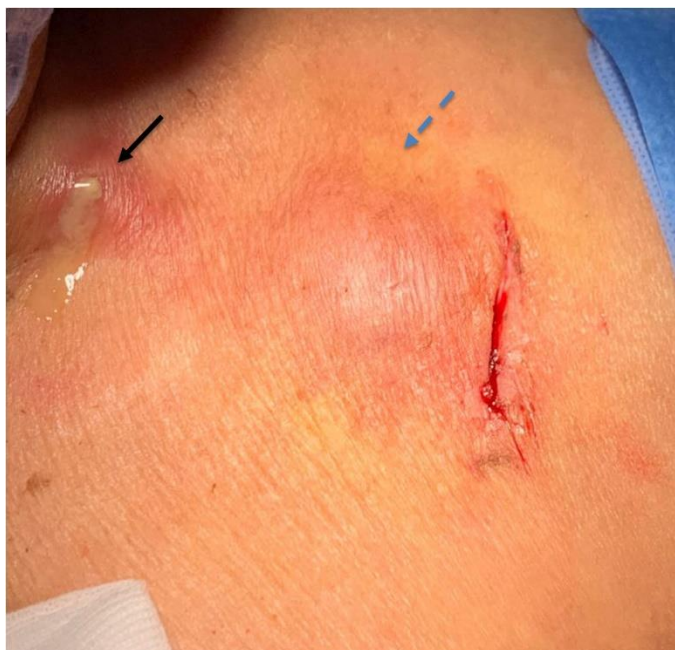

Figure 4 (left): 84 y/o female with Mycobacterium abscessus infection of a venous port. After removal of venous port as well as washing and irrigation.

Findings: Photograph after removal of the venous port. The neck wound (solid arrow) and subcutaneous pocket (dashed arrow) were both reopened and both sites were washed and irrigated with normal saline.

Etiology	Suboptimal preprocedural skin preparation Suboptimal post-procedure care including wound exposure to tap water, suboptimal tissue glue application.
Incidence	<i>M. abscessus</i> infection is uncommon globally (2.6-13%). Increasingly recognized in Asia, especially East and Southeast (17%), where it is the leading organism in NTM infections (up to 49.9% of NTM infections in Singapore) Venous Port infection incidence is 5% Incidence of venous Port infection with <i>M. abscessus</i> has not been reported.
Gender ratio	No gender predilection
Age predilection	No age predilection
Risk factors	Location and geography (high population density, wet tropical urban environment, increasing age), post-surgical/procedural state, immunosuppression Hematological malignancies, head and neck malignancy, leukopaenia, hypoalbuminemia and diabetes mellitus
Treatment	Source control, long course of intravenous and macrolide-based antimicrobial combination therapy followed by oral antimicrobial therapy In our case, the antibiotic regimen consisted of: - Initial treatment with Amikacin (IV, 700mg, once daily), Cefoxitin (IV, 1g, 4 hourly) and Azithromycin (PO, 500mg, once daily) for 6 weeks - Followed by 14 weeks of Clofazimine (PO, 100mg, once daily) and Azithromycin (PO, 500mg, once daily)
Prognosis	Cure rates of 30% to 50%. If not treated early or appropriately, progression can be complicated by disseminated infection and eventually death
Findings on imaging	Early - mimicking cellulitis: US: hypoechoic stranding between echogenic fat lobules. Increased vascularity CT: skin thickening, septation of subcutaneous fat, thickening of the underlying superficial fascia MRI: diffuse linear or ill-defined soft-tissue thickening with hyperintensity on T2-weighted/STIR images, hypointensity on T1-weighted images and enhancement Late – with development of abscess: US: anechoic or hypoechoic content with posterior acoustic enhancement and fluctuance. Internal content may appear isoechoic or hyperechoic. Raised surrounding vascularity is often seen on Doppler imaging. CT: Well-demarcated single or multiple fluid collections with a peripheral pseudocapsule showing irregular peripheral rim enhancement. Hypodense to isodense internal content MRI: Well-demarcated single or multiple fluid collections with a peripheral pseudocapsule showing irregular peripheral rim enhancement. Restricted diffusion can be seen. PET-CT: increased uptake at the infected port pocket (SUV 2.7-4.5)

Table 1: Summary table of venous port infection with Mycobacterium abscessus.

	Venous port pocket infection	Seroma	Hematoma
Clinical and Biochemical Findings	Soft tissue swelling, warmth, erythema, warm, tenderness, presence of pus, scar dehiscence, fever, raised inflammatory markers	Soft tissue swelling, soft tissue induration, warmth and erythema. No fever. Inflammatory markers are not raised	Soft tissue swelling with associated soft tissue induration, warmth and erythema. May be associated with pain. No fever. Inflammatory markers are not raised
US Findings	Anechoic or hypoechoic content with posterior acoustic enhancement and fluctuance. Internal content may appear isoechoic or hyperechoic. Raised surrounding vascularity is often seen on Doppler imaging	Anechoic or hypoechoic fluid collection. Hyperechoic content can suggest the presence of hemorrhagic component	Acute hemorrhage or hematoma -hyperechoic collection with a poorly defined margin. With time it becomes more hypoechoic and eventually becomes anechoic, with interspersed echogenic debris or septae. Clotted blood appears uniformly echogenic. The wall of the hematoma gradually evolves from appearing vague to a well-defined appearance
CT Findings	Well-demarcated single or multiple fluid collections with a peripheral pseudocapsule showing irregular peripheral rim enhancement. Hypodense to isodense internal content	Unenhanced CT: hypodense focal fluid collection that is closely related to the surgical site. Rarely, a small hematocrit fluid-fluid level may be present. Contrast enhanced CT: either no enhancement or mild peripheral rim enhancement	Variable depending on age. Acute hemorrhage is hyperattenuating. With time, there is decrease in attenuation. A thin hyperattenuating rim or thin peripheral enhancement is occasionally seen
MRI Findings	Well-demarcated single or multiple fluid collections with a peripheral pseudocapsule showing irregular peripheral rim enhancement. Restricted diffusion can be seen	Internal content shows low T1-weighted and high T2-weighted signal. A small hematocrit fluid-fluid level may also be observed - signal characteristics depend on the age of the blood product. The margin of the seroma may show uniform thin enhancement	Varies depending on age and parallels the evolution of blood products. Subacute - high T1-weighted signal. Chronic-low-signal-intensity rim on all pulse sequences. Generally appears as a heterogeneous hypointense to isointense fluid collection on T1-weighted sequences and a heterogeneous hypointense to hyperintense fluid collection on T2-weighted sequences. GRE sequences show foci of hypointensity. Delayed/chronic hematomas may show increased signal intensity on both T1-weighted and T2-weighted images. Thin peripheral enhancement can be seen

Table 2: Differential diagnosis table for Mycobacterium abscessus post-surgical infection.

ABBREVIATIONS

ADC = apparent diffusion coefficient
CT = computed tomography
DWI = diffusion-weighted imaging
FDG = Fluorodeoxyglucose
GRE = Gradient echo
I&D = incision and drainage
ID = infectious diseases
IV = Intravenous
MAC = Mycobacterium avium complex
MR = magnetic resonance
NTM = non-tuberculous mycobacteria
PET = positron emission tomography
PI = Povidone-Iodine
PO = per os (by mouth/orally)
POD = Post operative day
VAC = vacuum-assisted closure

KEYWORDS

Venous port; port-a-cath; port pocket; subcutaneous; skin and soft tissue; Mycobacterium; non-tuberculous; abscessus; infection; resistance

ACKNOWLEDGEMENTS

Sivanathan Chandramohan¹, Yu Wei Wang¹, Tira Jing Ying Tan⁴, Kiley Wei-Jen Loh⁴

Online access

This publication is online available at:
www.radiologycases.com/index.php/radiologycases/article/view/4587

Peer discussion

Discuss this manuscript in our protected discussion forum at:
www.radiolopolis.com/forums/JRCR

Interactivity

This publication is available as an interactive article with scroll, window/level, magnify and more features.
Available online at www.RadiologyCases.com

Published by EduRad



www.EduRad.org