

# Male Breast Imaging Uncovers Lymphoma

Luma Abunimer<sup>1\*</sup>, Sophia R O'Brien<sup>2</sup>, Nabil Calisi<sup>3</sup>

1. Virginia Tech Carilion School of Medicine, Roanoke, VA, USA

2. Department of Radiology, The Hospital of the University of Pennsylvania, Philadelphia, PA, USA

3. Department of Radiology and Imaging Science, Emory University School of Medicine, Atlanta, Georgia, USA

\* **Correspondence:** Luma Abunimer, MS, Virginia Tech Carilion School of Medicine, 2 Riverside Circle, Roanoke, VA 24016, USA  
(✉ [Luma@vt.edu](mailto:Luma@vt.edu))

Radiology Case. 2023 Feb; 17(2):1-8 :: DOI: 10.3941/jrcr.v17i2.4508

## ABSTRACT

**Background:** A 36-year-old man presented with a palpable mass in the right axillary tail for four months. He was referred to breast imaging for diagnostic work-up. He does not have a family history of breast cancer. **Aim:** Breast imaging work-up for diagnosis of lymphoma is unusual and even more so in a male patient. **Case presentation:** After Breast Mammography and targeted Ultrasound of the axillary tail and axilla, Magnetic Resonance Imaging (MRI) was performed and suggested lymphoproliferative disorder. Excisional biopsy was performed after the breast MRI with removal of right axillary tissue measuring 15.0 x 5.5 x 2.0 cm and containing multiple lymph nodes. Excisional biopsy revealed Classic Hodgkin lymphoma of nodular sclerosis type. Staging [18F]-FDG PET/CT revealed early stage of disease. **Conclusion:** The presentation and diagnostic elements of Hodgkin Lymphoma are described in this case report emphasizing the significance of breast imaging in multiple populations.

## CASE REPORT

### CASE REPORT

A 36-year-old man presented with a palpable mass in the right axillary tail for four months. Diagnostic mammography revealed an almost entirely fatty breast. There is a partially encapsulated fatty and soft tissue mass in the posterolateral right breast (Figure 1, white arrow). The posterior aspect of the mass was not clearly visible as it appears to extend posteriorly into the axilla. At the site of palpable abnormality in the right axillary tail, focused ultrasound revealed a mobile, palpable, largely fatty mass measuring 5.8 x 2.4 x 4.9 cm (Figure 2a). Ultrasound of the right axilla also revealed an adjacent abnormal lymph node with thickened cortex measuring 8 mm and partial effacement of the fatty hilum. Patient preferred surgical consultation before doing an US core biopsy. Breast

MR was recommended for further evaluation to exclude occult malignancy.

Breast MR revealed an 8.0 x 1.5 cm oval, fatty mass in the right axillary tail with a medially coursing vessel. The mass had an enhancing lateral rim (Figure 3b) which demonstrated restricted diffusion. Breast MR also revealed bilateral lymphadenopathy. After breast MR, the favored diagnosis was a lymphoproliferative disorder and tissue sampling was recommended. After surgical consultation, patient indicated preference for excisional biopsy. An excisional biopsy was subsequently performed with removal of a 15 x 5.5 x 2.0 cm block of tissue from the right axilla.

Excisional biopsy confirmed Classic Hodgkin lymphoma, nodular sclerosis subtype. Staging FDG PET/CT revealed early-stage disease, with post-procedural changes in the right axilla (Figure 4F, blue arrow), but without evidence of FDG-avid nodal or extra-nodal malignancy. Mildly FDG-avid lymph nodes in the left axilla (Figure 4F, circle) were favored to be reactive due to recent COVID-19 vaccination. The patient was referred to Hematology/Oncology for further management and was started on chemotherapy regimen. His follow-up imaging revealed no evidence of disease twelve months after treatment.

## DISCUSSION

### Etiology & Demographics:

Hodgkin Lymphoma is a class of B-cell lymphomas which most often occur in adolescents and young adults but can also present in patients older than 55 [1]. Hodgkin lymphoma is an uncommon type of lymphoma, with an incidence of about 8500 cases per year in the United States and representing only approximately 10% of all lymphomas diagnosed in the US [2]. Classic Hodgkin Lymphoma, which our patient has, is the most common subtype of the Hodgkin lymphomas, accounting for up to 85% of all Hodgkin cases [3]. Classic Hodgkin Lymphomas are also split into multiple subtypes; our patient has Nodular Sclerosing Classical Hodgkin Lymphoma (NSCHL), the most common subtype in the Western world, which has a predilection for young adults [3].

The etiology of Hodgkin Lymphoma is not known, though associations with viral exposures (notably the Epstein Barr Virus) and immunosuppression have been observed [2]. Additionally, the disease has a higher rate of occurrence in siblings of a Hodgkin patient than in the general population, leading experts to suspect a genetic component [1,2].

### Clinical & Imaging Findings:

Most patients present with supradiaphragmatic lymphadenopathy [3]. About 80% of patients with NSCHL present with an anterior mediastinal mass (which our patient did not have) [3]. Approximately 33% of HL patients present with classic "B-symptoms" such as night sweats, fever, and weight loss; these symptoms are common in patients with advanced disease and are included in the Hodgkin Lymphoma staging system [1,2]. Our patient had early-stage disease, with abnormal lymph nodes confined to only the right axilla and all of which were removed by excisional biopsy. Diagnosis depends upon tissue sampling [2,3].

Most Classic Hodgkin Lymphoma patients demonstrate supradiaphragmatic lymphadenopathy, typically of the cervical, supraclavicular, anterior mediastinal, and axillary nodal stations on imaging [3]. Infra-diaphragmatic lymphadenopathy, such as external iliac and inguinal nodal involvement, is less common [1,2].

Extra-nodal sites of disease, most commonly the spleen, liver, lungs, and bone, can become involved via hematogenous spread of disease or, rarely, by direct invasion [3]. About 80% of patients with NSCHL present with an anterior mediastinal

mass (which our patient did not have) [3]. Sites of involvement are FDG-avid, with [F18]-FDG PET/CT imaging representing the current standard of care for disease staging, restaging, and surveillance, using the Deauville Scoring system. The Deauville Scoring system is a scale used to guide therapy for Hodgkin Lymphoma and established the role of PET/CT in initial staging and measuring treatment response [2].

### Treatment & Prognosis:

Early-stage Classic Hodgkin's Lymphoma (Stage I and II) is defined as nodal involvement on one side of the diaphragm [2]. Advanced stage involves nodes on both sides of the diaphragm or supradiaphragmatic nodes with splenic involvement (Stage III) or extra-nodal disease (Stage IV) [2]. Early stage is typically treated with chemotherapy (Adriamycin, bleomycin, vinblastine, and dacarbazine, ABVD) with involved-node radiation [1]. Advanced stage disease is typically treated with chemotherapy, with ABVD as the primary agent [1]. Individualized treatment regimens are used based on patient demographics, comorbidities, and response. These treatments are given with curative intent [1]. Outcomes for Classic Hodgkin's Lymphoma are excellent. 5-year survival rates of patients with Hodgkin Lymphoma ranges from 90-96% [2].

### Differential Diagnoses:

#### **Hodgkin lymphoma**

Hodgkin Lymphoma is a class of B-cell lymphomas which most often occur in adolescents and young adults. Classic Hodgkin Lymphoma, which our patient has, is the most common subtype, accounting for up to 85% of all Hodgkin cases [3]. This disease typically presents with supradiaphragmatic lymphadenopathy. Our patient's age, lack of breast cancer family history or other risk factor, lack of breast mass, and asymmetric lymphadenopathy makes a lymphoproliferative disorder such as Hodgkin lymphoma the leading differential. Hodgkin lymphoma is diagnosed by tissue sampling.

#### **Sarcoidosis**

Sarcoidosis is a granulomatous disease which commonly presents as bilateral hilar and mediastinal lymphadenopathy. Sarcoidosis is a systemic disease which can cause lymphadenopathy elsewhere, in addition to lung, cardiac, and other abnormalities; however, asymmetric, axillary lymphadenopathy is not a typical presentation of this disease [4]. Other granulomatous diseases such as granulomatous with polyangiitis may also be considered in this differential but would be expected to present with widespread clinical disease [5].

#### **Invasive Ductal Carcinoma**

Invasive ductal carcinoma is by far the most common subtype of breast cancer in men, but typically presents as a painless retro-areolar mass (75% of cases) [6]. This patient does not have palpable or imaging findings of a breast mass. Rarely, male breast cancer can present as metastatic lymph node(s) of an occult breast primary. Though our patient's lymph node is enlarged, which can be seen in metastatic nodal disease, it does not have any other expected characteristics of nodal

metastasis such as cortical thickening, irregular borders, or fatty hilum effacement. Cortical thickness greater than three millimeters increases suspicion for malignancy. Other predictors of malignancy include round shape and absence of normal fatty hilum. In differentiating between lymphoma and invasive ductal carcinoma, imaging that reveals architectural distortion, calcifications or spiculations are commonly absent in lymphoma [7,8,9].

### Nonspecific reactive lymphadenopathy

Axillary lymphadenopathy is in most cases non-specific or reactive. It can be due to a range of causes including infection, malignancy, drug reactions, autoimmune disorders, and can also be idiopathic. General peripheral lymphadenopathy is a common occurrence with a low prevalence (<1%) of associated malignancy in general practice. Localization of lymphadenopathy is used to narrow the differential between localized and generalized disease. Palpable nodes in the axilla are generally considered abnormal if their diameter exceeds one cm, however, there is no threshold for neoplastic suspicion [10]. In contrast to malignancy, enlarged nodes in nonspecific reactive lymphadenopathy typically display normal node morphology [5]. Ultimate differentiation between reactive lymphadenopathy and malignancy requires tissue sampling diagnosis.

### Infection

Infectious etiologies of axillary lymphadenopathy are broad, but may include staphylococcal and streptococcal skin infections, cat scratch disease, Tuberculosis, and HIV [5]. Imaging features may be difficult to differentiate between benign nonspecific reactive lymphadenopathy and active infection due to underlying activation of lymphocytes, therefore clinical history and evaluation can assist in this differential [5,8,11,12]. In this patient, there is a focal peripheral lymph node enlargement without signs or symptoms of infection, including a lack of recent history of skin or upper respiratory tract infection. The chronicity of his symptoms presenting for four months also makes acute infectious etiologies less likely.

### Connective Tissue Diseases

Connective tissue diseases are a common cause of non-infectious lymphadenopathy and may include autoimmune or rheumatological diseases such as rheumatoid arthritis, Systemic Lupus Erythematosus, and scleroderma. Lymph node enlargement may also be secondary to gold salt therapy for rheumatoid arthritis treatment [5]. In our patient, the solitary presentation of axillary lymphadenopathy and breast mass is less likely attributed to a connective tissue disease in the absence of additional clinical symptoms like rashes, arthropathy, or muscular weakness. Further, while it is important to consider these syndromes, tissue biopsy continues to provide more definitive and effective results to rule out malignant processes in an otherwise healthy individual.

mammography, MRI and FDG-PET/CT, more robust research is required to reach a standard pathway of management to lead to efficient diagnosis, staging, and treatment.

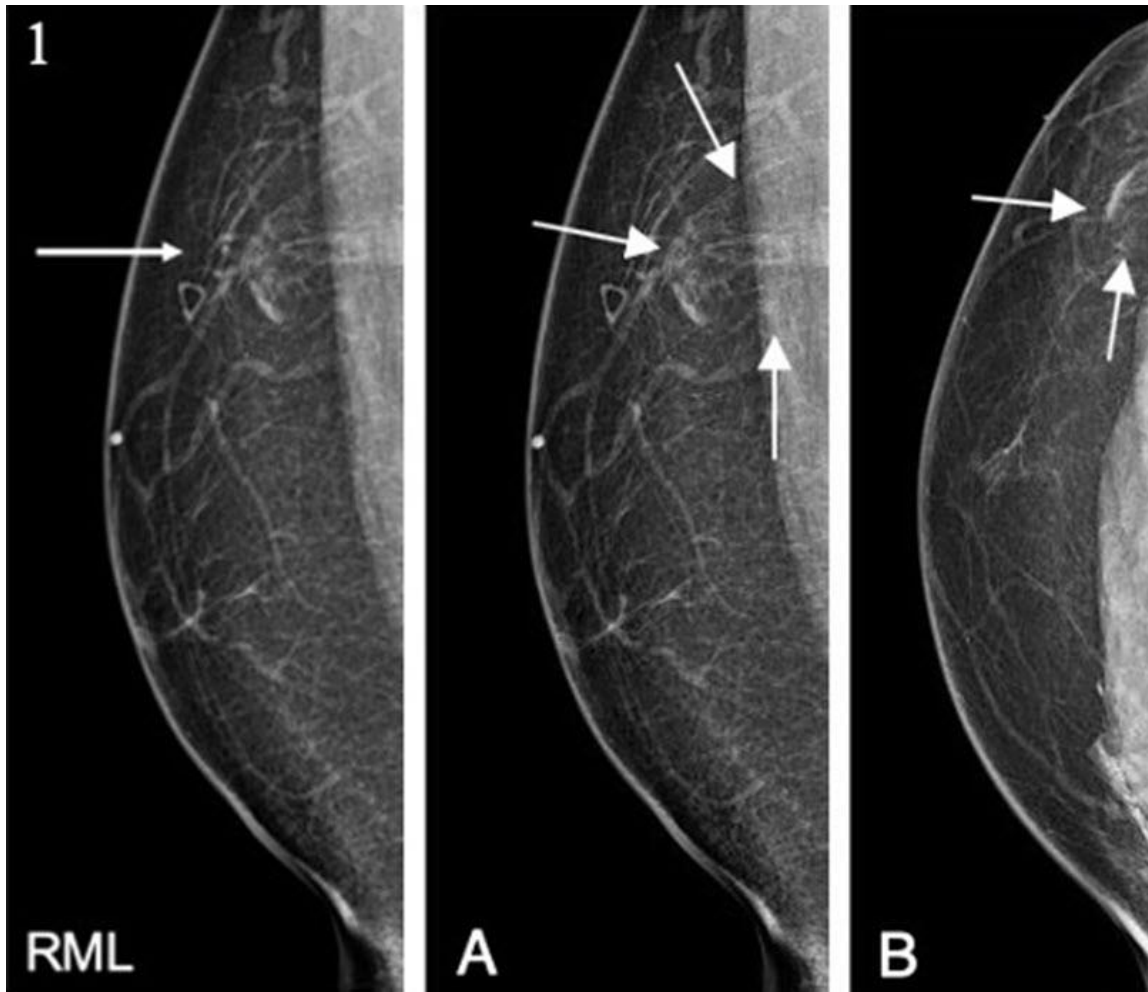
## REFERENCES

1. Ansell SM. Hodgkin lymphoma: A 2020 Update on Diagnosis, Risk-Stratification, and Management. *Am J Hematol* 2020;95 (8):978-989. PMID: 31880271
2. Shanbhag S, Ambinder RF. Hodgkin Lymphoma: A Review and Update on Recent Progress. *CA Cancer J Clin.* 2018;68 (2):116-132. PMID: 29194581
3. Wang HW, Balakrishna JP, Pittaluga S, Jaffe ES. Diagnosis of Hodgkin Lymphoma in the Modern Era. *Br J Haematol.* 2019;194 (1):45-49. PMID: 30407610
4. Crouser ED, Maier LA, Wilson KC, et al. Diagnosis and Detection of Sarcoidosis. An Official American Thoracic Society Clinical Practice Guideline. *Am J Respir Crit Care Med.* 2020;201(8):e26-e51. doi:10.1164/rccm.202002-0251ST. PMID: 32293205
5. Upadhyay N, Juette A, Denton E. Breast Disease and Mammography. Chapman & Nakielny's Aids to Radiological Differential Diagnosis. 7th ed. 2019;11: 333-348. ISBN: 9780702075407
6. Nofal MN, Yousef AJ. The Diagnosis of Male Breast Cancer. *Neth J Med.* 2019;77 (10): 356-359. PMID: 31880271
7. Shim E, Song SE, Seo BK, et al. Lymphoma affecting the breast: a pictorial review of multimodal imaging findings. *J Breast Cancer.* 2013;16(3):254-65. doi: 10.4048/jbc.2013.16.3.254. PMID: 24155754
8. Dialani V, James DF, Slanetz PJ. A practical approach to imaging the axilla. *Insights Imaging.* 2015;6(2):217-29. doi: 10.1007/s13244-014-0367-8. PMID: 25534139
9. Stachs A, Thi AT, Dieterich M, et al. Assessment of Ultrasound Features Predicting Axillary Nodal Metastasis in Breast Cancer: The Impact of Cortical Thickness. *Ultrasound Int Open.* 2015;1(1):E19-24. doi: 10.1055/s-0035-1555872. PMID: 27689144
10. Mohseni S, Shojaiefard A, Khorgami Z, et al. Peripheral lymphadenopathy: approach and diagnostic tools. *Iran J Med Sci.* 2014;39(2 Suppl):158-70. PMID: 24753638
11. Torabi M, Aquino SL, Harisinghani MG. Current concepts in lymph node imaging. *J Nucl Med.* 2004;45(9):1509-18. PMID: 15347718
12. Zeman MN, Green C, Akin EA. Spectrum of [18F] FDG-PET/CT Findings in Benign Lymph Node Pathology. *Mol Imaging Biol.* 2021;23(4):469-480. doi: 10.1007/s11307-020-01576-8. PMID: 33512649

## TEACHING POINT

This case demonstrates an unusual breast imaging diagnosis of lymphoma in an uncommon breast imaging patient, a male. While in this case the diagnosis was reached through imaging work-up of a palpable mass including diagnostic

## FIGURES



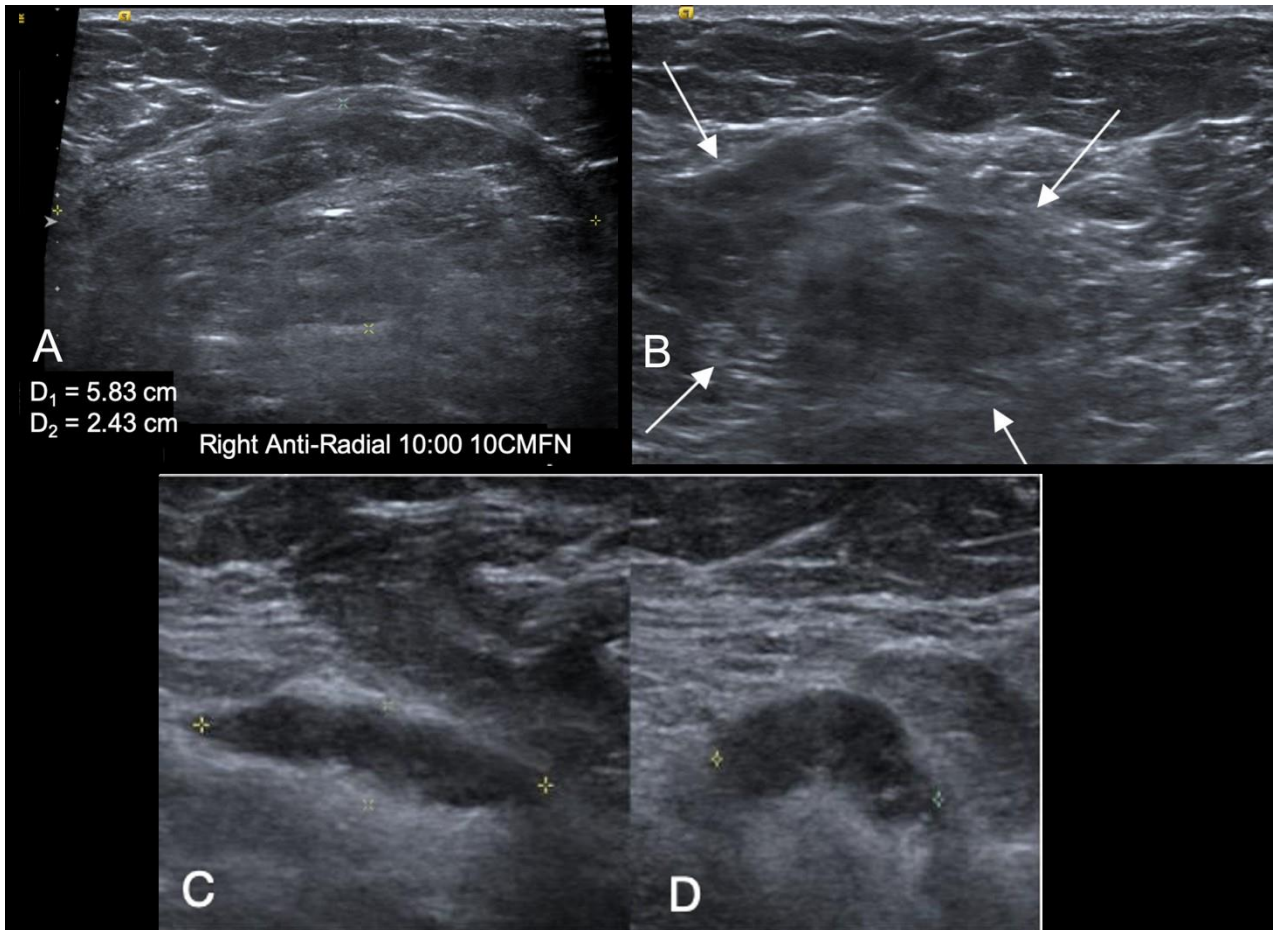
**Figure 1:** 36-year-old Male with Hodgkin's Lymphoma.

**Findings:**

A) Mediolateral (ML) view from diagnostic mammogram of the right breast revealed an almost entirely fatty breast with a partially encapsulated fatty and soft tissue mass in the upper outer right breast/axillary tail at posterior depth (white arrows). Note the triangular marker placed at the site of the patient's palpable abnormality and overlying this abnormal finding. The posterior aspect of the mass is not seen and is likely within the axilla.

B) Craniocaudal (CC) view from diagnostic mammogram of the right breast subtly captures part of the axillary tail fatty and soft tissue mass (white arrows). Again, the mass appears to extend posteriorly into the axilla.

**Technique:** Diagnostic mammogram of right breast. A) Mediolateral (ML) view. B) Craniocaudal (CC) view.



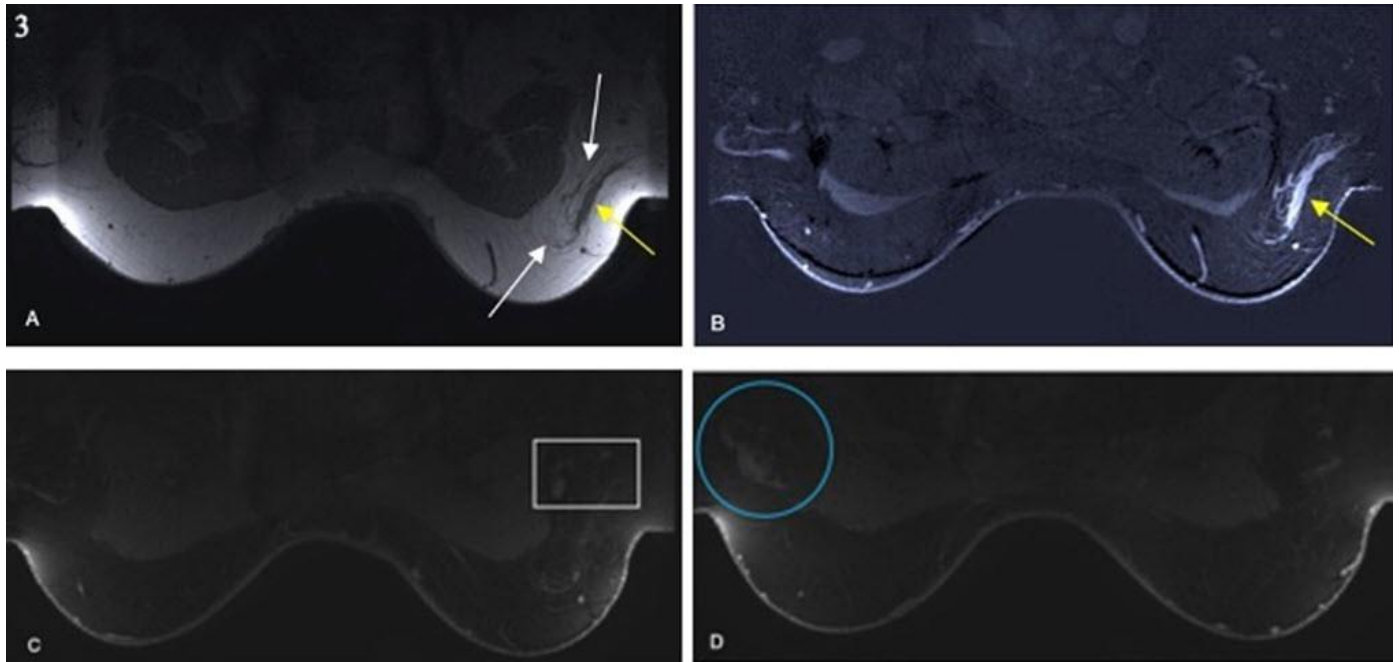
**Figure 2:** 36-year-old Male with Hodgkin's Lymphoma.

**Findings:**

A) Sagittal and B) Transverse gray-scale ultrasound images at the site of palpable abnormality in the right axillary tail revealed a mobile, palpable, largely fatty mass measuring 5.8 x 2.4 x 4.9 cm (white arrows).

C) Sagittal and D) Transverse views of an adjacent abnormal lymph node in the right axilla with cortical thickening (yellow calipers) measuring 8 mm and partial effacement of the fatty hilum.

**Technique:** Gray-scale ultrasound imaging of right axilla using 14-MHz linear-array transducer. A and C) Sagittal view. B and D) Transverse view.



**Figure 3:** 36-year-old Male with Hodgkin's Lymphoma.

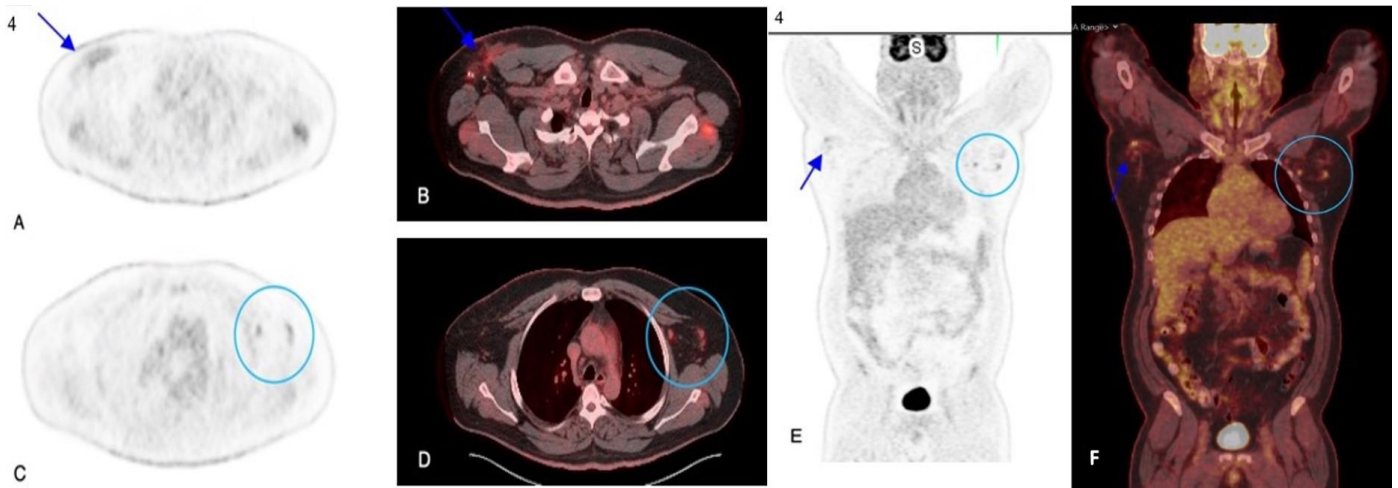
**Findings:**

A) Axial non-contrast T1-weighted image through the breasts revealed an 8.0 x 1.5 cm oval, heterogenous, ill-defined fatty mass in the right axillary tail (white arrow identifies fatty component, yellow arrow identifies non-fatty soft tissue).

B) Axial, contrast-enhanced T1-weighted subtraction image through the breasts revealed irregular enhancement of the mass's lateral soft tissue component (yellow arrow).

Post-contrast T1-weighted images through the breasts reveal C) rounded, abnormal right axillary lymph nodes with fatty hilum effacement (white square) and D) enlarged left axillary lymph nodes with possible cortical thickening (blue circle).

**Technique:** MRI 1.5 Tesla. 28 mL Gadoterate meglumine (DOTAREM). MR imaging of bilateral breasts. It is noted that per this imaging protocol, the right side of the patient's body aligns with the right side of the screen. A) Axial non-contrast T1-weighted MR image. B) Axial contrast-enhanced T1-weighted MR subtraction image. C and D) Post-contrast T1-weighted axial MR images with fat saturation.



**Figure 4:** 36-year-old Male with Hodgkin's Lymphoma.

#### Findings:

Axial PET (A) and fused axial PET/CT (B) through the upper chest obtained one hour after IV administration of 10.4 mCi 18F-FDG revealed mildly FDG-avid ill-defined soft tissue in the right axilla/right axillary tail (blue arrows) with adjacent surgical clips from excisional biopsy. There is also non-specific, likely physiologic, uptake seen in the bilateral shoulder muscles.

Axial PET (C) and fused axial PET/CT (D) images from the same study at a slightly superior aspect of the chest identified mildly FDG-avid left axillary lymph nodes (circle) normal in size and morphology. Left axillary nodal enlargement as seen on the prior breast MRI is no longer identified.

Coronal PET (E) and fused coronal PET/CT (F) from the skull base to mid-thigh from the same study identifies both findings on the same image - the FDG-avid ill-defined soft tissue in the right axilla/axillary tail (blue arrows) as well as the mildly FDG-avid but otherwise normal-appearing left axillary lymph nodes (circle). Also noted is high FDG uptake in the brain and bladder, part of the normal biodistribution of this radiotracer.

Technique: Axial PET (A and C) and fused axial PET/CT (B and D) through the upper chest. Coronal PET (E) and fused coronal PET/CT (F) from the skull base to mid-thigh. Images obtained one hour after IV administration of 10.4 mCi 18F-FDG.

<b>Etiology</b>	Not fully elucidated. Association with viral exposure, notably Epstein Barr Virus.
<b>Incidence</b>	8500 cases per year, comprising 10% of all lymphomas in the United States.
<b>Sex distribution</b>	Slight male dominance in childhood.
<b>Age predilection</b>	Bimodal distribution. Increased incidence in early adulthood (15-34 years old) and ages 55 years and older.
<b>Risk factors</b>	Age, family history of lymphoma, immunosuppression, HIV infection, organ transplantation.
<b>Treatment</b>	Chemotherapy and radiation are mainstays of treatment. Preferred chemotherapy agents are ABVD (Adriamycin, bleomycin, vinblastine, and dacarbazine) and involved-node radiation.
<b>Prognosis</b>	Excellent prognosis, 90-96% survival rate after 5 years.
<b>Imaging findings</b>	<p><i>Mammography:</i> Solitary, noncalcified mass, with varied density.</p> <p><i>Ultrasound:</i> Typically, hypoechoic solid mass, can have circumscribed or indistinct margins. Commonly with posterior acoustic enhancement.</p> <p><i>MRI:</i> Ill-defined fatty mass. Heterogeneous enhancement on T1-weighted imaging.</p> <p><i>PET/CT:</i> FDG-avid soft tissue.</p>

**Table 1:** Summary table of Hodgkin's Lymphoma.

	Location	CT	MRI	FDG-PET
<b>Hodgkin Lymphoma</b>	Lymph nodes, Axilla, Breast, Systemic.	Enlarged lymph node, often >1 cm. Circumscribed round or oval mass. Can have variable enhancement.	Ill-defined fatty mass. Heterogeneous enhancement on T1-weighted imaging. Can have rapid initial enhancement on kinetic analysis.	Mildly enhancing irregular soft tissue.
<b>Sarcoidosis</b>	Breast, Lungs, Systemic.	Pulmonary peri-lymphatic nodules.	Hilar and mediastinal lymphadenopathy.	Hypermetabolic bilateral mediastinal and hilar lymphadenopathy.
<b>Invasive Ductal Carcinoma</b>	Axillary tail, Breast.	Typically heterogeneous mass with irregular or spiculated margins.	Heterogeneous mass with irregular or spiculated margins. Variable internal enhancement. Rapid marked enhancement with early washout.	FDG-avid breast soft tissue lesion.
<b>Infection (HIV, TB)</b>	Depending on infectious agent: May be localized to focal area or systemic.	Typically enlarged lymph node, may have inflammatory peri-nodal stranding.	In systemic infection, would expect multiple enlarged lymph nodes. Size can be a nonspecific finding, however.	Marked enhancement from activated lymphocytes in round or oval circumscribed soft tissue.
<b>Connective Tissue Disease (Rheumatoid Arthritis, Scleroderma, SLE)</b>	Systemic, typically bilateral lymphadenopathy.	Features dependent on disease. Lymph node enlargement may be secondary to gold salt therapy for rheumatoid.	Features specific to disease, typically widespread systemic presentation.	Features are specific to disease.
<b>Nonspecific Reactive Lymphadenopathy</b>	May be unilateral or bilateral, diffuse, or focal.	Enlarged circumscribed lymph node. Preserved normal nodal morphology. Isodense to muscle on non-contrast and homogeneous contrast enhancement.	Well-defined enlarged lymph node. Preserved normal nodal morphology. T2-hyperintense and contrast enhancing.	Marked enhancement from activated lymphocytes in circumscribed soft tissue.

**Table 2:** Differential diagnosis table for Hodgkin's Lymphoma.

#### ABBREVIATIONS

CC = Craniocaudal  
 ML = Mediolateral  
 MR = Magnetic Resonance  
 NSCHL = Nodular Sclerosing Classical Hodgkin Lymphoma  
 PET = Positron Emission Tomography

#### KEYWORDS

Lymphoma; Hodgkin; Breast; Mammography; MRI; Ultrasound; Lymphoproliferative; Axillary

#### Online access

This publication is online available at:  
[www.radiologycases.com/index.php/radiologycases/article/view/4508](http://www.radiologycases.com/index.php/radiologycases/article/view/4508)

#### Peer discussion

Discuss this manuscript in our protected discussion forum at:  
[www.radiolopolis.com/forums/JRCR](http://www.radiolopolis.com/forums/JRCR)

#### Interactivity

This publication is available as an interactive article with scroll, window/level, magnify and more features.  
 Available online at [www.RadiologyCases.com](http://www.RadiologyCases.com)

Published by EduRad



[www.EduRad.org](http://www.EduRad.org)