

# Pleomorphic Sarcoma in a Patient with Osteopetrosis

Kevin McGill<sup>1\*</sup>, Daria Motamedi<sup>1</sup>, Nima Azimi<sup>2</sup>, Andrew Horvai<sup>3</sup>, Richard O'Donnell<sup>4</sup>


1. Department of Radiology, University of California, San Francisco, USA

2. Massachusetts General Hospital, Boston, USA

3. Department of Pathology, University of California, San Francisco, USA

4. Department of Orthopaedic Surgery, University of California, San Francisco, USA

\* **Correspondence:** Kevin McGill MD, MPH, Assistant Professor of Musculoskeletal Radiology, Department of Radiology and Biomedical Imaging, University of California, San Francisco, 400 Parnassus Ave., San Francisco, CA 94143, USA

 [Kevin.mcgill@ucsf.edu](mailto:Kevin.mcgill@ucsf.edu)

Radiology Case. 2020 Jul; 14(7):1-9 :: DOI: 10.3941/jrcr.v14i7.3920

## ABSTRACT

Osteopetrosis comprises a rare, heterogeneous group of heritable conditions that are characterized by a defect in bone resorption by osteoclasts. We report the case of a 53-year-old woman with previously undiagnosed osteopetrosis who presented with a pathologic proximal humeral fracture secondary to pleomorphic sarcoma, which is previously undescribed in the English literature. Management of the primary lesion necessitated ablative surgery, but the malignancy nonetheless was associated with rapidly progressive metastatic disease.

## CASE REPORT

### CASE REPORT

A 53-year-old woman with a past medical history of delayed development, hypothyroidism, and hyperlipidemia presented to the Emergency Department with shoulder pain and immobility. Radiographs showed a displaced pathologic fracture through a solitary lytic lesion of the proximal humerus characterized by irregular cortical destruction and lack of mineralized matrix. There was no periosteal reaction or soft tissue mass. The lesion was superimposed on a pattern of diffuse symmetric osseous sclerosis involving the entire visualized axial and peripheral skeleton (Figures 1 and 2). Magnetic resonance imaging (MRI) of the lower extremities demonstrated low intramedullary signal suggesting osteopetrosis, the autosomal dominant variant [1] (Figure 3). A shoulder MRI confirmed the presence of a destructive mass centered in the humeral metaphysis with extension into the epiphysis. The lesion returned low signal on T1-weighted images and high signal on short-tau inversion recovery (STIR) images. Peripheral enhancement surrounded a large central

non-enhancing area as well as the adjacent periosteum. Technetium-99m (99mTc)-diphosphonate bone scintigraphy demonstrated diffusely increased uptake throughout the axial and appendicular skeleton, with decreased renal activity, consistent with a “skeletal superscan”. Additional uptake was noted in the fractured proximal humerus, where there was a photopenic central region (Figure 4). The provisional diagnosis was an aggressive primary osseous sarcoma or solitary metastasis involving the humerus in a patient with osteopetrosis. Additional consideration was given to the possibility that a lytic metastasis could be superimposed on diffuse osteoblastic metastases. However, the smooth, symmetric diffuse sclerosis favored the diagnosis of osteopetrosis.

An incisional biopsy demonstrated a high grade undifferentiated pleomorphic sarcoma (UPS) of bone. A metastatic workup was negative for additional lesions. After considering the difficulty of achieving successful limb salvage reconstruction in an osteopetrotic humeral medullary canal,

and the likelihood of local recurrence in light of the pathologic fracture, the patient's parents decided to have her undergo a forequarter amputation for definitive local control, without the need for additional adjuvant radiation or chemotherapy. The patient was developmentally delayed and unable to fully participate in medical decision-making.

Final pathology revealed a 5.5 cm diameter, grade 3 tumor characterized by sheets of pleomorphic cells with marked nuclear atypia and mitotic activity including atypical forms (Figure 5). The tumor developed in the bone and spread to the soft tissues without involvement of the glenohumeral joint. No obvious line of differentiation was evident on routine hematoxylin and eosin sections, and no skeletal matrix production by tumor cells was observed. Immunohistochemical testing revealed positivity for CD68 and negativity for keratin, epithelial membrane antigen, desmin, S100, and smooth muscle actin. Based on the morphologic and immunophenotypic findings, a diagnosis of undifferentiated pleomorphic sarcoma (UPS) was rendered. Osteopetrotic bone was also observed, exemplified by thickened, dense cortices and bony trabeculae, with no indication of a medullary cavity (Figure 6). Surgical margins were negative.

The patient did well initially, however, a chest computed tomography (CT) scan performed 3 months postoperatively showed numerous large pulmonary nodules (Figure 7). The patient became wheelchair bound, developed widespread progression, and succumbed to her disease 5 months after the surgery.

## DISCUSSION

### Etiology & Demographics:

Osteopetrosis is a heterogenous collection of hereditary diseases with three commonly described variants. The more common, autosomal dominant and often phenotypically benign mutation, which has an incidence of 1:20,000 [2], is associated with a normal life expectancy. The more aggressive (autosomal recessive) variant has an incidence in the general population of 1:250,000 [2] and usually presents early in life with widespread systemic manifestations. Symptoms in infants include a characteristic heavy head with frontal bossing and blindness. The defects in osteoclast function and bone resorption inhibit normal organ development in bony cavities [3]. This can also lead to fatal infections such as pneumonia, and osteomyelitis complicated by septicaemia [2]. The X-linked recessive form is extremely rare, with only a few cases described in the literature. This type of osteopetrosis is also associated with lymphedema, ectodermal dysplasia, and immunodeficiency syndrome (OL-EDA-ID) [4].

The primary genetic defects in these patients often relate to abnormalities in osteoclast-specific membrane proteins involved in ion transport [5]. The deficiency in osteoclast functioning has also been found to be linked with a mutation of the macrophage colony stimulating factor (M-CSF) gene

[6]. Other genetic malfunctions create deficiencies in the proton pump, chloride channel, and osteopetrosis associated transmembrane protein 1 (OSTM1), which also diminishes the effectiveness of osteoclasts [3]. The majority of these genes are linked to the control of osteoclast pH [2].

UPS (formerly malignant fibrous histiocytoma, MFH) is one of the most common soft tissue sarcomas, but it is rare as a form of primary bone tumor [7-9]. The incidence of UPS of bone increases with age, with the median age of incidence around 65 years [8]. The most common type of UPS is storiform-pleomorphic, although other variants include giant cell, inflammatory, and myxoid [8, 10]. This sarcoma is usually found in the extremities and trunk, particularly the femur [17]. Rare cases of UPS have been observed in the calcaneus and patella [9, 11]. UPS associated with multiple primary sites, neurofibromatosis, and chronic osteomyelitis have been reported [8, 12, 13].

### Clinical & Imaging Findings:

Clinically, severely affected individuals often present with anemia, cranial neuropathies, and fracture deformities. Osteomyelitis of the jaw may occur secondary to poor dentition. The more common benign form of osteopetrosis is associated with characteristic diffuse increased sclerosis in the axial and peripheral skeleton with an increased incidence of fractures. These patients often present later in life and as they progress in age, increase their risk for developing an underlying malignancy.

Tumors involving the bone in patients with osteopetrosis are extremely rare. To our knowledge, this case is the only report in the English literature of sarcomatous transformation of osteopetrosis. Lopes described a similar occurrence in the Belgian literature in 1952 [14]. No reports of osteopetrosis patients having osseous metastases exist. Fadda et al. discussed a young patient with osteopetrosis and small cell lung carcinoma, but without bone metastases [15]. This paper stressed the unusual age of the lung cancer patient and the importance of careful titration of chemotherapeutic agents in this population due to their limited bone marrow reserve. Due to the rare nature of osteopetrosis, it is unknown if the overall decreased marrow space decreases the incidence of osseous metastases.

Some authors have highlighted the potential effect of osteopetrosis on various bone marrow elements and/or the immune system, including case reports describing patients with osteopetrosis and peripheral T-cell lymphoma; esophageal adenocarcinoma and secondary hypersplenism; and acute myeloid leukemia in a child [16-18]. Finally, Toren et al. noted the similarities between osteopetrosis and juvenile chronic myeloid leukemia [19].

Other authors have investigated osteopetrosis patients who had specific osseous lesions that were ultimately determined to be non-malignant, including a lytic rib abnormality confirmed histologically to be a benign post-traumatic hemorrhagic bone cyst, and a case of osteopetrosis mimicking osteosarcoma [20, 21].

UPS of bone can present as pain and swelling of the affected extremity, prompting an x-ray to confirm the presence of an aggressive lesion. UPS is rare, accounting for only 0.8-1 new cases/100,000 patients/year, with a slight male predominance [22, 23]. Older patients, usually 50-70 years old [22], are more likely to be affected but UPS can occur at any age. While most patients have no risk factors, prior radiation and certain tumor predisposition syndromes have been known to be precipitating factors [24-26].

While most UPS occurs in the soft tissue and may appear similar to other aggressive soft tissue processes, when UPS is centered in the bone, it more closely resembles destructive osseous lesions such as osteosarcoma, Ewing's sarcoma, or metastatic carcinoma. UPS of bone can present as a large lucent lesion with cortical destruction, a permeative "moth eaten" appearance, and ill-defined margins on radiographs and CT. Magnetic resonance imaging (MRI) may demonstrate increase T2 signal and heterogeneous enhancement of the mass. T1 signal is low to iso intense but may be variable in the presence of internal hemorrhage.

Increased uptake is present on bone scintigraphy, which can be central or peripheral. In a patient with generally increased tracer uptake, which is common in osteopetrosis, mild central uptake could make the lesion indistinguishable from the adjacent bone. Alternatively, if there is only peripheral uptake at the site of the tumor, the primary lesion could appear as a central focus of photopenia. Radiographic skeletal surveys may thus be a complimentary modality to bone scintigraphy in screening for osseous lesions in patients with osteopetrosis.

Patients with osteopetrosis can exhibit many different clinical manifestations. However, this is the first reported case in the English literature of a UPS involving the appendicular skeleton in osteopetrosis. This case demonstrates the possibility of UPS of bone arising concurrently with osteopetrosis. Due to the rarity of this condition, it is unclear whether osteopetrosis is a pre-malignant condition, as only a few case reports have described the co-occurrence of this disease and a malignancy, and no case reports of patients with osseous metastases have been reported. The importance of careful clinical and radiologic follow-up, including standard skeletal surveys, is exemplified with this case, as bone lesions can be masked by underlying osteopetrosis on scintigraphic imaging.

#### Treatment & Prognosis:

Treatment of UPS of bone involves a multimodality approach, often including chemotherapy and wide surgical excision. Radiation therapy is generally reserved for cases of positive surgical margins [27]. Most UPS occurs as a soft tissue sarcoma, and, despite aggressive treatment, the diagnosis is associated with a poor prognosis, with a metastatic rate of 50% [28]; local recurrence rates ranging from 10-30% over a 5 year period depending on tumor histology, grade, and surgical margins [29-33]; and 5-year and 10-year overall survival rates of 60% and 48%, respectively [34]. Some important positive prognostic indicators are

negative surgical margins and radiation therapy [32]. Factors that may suggest poor outcomes include advanced patient age and larger tumor size, with lesions greater than 5 cm being associated with tumor recurrence [35].

#### Differential Diagnosis:

UPS is a diagnosis of exclusion which describes a heterogeneous group of malignant mesenchymal tumors characterized by morphologic pleomorphism without specific features that would enable classification within the group of pleomorphic sarcomas. While imaging can also be nonspecific [36], these lesions may resemble other aggressive osseous lesions such as osteosarcoma, Ewing's sarcoma, or metastatic carcinoma. The pathologic differential includes other pleomorphic sarcomas (leiomyosarcoma, rhabdomyosarcoma, osteosarcoma), so-called "dedifferentiated" sarcomas (liposarcoma, chondrosarcoma) as well as sarcomatoid carcinoma and melanoma). Patient history may be useful as UPS has a male preponderance, is more common in older adults, and is the most common postradiation sarcoma [22, 24-26]. UPS also exhibits a predilection for the extremities (most commonly seen in the femur), which accounts for the majority of cases [37]. Involvement of the abdominal viscera is rare; therefore, this presentation would suggest a different diagnosis.

#### TEACHING POINT

Primary bone malignancies such as undifferentiated pleomorphic sarcoma (UPS) are rare, but can occur in patients with osteopetrosis. Careful clinical and radiologic follow-up with standard skeletal surveys and advanced imaging techniques such as magnetic resonance imaging (MRI) and computed tomography (CT) are important since osseous lesions can be masked by underlying osteopetrosis on scintigraphic imaging.

#### REFERENCES

1. Rao VM, Dalinka MK, Mitchell DG, Spritzer CE, Kaplan F, August CS, et al. Osteopetrosis: MR characteristics at 1.5 T. *Radiology* 1986;161(1):217-20. PMID: 3763870
2. Del Fattore A, Cappariello A, Teti A. Genetics, pathogenesis and complications of osteopetrosis. *Bone* 2008;42(1):19-29. PMID: 17936098
3. Askmyr MK, Fasth A, Richter J. Towards a better understanding and new therapeutics of osteopetrosis. *Br J Haematol* 2008;140(6):597-609. PMID: 18241253
4. Smahi A, Courtois G, Rabia SH, Doffinger R, Bodemer C, Munnich A, et al. The NF-kappaB signalling pathway in human diseases: from incontinentia pigmenti to ectodermal dysplasias and immune-deficiency syndromes. *Hum Mol Genet* 2002;11(20):2371-5. PMID: 12351572

5. Tolar J, Teitelbaum SL, Orchard PJ. Osteopetrosis. *N Engl J Med* 2004;351(27):2839-49. PMID: 15625335
6. Yoshida H, Hayashi S, Kunisada T, Ogawa M, Nishikawa S, Okamura H, et al. The murine mutation osteopetrosis is in the coding region of the macrophage colony stimulating factor gene. *Nature* 1990;345(6274):442-4. PMID: 2188141
7. Li J, Geng ZJ, Lv XF, Zhang XK, Xie CM. Computed tomography and magnetic resonance imaging findings of malignant fibrous histiocytoma of the head and neck. *Mol Clin Oncol* 2016;4(5):888-92. PMID: 27123302
8. Muler JH, Paulino AF, Roulston D, Baker LH. Myxoid malignant fibrous histiocytoma with multiple primary sites. *Sarcoma* 2002;6(1):51-5. PMID: 18521346
9. Demiralp B, Erler K, Ozturan EK, Bek D, Ozdemir T, Kurt B. An uncommon presentation of malignant fibrous histiocytoma of the calcaneus. *J Am Podiatr Med Assoc* 2007;97(3):218-22. PMID: 17507531
10. Enzinger FW, S. *Soft Tissue Tumors*. Soft Tissue Tumors. Mosby Inc.; 1995, p. 351-80. ISBN: 0815131321
11. Lopez-Barea F, Rodriguez-Peralto JL, Burgos-Lizalde E, Gonzalez-Lopez J, Sanchez-Herrera S. Case report 639: Malignant fibrous histiocytoma (MFH) of the patella. *Skeletal Radiol* 1991;20(2):125-8. PMID: 1850554
12. Papagelopoulos PJ, Mavrogenis AF, Galanis EC, Chloros GD, Papaparaskaeva KT. Malignant fibrous histiocytoma of bone associated with type-1 neurofibromatosis. A case report. *J Bone Joint Surg Am* 2005;87(2):399-403. PMID: 15687166
13. Zlowodzki M, Allen B, Schreiberman KL, Vance RB, Kregor PJ. CASE REPORTS: malignant fibrous histiocytoma of bone arising in chronic osteomyelitis. *Clin Orthop Relat Res* 2005;439:269-73. PMID: 16205169
14. Lopes F. [Sarcomatous degeneration in a case of osteopetrosis]. *J Belge Radiol* 1952;35(1):212-5. PMID: 14917642
15. Fadda GM, Santeufemia DA, Rocca PC, Costantino S, Sanna G, Sarobba MG, et al. Small cell lung cancer in a young patient with osteopetrosis. *Tumori* 2006;92(6):563-6. PMID: 17260504
16. Hendren SK, Wang J, Gorman J, Peacock T, Herschok DM, Rosato EF. Esophagectomy and splenectomy in a patient with osteopetrosis. *J Thorac Cardiovasc Surg* 2005;129(6):1457-8. PMID: 15942603
17. Hashino S, Hirota G, Hasegawa M, Chiba K, Toyoshima N, Suzuki S, et al. Peripheral T-cell lymphoma in a patient with osteopetrosis. *Ann Hematol* 2001;80(6):376-8. PMID: 11475155
18. Prasad R, Jaiswal BP, Mishra OP, Singh UK. Association of possible osteopetrosis with acute myeloid leukaemia in a child. *BMJ Case Rep* 2013;2013. PMID: 23921696
19. Toren A, Neumann Y, Meyer JJ, Mandel M, Schiby G, Kende G, et al. Malignant osteopetrosis manifested as juvenile chronic myeloid leukemia. *Pediatr Hematol Oncol* 1993;10(2):187-9. PMID: 8318376
20. Greene GS, Bonakdarpour A, Levy W. Case report 278. Osteopetrosis (tarsia type) with hemorrhagic cyst of the right sixth rib (proved) and the left second rib (presumptive). *Skeletal Radiol* 1984;12(1):59-62. PMID: 6474222
21. Ferrari C, Niccoli Asabella A, Altini C, Rubini G. A rare case of osteopetrosis mimicking osteosarcoma: 18F-FDG PET/CT findings in an unexpected diagnosis. *Nuklearmedizin* 2016;55(1):N1-3. PMID: 26875431
22. Weiss SW, Enzinger FM. Malignant fibrous histiocytoma: an analysis of 200 cases. *Cancer* 1978;41(6):2250-66. PMID: 207408
23. Demetri GD, Antonia S, Benjamin RS, Bui MM, Casper ES, Conrad EU, 3rd, et al. Soft tissue sarcoma. *J Natl Compr Canc Netw* 2010;8(6):630-74. PMID: 20581298
24. Berrington de Gonzalez A, Kutsenko A, Rajaraman P. Sarcoma risk after radiation exposure. *Clin Sarcoma Res* 2012;2(1):18. PMID: 23036235
25. Mark RJ, Poen J, Tran LM, Fu YS, Selch MT, Parker RG. Postirradiation sarcomas. A single-institution study and review of the literature. *Cancer* 1994;73(10):2653-62. PMID: 8174066
26. Pitcher ME, Davidson TI, Fisher C, Thomas JM. Post irradiation sarcoma of soft tissue and bone. *Eur J Surg Oncol* 1994;20(1):53-6. PMID: 8131870
27. Lehnhardt M, Daigeler A, Homann HH, Schwaiberger V, Goertz O, Kuhnen C, et al. MFH revisited: outcome after surgical treatment of undifferentiated pleomorphic or not otherwise specified (NOS) sarcomas of the extremities -- an analysis of 140 patients. *Langenbecks Arch Surg* 2009;394(2):313-20. PMID: 18584203
28. Hornick JL. Subclassification of pleomorphic sarcomas: How and why should we care? *Ann Diagn Pathol* 2018;37:118-24. PMID: 30340082
29. Jones NB, Iwenofu H, Scharschmidt T, Kraybill W. Prognostic factors and staging for soft tissue sarcomas: an update. *Surg Oncol Clin N Am* 2012;21(2):187-200. PMID: 22365514
30. Gronchi A, Lo Vullo S, Colombo C, Collini P, Stacchiotti S, Mariani L, et al. Extremity soft tissue sarcoma in a series of patients treated at a single institution: local control directly impacts survival. *Ann Surg* 2010;251(3):506-11. PMID: 20130465
31. Eilber FC, Rosen G, Nelson SD, Selch M, Dorey F, Eckardt J, et al. High-grade extremity soft tissue sarcomas: factors predictive of local recurrence and its effect on morbidity and mortality. *Ann Surg* 2003;237(2):218-26. PMID: 12560780

32. Kamat NV, Million L, Yao DH, Donaldson SS, Mohler DG, van de Rijn M, et al. The Outcome of Patients With Localized Undifferentiated Pleomorphic Sarcoma of the Lower Extremity Treated at Stanford University. *Am J Clin Oncol* 2019;42(2):166-71. PMID: 30557163

33. Lewis JJ, Leung D, Heslin M, Woodruff JM, Brennan MF. Association of local recurrence with subsequent survival in extremity soft tissue sarcoma. *J Clin Oncol* 1997;15(2):646-52. PMID: 9053489

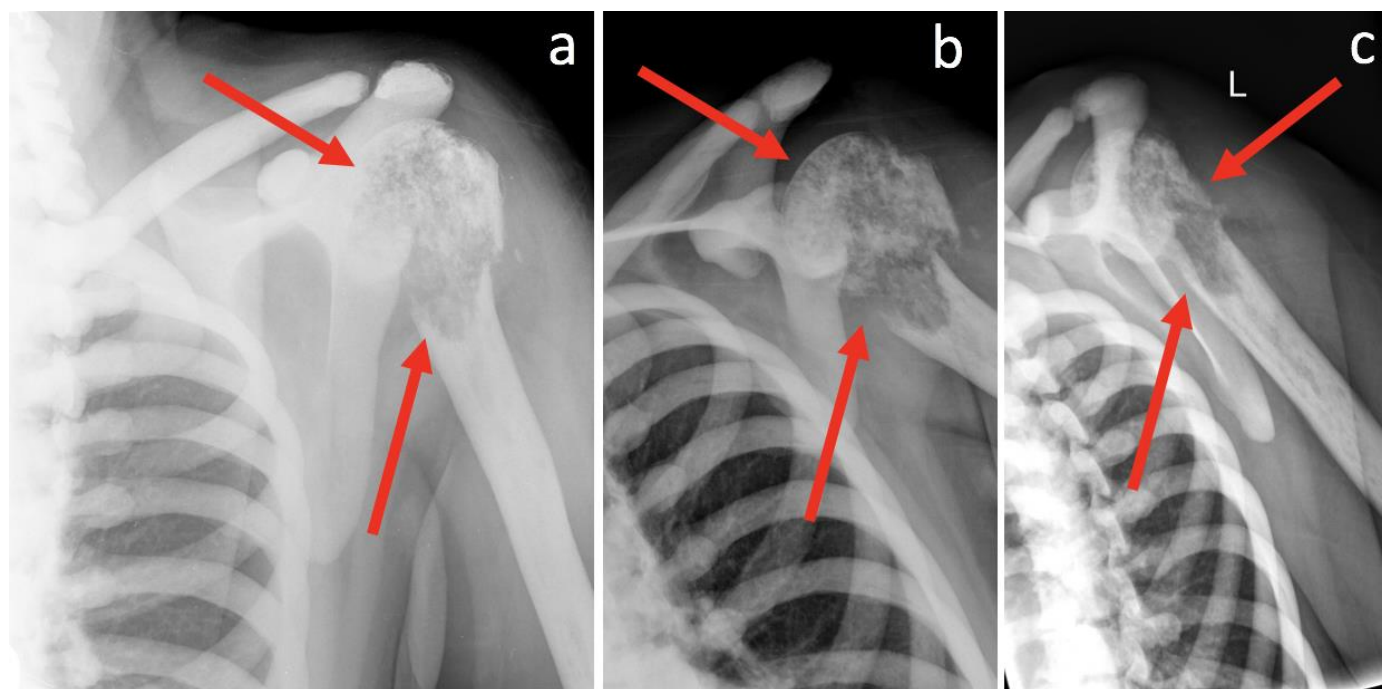
34. Vodanovich DA, Spelman T, May D, Slavin J, Choong PFM. Predicting the prognosis of undifferentiated pleomorphic soft tissue sarcoma: a 20-year experience of 266 cases. *ANZ J Surg* 2019;89(9):1045-50. PMID: 31364245

35. Winchester D, Lehman J, Tello T, Chimato N, Hocker T, Kim S, et al. Undifferentiated pleomorphic sarcoma: Factors predictive of adverse outcomes. *J Am Acad Dermatol* 2018;79(5):853-9. PMID: 29787841

36. Pobirci D, Bogdan F, Pobirici O, Petcu C, Rosca E. Study of malignant fibrous histiocytoma Clinical, statistic and histopatological interrelation. *Romanian Journal of Morphology and Embryology* 2011;52:385-8. PMID: 21424079

37. Ozkurt B, Basarir K, Yildiz YH, Kalem M, Saglik Y. Primary malignant fibrous histiocytoma of long bones: long-term follow-up. *Ekleml Hastalik Cerrahisi* 2016;27(2):94-9. PMID: 27499321

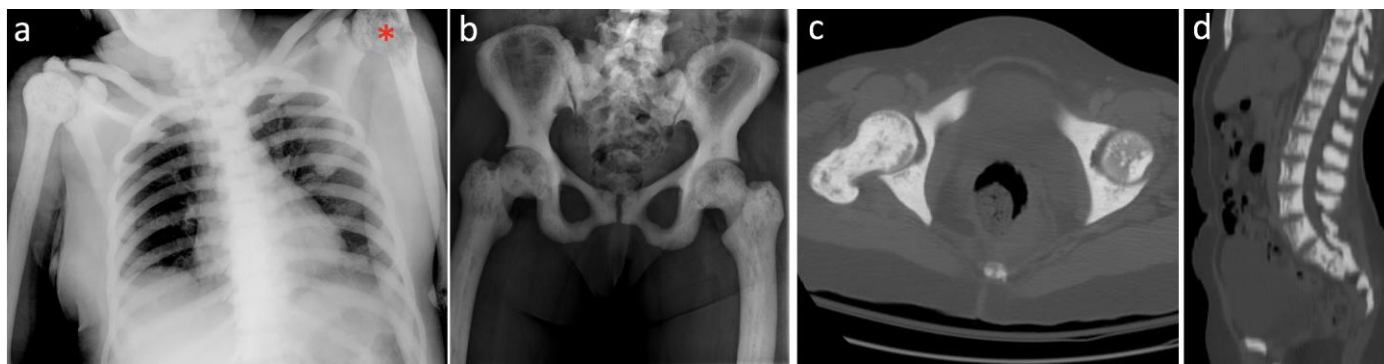
FIGURES



**Figure 1:** 53-year-old woman with previously undiagnosed osteopetrosis who presented with a pathologic proximal humeral fracture secondary to pleomorphic sarcoma.

**Findings:** Anteroposterior radiographs of left shoulder in (a) internal rotation (b) external rotation and (c) scapular Y view. (a), (b), & (c) Radiographs of the left shoulder show a displaced pathologic fracture (arrows) at the surgical neck of the humerus. The fracture extends through an expansile lytic lesion with ill defined borders characterized by irregular cortical destruction. The lesion is superimposed on a pattern of diffuse symmetric osseous sclerosis involving the visualized skeleton, compatible with osteopetrosis.

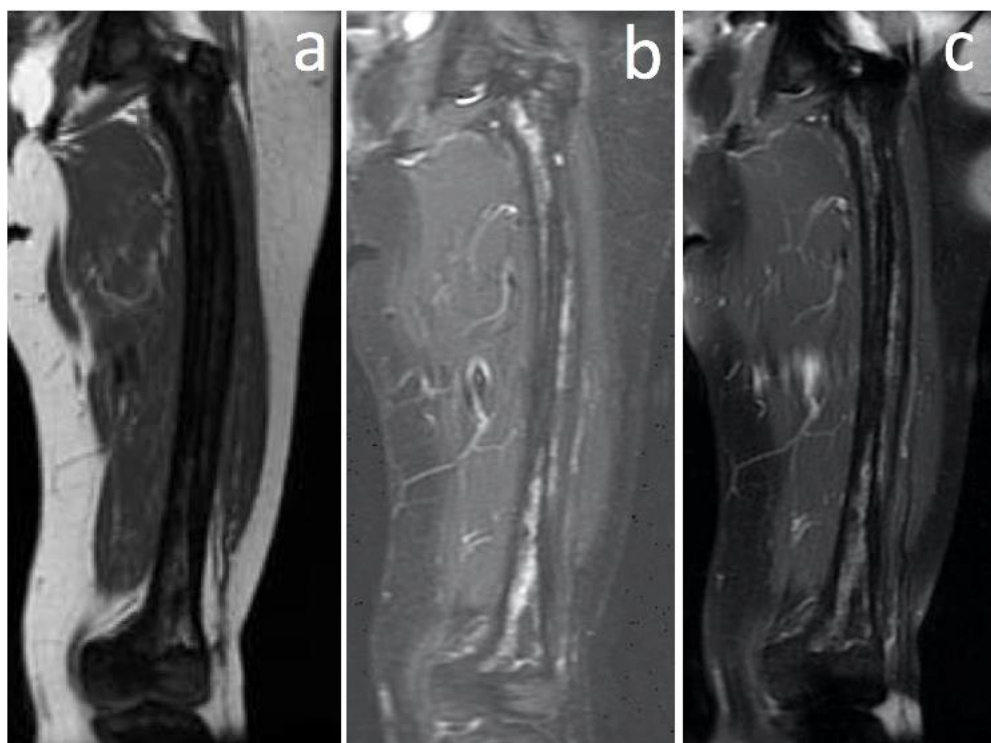
**Technique:** 70 kVp x 10 mAs



**Figure 2:** 53 year old woman with previously undiagnosed osteopetrosis who presented with a pathologic proximal humeral fracture secondary to pleomorphic sarcoma.

**Findings:** Anteroposterior radiographs of the (a) chest and (b) pelvis. (c) Axial CT image of the pelvis. (d) Sagittal CT scan of the spine. (a), (b), (c), & (d) Radiographs and CT scan demonstrating diffuse symmetric osseous sclerosis involving the entire visualized axial and peripheral skeleton. Also again seen (\*), in image 2a is a pathologic fracture through a solitary lytic lesion of the proximal humerus characterized by irregular cortical destruction and lack of mineralized matrix.

**Technique:** Chest radiograph anteroposterior (a) 110 kVp and 4 mAs. Anteroposterior radiograph of the pelvis (b) 80 kVp and 20 mAs in supine position. Contrast enhanced CT with axial (c) and sagittal (d) reformats, GE Discovery CT (General Electric, Milwaukee, WI) 120 kV and 40 mAs with 5 mm slice thickness, 100cc Omnipaque 300.

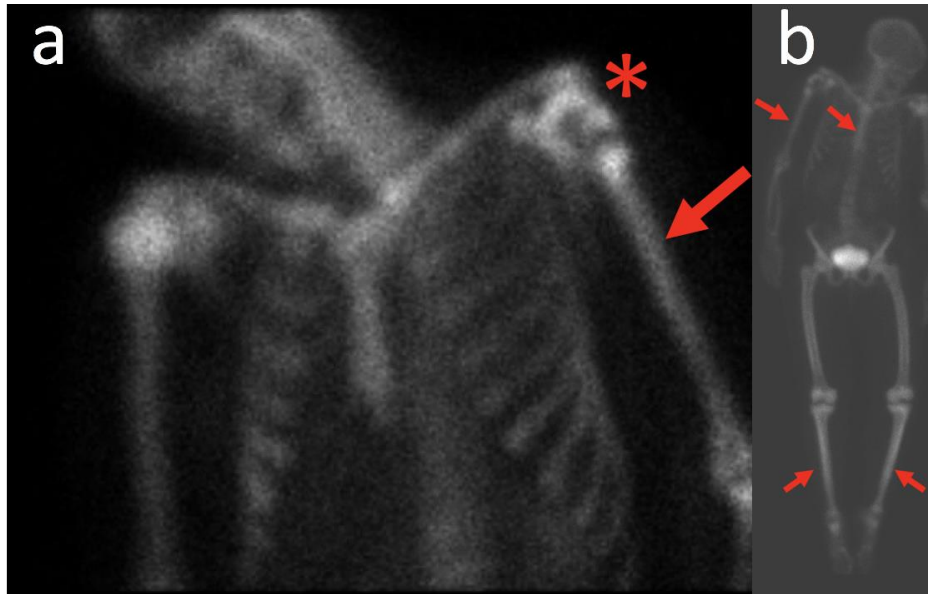


**Figure 3:** 53 year old woman with previously undiagnosed osteopetrosis who presented with a pathologic proximal humeral fracture secondary to pleomorphic sarcoma.

**Findings:** (a) Coronal T1-weighted, (b) Coronal STIR, and (c) Post contrast coronal T1 fat saturated MRI of the left femur demonstrate primarily low intramedullary signal on all sequences corresponding to the diffuse sclerosis with a few scattered areas of bone marrow suggesting the autosomal dominant type of osteopetrosis. No abnormal enhancement is present on post contrast images.

**Technique:** 3T Signa (General Electric, Milwaukee, WI) (a) Coronal T1, TR 600, TE 16, slice thickness 6 mm (b) Coronal STIR, TR 3500, TE 55, slice thickness 6 mm, (c) Coronal T1 fat saturated post contrast MRI, 20 cc gadodiamide (Omniscan, General Electric, Milwaukee, WI), TR 600, TE 16, slice thickness 6 mm

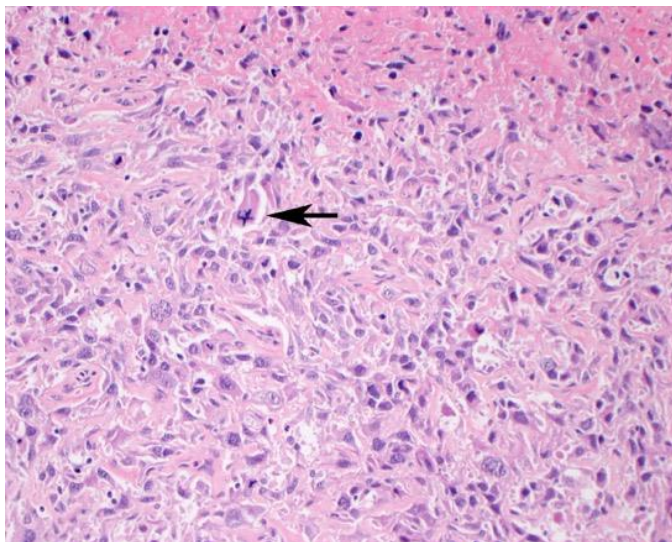




**Figure 4:** 53 year old woman with previously undiagnosed osteopetrosis who presented with a pathologic proximal humeral fracture secondary to pleomorphic sarcoma.

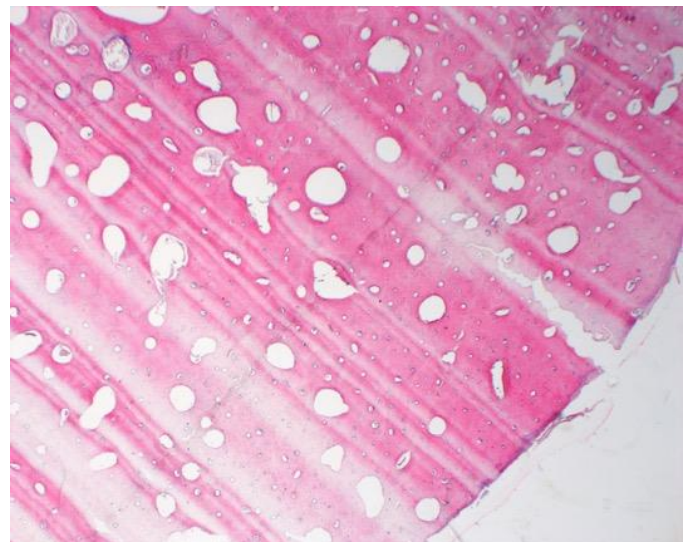
**Findings:** The upper body left anterior oblique (a) and full body anterior (b) bone scan images show diffusely increased uptake (arrows) throughout the skeleton with decreased renal activity consistent with a superscan. Increased uptake with a photopenic central region (\*) is noted within the left proximal humerus corresponding with the site of the lesion seen on radiographs.

**Technique:** Whole body bone scan. Images were obtained 3 hours after intravenous administration of 22 mCi of Tc99m MDP.



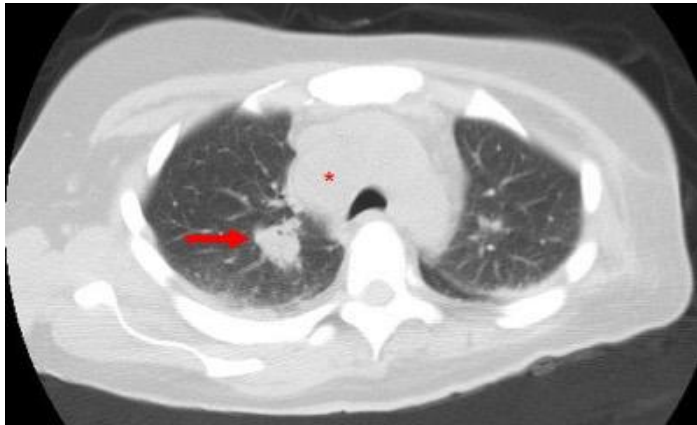
**Figure 5:** 53 year old woman with previously undiagnosed osteopetrosis who presented with a pathologic proximal humeral fracture secondary to pleomorphic sarcoma.

Hematoxylin and eosin stained section of undifferentiated pleomorphic sarcoma (UPS) showed bizarre, atypical cells with atypical mitosis (arrow) and necrosis (top of image). Original magnification 200X.



**Figure 6:** 53 year old woman with previously undiagnosed osteopetrosis who presented with a pathologic proximal humeral fracture secondary to pleomorphic sarcoma.

Osteopetrosis was observed in the uninvolved bone as replacement of the medullary cavity by dense cortical bone. Original magnification 20X.



**Figure 7 (left):** 53 year old woman with previously undiagnosed osteopetrosis who presented with a pathologic proximal humeral fracture secondary to pleomorphic sarcoma.

**Findings:** Axial CT image of the upper chest demonstrate a spiculated mass in the superior aspect of the right upper lobe (arrow) and a large pretracheal lymph node (\*) consistent with metastatic disease.

**Technique:** Axial chest CT, GE Discovery CT (General Electric, Milwaukee, WI), 120 kV and 40 mAs with 5 mm slice thickness.

<b>Entity</b>	Undifferentiated pleomorphic sarcoma of bone
<b>Etiology</b>	Mesenchymal cells without a specific line of differentiation
<b>Clinical Presentation</b>	Pain and swelling of the extremity
<b>Incidence</b>	0.8-1 new case per 100,000 per year
<b>Gender Ratio</b>	Slight male preponderance
<b>Age Predilection</b>	50-70 years old, but can occur at any age
<b>Risk Factors</b>	Most patients have no risk factors, but it can occur in the setting of prior radiation or with tumor predisposition syndromes
<b>Treatment</b>	Surgery (wide margins), +/- Chemotherapy, +/- adjuvant radiation therapy
<b>Prognosis</b>	Overall poor, at least 10-30% local recurrence in 5 years, 50% overall metastatic rate, 38% metastatic rate post treatment, 5-year and 10-year survival rates 60% and 48% respectively
<b>Imaging Findings</b>	Radiographs/CT scan: large lucent aggressive osseous lesion with cortical destruction MRI: large osseous mass iso/low heterogeneous signal on T1 and iso to high heterogeneous signal on T2 weighted images with heterogeneous enhancement

**Table 1:** Summary table for undifferentiated pleomorphic sarcoma of bone.



Diagnosis	General	X-ray/CT	MRI
<b>Undifferentiated pleomorphic sarcoma of bone</b>	Aggressive osseous mass within extremities, femur is most common location, possible metastatic disease	Aggressive osseous lesion, moth eaten appearance	T1: Heterogeneous Iso/low signal, variable signal with hemorrhage T2: Heterogeneous Iso/high signal Heterogeneous enhancement
<b>Ewing's Sarcoma</b>	Younger patients, nonspecific pain, lower extremities and pelvis	Variable, laminated periosteal reaction (onion skinning), sclerosis	T1: Iso/mild hyperintense signal T2: Heterogeneous hyperintense with possible low signal striations (hair on end) Heterogeneous prominent enhancement
<b>Osteosarcoma</b>	Primary: younger patients, metadiaphysis of long bones Secondary: elderly, wide distribution, multiple associated conditions (ex. Paget's, bone infarct, prior radiation etc....)	Aggressive osseous lesion, wide zone of transition, elevation of periosteum (Codman triangle), aggressive periosteal reaction (sunburst pattern), fluffy/cloud-like matrix	T1: Iso signal of soft tissue, low signal of mineralized components, variable signal hemorrhage T2: High signal soft tissue/nonmineralized components, high signal peritumoral edema Enhancement of solid components
<b>Metastatic Carcinoma</b>	Usually follows distribution of red marrow (vertebrae, pelvis, femur, humerus etc....), characteristics may vary based on underlying malignancy	Lucent lesion, usually, typically less periosteal reaction than primary bone tumor	T1: Variable low signal T2: Variable high signal Variable enhancement

**Table 2:** Differential diagnosis table for undifferentiated pleomorphic sarcoma of bone to radiographic mimics.

**ABBREVIATIONS**

CT = Computed Tomography  
M-CSF = Macrophage Colony Stimulating Factor  
MFH = Malignant Fibrous Histiocytoma  
MRI = Magnetic Resonance Imaging  
OL-EDA-ID = Osteopetrosis associated with Lymphedema, Ectodermal Dysplasia, And Immunodeficiency Syndrome  
OSTM1 = Osteopetrosis associated Transmembrane Protein 1  
STIR = Short-tau inversion recovery  
UPS = Undifferentiated Pleomorphic Sarcoma

**KEYWORDS**

bone scintigraphy; humerus; malignant fibrous histiocytoma; osteopetrosis; undifferentiated pleomorphic sarcoma of bone

**Online access**

This publication is online available at:  
[www.radiologycases.com/index.php/radiologycases/article/view/3920](http://www.radiologycases.com/index.php/radiologycases/article/view/3920)

**Peer discussion**

Discuss this manuscript in our protected discussion forum at:  
[www.radiopolis.com/forums/JRCR](http://www.radiopolis.com/forums/JRCR)

**Interactivity**

This publication is available as an interactive article with scroll, window/level, magnify and more features.  
Available online at [www.RadiologyCases.com](http://www.RadiologyCases.com)

Published by EduRad



[www.EduRad.org](http://www.EduRad.org)