

Opposite cerebral dominance for reading and sign language

Sirisha. T. Komakula^{1*}, Robert. B. Burr², James N. Lee¹, Jeffrey Anderson¹

1. University of Utah, Department of Neuroradiology, Salt Lake City, UT, USA

2. University of Utah, Pediatric Behavioral Health, Salt Lake City, UT, USA

* **Correspondence:** Sirisha. T. Komakula, University of Utah, Department of Neuroradiology, 30N 1900 E, #1A071, Salt Lake City, UT 84132-2101, USA

(✉ sirisha.komakula@hsc.utah.edu)

Radiology Case. 2010 Mar; 4(3):11-14 :: DOI: 10.3941/jrcr.v4i3.364

ABSTRACT

We present a case of right hemispheric dominance for sign language but left hemispheric dominance for reading, in a left-handed deaf patient with epilepsy and left mesial temporal sclerosis. Atypical language laterality for ASL was determined by preoperative fMRI, and congruent with ASL modified WADA testing. We conclude that reading and sign language can have crossed dominance and preoperative fMRI evaluation of deaf patients should include both reading and sign language evaluations.

CASE REPORT

CASE REPORT

Clinical History

A 15-year-old left-handed patient with refractory seizures and deafness was referred for preoperative mapping. The patient was developmentally normal until an episode of spinal meningitis and febrile seizures at age 15 months. Because of the ensuing deafness, she never regained oral speech and learned ASL. Current seizure frequency was estimated at two to three events per week. Video EEG monitoring did not show an electrophysiological seizure focus. Structural MR imaging revealed left mesial temporal sclerosis.

fMRI Data Acquisition and Processing

Scanning was performed on a Siemens 3T Trio MR scanner with a 12-channel head coil using block design paradigms with alternating 20 sec on/off epochs. Visual stimuli for ASL activation tasks were presented via video of an ASL translator played on a projection screen in the bore of the scanner. This was viewed through a mirror mounted on top of the head coil. fMRI BOLD EPI sequence was used (field-of-view 22 cm, matrix 64 x 64, repetition time 2.44 s, echo

time=30 ms, slice thickness 3 mm with 10% gap, flip angle 80 degrees). Anatomic T1-weighted images were acquired using an MPRAGE sequence (field-of-view 22 cm, matrix 192 x 192, TR=1.4 s, TE=2.15 ms, inversion time 1.1 s, slice thickness 2 mm, flip angle 8 degrees).

Preprocessing and statistical analysis were carried out with SPM5 software (Wellcome Trust, London) with correction for motion and distortion (realign and unwarp) with separately obtained field map. The mean realigned EPI image was co registered with the anatomic image. EPI images were smoothed using isotropic 6 mm Gaussian kernels and statistically analyzed using a general linear model. Activation maps were thresholded at $p=0.05$ after familywise error correction.

fMRI Paradigms

Passive story watching (ASL): The patient was shown a videotaped sign language presentation of a story in 20 second blocks alternating with 20 second blocks of a motionless interpreter, and encouraged to remember details of the story. There was activation in the right greater than left posterior superior and middle temporal gyri and temporoparietal

junction (Wernicke's area). Right activation also included the primary auditory cortex (Figure 1; peak t-values: left Wernicke's $t=10.22$, right Wernicke's $t=10.56$, right auditory cortex $t=12.76$).

Object/Action description (ASL): The patient was shown a videotape of the sign language interpreter signing representations of questions or phrases and instructed to respond by silently thinking of the answer. There was right greater than left activation of Wernicke's area with recruitment of the right primary auditory cortex (Figure 2; peak t values: left Wernicke's $t=8.01$, right Wernicke's $t=13.57$, right auditory cortex $t=12.4$).

Sentence completion (Reading): The patient was shown written sentences with one missing word (e.g. "She put dishes in the ____"). She was instructed to read as many words in the sentences as she was able and complete the sentence in her mind. Control blocks consisted of a central fixation crosshair. Activation occurred in left Wernicke's area with minimal activation of the right primary auditory cortex (Figure 3; peak t-values: left Wernicke's $t=8.42$, right auditory cortex $t=7.82$). Visual cortex activation was seen in the bilateral inferior occipital lobes (Figure 4; peak t-values: left Wernicke's $t=8.42$, right auditory cortex $t=7.82$). No significant activation was seen of inferior frontal gyrus (Broca's area).

DISCUSSION

Atypical or RH language dominance is often observed in patients with early cortical injury during the language formative period suggesting that early injury may affect the normal development of language lateralization (1-3). Reports of varying hemispheric recruitment as well as language recovery after left lesion resection suggest reorganization of language networks related to cerebral plasticity after injury (4-6). Typically on fMRI, functional activation to reading is observed in the visual cortex, lateral occipital cortex, Wernicke's area, Broca's area, and the lateral premotor cortex of the dominant hemisphere. We present a case of RH dominance for sign language but LH dominance for reading. Such crossed cerebral dominance demonstrates the need to include sign language tasks in preoperative fMRI or WADA language mapping in deaf subjects.

Lesional studies have shown that LH lesions give rise to sign language aphasia in deaf signers whereas RH lesions do not (7, 8). Although there is some evidence that the RH may play a role in language systems like the ASL which rely on visiospatial processing, there is debate in the literature regarding the extent of this contribution (7, 8). On the whole, it is generally believed that the patterns for brain localization for deaf native signers processing sign language are very similar to those for spoken language processing in hearing native speakers. A case of sign language aphasia following RH damage in a left-handed subject may indicate that RH dominance for ASL is more likely common in left-handed individuals, just as one finds in the hearing population (9). Atypical laterality has also been observed in patients with autism and schizophrenia (10, 11, 12).

Radiology Case. 2010 Mar; 4(3):11-14

Previous studies with hearing native speakers, deaf native signers and hearing native signers (hearing children of deaf patients who learned ASL as a native language), have demonstrated that classical language areas within the left hemisphere were recruited by both English in native speakers and ASL in native signers, supporting lesion data (13, 14). Nevertheless, this study also presented extensive RH recruitment with ASL in both deaf and hearing native signers.

In our patient there was dominant activation of right Wernicke's area with a much smaller spatial extent of left-sided activation for ASL tasks and left lateralization for reading. Recruitment of the right primary auditory cortex for receptive speech also suggests cerebral plasticity after injury. The fMRI RH dominance for sign language in our case was also congruent with ASL modified WADA test. Using an ASL interpreter, she was asked to copy/repeat specific signs, name objects and follow commands; all in ASL. Results indicated RH dominance for ASL with some left participation, and suggest cortical reorganization related to early childhood illness and left-sided cortical injury.

It should be noted that existing data on hemispheric dominance patterns for language in left handed subjects have come from studies of normally hearing speaking individuals (15, 16). Further research in larger groups of atypically dominant patients is required to understand the conditions and variability of hemispheric dominance for language in these populations.

TEACHING POINT

Although language dominance in sign language patients is typically ipsilateral to that for reading, it is possible that sign language and reading functions can have crossed dominance. This is particularly true for patients with deafness arising from early injury and cortical reorganization should be suspected in patients with injury during the language formative period.

REFERENCES

1. Pataraiia E, Simos PG, Castillo EM, et al. Reorganization of language-specific cortex in patients with lesions or mesial temporal epilepsy. *Neurology* 2004;63:1825-1832.
2. Staudt M, Lidzba K, Grodd W, Wildgruber D, Erb M, Krageloh-Mann I. Right-hemispheric organization of language following early left-sided brain lesions: functional MRI topography. *Neuroimage* 2002;16:954-967.
3. Springer JA, Binder JR, Hammeke TA, et al. Language dominance in neurologically normal and epilepsy subjects: a functional MRI study. *Brain* 1999;122 (Pt 11):2033-2046.
4. Adcock JE, Wise RG, Oxbury JM, Oxbury SM, Matthews PM. Quantitative fMRI assessment of the differences in lateralization of language-related brain activation in patients with temporal lobe epilepsy. *Neuroimage* 2003;18:423-438.

5. Voets NL, Adcock JE, Flitney DE, et al. Distinct right frontal lobe activation in language processing following left hemisphere injury. *Brain* 2006;129:754-766.

6. Helmstaedter C, Fritz NE, Gonzalez Perez PA, Elger CE, Weber B. Shift-back of right into left hemisphere language dominance after control of epileptic seizures: evidence for epilepsy driven functional cerebral organization. *Epilepsy Res* 2006;70:257-262.

7. Hickok G, Love-Geffen T, Klima ES. Role of the left hemisphere in sign language comprehension. *Brain Lang* 2002;82:167-178.

8. Campbell R, MacSweeney M, Waters D. Sign language and the brain: a review. *J Deaf Stud Deaf Educ* 2008;13:3-20.

9. Pickell H, Klima E, Love T, Kritchevsky M, Bellugi U, Hickok G. Sign language aphasia following right hemisphere damage in a left-hander: a case of reversed cerebral dominance in a deaf signer? *Neurocase* 2005;11:194-203.

10. Dollfus S, Razafimandimby A, Delamillieure P, et al. Atypical hemispheric specialization for language in right-handed schizophrenia patients. *Biol Psychiatry*. 2005 May 1;57(9):1020-8.

11. Kleinhans NM, Müller RA, Cohen DN, et al. Atypical functional lateralization of language in autism spectrum disorders. *Brain Res*. 2008 Jul 24;1221:115-25.

12. Escalante-Mead PR, Minshew NJ, Sweeney JA. Abnormal brain lateralization in high-functioning autism. *J Autism Dev Disord*. 2003 Oct;33(5):539-43.

13. Neville HJ, Bavelier D, Corina D, et al. Cerebral organization for language in deaf and hearing subjects: biological constraints and effects of experience. *Proc Natl Acad Sci U S A* 1998;95:922-929.

14. Bavelier D, Corina D, Jezzard P, et al. Hemispheric specialization for English and ASL: left invariance-right variability. *Neuroreport* 1998;9:1537-1542.

15. Knecht S, Jansen A, Frank A, van Randenborgh J, et al. How atypical is atypical language dominance? *Neuroimage*. 2003 Apr;18(4):917-27.

16. Hécaen H, De Agostini M, Monzon-Montes A. Cerebral organization in left-handers. *Brain Lang*. 1981 Mar;12(2):261-84.

Figure 2 (right): 15-year-old female with refractory seizures and deafness. Axial fMRI (3.0 Tesla magnet, fMRI BOLD EPI sequence, TR=2.44 s, TE=30 ms; co-registered on anatomic T1 MPRAGE image, TR=1.4 s, TE= 2.15 ms) during ASL object/action description task demonstrates activation of the right (long arrow) greater than left (broad arrow) Wernicke's area and activation of the right primary auditory cortex (arrowhead).

FIGURES

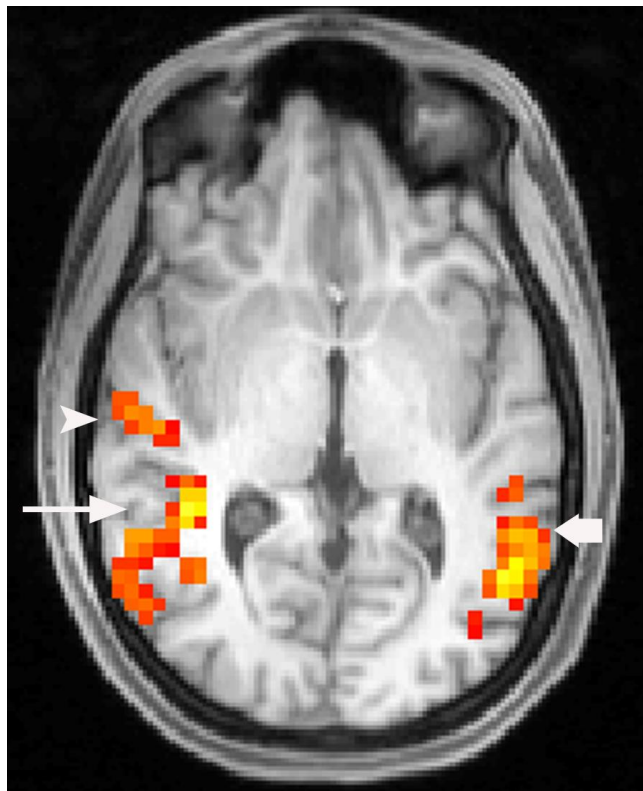
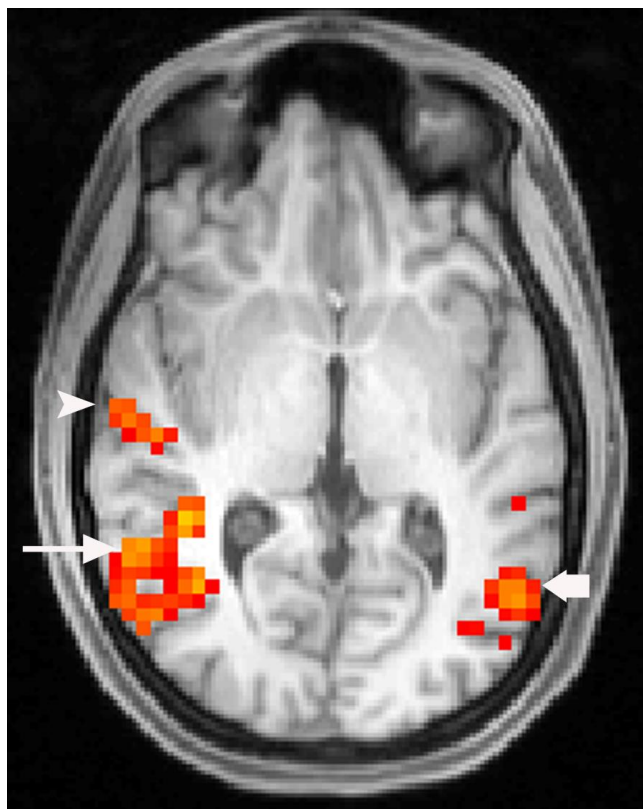


Figure 1: 15-year-old female with refractory seizures and deafness. Axial fMRI (3.0 Tesla magnet, fMRI BOLD EPI sequence, TR=2.44 s, TE=30 ms; co-registered on anatomic T1 MPRAGE image, TR=1.4 s, TE= 2.15 ms) during passive ASL story presentation demonstrates activation of the right (long arrow) greater than left (broad arrow) Wernicke's area and activation of the right primary auditory cortex (arrowhead).



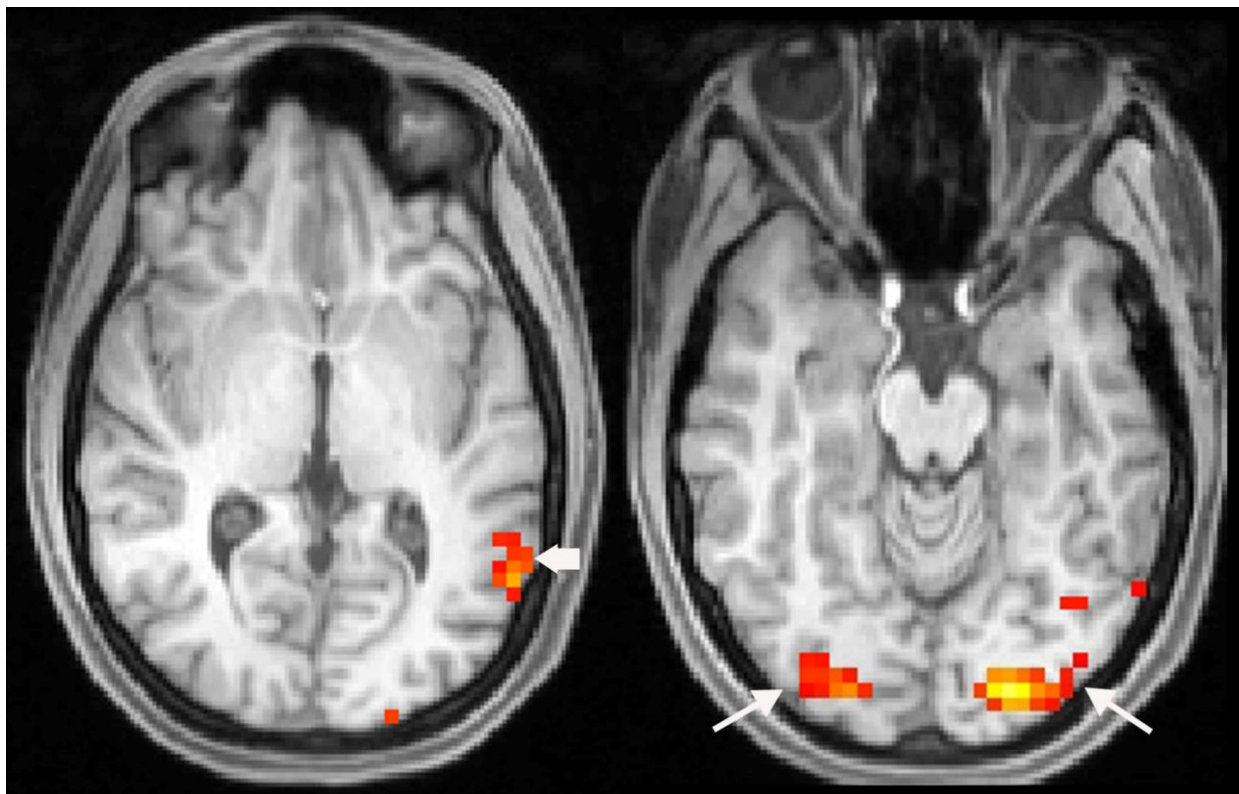


Figure 3: 15-year-old female with refractory seizures and deafness. Axial fMRI (3.0 Tesla magnet, fMRI BOLD EPI sequence, TR=2.44 s, TE=30 ms; co-registered on anatomic T1 MPRAGE image, TR=1.4 s, TE= 2.15 ms) during sentence completion (reading) task demonstrates activation of left Wernicke's area (broad arrow) with minimal activation of the right primary auditory cortex and bilateral visual cortex activation (long arrows).

ABBREVIATIONS

- ASL=American Sign Language
- fMRI=functional magnetic resonance imaging
- EEG=Electroencephalography
- BOLD=Blood Oxygen Level-Dependent
- EPI= Echo Planar Imaging
- MPRAGE=Magnetization Prepared Rapid Gradient Echo
- LH= Left hemisphere
- RH= right hemisphere

KEYWORDS

Functional magnetic resonance imaging, American Sign Language, Language dominance

Online access

This publication is online available at:
www.radiologycases.com/index.php/radiologycases/article/view/364

Interactivity

This publication is available as an interactive article with scroll, window/level, magnify and more features.
 Available online at www.RadiologyCases.com

Published by EduRad



www.EduRad.org