


# Case Report: Gastric Adenocarcinoma Metastatic to the Prostate Gland

Ping Zhang<sup>1</sup>, Yuanyi Zheng<sup>1\*</sup>, Haitao Ran<sup>1</sup>, Zhi Leng<sup>2</sup>, Zhigang Wang<sup>1</sup>

1. Department of Ultrasound, Second Affiliated Hospital of Chongqing Medical University, Chongqing, China

2. Department of Pathology, Second Affiliated Hospital of Chongqing Medical University, Chongqing, China

\* **Correspondence:** Yuanyi Zheng, M.D., Ph.D. Department of Ultrasound, Second Affiliated Hospital of Chongqing Medical University, 76 Linjiang Road, Yuzhong District, Chongqing 400010, China

 zhengyuanyi@gmail.com

Radiology Case. 2010 Mar; 4(3):35-38 :: DOI: 10.3941/jrcr.v4i3.355

## ABSTRACT

Metastasis to the prostate gland from gastric cancer is exceedingly rare. We have presented a rare case of gastric malignancy metastasizing to the prostate diagnosed by transrectal ultrasound guided prostate biopsy.

## CASE REPORT

### CASE REPORT

A 51-year-old Asian male, with a history of gastric adenocarcinoma treated with a total gastrectomy ten years prior to admission, presented with multiple episodes of urinary retention during the past one month. His physical examination was significant for only mild abdominal distension due to urinary retention. A prostate CT scan was performed with no positive findings. A transrectal ultrasound (TRUS) was performed and a hypoechoic lesion without hypervascular color Doppler signals within the peripheral zone was found (Fig. 1). A transrectal ultrasound guided prostate biopsy was performed and the histological examination revealed malignant tumor (Fig. 2), which was negative for PSA (prostatic specific antigen) (Fig. 3), P504s, Tyrosine Kinase (HCK), and P63, while was positive for mucin (Fig. 4), Ki-67 and Cerb B2.

### DISCUSSION

It is common to find metastasis of gastric cancer to many areas of the body, such as the liver, lung, but metastasis to the prostate gland from gastric cancer is exceedingly rare. Few reported cases are available in the literature (1-3).

In this case, we tested the PSA (Prostate specific antigen), P504S (a new tumor marker for diagnosing prostate cancer), P63 markers, which were useful in the differentiation diagnosis of the prostate lesions (4,5). We also tested the Ki-67 and Cerb B2 markers. These are cellular markers for proliferation, which is often correlated with the clinical course of cancer. Finally, we did the mucin immunohistochemical stain, which was positive. Mucin was reported to be a marker for gastric adenocarcinoma (6-8). Based on the patient's gastric adenocarcinoma history and the results of the immunohistochemical stain for these markers, we gave a diagnosis of "Gastric Adenocarcinoma Metastatic to the Prostate Gland".

Mechanism of spread from the stomach to the prostate gland is not certain. Secondary prostate neoplasms are typically the result of direct invasion by adjacent tissue. Malignancy of the prostate arising from nonadjacent site is very rare and infrequently diagnosed prior to death. Lymphatic spread of the gastric cancer usually affects the perigastric lymph nodes (9,10). Therefore, hematogenous route appears to be a more reasonable pathway in our case.

Transrectal ultrasound is an important tool in diagnosing prostate cancer. However, its specificity and sensitivity for the detection of prostate cancer are not high. The sonographic finding of the classic hypoechoic peripheral zone lesion has a sensitivity of cancer detection 85.5%, specificity of 28.4%,

positive predictive value of 29%, negative predictive value of 85.2% and overall accuracy of 43%. The prevalence of isoechoic or nearly invisible prostate cancers on TRUS ranges from 25~42% (11). Transrectal ultrasound guided prostate biopsy is still the most important method for the diagnosis of prostate cancer. But there were some minor risks we need to be careful. According to a report by Rodriguez LV, most patients tolerated the procedure with minimal discomfort regardless of the number and location of biopsies but younger patients had significantly more discomfort than older men. The most common complication was persistent hematuria in 47.1% of cases. Infectious complications were rare with only a 1.7% incidence of fever(12). This rate was associated with the choice of antibiotic combination used.

We have presented a rare case of gastric malignancy metastasizing to the prostate diagnosed by transrectal ultrasound guided prostate biopsy. Since the clinical imaging techniques such as CT, transabdominal ultrasound or MRI might not find lesions, and only 70% prostate cancer patients present with elevated PSA, clinicians should be aware of this unusual circumstance and transrectal ultrasound guided biopsy should be routinely considered if any suspected lesions were found in the prostate.

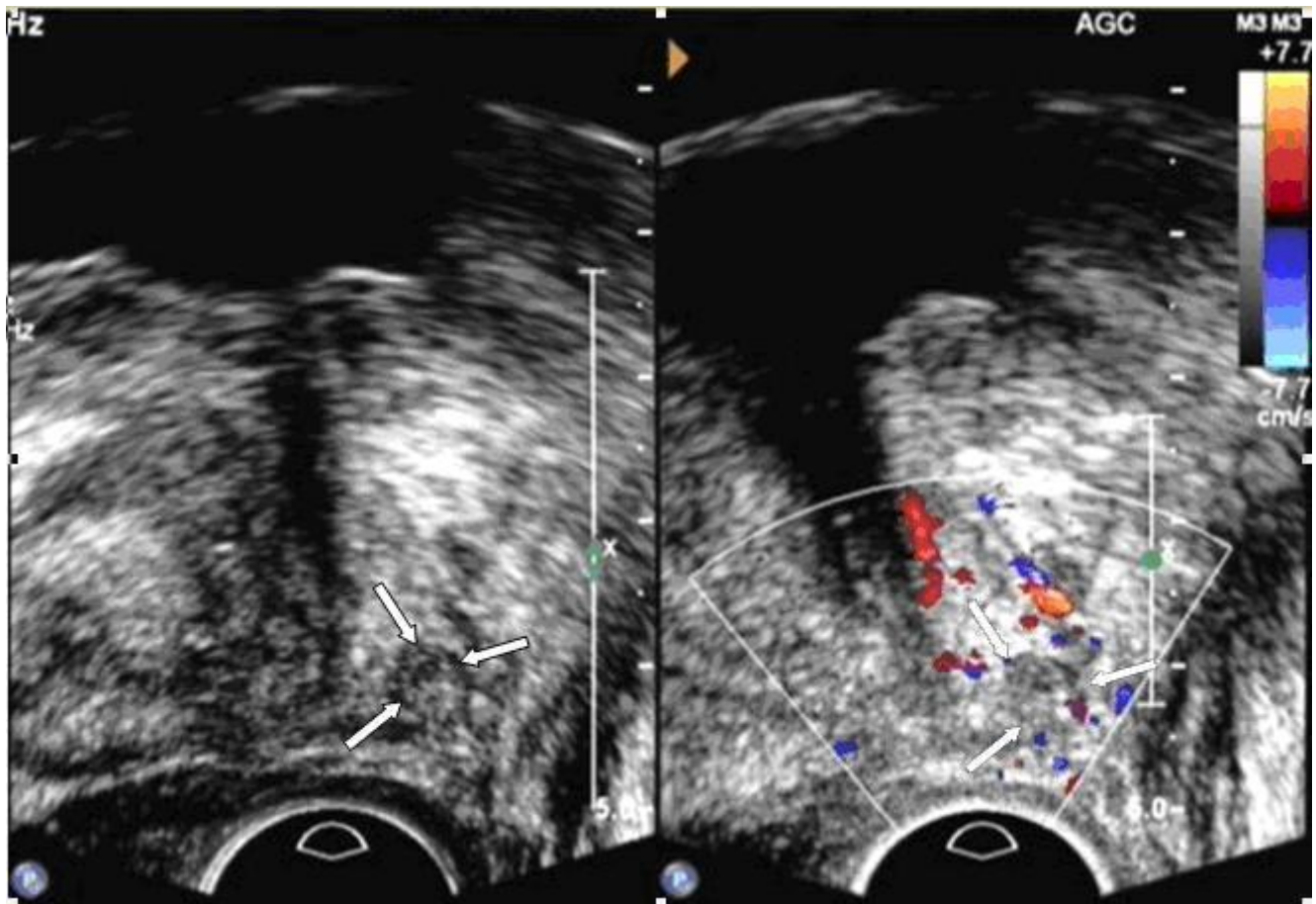
#### TEACHING POINT

Metastasis from gastric cancer to the prostate gland is exceedingly rare and transrectal ultrasound guided biopsy is important for the diagnosis.

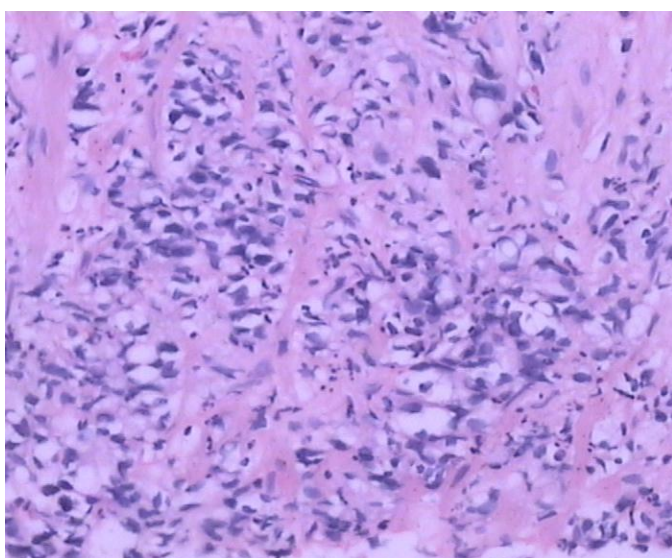
#### REFERENCES

1. Watson CJ, Doyle PT. Gastric carcinoma presenting as urinary retention. *Br J Urol* 1990;66:431.
2. Borum ML, Chen HC. Gastric adenocarcinoma metastatic to the prostate gland: A rare case and review of the literature. *Dig Dis Sci* 2001;46:2658-2659.
3. Cobo Dols M, Munoz Gallardo S, Pelaez Angulo J, Algarra Garcia R, Fuente Lupianez C, Gil Calle S, Villar Chamorro E, Montesa Pino A, Alcaide Garcia J, Ales Diaz I, Gutierrez Calderon V, Carabante Ocon F, Benavides Orgaz M. Secondary signet-ring cell tumour of the prostate derived from a primary gastric malignancy. *Clin Transl Oncol* 2005;7:409-412.
4. Molinie V, Herve JM, Lugagne PM, Baglin AC. P63 and p504s cocktail is useful in ambiguous lesions of the prostate. *Histopathology* 2004;44:403-404.
5. Tacha DE, Miller RT. Use of p63/p504s monoclonal antibody cocktail in immunohistochemical staining of prostate tissue. *Appl Immunohistochem Mol Morphol* 2004;12:75-78.
6. Mall A, McLeod H, Dent D, Hickman R. Gastric cancer mucins as clinical markers. *Gut* 1992;33:1681.
7. Tatematsu M, Iwata H, Ichinose M, Kakei N, Tsukada S, Miki K, Imai S, Imaida K. Markers of surface mucous cell type human gastric cancer cells: Galactose oxidase-schiff reactive mucins, monoclonal antibody sh-9 reactive mucins and cathepsin e. *Acta Pathol Jpn* 1993;43:500-506.
8. Gurbuz Y, Kahlke V, Kloppel G. How do gastric carcinoma classification systems relate to mucin expression patterns? An immunohistochemical analysis in a series of advanced gastric carcinomas. *Virchows Arch* 2002;440:505-511.
9. Nakajima T, Ota K, Ishihara S, Oyama S, Nishi M. Indication for the lymph node dissection of gastric cancer based on the pattern analysis small of lymphatic spread. *Gan To Kagaku Ryoho* 1994;21:1751-1757.
10. Sunderland DA, Mc NG, Ortega LG, Pearce LS. The lymphatic spread of gastric cancer. *Cancer* 1953;6:987-996.
11. Stock C, Hruza M, Cresswell J, Rassweiler JJ. Transrectal ultrasound-guided biopsy of the prostate: Development of the procedure, current clinical practice, and introduction of self-embedding as a new way of processing biopsy cores. *J Endourol* 2008;22:1321-1329.
12. Rodriguez LV, Terris MK. Risks and complications of transrectal ultrasound guided prostate needle biopsy: A prospective study and review of the literature. *J Urol* 1998;160:2115-2120.

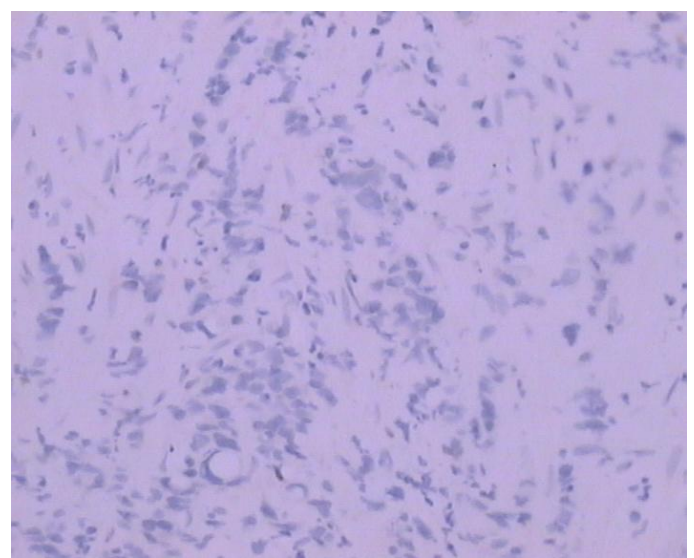
FIGURES



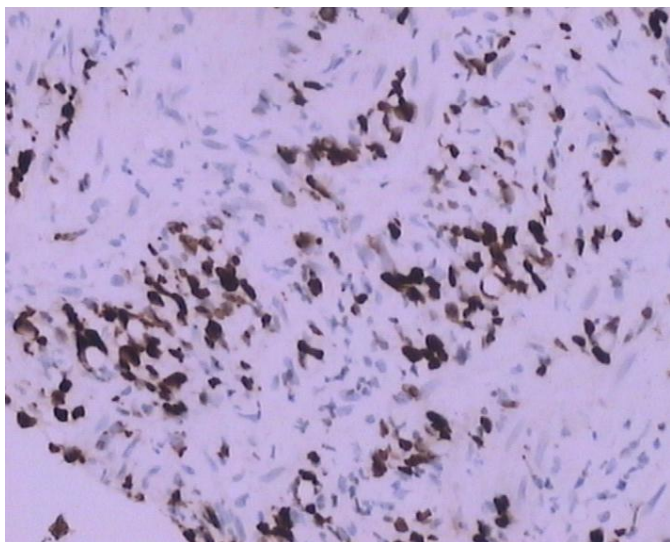
**Figure 1:** 51-year-old male with gastric adenocarcinoma metastatic to the prostate gland. Left image, white arrow depicts heterogeneous lesion (White arrows) within the peripheral zone of the prostate. Right image depicts no hypervascular area (White arrows) seen with color Doppler imaging. (Transrectal ultrasound, C9-5sec probe, 5~9MHz)



**Figure 2:** 51-year-old male with gastric adenocarcinoma metastatic to the prostate gland (HE stain, X200).



**Figure 3:** 51-year-old male with gastric adenocarcinoma metastatic to the prostate gland, which is negative for PSA (prostatic specific antigen) immunohistochemical stain. (X200).



**Figure 4:** 51-year-old male with gastric adenocarcinoma metastatic to the prostate gland, which is positive for mucin immunohistochemical stain. (X200).

Journal of Radiology Case Reports

www.RadiologyCases.com

**Online access**

This publication is online available at:  
[www.radiologycases.com/index.php/radiologycases/article/view/355](http://www.radiologycases.com/index.php/radiologycases/article/view/355)

**Interactivity**

This publication is available as an interactive article with scroll, window/level, magnify and more features.  
Available online at [www.RadiologyCases.com](http://www.RadiologyCases.com)

Published by EduRad



[www.EduRad.org](http://www.EduRad.org)

ABBREVIATIONS

CT = Computed tomography  
MRI = Magnetic resonance imaging  
PSA = Prostate specific antigen  
TRUS = Transrectal ultrasound

KEYWORDS

gastric adenocarcinoma; metastases; secondary prostatic cancer; transrectal ultrasound

ACKNOWLEDGEMENTS

This manuscript could not be finished without the help and support from Professor Chuan Liu in Urology department, Second Affiliated Hospital of Chongqing Medical University.