

# Melorheostosis of The Leg: A Case Report

Maram Alothman<sup>1\*</sup>, Layla Alkhamees<sup>2</sup>, Ahmed M Al Subaie<sup>3</sup>

1. Department of Radiology, King Faisal University, KSA

2. Medical intern, King Faisal University, KSA

3. Department of Radiology, King Fahad Hofuf Hospital, KSA

\* **Correspondence:** Maram Alothman, King Faisal University, 31982 ALAhsaa Kingdom of Saudi Arabia  
(✉ [alothman.maram@gmail.com](mailto:alothman.maram@gmail.com))

Radiology Case. 2018 Nov; 12(11):12-17 :: DOI: 10.3941/jrcr.v12i11.3539

## ABSTRACT

Melorheostosis is a benign hyperostotic disease of the peripheral skeleton, rarely involving the axial skeleton. This disease is associated with ossified and non-ossified soft tissue masses surrounding the joints. We report the case of a 28-year-old male who presented to an orthopedic clinic with a chronic history of right leg pain. Radiological evaluation using X-ray, computed tomography, and magnetic resonance imaging showed features consistent with that of melorheostosis. Recognition of this entity by clinicians can avoid unnecessary investigations and biopsy.

## CASE REPORT

### CASE REPORT

A 28-year-old male with no history of medical illness or previous trauma presented to the orthopedic clinic with mild right leg pain that persisted for 6 months. The patient described his pain as a dull-ache accompanied with a tingling sensation to touch.

The results of the clinical examination were unremarkable apart from mild tenderness and numbness extending along the anterior lateral aspect of the right leg. Vital signs were all within normal ranges, and no muscle weakness or limitation of joint mobility was observed. Lab tests, including complete blood count (CBC), erythrocyte sedimentation rate (ESR), and C-reactive protein (CRP), were normal.

For further evaluation, the patient was referred to the radiology department. Anteroposterior and lateral radiographs of the right leg were initially obtained. Results revealed sclerotic changes in the proximal two-thirds of the fibula with periosteal and endosteal cortical thickening, consistent with the characteristic “dripping wax” appearance of melorheostosis (Figure 1). Magnetic resonance imaging (MRI) and computed tomography (CT) were subsequently performed

to define the extent of pathology and to exclude associated complications. MRI results demonstrated a low signal intensity lobulated periosteal new bone formation involving the posterolateral cortex of the right fibular shaft. Clear endosteal thickening with no medullary invasion or soft tissue masses was observed (Figure 2). CT scan results showed a lobulated undulating periosteal and endosteal thickening partially encroaching the medulla, corresponding to the low signal abnormality observed on the MRI. No fracture was identified (Figure 3).

The patient was treated symptomatically; he was prescribed nonsteroidal anti-inflammatory drugs for 1 month and has been followed at the orthopedic clinic with partial improvement of symptoms.

### DISCUSSION

#### Etiology & Demographics:

Melorheostosis, also known as Leri disease and candle bone disease, is a benign hyperostotic disease [1]. It is a rare condition with an estimated prevalence of 0.9 per million [2] and affects both sexes equally [3]. The disease manifests during late childhood or early adulthood; however, it can occur

at any age [1,3]. It is a unilateral disease of the peripheral skeleton, more commonly affecting the lower extremities with a diaphyseal predilection [2]. Melorheostosis rarely affects the axial skeleton [1].

The exact etiology of melorheostosis remains unclear [1]; however, there are two major theories attempting to explain its origin. Murray and McCredie hypothesized that melorheostosis results from insult to segments of the neural crest during embryogenesis, resulting in segmental sensory lesions. This hypothesis is based on the observation that melorheostosis correlates with sclerotomes in their distribution [4]. Conversely, Fryns hypothesized that melorheostosis results from post zygotic mutations in the mesenchyme. These mutations lead to variable and asymmetric involvement of the skeletal structures, and vascular and hamartomatous changes in the overlying soft tissues [5].

Despite the increased prevalence of melorheostosis in families with autosomal dominant osteopoikilosis the disease is nonhereditary [1].

#### Clinical & Imaging findings:

Patients with melorheostosis are usually asymptomatic; however, various symptoms, including pain, limitation of movement, deformities, limb swelling, and limb length discrepancy may occur in growing children [1]. In most patients seeking medical attention, pain is usually the presenting symptom [6]. Melorheostosis may be associated with ossified and non-ossified soft tissue masses, usually surrounding the joints. The symptoms may arise due to impingement on nearby structures, either directly or through associated soft tissue masses. These masses are not necessarily a continuum of the disease lesions [1]. Clinical course may fluctuate with alternating exacerbation and remission periods [1]. Melorheostosis has been associated with various conditions, including neurofibromatosis, tuberous sclerosis, linear scleroderma, tricho-dento-osseous syndrome, rheumatoid arthritis, hypophosphatemic rickets, vascular malformations, and hemangioma [3].

The disease may extend along the affected cortex in a proximal to distal pattern, resembling the pathognomonic “dripping candle wax” appearance on an X-ray and CT scan. Other radiologic appearances include osteoma, an osteopathia striata-like appearance, and myositis ossificans-like lesions without lamellae in soft tissues [1]. CT scans show cortical thickening that might extend to the medulla, with a clear demarcation between the normal bone and the hyperostotic lesions [3,7]. Additionally, CT scans clearly depict soft tissue abnormalities associated with the disease. MRI typically shows cortical hyperostosis of low signal intensity on all pulse sequences [1]. Rarely, MRI may show enhancing soft tissue masses that resemble aggressive neoplastic lesions [8]. Melorheostosis typically show high uptake of the tracer on bone scintigraphy that crosses the adjacent joints [3].

#### Treatment & Prognosis:

Many surgical and nonsurgical treatment options exist; however, all treatment options are symptomatic rather than curative, and are directed toward the disease symptoms and complications [1]. Therapy is primarily aimed at relieving the pain and restoring full range of motion. Examples of treatment modalities include analgesia, manipulation, braces, serial casting, physiotherapy, nerve blocks, and sympathectomy [3]. Patients experiencing mechanical symptoms, such as nerve compression, contractures, impingement, and deformity should be offered surgical alternatives [6]. Symptomatic cases are eligible for surgical excision [9]; however, the recurrence of disease remains a possibility [6]. Although the condition is not fatal, it causes considerable morbidity. Melorheostosis typically has a benign course, however two case reports of malignant transformation to osteosarcoma and malignant fibrous histiocytoma have been reported in literature [15].

#### Differential Diagnoses:

Melorheostosis has to be differentiated from common differential diagnoses, including but not exclusive to myositis ossificans, osteoid osteoma, parosteal osteosarcoma, osteochondroma, and chronic osteomyelitis [7].

#### **Myositis ossificans:**

Myositis ossificans is a condition stemming from trauma or an injury. Radiographs show peripheral ossification with central lucency. The lesion is usually distant from adjacent bone. CT scans demonstrate peripheral calcification early in the disease course before it becomes evident on conventional radiographs.

MRI scans show iso- or slight hyperintensity within the lesions on T1-weighted and T2-weighted images. Diffuse or rim enhancement may also be observed [10].

#### **Osteoid osteoma:**

On radiographs, intracortical radiolucency, known as intracortical nidus, surrounded by cortical thickening can be observed. The nidus is more apparent on CT scans and may show internal calcification. On MRI, the nidus appears to have low to intermediate signal intensity on T1-weighted images and variable signal intensity on T2-weighted images. Inflammatory changes surrounding the bone marrow and soft tissues are better observed on MRI [11].

#### **Parosteal osteosarcoma:**

Plain radiographs show a mushroom-like mass with a broad base attachment protruding from the underlying cortex. The connection between the tumor and underlying bone cortex can be well visualized using CT and MRI. Periosteal reaction is commonly minimal, and the underlying bone cortex may be thickened or partially eroded. CT is the most accurate modality for evaluating the underlying cortical bone integrity, and MRI is better for demonstrating bone marrow invasion [12].

### Osteochondroma:

On radiographs, the cortex of the lesion appears to be attached to the cortex of underlying bone, and the medullary cavity of the lesion is continuous with the medullary cavity of the underlying bone. In addition, the lesion is capped with cartilage. In comparison with radiographs, CT scans delineate the connection between the cortex and the medullary cavity of the lesion with the original bone in a better manner than radiographs. The best modality for measuring cartilage cap thickness is MRI because it shows high signal intensity on T2-weighted images [13].

### Chronic osteomyelitis:

In chronic osteomyelitis, a sequestrum is frequently visible on radiographs as focal sclerosis surrounded by a lucent rim. In some cases, the sequestrum becomes encased in a thick sheath of new bone known as an involucrum. The bone cortex may appear to be destructed. These findings are better visualized on a CT scan. MRI shows a dark sequestrum in all sequences surrounded by hypervascular granulation tissue with post-contrast peripheral enhancement. The involucrum either displays a normal signal or edema. A defect, known as cloaca, connecting the medulla to the surrounding soft tissues may be visualized. Draining pus within the cloaca displays high signal [14].

### TEACHING POINT

Melorheostosis is a rare, often asymptomatic disease; however, it warrants consideration and a clear differentiation from more deleterious abnormalities in patients presenting with chronic limb pain. Melorheostosis is characterized by classic signs on radiographs and CT such as the “dripping candle wax”. The clinician can avoid unnecessary investigations and biopsy if asymptomatic, while management depends on various particular clinical presentations or complications.

### REFERENCES

1. Suresh S, Muthukumar T, Saifuddin A. Classical and Unusual Imaging Appearances of Melorheostosis. *Clin Radiol*. 2010 Aug; 65(8):593-600. PMID: 20599060.
2. Jha S, Laucis N, Kim L, et al. CT Analysis of Anatomical Distribution of Melorheostosis Challenges the Sclerotome Hypothesis. *Bone*. 2018 Sep; 117:31-36. PMID: 30218789.
3. Sureka B, Mittal MK, Udhaya KK, et al. Melorheostosis: Two Atypical Cases. *Indian J Radiol Imaging*. 2014 Apr; 24(2):192-195. PMID: 25024532.
4. Murray RO, McCredie J. Melorheostosis and the sclerotomes: A radiological correlation. *Skeletal Radiol*. 1979 Jun; 4(2):57-71. PMID: 505048.
5. Fryns JP. Melorheostosis and Somatic Mosaicism. *Am J Med Genet*. 1995 Aug; 58(2):199. PMID: 8533816.

6. Kumar R, Sankhala SS, Bijarnia I. Melorheostosis-Case Report of Rare Disease. *Journal of Orthopaedic Case Reports*. 2014 Apr-Jun; 4(2): 25-27. PMID: 27298954.

7. Elsheikh AA, Pinto RS, Mistry A, et al. A Unique Case of Melorheostosis Presenting with Two Radiologically Distinct Lesions in the Shoulder. *Case reports in orthopedics*. 2017:9307259. PMID:29234550.

8. Ashish G, Shashikant J, Ajay P, et al. Melorheostosis of the Foot: A Case Report of A rare entity with a Review of Multimodality Imaging Emphasizing the Importance of Conventional Radiography in Diagnosis. *Journal of Orthopaedic Case Reports*. 2016 Jan-Mar; 6(1): 79-81. PMID: 27299136.

9. Semionov A, Jaffer R, Kosiuk J. (2018). Melorheostosis of a rib. *Radiology Case Reports*. 2018 Jul; 13(4):886-889. PMID:29997717.

10. Lacout A, Jarraya M, Marcy PY, et al. Myositis ossificans imaging: keys to successful diagnosis. *The Indian Journal of Radiology & Imaging*. 2012 Jan; 22(1):35-39. PMID:22623814.

11. Chai J, Hong S, Choi J, et al. Radiologic Diagnosis of Osteoid Osteoma: From Simple to Challenging Findings. *RadioGraphics*. 2010 May; 30(3):737-749. PMID:20462991.

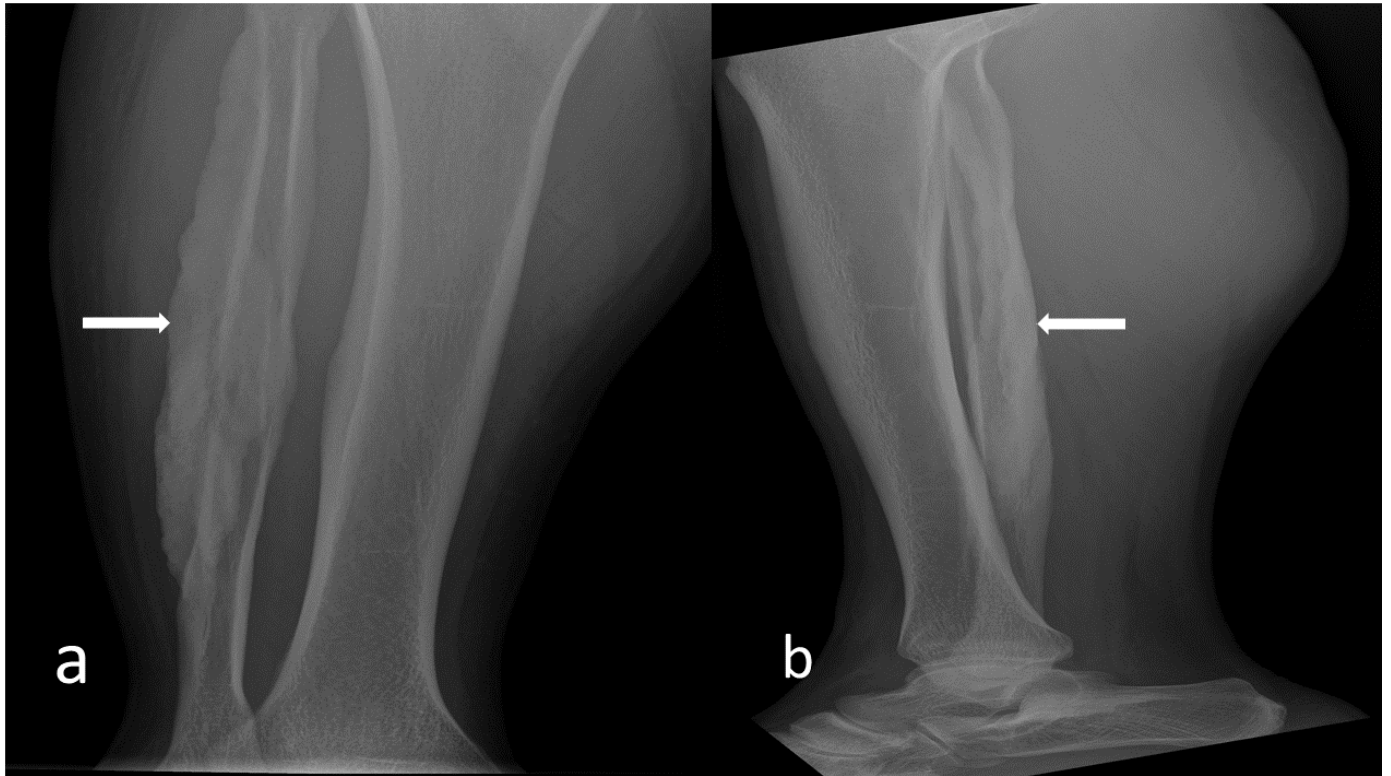12. Hang J, and Chen P. Parosteal Osteosarcoma. *Arch Pathol Lab Med*. 2014 May; 138:694-699. PMID:24786129.

13. Murphey MD, Choi JJ, Kransdorf MJ, et al. Imaging of Osteochondroma: Variants and Complications with Radiologic-Pathologic Correlation. *RadioGraphics*. 2000 Sep-Oct; 20(5):1407-1434. PMID:10992031.

14. Lee YJ, Sadigh S, Mankad K, et al. The Imaging of Osteomyelitis. *Quantitative Imaging in Medicine and Surgery*. 2016 Apr; 6(2), 184-198. PMID: 27190771.

15. Kotwal A, Clarke BL. Melorheostosis: a Rare Sclerosing Bone Dysplasia. *Curr Osteoporosis Rep*. 2017 Aug;15(4):335-342. PMID: 28676968.

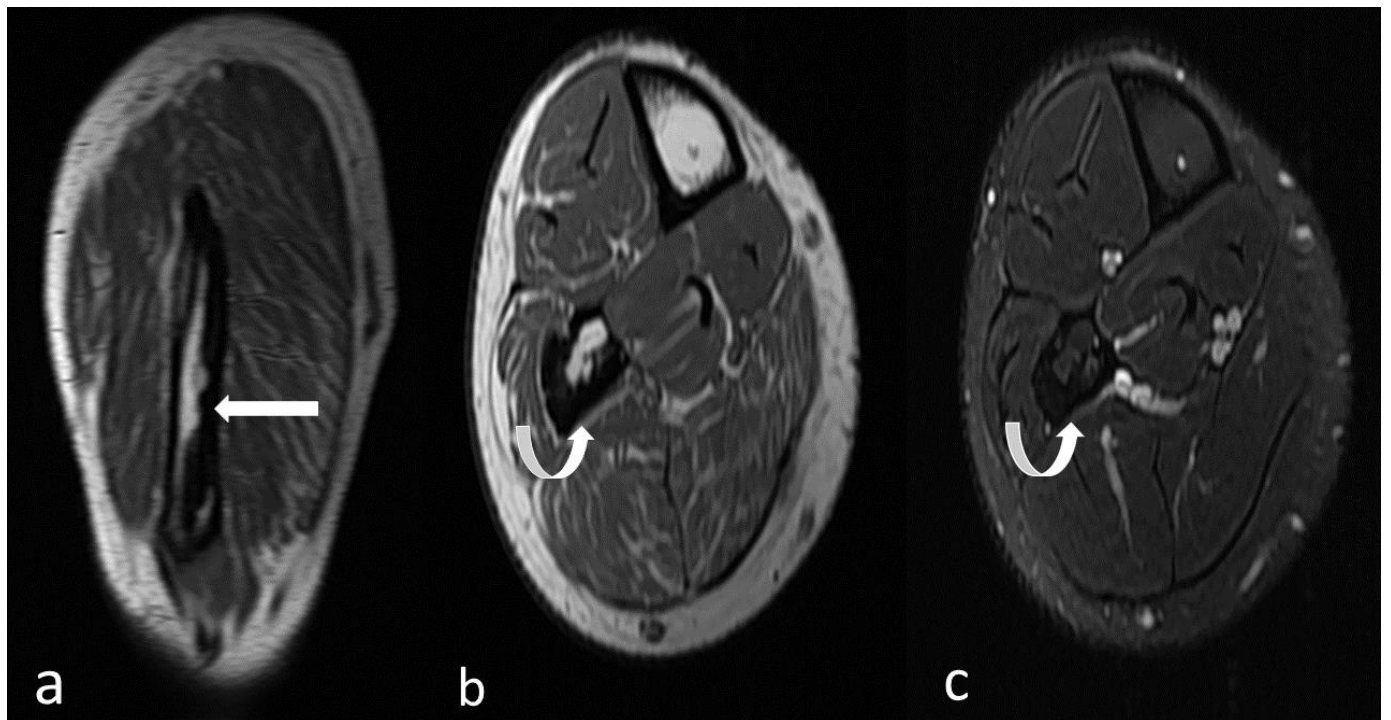
FIGURES



**Figure 1:** 28-year-old male with melorheostosis.

Findings: (a, b) Anteroposterior and lateral radiographs of the right leg show sclerosis on the posterior lateral aspect of the proximal two-thirds of the fibula with periosteal and endosteal cortical thickening, consistent with the classic dripping wax appearance (arrows).

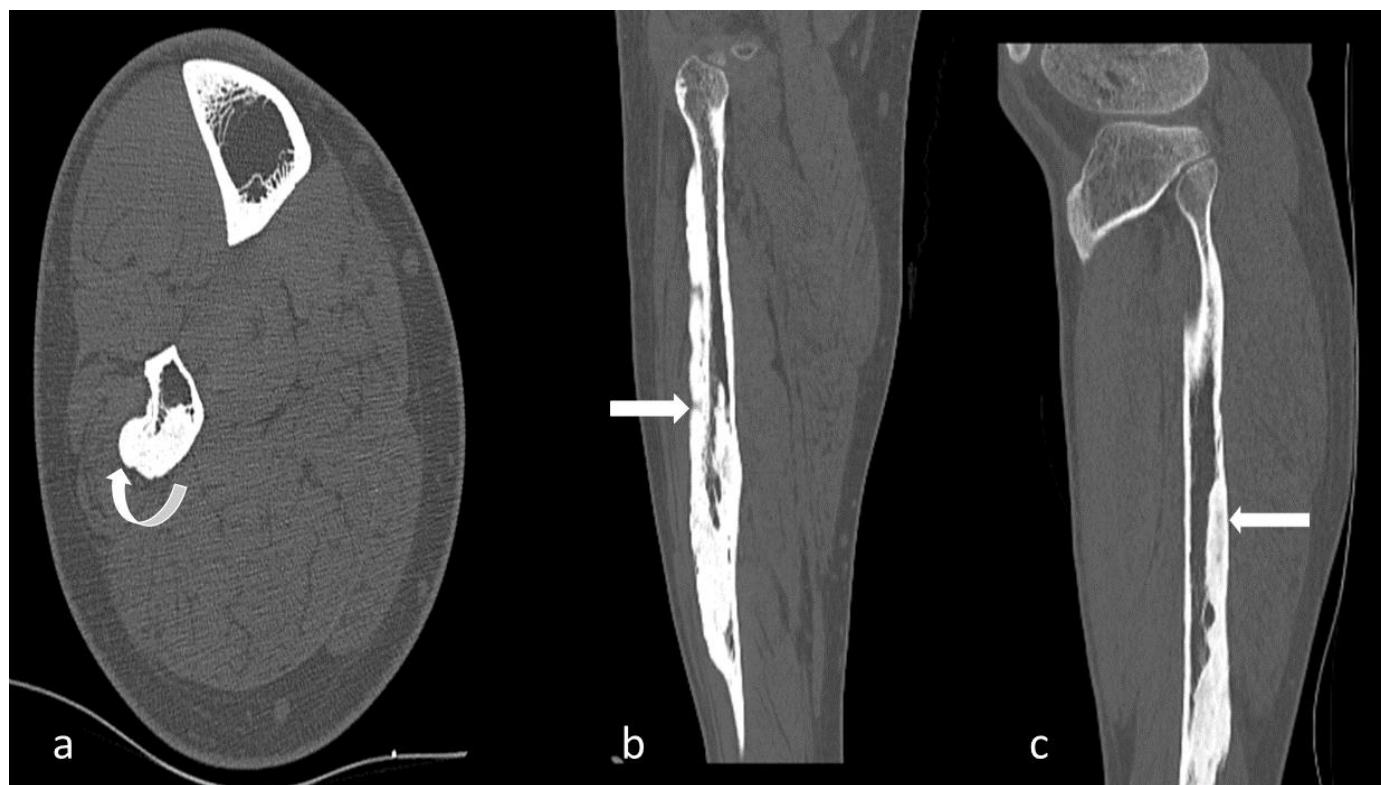Technique: X-ray of tibia/fibula, kVp 45, mAs 4.



**Figure 2:** 28-year-old male with melorheostosis.

Findings: Sagittal T1-weighted (Figure 2a), axial T1-weighted (Figure 2b), axial T2-weighted with fat suppression (Figure 2c). MRI demonstrates low signal intensity lobulated periosteal new bone formation involving the posterolateral cortex of the right fibular shaft (arrows). Clear endosteal thickening is best observed on axial images (Figure 2b-c). No medullary invasion or soft tissue masses were evident.

Technique: MRI right leg without contrast (GE 1.5T Signa)



**Figure 3:** 28-year-old male with melorheostosis.

Findings: Selected axial (Figure 3a) with reconstructed coronal (Figure 3b) and sagittal (Figure 3c) images of a non-contrast computed tomography of the leg show lobulated undulating periosteal and endosteal thickening partially encroaching the medulla, corresponding to MRI low signal abnormality (arrows). No fractures are evident.

Technique: MDCT (GE Discovery CT750 HD), 120 KVP, 149 mA, 0.6-mm slice thickness.

www.RadiologyCases.com

Items	Melorheostosis
<b>Etiology</b>	Unknown
<b>Prevalence</b>	0.9 per million
<b>Sex ratio</b>	Male to Female 1:1
<b>Age predilection</b>	It can occur at any age; however, is most prevalent in late childhood to early adulthood
<b>Risk factors</b>	No identified risk factors
<b>Treatment</b>	Symptomatic
<b>Prognosis</b>	Non-fatal disease with considerable morbidity
<b>Findings on imaging</b>	X-ray: candlewax appearance CT scan: candlewax appearance with high density cortical thickening MRI: cortical hyperostosis of low signal intensity on all pulse sequences.

**Table 1:** Summary table of melorheostosis.



	<b>Radiographs</b>	<b>CT scan</b>	<b>MRI</b>
<b>Melorheostosis</b>	Classic dripping candlewax appearance	Candlewax appearance with high attenuation cortical thickening	Cortical hyperostosis of low signal intensity on all pulse sequences
<b>Myositis ossificans</b>	Peripheral ossification with central lucency and clear demarcating line between the lesion and normal bone	Peripheral calcification of the lesion becomes evident earlier on CT than on conventional radiographs	Iso- or slight hyperintensity on T1W and T2W images, respectively; diffuse or rim enhancement may also be observed
<b>Osteoid osteoma</b>	Intracortical nidus surrounded by cortical thickening	The nidus is more apparent on CT than radiographs with low or high attenuation	The nidus appears to have low to intermediate signal intensity on T1W images and variable signal intensity on T2W images
<b>Parosteal osteosarcoma</b>	Mushroom-like mass with a broad base attachment protruding from the underlying cortex	CT is most accurate for evaluating the cortical integrity	MRI is better for demonstrating bone marrow invasion
<b>Osteochondroma</b>	The cortex and medullary cavity of the lesion appear to be continuous with the cortex and medullary cavity of the underlying bone	CT can clearly delineate the connection between the cortex and medullary cavity of the lesion	MRI is the best modality for measuring the cartilage cap thickness because it shows high signal intensity on T2W images
<b>Chronic osteomyelitis</b>	Usually shows focal sclerosis surrounded by a lucent rim, known as a sequestrum; it also shows the involucrum that surrounds the sequestrum	The findings in conventional radiographs are better visualized by CT scan	MRI shows a dark sequestrum in all sequences surrounded by hypervascular granulation tissue with post-contrast peripheral enhancement; cloaca may be visualized; draining pus within the cloaca displays a high signal

**Table 2:** Differential diagnoses table for melorheostosis.

#### ABBREVIATIONS

AP = Anterior posterior  
 CBC = complete blood count  
 CRP = C-reactive protein  
 CT = computed tomography  
 ESR = erythrocyte sedimentation rate  
 KVp = Peak Kilovolt  
 mAs = milliamperere seconds  
 MDCT = Multidetector computed tomography  
 mm = millimeter  
 MRI = magnetic resonance imaging  
 T1W = T1-weighted  
 T2W = T2-weighted

#### KEYWORDS

Melorheostosis; Leri disease; Candle bone disease; Fibula; Magnetic resonance imaging; MRI

#### Online access

This publication is online available at:  
[www.radiologycases.com/index.php/radiologycases/article/view/3539](http://www.radiologycases.com/index.php/radiologycases/article/view/3539)

#### Peer discussion

Discuss this manuscript in our protected discussion forum at:  
[www.radiolopolis.com/forums/JRCR](http://www.radiolopolis.com/forums/JRCR)

#### Interactivity

This publication is available as an interactive article with scroll, window/level, magnify and more features.  
 Available online at [www.RadiologyCases.com](http://www.RadiologyCases.com)

Published by EduRad



[www.EduRad.org](http://www.EduRad.org)