

# Accidental Concentrated Hydrogen Peroxide Ingestion Associated with Portal Venous Gas

Eslam W Youssef<sup>1,2\*</sup>, Victor S Chukwueke<sup>3</sup>, Lina Elsamaloty<sup>3</sup>, Sherif Moawad<sup>1,2</sup>, Haitham Elsamaloty<sup>1</sup>

1. Department of Diagnostic Radiology, the University of Toledo Medical Center, Ohio, USA

2. Department of Diagnostic and Interventional Radiology, Cairo University, Cairo, Egypt

3. The University of Toledo Medical Center, Ohio, USA

\* **Correspondence:** Eslam W. Youssef, MD, MSc, Department of Diagnostic Radiology, the University of Toledo Medical Center, 3000 Arlington Ave, Toledo, Ohio 43614, USA  
(✉ [Eslam.youssef@utoledo.edu](mailto:Eslam.youssef@utoledo.edu))

Radiology Case. 2018 Aug; 12(8):12-16 :: DOI: 10.3941/jrcr.v12i8.3253

## ABSTRACT

A case of a 52-year old male patient who presented to the emergency department with severe nausea and vomiting following accidental ingestion of H<sub>2</sub>O<sub>2</sub>. A computed tomography (CT) abdomen performed at our institution demonstrated extensive portal venous gas throughout the liver with few gas droplets seen in the extrahepatic portal vein portion. Pneumatosis was also noted in the wall of the gastric antrum. Upper GI Endoscopy was done revealing diffuse hemorrhagic gastritis and mild duodenal bulb erosion. The patient was treated with hyperbaric oxygen. On the second day of admission, the patient was able to eat without difficulty or pain. Accidental ingestion of high concentration H<sub>2</sub>O<sub>2</sub> solution has been shown to cause extensive injury to surrounding tissues. The injury occurs via three main mechanisms: corrosive damage, oxygen gas formation, and lipid peroxidation. We report a case of accidental ingestion of a highly concentrated (35%) solution of H<sub>2</sub>O<sub>2</sub> causing portal venous gas.

## CASE REPORT

### CASE REPORT

We present a case of a 52-year old male patient with a past medical history of GERD, who presented to the emergency department at our institution with severe nausea and vomiting after accidental ingestion of H<sub>2</sub>O<sub>2</sub>. The patient ingested a highly concentrated (35%) solution of H<sub>2</sub>O<sub>2</sub>, thinking it was water, after a family member mistakenly placed a water jar filled with hydrogen peroxide in the fridge.

Following ingestion, the patient had 6-7 attacks of non-bloody vomiting. In an attempt to relieve the intense burning sensation, the patient drank 2 glasses of milk before coming to the hospital.

A CT of the abdomen and pelvis was performed, approximately 4 hours after ingestion, and showed extensive portal venous gas throughout the whole liver (Figure 1, 3 & 4), with 2-3 droplets visualized in the extrahepatic portion of the portal vein. Pneumatosis was also noted in the wall of the gastric antrum (Figure 2). Upper endoscopy revealed diffuse hemorrhagic gastritis, mild duodenal bulb erosion, and an unremarkable esophagus (Figure 3).

The neurological examination was normal and magnetic resonance imaging (MRI) of the brain did not show evidence of intravascular cerebral air or infarction.

The patient was treated with hyperbaric oxygen with marked improvement of symptoms. On the second day of

admission, the patient was able to tolerate a liquid diet well and was discharged home.

## DISCUSSION

### Etiology & Demographics:

H<sub>2</sub>O<sub>2</sub> is a colorless, odorless oxidizing agent used in many household products, including general-purpose disinfectants and chlorine-free bleaches. It is easily purchased, even in concentration, in health food stores for various uses [1]. Because of its colorless and odorless characteristics, H<sub>2</sub>O<sub>2</sub> can easily be confused with water, especially when stored inappropriately; hence increasing the probability of accidental ingestion.

3% solutions are used as common household disinfectants, and are therefore a common source of accidental poisonings, especially in children. In one study of more than 95,000 toxic exposures reported to a poison control center over three years, 0.34% were due to hydrogen peroxide and of these, 60% occurred in children younger than six years of age, and 85% occurred through ingestion [2].

Other causes of portal and/or systemic venous gas include intestinal ischemia, necrotizing enterocolitis, sepsis, and trauma. Risk factors include bowel distension and infection.

### Clinical & imaging findings

H<sub>2</sub>O<sub>2</sub> causes health issues via three main mechanisms: corrosive damage, oxygen gas formation, and lipid peroxidation [3]. While ingestion of diluted solution (3%) of H<sub>2</sub>O<sub>2</sub> is mostly asymptomatic or with minimal symptoms, exposure to higher concentration (>35%) is caustic and likely to cause tissue damage requiring medical attention. The irritation and direct cytotoxic injury from lipid peroxidation of cell membranes leads to hemorrhagic injury and inflammation of the skin and mucosa of the oropharyngeal, gastrointestinal, and pulmonary tissues.

Ingestion of concentrated H<sub>2</sub>O<sub>2</sub> can result in the generation of large volumes of oxygen. When oxygen levels exceed their maximum solubility in blood, venous or arterial gas emboli may result. The rapid generation of oxygen in closed body cavities can cause mechanical distension with potential risk for hollow viscus rupture secondary to oxygen liberation. Painful gastric distension and belching may be caused by the liberation of large volumes of oxygen in the stomach. Injury to the mucosae and oropharyngeal burns are usually common following ingestion of concentrated solutions. Also, laryngospasm and hemorrhagic gastritis have been reported. Moreover, sinus tachycardia, lethargy, coma, confusion, convulsions, sub-epiglottic narrowing, and stridor may ensue within minutes of ingestion [3].

Endoscopy has a diagnostic and therapeutic function in cases of H<sub>2</sub>O<sub>2</sub> ingestion. The depth and extent of injury can be assessed by endoscopy. Most patients with grade 3 burns develop stricture formation, while one-third of patients with grade 2 develop pyloric stenosis, acid regurgitation, and perforation [4].

CT is the most sensitive imaging modality to diagnose portal and systemic venous gas as a complication of H<sub>2</sub>O<sub>2</sub> ingestion. Portal vein gas appears as branching air densities following portal vein distribution in a more peripheral fashion in the liver. X-Ray has also some diagnostic value and might show branching lucencies at the presumed site of the liver. Ultrasound (US) shows echogenic foci at the periphery of the liver.

### Treatment & prognosis

Treatment of H<sub>2</sub>O<sub>2</sub> ingestion depends on the concentration of H<sub>2</sub>O<sub>2</sub>, as well as the degree and extent of injury. Treatment options are conservative, surgical, and/or hyperbaric oxygen. Diluted H<sub>2</sub>O<sub>2</sub> ingestion without significant symptoms usually resolves spontaneously [5]. For esophageal and gastric symptoms antacids (proton pump inhibitors and H<sub>2</sub> antagonists) are used. Additionally, nasogastric irrigation can be used and is the treatment of choice to reduce many symptoms and complications [5].

In the literature, patients who developed serious neurologic symptoms like somnolence, epileptic seizures, and hemiparesis, as a result of systemic gas emboli, were successfully treated with hyperbaric oxygen therapy [6].

Activated charcoal has not been shown to absorb hydrogen peroxide and interferes with endoscopy visualization. [7].

Gastric lavage is useful in certain circumstances to remove caustic material and prepare for endoscopic examination. Gastric lavage can be considered if: (1) a large dose of H<sub>2</sub>O<sub>2</sub> has been ingested, (2) the patient has oral lesions or persistent esophageal discomfort, and (3) the lavage can be administered within 1 hour of ingestion [6].

Usually, the prognosis is related to the pathology and damage caused by the H<sub>2</sub>O<sub>2</sub> ingestion and is not affected by the presence or absence of portal venous gas emboli [8].

### Differential Diagnosis

The differential diagnosis for portal vein gas includes pneumobilia and pneumoperitoneum.

**Pneumobilia:** On CT, it appears as branching air densities with a more central distribution. On X-Ray, sword shaped lucency in the right paraspinous region (Sabre sign) is present in ~50%. On ultrasound, air causes artifact with shadowing (Stripped appearance).

**Pneumoperitoneum:** On CT, free air densities are seen within the peritoneal cavity at the interface between the visceral and parietal peritoneum. Cupola sign is the most sensitive x-ray sign. On ultrasound, the linear array transducer is more sensitive and shows enhancement of the peritoneal stripe, and maybe accompanied by artifacts or dirty shadowing.

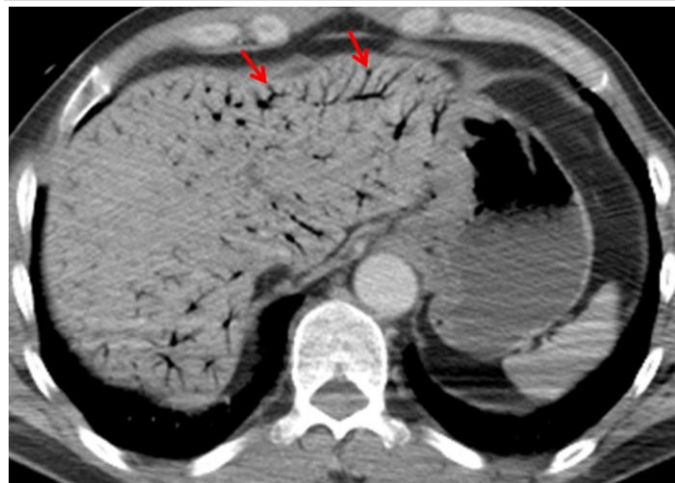
TEACHING POINT

Household use of concentrated H<sub>2</sub>O<sub>2</sub> has increased the likelihood of accidental ingestion of concentrated H<sub>2</sub>O<sub>2</sub>. Given its colorless and odorless properties, H<sub>2</sub>O<sub>2</sub> can be easily mistaken as water when inappropriately stored. As an oxidizing agent, it is caustic to the surrounding tissues upon ingestion and causes oxygen emboli formation, which appears on CT as portal and/or systemic venous gas. Hyperbaric oxygen therapy is an effective treatment. In addition to hyperbaric oxygen therapy, the patient will require a follow-up CT abdomen and pelvis.

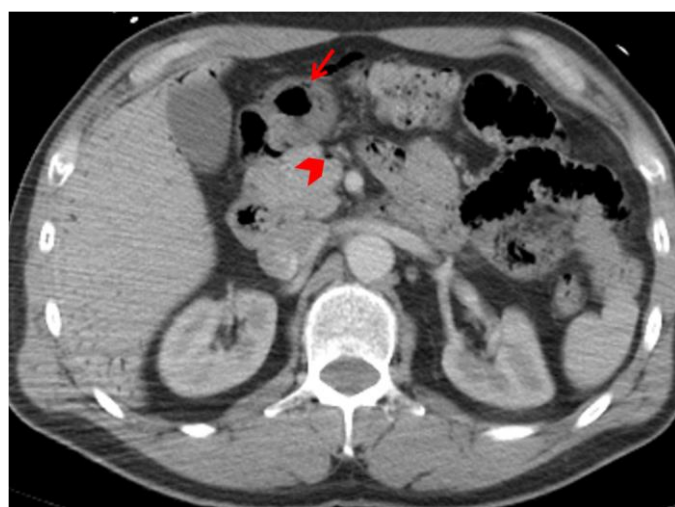REFERENCES

1. Burns RA, Schmidt SM. Portal venous gas emboli after accidental ingestion of concentrated H<sub>2</sub>O<sub>2</sub>. *J Emerg Med.* 2013 Sep; 45(3):345-7. PMID: 23664195
2. Pritchett S, Green D, Rossos P. Accidental ingestion of 35% hydrogen peroxide. *Canadian Journal of Gastroenterology.* 2007; 21(10):665-667. PMID: 17948137
3. Watt BE, Proudfoot AT, Vale JA. H<sub>2</sub>O<sub>2</sub> poisoning. *Toxicol Rev.* 2004; 23(1):51-7. PMID: 15298493
4. Zargar SA, Kochhar R, Nagi B et al. Ingestion of strong corrosive alkalis: spectrum of injury to upper gastrointestinal tract and natural history. *Am J Gastroenterol.* 1992 Mar; 87(3):337-41. PMID: 1539568
5. Zengin S, Al B, Genç S et al. A rare case of portal vein gas: accidental. *BMJ Case Reports.* 2012 May. PMID: 22669852
6. Rider SP, Jackson SB, Rusyniak DE. Cerebral air gas embolism from concentrated. *Clin Toxicol (Phila)* 2008 Nov; 46(9):815-8. PMID: 18608295
7. Agency for Toxic Substances and Disease Registry. Medical Management Guidelines for Hydrogen Peroxide 2014. <https://www.atsdr.cdc.gov/MMG/MMG.asp?id=304&tid=55>. Accessed June 2018.
8. Abboud B, El Hachem J, Yazbeck T et al. Hepatic portal venous gas: physiopathology, etiology, prognosis and treatment. *World J Gastroenterol.* 2009 Aug 7; 15(29):3585-90. PMID: 19653334

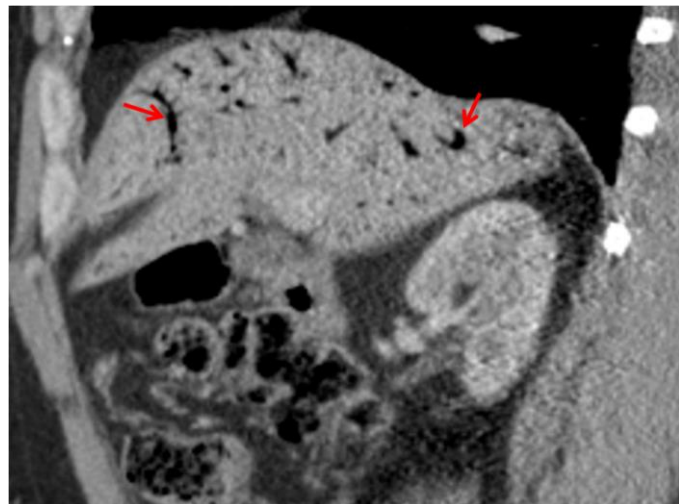
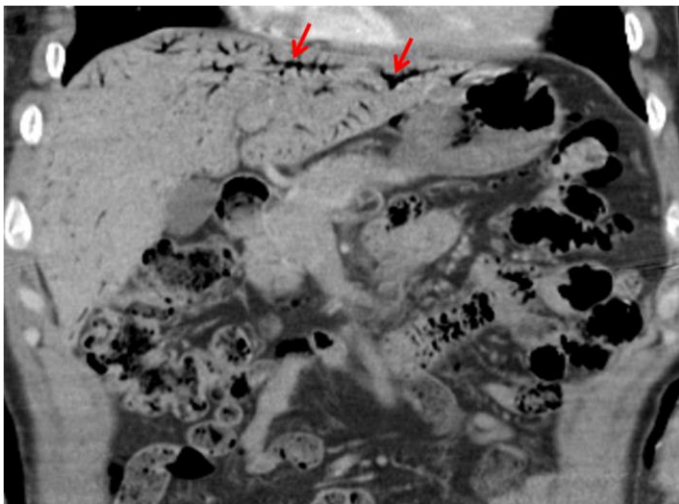
FIGURES



**Figure 1:** 52-years old male patient imaged following accidental ingestion of H<sub>2</sub>O<sub>2</sub> resulting in portal venous gas. Technique: GE MEDICAL SYSTEMS 64 slice CT scanner, Contrast enhanced (Portal venous phase) axial CT view in soft tissue window, 295 mA, Contrast: 85 mlsOmnipaque 350 at 3mls/second, 120kV, 5mm slice thickness Findings: Extensive portal venous gas throughout the liver (arrows).

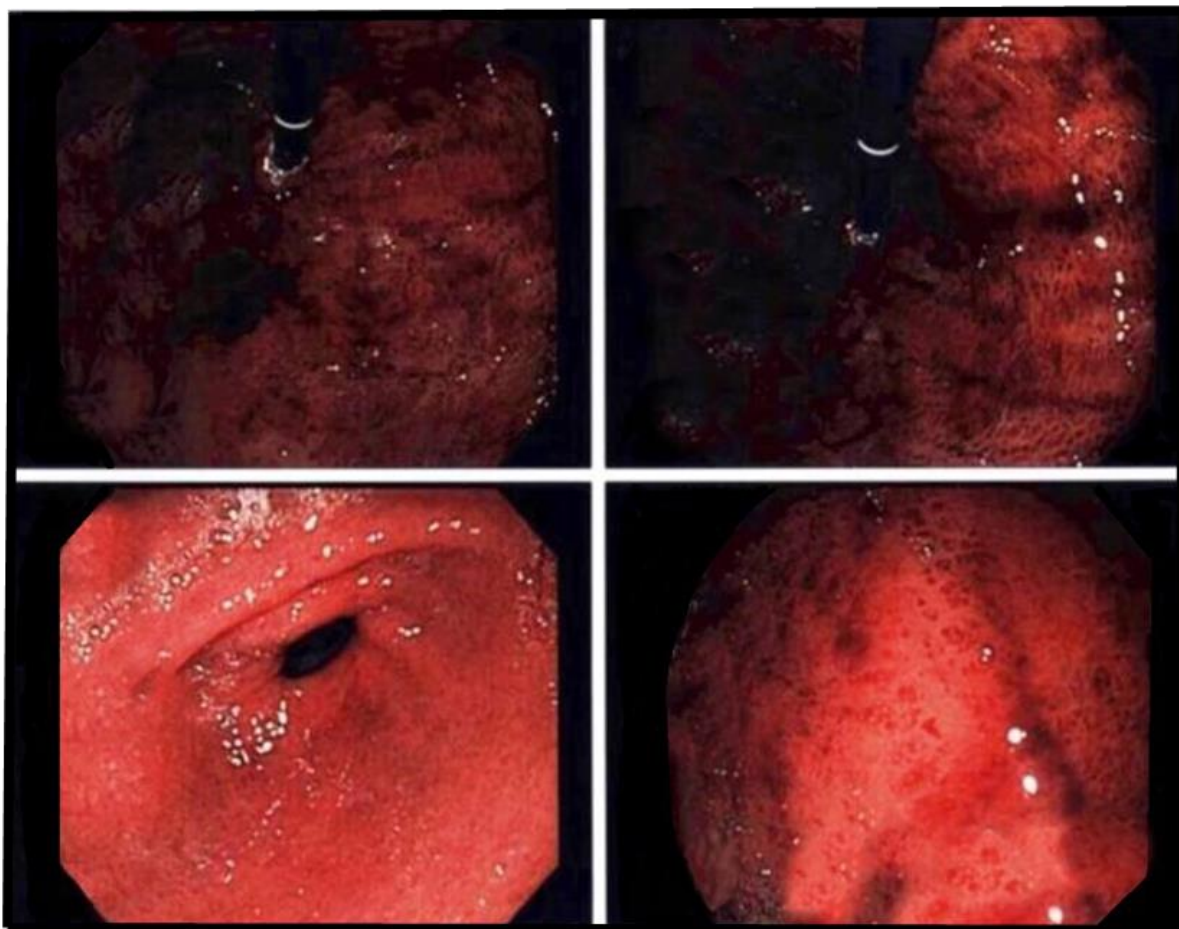


**Figure 2:** 52-years old male patient imaged following accidental ingestion of H<sub>2</sub>O<sub>2</sub> resulting in portal venous gas. Technique: GE MEDICAL SYSTEMS 64 slice CT scanner, Contrast enhanced (Portal venous phase) axial CT view in soft tissue window, 295 mA, Contrast: 85 mlsOmnipaque 350 at 3mls/second, 120kV, 5mm slice thickness Findings: air in the extra-hepatic portion of the portal vein (arrow head) as well pneumatosis in the wall of the gastric antrum (arrow).



**Figure 3:** 52-years old male patient imaged following accidental ingestion of H<sub>2</sub>O<sub>2</sub> resulting in portal venous gas. Technique: GE MEDICAL SYSTEMS 64 slice CT scanner, Contrast enhanced (Portal venous phase) coronal CT view in soft tissue window, 295 mA, Contrast: 85 mlsOmnipaque 350 at 3mls/second, 120kV, 5mm slice thickness Findings: Extensive portal venous gas throughout the liver (arrows).

**Figure 4:** 52-years old male patient imaged following accidental ingestion of H<sub>2</sub>O<sub>2</sub> resulting in portal venous gas. Technique: GE MEDICAL SYSTEMS 64 slice CT scanner, Contrast enhanced (Portal venous phase) sagittal CT view in soft tissue window, 295 mA, Contrast: 85 mlsOmnipaque 350 at 3mls/second, 120kV, 5mm slice thickness Findings: Extensive portal venous gas throughout the liver (arrows).



**Figure 5:** 52-years old male patient imaged following accidental ingestion of H<sub>2</sub>O<sub>2</sub> resulting in portal venous gas. Technique: Esophagogastroduodenoscopy Findings: diffuse acute hemorrhagic gastritis and mild duodenal bulb erosions.

<b>Etiology</b>	Other causes of portal and/or systemic venous gas include intestinal ischemia, necrotizing enterocolitis, sepsis, and trauma
<b>Incidence</b>	Higher incidence of concentrated than diluted H <sub>2</sub> O <sub>2</sub>
<b>Gender ratio</b>	None
<b>Age predilection</b>	None
<b>Risk factors</b>	Bowel distension and infection
<b>Treatment</b>	Hyperbaric oxygen therapy
<b>Prognosis</b>	Hyperbaric oxygen therapy is successful in resolving portal venous gas embolism from accidental concentrated H <sub>2</sub> O <sub>2</sub> ingestions.
<b>Findings on CT imaging</b>	Branching air densities in the main portal vein and its branches and/or mesenteric veins.

**Table 1:** Summary table for portal venous gas secondary to H<sub>2</sub>O<sub>2</sub> ingestion.

Differential	CT findings	X-Ray	Ultrasound
<b>Portal vein gas</b>	Branching air densities following portal vein distribution and more peripheral in location.	Thinner lucencies than seen in pneumobilia.	Bright, echogenic foci at the periphery with centrifugal flow
<b>Pneumobilia</b>	Branching air densities with more central distribution.	Sword-shaped lucency in the right paraspinous region (Sabre sign) present in ~50%	Air causes artifact with shadowing (Stripped appearance)
<b>Pneumoperitoneum</b>	Free air densities within the peritoneal cavity at the interface between the visceral and parietal peritoneum.	Cupola sign is the most sensitive x-ray sign	The linear array transducer is more sensitive and shows enhancement of the peritoneal stripe and may be accompanied by artifacts or dirty shadowing.

**Table 2:** Differential diagnosis table for portal venous gas.

**ABBREVIATIONS**

CT = Computed Tomography  
H<sub>2</sub>O<sub>2</sub> = Hydrogen Peroxide  
MRI = Magnetic Resonance Imaging  
US = Ultrasound

**KEYWORDS**

H<sub>2</sub>O<sub>2</sub>; venous gas; computed tomography; ultrasound; endoscopy; pneumatosis

**Online access**

This publication is online available at:  
[www.radiologycases.com/index.php/radiologycases/article/view/3253](http://www.radiologycases.com/index.php/radiologycases/article/view/3253)

**Peer discussion**

Discuss this manuscript in our protected discussion forum at:  
[www.radiolopolis.com/forums/JRCR](http://www.radiolopolis.com/forums/JRCR)

**Interactivity**

This publication is available as an interactive article with scroll, window/level, magnify and more features.  
Available online at [www.RadiologyCases.com](http://www.RadiologyCases.com)

Published by EduRad



[www.EduRad.org](http://www.EduRad.org)