

Crossed Aphasia in a Patient with Anaplastic Astrocytoma of the Non-Dominant Hemisphere

Stephanie Prater^{1*}, Neil Anand¹, Lawrence Wei², Neil Horner³

1. Department of Radiology, Morristown Medical Center, Morristown, NJ, USA

2. Sidney Kimmel Medical College, Jefferson University, Philadelphia, PA, USA

3. Department of Radiology, Overlook Medical Center, Summit, NJ, USA

* Correspondence: Stephanie Prater, Morristown Medical Center, 100 Madison Ave, Morristown, NJ 07960, USA
(✉ sprater16@yahoo.com)

Radiology Case. 2017 Sep; 11(9):1-9 :: DOI: 10.3941/jrcr.v11i9.3154

ABSTRACT

Aphasia describes a spectrum of speech impairments due to damage in the language centers of the brain. Insult to the inferior frontal gyrus of the dominant cerebral hemisphere results in Broca's aphasia - the inability to produce fluent speech. The left cerebral hemisphere has historically been considered the dominant side, a characteristic long presumed to be related to a person's "handedness". However, recent studies utilizing fMRI have shown that right hemispheric dominance occurs more frequently than previously proposed and despite a person's handedness. Here we present a case of a right-handed patient with Broca's aphasia caused by a right-sided brain tumor. This is significant not only because the occurrence of aphasia in right-handed-individuals with right hemispheric brain damage (so-called "crossed aphasia") is unusual but also because such findings support dissociation between hemispheric linguistic dominance and handedness.

CASE REPORT

CASE REPORT

We present the case of a 54-year-old right-handed woman with no significant past medical history who presented with expressive aphasia following a seizure. She had never experienced a seizure before this occurrence nor was there any family history of epilepsy or seizure disorders. Furthermore, she had no familial history of left-handedness.

A non-contrast CT of the head was performed as part of the initial evaluation. A vague focus of hypoattenuation was noted along the right perisylvian ribbon (Figure 1). Further investigation with gadolinium enhanced MRI revealed increased T2WI/FLAIR signal in the right perisylvian operculum with adjacent gyral expansion but no appreciable contrast enhancement (Figure 2 and Figure 3). This finding was suggestive of an infiltrative neoplastic process. Based on

the MRI diagnosis, the patient was placed on high-dose steroids to reduce the edema surrounding the tumor.

The combination of the patient's aphasic symptoms, right sidedness of the lesion, and the proximity of the lesion to the anatomical homologue of the expressive language center known as Broca's area raised concern for right-hemispheric expressive speech dysfunction, such that evaluation with fMRI was recommended by the neurosurgery service.

To localize Broca's speech area, the patient was asked to speak to generate a semantically related word to complete a simple blanked sentence that was presented on a screen. The response was covert (thought) rather than overt (spoken), to identify the expressive speech centers while avoiding activation of the facial motor regions. During completion of this task, the fMRI of the brain was performed utilizing a 3

Tesla GE-brand MRI scanner then fusing the acquired BOLD functional sequences with the fast spin echo T2-weight images and post-contrast 3-D gradient echo images. The study revealed speech function activation in the pars opercularis of the posterior portion of the right inferior frontal gyrus (Figure 4). This region of activation is analogous to Broca's area, the language center responsible for speech production located in the left (typically dominant) cerebral hemisphere. Additionally, because the patient was asked to look at the screen to view the blanked sentence, the visual cortices in the bilateral calcarine fissures of the occipital lobe also demonstrated activation. Interestingly, functional activity was also noted within pars opercularis of the left cerebral hemisphere, suggesting bilaterality of the patient's speech functionality.

There was a 3 day interval between the initial MRI and the fMRI; the aphasia resolved completely within this time frame. Indeed, the fMRI images (Figure 4) do not show direct contact between the tumor and the speech area such that the authors believe the aphasia was induced by peritumoral edema and subsequent mass effect on the adjacent speech area rather than direct contact by the tumor itself. The authors believe the 3 days of treatment with high dose steroids reduced the amount of edema, thus reversing the aphasia.

Given the assumption of right hemispheric linguistic dominance and the close proximity of the tumor to the region of speech function activation, the neurosurgeon recommended awake craniotomy with intraoperative speech mapping in order to safely resect the mass. Total resection was achieved without any language disturbance during the intraoperative continuous speech testing or postoperatively. Histological analysis revealed the mass to be a high grade anaplastic astrocytoma (Figure 5). The patient was scheduled for outpatient follow up with Oncology to begin a radiotherapy regimen and adjuvant temozolomide.

DISCUSSION

Etiology & Demographics:

Broca's area, Brodmann's area 44 and 45 in the inferior frontal gyrus, plays a key role in complex speech, receiving the flow of sensory input from the temporal cortex, creating a plan for speaking and transmitting said plan to the motor cortex, which exerts control over the musculature of the mouth [1]. Insult to this region results in Broca's aphasia, also known as expressive aphasia, and is characterized by the loss of ability to communicate in both spoken and written forms [1]. A person with expressive aphasia will present with telegraphic speech, speech comprised entirely of content words which leaves out insignificant words like "the" [1]. While the person may be understood, the speech they produce will not be grammatically correct.

Interestingly, it has been discovered that the damage restricted to the Broca's area is not enough to produce the "classical" Broca's aphasia; extension to the insula, lower motor cortex, and subjacent subcortical and periventricular

white matter must also occur [2]. However, lesions to the area alone may cause "minor Broca's aphasia," the symptoms of which are similar but lesser in severity than classical Broca's aphasia [2]. Furthermore, damage to Broca's area does not always result in permanent Broca's aphasia, as many patients with damage to the area can regain lost language functions overtime. This recovery may be due to reorganization, in which language tasks that previously depended on Broca's area now accomplished using different brain regions, including those in the opposite hemisphere [3].

All types of aphasia, including Broca's, are caused by lesions of various language areas throughout the dominant cerebral hemisphere. Insults include infarction, neoplastic process, seizure disorders, traumatic brain injury, and neurodegenerative diseases [1].

It is estimated that there are 80,000 new cases of aphasia due to stroke per year in the United States [4]. 15% of stroke patients under the age of 65 experience aphasia; this percentage increases to 43% for stroke patients age 85 and older [4]. With regard to neoplastic processes as the cause of aphasia, about 30%–50% of patients with primary brain tumors experience aphasia. These numbers, as well additional studies suggest the prevalence of stroke-induced aphasia seems to be lower than it is from tumor-induced aphasia [5].

Furthermore, various studies conclude that gender may play a role in the type and severity of stroke-induced aphasia experienced. For example, Wernicke's and global aphasia occur more commonly in women while Broca's aphasia occurs more commonly in men [6].

Clinical:

It is widely accepted that language production and processing is predominantly a left-hemispheric function. Several studies have reported that linguistic hemispheric dominance in healthy subjects depends primarily on personal handedness such that left cerebral hemisphere language dominance is the most common, as is dextrality [7-9]. Furthermore, several non-invasive neuroimaging studies in healthy adults demonstrated that approximately 95% of patients have left hemispheric language dominance no matter their handedness [8-10]. In healthy right-handed subjects 'atypical', i.e. right hemisphere language dominance, has generally been assumed to be exceedingly rare. However, in a recent study, right hemisphere dominance was found in 7.5% of healthy right-handed subjects, indicating that atypical language dominance is more common than previously believed [11].

In right-handed patients with right hemisphere brain lesions, language deficit symptomatology is referred to as crossed aphasia. This presentation is due to atypical right hemisphere linguistic dominance such that a lesion in the analogous language centers on right produce aphasic symptoms, which are normally seen in patients with left-sided lesions and typical hemispheric language dominance. The anomaly known as "crossed-aphasia" is significant because, not only is it rare, but it further supports recent research which

suggests hemispheric language dominance is influenced by, but not completely dependent on, handedness [12].

While the presentation of crossed Broca's aphasia indicates linguistic dominance of the right cerebral hemisphere in the aforementioned patient, the fMRI study revealed bilateral Broca's area functionality. This can be explained by research suggesting that plasticity of the human brain allows for reorganization of the functional speech system following an insult by stroke, epilepsy, and brain tumors, etc. Reorganization refers to transfer of function from the diseased dominant cerebral hemisphere to the healthy contralateral side in an effort to preserve speech. Recruitment of networks in the non-dominant hemisphere is believed to occur concurrently with efforts to repair the damaged original language networks in the dominant hemisphere [13, 14].

Imaging findings:

Imaging findings in patients with aphasia depend on both the type of aphasia and the etiology of the neural insult. Aphasia-inducing etiologies vary widely and include neoplastic, vascular, traumatic, and degenerative causes. Regardless of the type of the insult, the location and size of the insult will determine the type and extent of aphasia experienced. Broca's aphasia results from lesions to Brodmann's areas 44 and 45, which correspond to the posterior aspect of the inferior frontal gyrus (pars opercularis and triangularis) [15, 16].

The traditional test for evaluating hemispheric language dominance is the WADA test. Medical professionals conduct this test with the patient awake. Essentially, they introduce a barbiturate into one of the internal carotid arteries. That side of the brain becomes inhibited, effectively shutting down any language function in that hemisphere in order to evaluate the other hemisphere. An EEG recording at the same time confirms that the injected side of the brain is inactive as a neurologist or neuropsychiatrist engages the patient in a series of language tests. However, there is great variability in how both the procedure and language evaluation are performed making results difficult to compare between patients. With the advent of neuroimaging, more sensitive and reproducible language testing methods have emerged [17].

Evaluation of intracranial lesions using CT is limited but may be helpful in determining their initial presence and location. PET studies utilizing FDG can also be used to evaluate areas of increased neural activity and thus, functionality. MRI is the gold standard for the evaluation of central nervous system. fMRI is a technique for measuring brain activity that works by detecting the changes in blood oxygenation and flow that occur in response to neural activity. It can produce activation maps showing which parts of the brain are involved in language function. Additionally, it is excellent for determining the degree of function in a given region of brain following a neural insult [3,18].

Treatment & prognosis:

There are multiple rehabilitation strategies for the treatment of aphasia. The disorder-oriented approach aims at restoring language processing by providing speech therapy, the functional treatment approach maximizes communication, and the participation-oriented treatment emphasizes minimization of the social barriers many aphasics experience [19, 20]. All of the aforementioned therapies must be combined for the best possible outcome.

The prognosis for recovery depends largely on the underlying etiology. A recently conducted large meta-analysis study examining stroke-related aphasia did not demonstrate a positive relationship between age and recovery or clinical outcomes [21]. However, the majority of patients with aphasia due to stroke improve to some extent, despite permanent damage to the language area(s) [5, 22-24].

Differential Diagnosis:

Patients with aphasia may have difficulty finding the right words to complete their thoughts. While all types of aphasia affect a person's ability to communicate, they can be further subdivided by fluent versus non-fluent deficits in content, repetition, naming, and comprehension as well as reading/writing. Often times, different types of aphasia are also accompanied by motor deficits due to the location of the causative lesion [25]. Various forms of aphasia which are commonly confused for Broca's aphasia include Wernicke's, Conduction, Global, and Anomic aphasias.

Wernicke's aphasia: Wernicke's aphasia is a fluent aphasia characterized by impaired comprehension [25]. Speech is often described as "word salad" - voluminous but meaningless. Comprehension and production of written language is limited and the patient is unaware of these deficits. This type of aphasia results from lesions in the posterior superior temporal gyrus (Wernicke's area). Unlike Global aphasia, there is typically no motor deficit with this syndrome though a right superior visual field cut may be observed [25].

Conduction aphasia: Conduction aphasia is a fluent aphasia with impaired repetition and frequent paraphasic (typically phonemic) errors. Written language may be similarly affected. It is further characterized by relatively well-preserved comprehension [25, 26]. This disorder may be observed with lesions of the arcuate fasciculus within the deep parietal white matter [16, 26]. There is often no additional neurologic deficit.

Global aphasia: Global aphasia encompasses impairment of all language function [25]. Patients are often mute or produce only non-word sounds. They are unable to follow commands, although they may respond to the intonation of the command. Because this syndrome is usually associated with extensive perisylvian injury affecting both Broca's and Wernicke's areas, patients often present with right hemiparesis and sometimes, a right visual field deficit [16, 25]. However, case reports of global aphasia devoid of hemiparesis have been

reported in the setting of both encephalitis and late-stage degenerative dementia [27].

Anomic aphasia: Anomic aphasia is a type of aphasia characterized by problems recalling words, names, and numbers. Speech is fluent and receptive language is not impaired. Subjects often use circumlocutions (speaking in a roundabout way) in order to avoid a word they cannot remember. Patients are able to speak with correct grammar; the main problem is finding the appropriate word to identify an object or person. This type of aphasia can be quite complex, usually involving a breakdown in one or more pathways among various regions in the brain such that there is no specific spatial lesion [25].

TEACHING POINT

Crossed Broca's aphasia results from a right-sided lesion in the posterior aspect of the inferior frontal gyrus of right-handed patients with atypical right-sided hemispheric language dominance. It occurs rarely and supports recent studies which demonstrate discordance between handedness and cerebral hemispheric language dominance.

REFERENCES

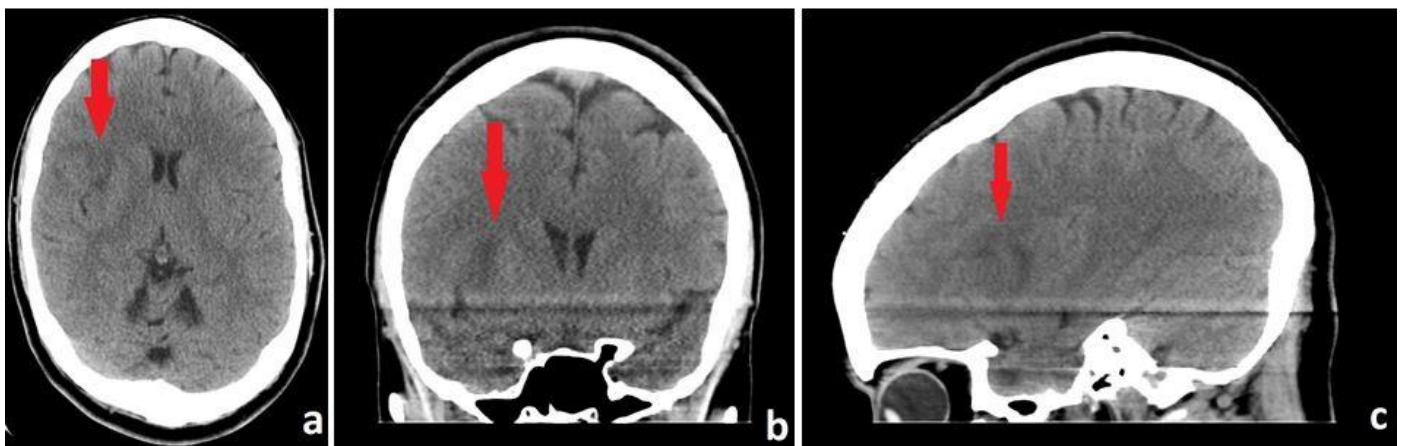
- Alexander MP, Naeser MA, Palumbo C. Broca's area aphasias: aphasia after lesions including the frontal operculum. *Neurology*. 1990;40(2):353-62. PMID: 2300260
- Ardila A, Bernal B, Rosselli M. Why Broca's Area Damage Does Not Result in Classical Broca's Aphasia. *Frontiers in Human Neuroscience*. 2016;10:249. PMID: 27313519
- Pedersen PM, Jorgensen HS, Raaschou HO, Olsen TS. Aphasia in acute stroke: Incidence, determinants, and recovery. *Annals of Neurology*. 1995;38:659-666. PMID: 7574464
- Thompson CK, Ouden DBD. Neuroimaging and recovery of language in aphasia. *Current Neurology and Neuroscience Reports*. 2008;8(6):475-483. PMID: 18957184
- Berthier ML. (2005). Poststroke aphasia: Epidemiology, pathophysiology and treatment. *Drugs and Aging*. 2005;22:163-182. PMID: 15733022
- Hier DB, Yoon WB, Mohr JP, Price TR, Wolf PA. Gender and Aphasia in the Stroke Database. *Brain Lang*. 1994;47(1):155-67. PMID: 7922475
- Holland SK, Plante E, Weber Byars A, Strawsburg RH, Schmithorst VJ, Ball Jr WS. Normal fMRI Brain Activation Patterns in Children Performing a Verb Generation Task. *Neuroimage*. 2001;14(4):837-43. PMID: 11554802
- Springer JA, Binder JR, Hammeke TA, Swanson SJ, Frost JA, Bellgowan PS, Brewer CC, Perry HM, Morris GL, Mueller WM. Language dominance in neurologically normal and epilepsy subjects: a functional MRI study. *Brain*. 1999;122(11):2033-46. PMID: 10545389
- Szaflarski JP, Holland SK, Schmithorst VJ, and Byars AW. An fMRI study of language lateralization in children and adults. *Hum Brain Mapp*. 2006;27(3): 202-212. PMID: 16035047
- Knecht S, Drager B, Deppe M, Bobe L, Lohmann H, Floel A, Ringelstein EB, Henningsen H. Handedness and hemispheric language dominance in healthy humans. *Brain* 123 Pt. 2000a;12:2512-8. PMID: 11099452
- Knecht S, Jansen A, Frank A, van Randenborgh J, Sommer J, Kanowski M, Heinze HJ. How atypical is atypical language dominance? *Neuroimage*. 2003;18(4):917-27. PMID: 12725767
- Brown JW, Wilson FR. Crossed aphasia in a dextral. A Case Report. *Neurology*. 1973;23:907-911. PMID: 4737683
- Karbe H, Thiel A, Weber-Luxenburger G, Herholz K, Kessler J, Heiss WD. Brain plasticity in poststroke aphasia: what is the contribution of the right hemisphere? *Brain Lang*. 1998;64:215-230. PMID: 9710490
- Oliveira FF, Damasceno BP. Global aphasia as a predictor of mortality in the acute phase of a first stroke. *Arq Neuropsiquiatr*. 2011;69:277-282. PMID: 21625750
- Kreisler A, Godefroy O, Delmaire C, Debachy B, Leclercq M, Pruvo JP, Leys D. The anatomy of aphasia revisited. *Neurology*. 2000;54(5):1117-23. PMID: 10720284
- Yang ZH, Zhao XQ, Wang CX, Chen HY, Zhang YM. Neuroanatomic correlation of the post-stroke aphasias studied with imaging. *Neurol Res*. 2008;30:356. PMID: 18544251
- Ishikawa T, Muragaki Y, Maruyama T, Abe K, Kawamata T. Roles of the Wada Test and Functional Magnetic Resonance Imaging in Identifying the Language-dominant Hemisphere among Patients with Gliomas Located near Speech Areas. *Neurologia medico-chirurgica*. 2017;57(1):28-34. PMID 27980284
- Bakar M, Kirshner HS, Wertz RT. Crossed aphasia. Functional brain imaging with PET or SPECT. *Arch Neurol*. 1996;53(10):1026-32. PMID: 8859065
- Cappa SF, Benke T, Clarke S, Rossi B, Stemmer B, van Heugten M; Task Force on Cognitive Rehabilitation; European Federation of Neurological Societies. EFNS guidelines on cognitive rehabilitation: report of an EFNS task force. *Eur J Neurol*. 2005;12:665-680. PMID: 16128867

20. Cicerone KD, Langenbahn DM, Braden C, Malec JF, Kalmar K, Fraas M, Felicetti T, Laatsch L, Harley JP, Bergquist T, Azulay J, Cantor J, Ashman T. Evidence-based cognitive rehabilitation: updated review of the literature from 2003 through 2008. *Arch Phys Med Rehabil.* 2011;92:519–530. PMID: 21440699
21. Ellis C, Urban S. Age and aphasia: a review of presence, type, recovery and clinical outcomes. *Top Stroke Rehabil.* 2016(6):430-439. PMID: 26916396
22. Laska AC, Hellblom A, Murray V, Kahan T, Von Arbin M. Aphasia in acute stroke and relation to outcome. *J Intern Med.* 2001;249:413. PMID: 11350565
23. Pedersen PM, Vinter K, Olsen TS. Aphasia after stroke: type, severity and prognosis. The Copenhagen aphasia study. *Cerebrovasc Dis.* 2004;17:35. PMID: 14530636
24. Ochfeld E, Newhart M, Molitoris J, Leigh R, Cloutman L, Davis C, Crinion J, Hillis AE. (2010). Ischemia in Broca's Area is Associated with Broca's Aphasia More Reliably in Acute than Chronic Stroke. *Stroke; a Journal of Cerebral Circulation.* 2010;41(2):325–330. PMID: 20044520
25. Hillis AE. Aphasia: progress in the last quarter of a century. *Neurology.* 2007;69:200. PMID: 17620554
26. Balasubramanian V. Dysgraphia in two forms of conduction aphasia. *Brain Cogn.* 2005;57:8. PMID: 15629207
27. Hanlon RE, Lux WE, Dromerick AW. Global aphasia without hemiparesis: language profiles and lesion distribution. *J Neurol Neurosurg Psychiatry.* 1999;66:365. PMID: 10084536

FIGURES

Figure 1 (bottom): 54-year-old female patient with crossed aphasia due to anaplastic astrocytoma of the non-dominant hemisphere.

- a. Findings: Axial non-contrast CT of the head demonstrates a vague focus of hypoattenuation along the right perisylvian ribbon (red arrow).
Technique: GE brand CT scanner. 160 mA. 120 kvp. 5mm slice thickness.
- b. Findings: Coronal non-contrast CT of the head demonstrates a vague focus of hypoattenuation along the right perisylvian ribbon (red arrow).
Technique: General Electric brand CT scanner. 160 mA. 120 kvp. 5mm slice thickness.
- c. Findings: Sagittal non-contrast CT of the head demonstrates a vague focus of hypoattenuation along the right perisylvian ribbon (red arrow).
Technique: General Electric brand CT scanner. 160 mA. 120 kvp. 5mm slice thickness.



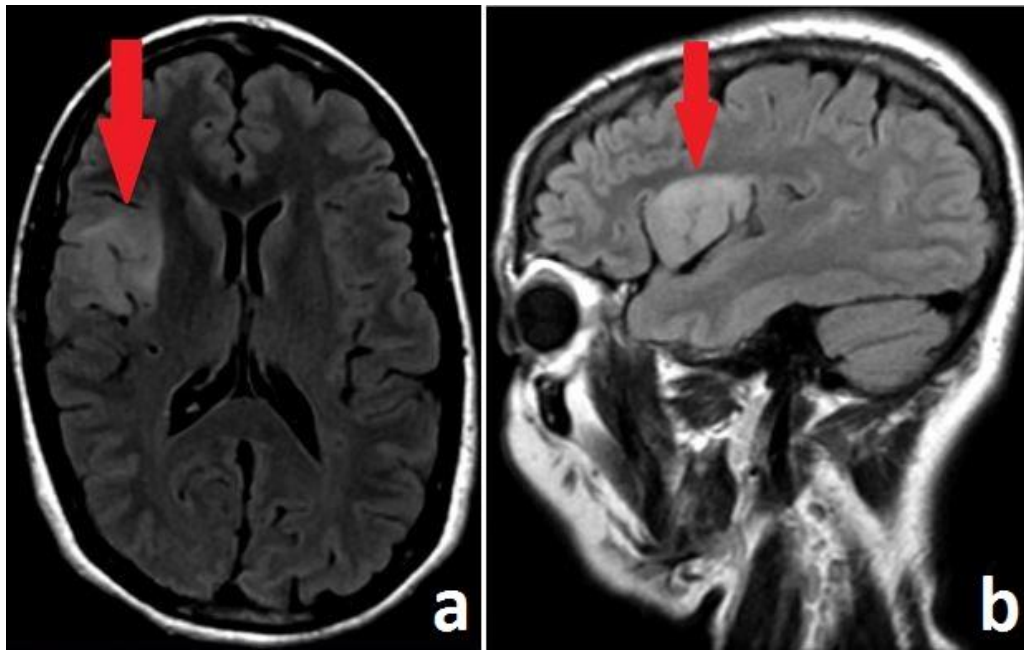


Figure 2: 54-year-old female patient with crossed aphasia due to anaplastic astrocytoma of the non-dominant hemisphere. a) Findings: Axial T2WI/FLAIR pre-contrast MRI of the brain demonstrates a hyperintense mass in the right perisylvian operculum (red arrow).

Technique: 3 Tesla General Electric brand MR scanner. TR 8000. TE 127. 5mm slice thickness.

b) Findings: Sagittal T2WI/FLAIR pre-contrast MRI of the brain demonstrates a hyperintense mass in the right perisylvian operculum (red arrow).

Technique: 3 Tesla General Electric brand MR scanner. TR 8000. TE 127. 5mm slice thickness.

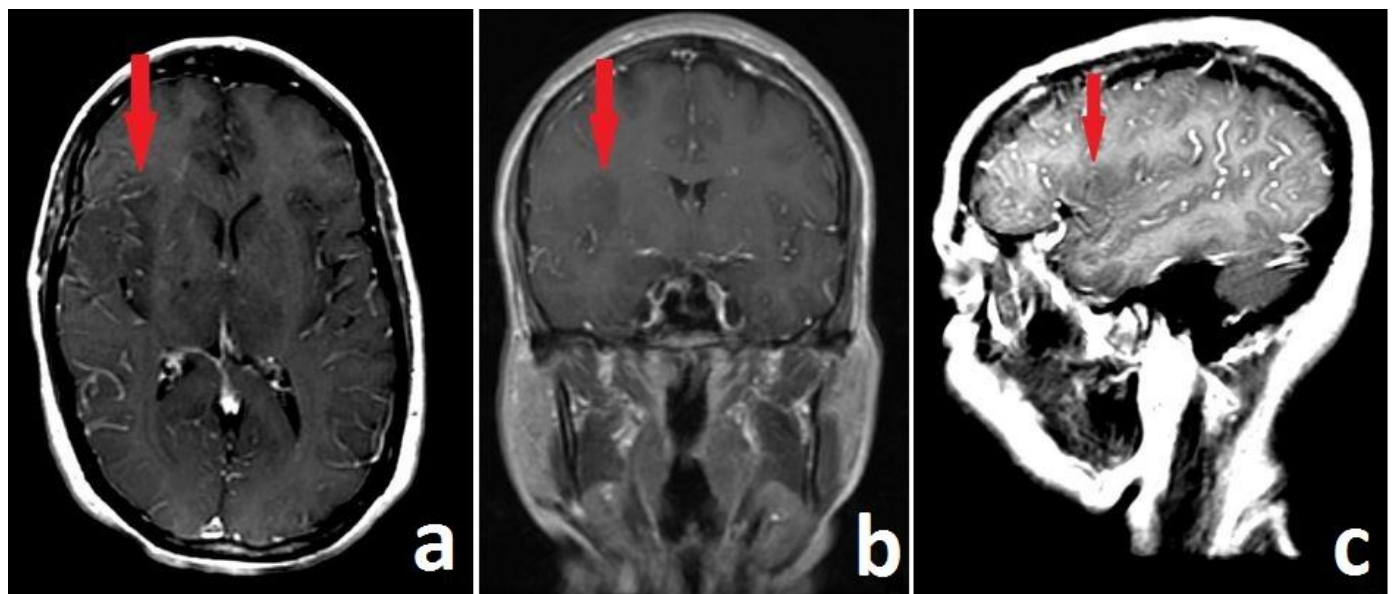


Figure 3: 54-year-old female patient with crossed aphasia due to anaplastic astrocytoma of the non-dominant hemisphere.

a) Findings: Axial T1WI post-contrast MRI of the brain demonstrates a vague focus of hypointensity with no appreciable contrast enhancement in the right perisylvian operculum (red arrow).

Technique: 3 Tesla General Electric brand MR scanner. TR 450. TE 20. 5mm slice thickness. 7.5mL Gadavist.

b) Findings: Coronal T1WI post-contrast MRI of the brain demonstrates a vague focus of hypointensity with no appreciable enhancement in the right perisylvian operculum (red arrow).

Technique: 3 Tesla General Electric brand MR scanner. TR 333. TE 20. 5mm slice thickness. 7.5mL Gadavist.

c) Findings: Sagittal T1WI post-contrast MRI of the brain demonstrates a vague focus of hypointensity with no appreciable enhancement in the right perisylvian operculum (red arrow).

Technique: 3 Tesla General Electric brand MR scanner. TR 400. TE 20. 5mm slice thickness. 7.5mL Gadavist.

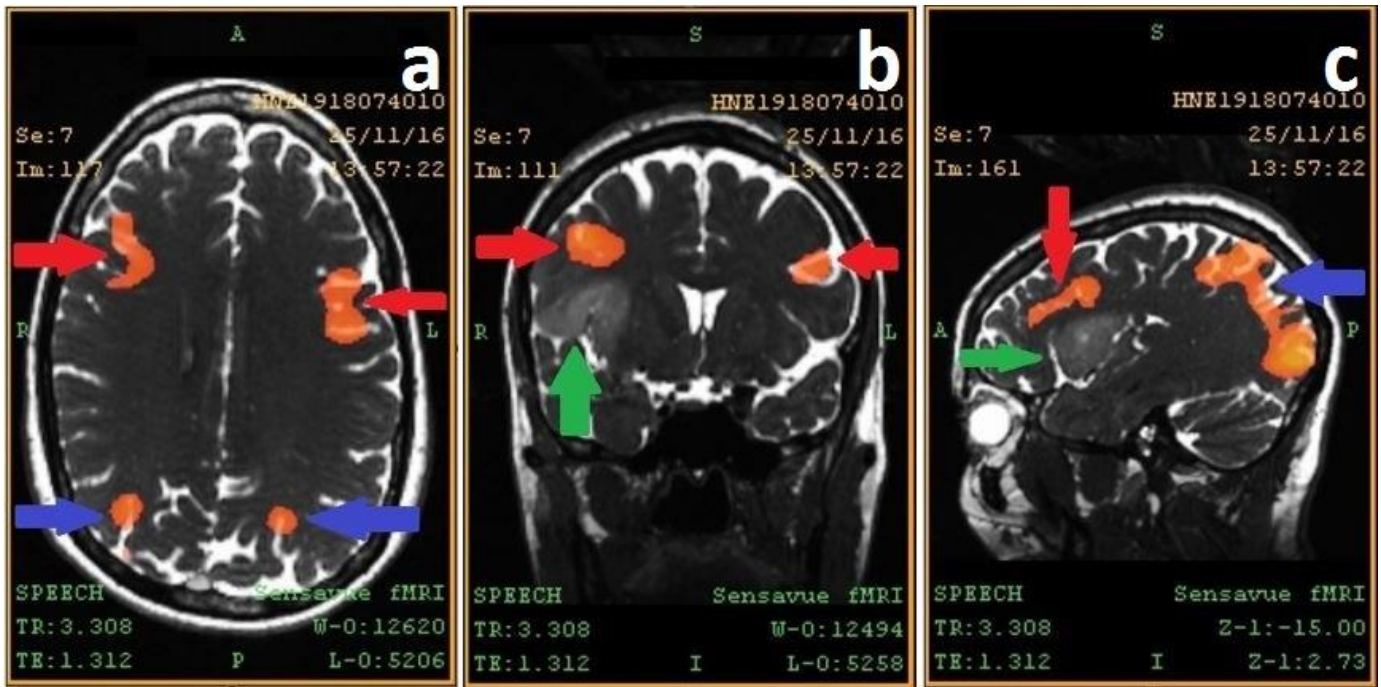


Figure 4: 54-year-old female patient with crossed aphasia due to anaplastic astrocytoma of the non-dominant hemisphere.
 a) Findings: Axial fMRI image of the brain demonstrates activity in the inferior frontal lobe at the level of the sylvian fissure (Broca's area) in the bilateral cerebral hemispheres (red arrows) and bilateral calcarine fissures (Visual cortex) in the occipital lobe (blue arrows).
 Technique: BOLD functional sequence fused to fast spin-echo T2-weighted and post-contrast 3D gradient echo magnetic resonance imaging sequences of the brain acquired while patient was covertly generating a word to complete a blanked sentence. 3 Tesla General Electric brand MR scanner. TR 3. TE 1. 1 mm slice thickness.
 b) Findings: Coronal fMRI image of the brain at the time of presentation for expressive aphasia following new onset seizure demonstrates activity in the inferior frontal lobe at the level of the sylvian fissure (Broca's area) in the bilateral cerebral hemispheres. Technique: same as above.
 c) Findings: Sagittal fMRI image of the brain at the time of presentation for expressive aphasia following new onset seizure demonstrates activity in the inferior frontal lobe at the level of the sylvian fissure (Broca's area) in the right cerebral hemisphere and right calcarine fissure (Visual Cortex) in the occipital lobe. Technique: same as above.

Journal of Radiology Case Reports

www.RadiologyCases.com

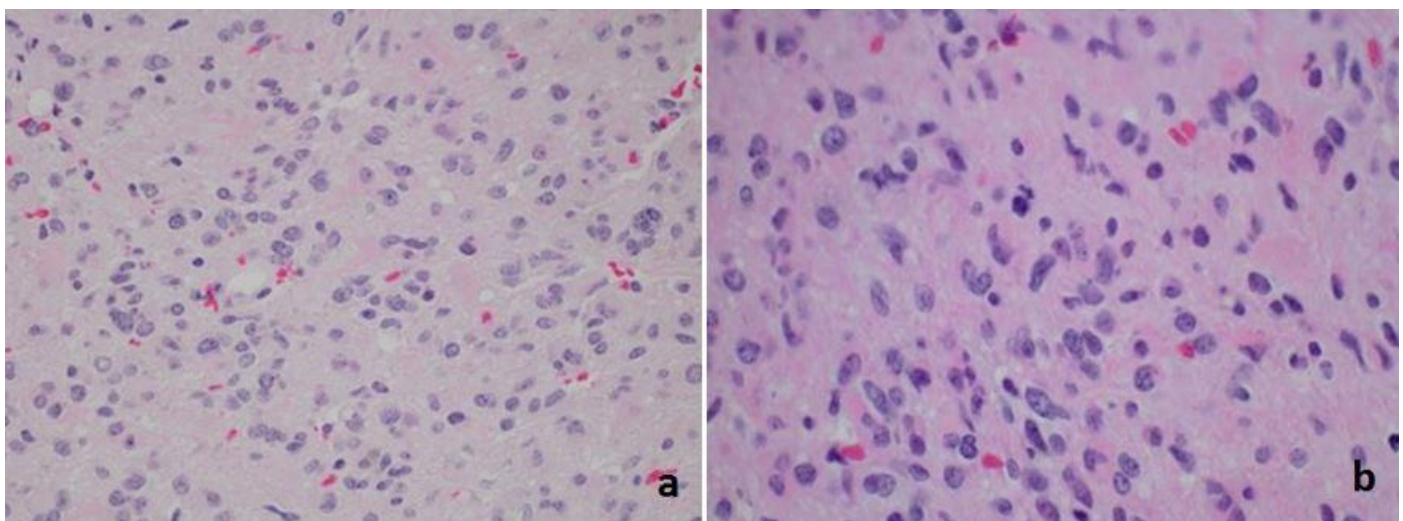


Figure 5: 54-year-old female patient with crossed aphasia due to anaplastic astrocytoma of the non-dominant hemisphere.
 a) H&E stained squash prep of a tissue sample retrieved at the time of resection. The image demonstrates low cellularity with mitoses, distinct nuclear atypia and pleomorphism. 10x Magnification.
 b) H&E stained squash prep of a tissue sample retrieved at the time of resection. The image demonstrates low cellularity with mitoses, distinct nuclear atypia and pleomorphism. 100x Magnification.

	CT	MRI	PET
Broca's Aphasia	<p><i>Hyperdense lesions (acute hemorrhage, tumors with hypercellularity or calcification); hypodense lesions (ischemic stroke, astrocytic tumors).</i></p> <p>Lesion typically located in the posterior frontal gyrus (Broca's area) of dominant hemisphere, frequently extending to subcortical or insular regions.</p>	<p><i>T1WI: Hyperintense lesions (hemorrhagic tumors or melanoma metastasis); Hypointense lesions (most tumors)</i> <i>T2WI: Hyperintense lesions (ischemic stroke, most tumors), hypointense lesions (hypercellular, calcifying, and hemorrhagic tumors, vascular malformations, colloid cysts)</i> <i>DWI: Hyperintense lesions (ischemic stroke, abscess, epidermoid cysts); isointense (most tumors).</i></p> <p>Lesion typically located in the posterior frontal gyrus (Broca's area) of dominant hemisphere, frequently extending to subcortical or insular regions.</p>	<p>Hypometabolism of the dominant posterior frontal gyrus, frequently extending to subcortical or insular regions; there may be hypermetabolism of ipsilateral undamaged regions around Broca's area and of contralateral homologue of Broca's area if there is any recovery of language functions.</p>
Wernicke's Aphasia	<p>Lesion are typically located in the posterior superior temporal gyrus (Wernicke's area) of dominant hemisphere.</p>	<p>Lesion are typically located in the posterior superior temporal gyrus (Wernicke's area) of dominant hemisphere.</p>	<p>Hypometabolism involving the posterior superior temporal gyrus. There may be hypermetabolism of ipsilateral undamaged regions around Wernicke's area and of contralateral homologue of Wernicke's area if there is any recovery of language functions.</p>
Global Aphasia	<p>Typically, extensive lesion of cortical regions supplied by MCA of the dominant hemisphere, including superior, middle, and inferior frontal gyrus, precentral gyrus, insula, putamen, and white matter tracts of uncinata, arcuate, and corticospinal tract.</p>	<p>Typically, extensive lesion of cortical regions supplied by MCA of the dominant hemisphere, including superior, middle, and inferior frontal gyrus, precentral gyrus, insula, putamen, and white matter tracts of uncinata, arcuate, and corticospinal tract.</p>	<p>Extensive hypometabolism of cortical regions supplied by MCA of the dominant hemisphere</p>
Conduction Aphasia	<p>Lesions are typically found in the arcuate fasciculus.</p>	<p>Lesions are typically found in the arcuate fasciculus.</p>	<p>Hypometabolism along the arcuate fasciculus.</p>
Anomic Aphasia	<p>No specific spatial pattern of lesion is characteristic.</p>	<p>No specific spatial pattern of lesion.</p>	<p>No specific spatial pattern of hypometabolism correlates with anomic aphasia.</p>

Table 1: Differential diagnosis table for Aphasia.

Etiology	Lesion of one or more of the language centers in the dominant cerebral hemisphere [1, 15, 28]
Incidence	80,000 new cases of aphasia per year due to stroke [2]. The incidence of aphasia due to other causes is not well documented.
Gender Ratio	Wernicke's and global aphasia occur more commonly in women [5]. Broca's aphasia occurs more commonly in men [5].
Age Predilection	15% of stroke patients under age 65, 43% of stroke patients over age 85 [2].
Risk Factors	Ischemic or hemorrhagic stroke, traumatic brain injury, brain tumor, brain surgery, brain infection, neurological disease (dementia, epilepsy, etc.)
Treatment	Various types of cognitive/speech/writing therapies [20,21]
Prognosis	Varies depending upon the cause of aphasia rather than the type of aphasia. Overall health of the patient also plays a role [4, 22-26].
Image Findings	<ul style="list-style-type: none"> • Imaging findings depend on the pathology causing the brain lesion as well as the affected language center/area of the brain. • Representative lesions include Brain tumor (imaging findings depend on the type), infarction (imaging findings depend on the type and age of the infarct), and dementia (imaging findings depend on the type). • Generally, one will see a lesion in one of the following language centers in the dominant cerebral hemisphere: posterior aspect of the inferior frontal gyrus (Broca's), posterior aspect of the superior temporal lobe (Wernicke's), arcuate fasciculus (Conduction), perisylvian region in the MCA territory (Global). • There is no specific imaging finding associated with Anomic aphasia.

Table 2: Summary table for Aphasia.

ABBREVIATIONS

- BOLD = Blood Oxygen Level Dependent
 CT = Computer Tomography
 DWI = Diffusion Weighted Imaging
 FDG = Fluorodeoxyglucose
 FLAIR = Fluid Attenuated Inversion Recovery
 fMRI = Functional Magnetic Resonance Imaging
 kVp = Peak Kilovoltage
 mA = Milliampere
 MCA = Middle Cerebral Artery
 mL = Milliliters
 MRI = Magnetic Resonance Imaging
 T1WI = T1 Weighted Imaging
 T2WI = T2 Weighted Imaging
 TE = Echo Time
 TR = Repetition Time

KEYWORDS

Broca; Aphasia; Tumor; Neoplasm; White Matter; MRI; fMRI; Functional; Anaplastic; Astrocytoma; Wernicke

Online access

This publication is online available at:
www.radiologycases.com/index.php/radiologycases/article/view/3154

Peer discussion

Discuss this manuscript in our protected discussion forum at:
www.radiolopolis.com/forums/JRCR

Interactivity

This publication is available as an interactive article with scroll, window/level, magnify and more features.
 Available online at www.RadiologyCases.com

Published by EduRad



www.EduRad.org