

# Adenocarcinoma of the Appendix Presenting as a Palpable Right Thigh Mass

Marci Handler<sup>1\*</sup>, Neil Anand<sup>1</sup>, Lawrence Wei<sup>2</sup>, Peter Snieckus<sup>3</sup>

1. Department of Radiology, Morristown Medical Center, Morristown, NJ, USA

2. Sidney Kimmel Medical College, Jefferson University, Philadelphia, PA, USA

3. Department of Radiology, Overlook Medical Center, Summit, NJ, USA

\* **Correspondence:** Marci Handler, Morristown Medical Center, 100 Madison Ave, Morristown, NJ 07960, USA  
(✉ [Marci.handler@gmail.com](mailto:Marci.handler@gmail.com))

Radiology Case. 2017 Apr; 11(4):20-29 :: DOI: 10.3941/jrcr.v11i4.3087

## ABSTRACT

Intra-abdominal and intra-pelvic pathologies initially presenting in extra-abdominal/pelvic locations is unusual. This spread predominantly occurs with infectious processes to sites including the buttock, thigh, and calf. The routes of extension into adjacent anatomically weak compartments include the pelvic outlet, greater sciatic foramen, obturator foramen, inguinal or femoral canal, weak bones, or along nerves and blood vessels. Malignant neoplasms of the appendix, while extremely rare and accounting for only 0.4% of all gastrointestinal cancers, is one of the intra-abdominal pathologies that can spread via these routes. Adenocarcinoma of the appendix accounts for 10-20% of primary appendiceal tumors. They usually present as acute appendicitis or as a right lower quadrant abdominal mass when associated with a mucocele. We report the unique case of mucinous appendiceal adenocarcinoma in a 57-year-old male who initially presented with a right thigh mass secondary to extension of the neoplasm from the right lower quadrant through the femoral canal. A similar presentation of a mucinous appendiceal cystadenoma has been previously reported, however, to our knowledge, this is the first case of a malignant appendiceal tumor extending into the thigh. We review the literature and discuss imaging findings and treatment of this tumor.

## CASE REPORT

### CASE REPORT

A 57-year-old gentleman with no significant past medical history first noticed a “lump” in his right inner thigh. After unsuccessful treatment with home remedies, he presented to his primary care physician who referred him to a sports medicine physician.

An ultrasound of the right thigh was performed, which demonstrated a multiseptated mass adjacent to the right thigh

musculature [Figures 1a, 1b]. The ultrasound was subsequently followed by MRI. MRI of the right femur demonstrated a large, approximately 7.0 x 2.4 cm, multiseptated cystic lesion extending into the deep fascial plane of the proximal anterior thigh and adductor compartments. The right femur was unremarkable and no bone involvement was seen [Figures 2-5]. Differential diagnoses at that time included plexiform neurofibroma, cystic lymphangioma, and vascular malformation. Given that the superior margin of the mass was not visualized on the MRI, a CT of the abdomen and pelvis

was recommended and completed. The CT revealed a cystic mass containing scattered calcifications within the right lower quadrant, adjacent to the right colon and extending along the right iliopsoas muscle into the right thigh through the femoral canal [Figures 6-8]. A normal appendix was not visualized. No lymphadenopathy or bony involvement was demonstrated on CT.

The patient underwent surgical resection of the abdominal mass, which included right hemicolectomy. His postoperative course was uncomplicated and he was discharged on the sixth postoperative day. Pathology revealed a mucinous appendiceal neoplasm with negative regional lymph nodes [Figures 9a, 9b]. Staging of the tumor was pT4b N0 M0. The patient was later scheduled to undergo surgical resection of the right thigh mass as well as chemotherapy.

## DISCUSSION

### Etiology & Demographics:

Malignant neoplasms of the appendix are extremely rare, accounting for only 0.4% of all gastrointestinal cancers. The majority of appendiceal tumors are carcinoids. Adenocarcinoma of the appendix accounts for only 10-20% of all appendiceal neoplasms [1]. The mucinous subtype of adenocarcinoma accounts for one third of those. The incidence of mucinous appendiceal adenocarcinoma has been reported between 0.01-0.02 per 100,000 people per year [2]. The mean age at presentation is 60 years and there is no clear sex predilection [3].

### Clinical & Imaging Findings:

Mucinous adenocarcinoma of the appendix is seldomly diagnosed preoperatively and is often only diagnosed after advanced disease has ensued. Approximately 30-50% of appendiceal tumors present with signs and symptoms of acute appendicitis [4]. To our knowledge, no confirmed cases of a malignant appendiceal tumor presenting as a right thigh mass from extension through the femoral canal have been published. A similar case of a thigh mass from a mucinous appendiceal stump extension was reported by Kim et al, but this was diagnosed histologically as a cystadenoma [5]. Another case of a thigh myxoma with pelvic communication was reported by Li et al, which was assumed to be from an appendiceal adenocarcinoma, yet lacked histologic confirmation [6]. Reported cases of non-appendiceal tumor extension into the thigh have been reported [7, 8]. More commonly, extra-pelvic spread was seen with infectious processes such as iliopsoas abscesses, appendicitis, and diverticulitis [8]. The known routes of spread of intra-abdominal pathologies outside of the abdomen or pelvis can occur through the pelvic outlet, greater sciatic foramen, obturator foramen, inguinal canal, femoral canal, and extension along nerves and blood vessels or through weak bone [7-9].

Mucinous appendiceal adenocarcinomas demonstrate circumferential mucosal involvement and have a strong

tendency to form mucoceles. Mucinous appendiceal adenocarcinomas are likely to be detected on imaging if they form a mucocele, especially if they are large or with complications. CT with contrast is an excellent modality for diagnosis and will often demonstrate a cystic, elongated mass in the right lower quadrant. The tumors are usually greater than 2 cm. Curvilinear mural calcifications can often be seen. Differentiating between a benign and malignant mucocele is often not possible [10]. However, nonspecific imaging features such as soft-tissue thickening and irregularity of the mucocele wall and adjacent fat can suggest malignancy [11]. Ultrasonography may show an anechoic structure or hypoechoic tubular structure with low-level internal echoes. Acoustic shadowing from mural calcification may be apparent. MR imaging will replicate the cystic findings on CT, yet calcification may be less apparent. MR characteristics include hyperintensity on T2 and post-contrast enhancement. The T1 signal characteristics are dependent on the amount of mucin within the neoplasm.

Pathologically, the presence of invasive neoplastic cells beyond the muscularis mucosae is diagnostic for mucinous appendiceal adenocarcinomas. More than 50% of the lesion is composed of mucin, which differentiates the tumor pathologically from the similar colonic-type adenocarcinoma. Secondary complications from mucinous appendiceal adenocarcinomas include intussusception, torsion, and especially rupture, as they represent a gastrointestinal tumor type most commonly presenting with perforations [12]. Mucinous material fills and distends the lumen, leading to a marked tendency for the tumor to rupture, thought to be the cause of pseudomyxoma peritonei. Pseudomyxoma peritonei is the presence of thick, copious mucinous or gelatinous material within the abdomen. This may lead to mucinous ascites, peritoneal implantation with tumor cells, adhesions and/or intestinal obstruction. Recent studies have suggested that the majority of pseudomyxoma peritonei cases are caused by penetration or rupture of appendiceal mucinous neoplasms into the peritoneal cavity [13]. Whereas mucoceles that develop from appendiceal hyperplasia or retention cysts do not cause recurrence once ruptured, mucoceles in the setting of adenocarcinoma can continually secrete mucin even after rupture, leading to pseudomyxoma peritonei.

### Treatment & Prognosis:

Right hemicolectomy leads to significant increase in survival compared to appendectomy alone in treating mucinous adenocarcinoma of the appendix, with a 5-year survival of 73% vs. 44%, respectively [14]. Because the mucinous subtype is thought to have no bloodborne or lymphatic tendency to metastasize, appendectomy alone may be a sufficient treatment option if the tumor is confined to the mucosa or is well differentiated and invades no deeper than the submucosa, although this distinction is often not possible intraoperatively [15-16].

The treatment of pseudomyxoma peritonei with external beam radiotherapy, intraperitoneal radioisotopes, intraperitoneal chemotherapy, and systemic chemotherapy may

be considered in addition to surgical resection, although their effectiveness on prolonging survival is yet unclear [17]. It is also unclear whether the presence of pseudomyxoma peritonei adversely affects survival, as previous studies are limited and not well controlled.

Because ovaries are a common site for metastasis from appendiceal adenocarcinoma, routine bilateral oophorectomy should be considered at the time of the appendiceal tumor resection and certainly pursued if there is evidence of metastasis to the ovaries [3].

Appendiceal adenocarcinoma is staged according to the TNM system. The patient presented with Grade 2 (larger than 2cm and has or has not extended into the large or small intestine) T4bN0M0 disease, representing a tumor that directly invades the abdominal wall or other nearby organs, without regional lymph node metastases, or spread to other parts of the body.

#### Differential Diagnosis:

The main differential considerations for mucinous appendiceal adenocarcinomas include, but are not limited to, appendicitis, appendiceal carcinoid, cecal carcinoma, appendiceal lymphoma, and ovarian cystic mass.

#### Appendicitis

Appendicitis is a commonly seen cause of abdominal pain with an incidence of approximately 7% of individuals affected in western countries in their lifetime [18]. It can present in all age groups and has no sex predilection. Appendicitis is characterized by appendiceal inflammation due to luminal obstruction and superimposed infection. On ultrasonography, the appendix will be non-compressible and will measure greater than 6 mm. The patient will usually be tender over McBurney's point. An appendicolith may be visualized as an echogenic shadowing focus. Increased vascular flow within the wall of the appendix is likely to be visualized. Additional signs on ultrasonography include right lower quadrant fluid, phlegmon or abscess. Contrast-enhanced CT will demonstrate a prominent appendix with abnormal wall enhancement and possible appendicolith. Right lower quadrant peri-appendiceal inflammation and phlegmon or abscess may be seen. MRI demonstrates the same general features as seen on CT with peri-appendiceal inflammatory changes. The wall of the appendix may demonstrate high signal on diffusion-weighted imaging.

#### Appendiceal Carcinoid

Carcinoid is the most common type of primary appendiceal neoplasm, accounting for 66% of cases [1]. The average age of diagnosis at 42.2 years is much lower than other types of GI carcinoids and appendiceal neoplasms [19]. Most tumors are asymptomatic, given that the majority of the lesions are located at the tip of the appendix. Those located at the base are more likely to cause obstruction, leading to appendicitis [1]. Rarely, in cases of metastasis, patients may have carcinoid syndrome and exhibit flushing, tachycardia, diarrhea, and/or hypotension due to the serotonin and

vasoactive substances produced by enterochromaffin cells. In suspected carcinoid syndrome, 24 hour urine 5-hydroxyindoleacetic acid (5-HIAA) or serum concentration of chromogranin A is indicated. Diagnosis is usually made histologically following appendectomy from appendicitis. US and CT commonly only show signs of appendicitis, as the tumor may not be appreciated due to its typical small size (<1 cm diameter). When seen, the tumors can have a diffuse infiltrative pattern of mural thickening, and if there is calcification, it may mimic an appendicolith. Rare metastatic disease can have CT features of small bowel carcinoid tumors, with an irregular soft-tissue mass near the root of the mesentery [4].

#### Cecal Carcinoma

Colon carcinoma is the second most frequently diagnosed malignancy in adults and has a mean age of diagnosis of 60-80 years with a slight male predilection. The most common location of colon carcinoma is in the rectosigmoid colon. Cecal and ascending carcinomas are the second-most common location [20]. Cecal masses may obstruct the appendiceal orifice and cause dilatation of the appendix. Contrast-enhanced CT will demonstrate a circumferential cecal mass, often with adjacent lymphadenopathy. Contrast enema may show narrowing of the cecal lumen.

#### Appendiceal Lymphoma

Appendiceal lymphoma is an extremely rare malignancy of the appendix, representing less than 1% of all primary appendiceal malignancies. It can manifest as a posttransplant lymphoproliferative disorder. Contrast-enhanced CT will demonstrate a prominent cylindrical soft tissue density. A lymphomatous infiltration of the appendix producing marked diffuse mural soft tissue thickening may be observed [21]. When the lymphoma is limited to the appendix, it cannot be accurately distinguished from other primary appendiceal neoplasms, such as adenocarcinoma. However, appendiceal lymphomas are rarely limited to the appendix, and the presence of abdominal lymphadenopathy increases the specificity for lymphoma [21].

#### Ovarian Cystic Mass

Ovarian cystic neoplasms may be benign or malignant. On ultrasonography, features suggestive of malignancy include thickened, irregular wall with thick septa, papillary projections, and increased vascularity. Ascites and/or discrete peritoneal deposits may be present. On CT, right ovarian cystic masses can be difficult to distinguish from the appendix.

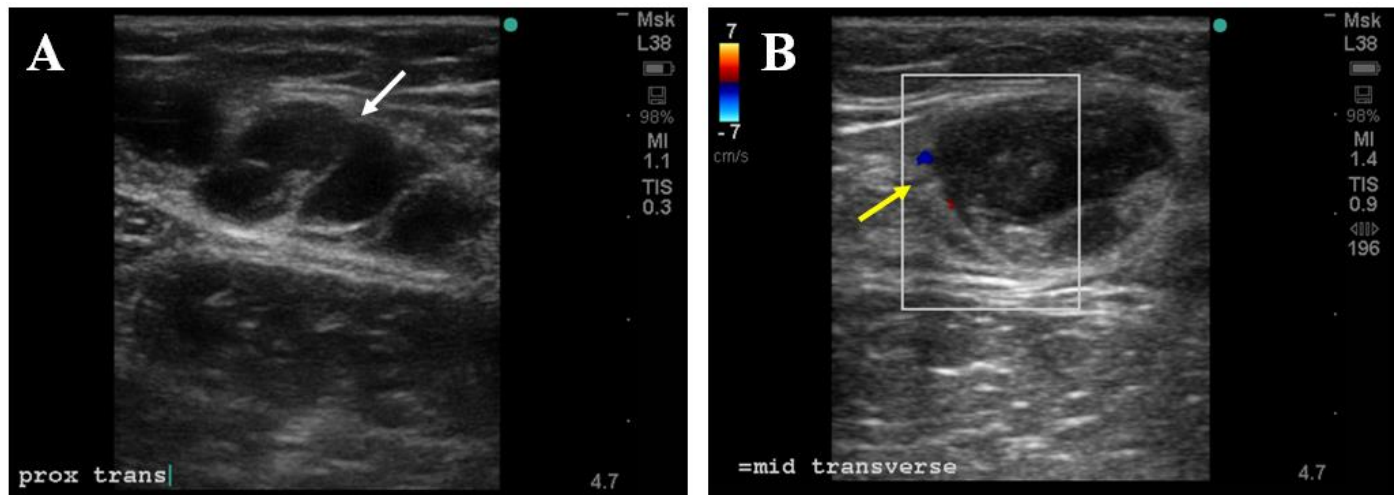
#### TEACHING POINT

Differentiating between benign and malignant appendiceal mucocèles is often difficult on imaging. Some of the features suggesting malignancy on CT include a mass greater than 2 cm, irregularity of the mucocèle wall and adjacent fat, and soft-tissue thickening. Lymphadenopathy or pseudomyxoma peritonei are other clues of a malignant process.

REFERENCES

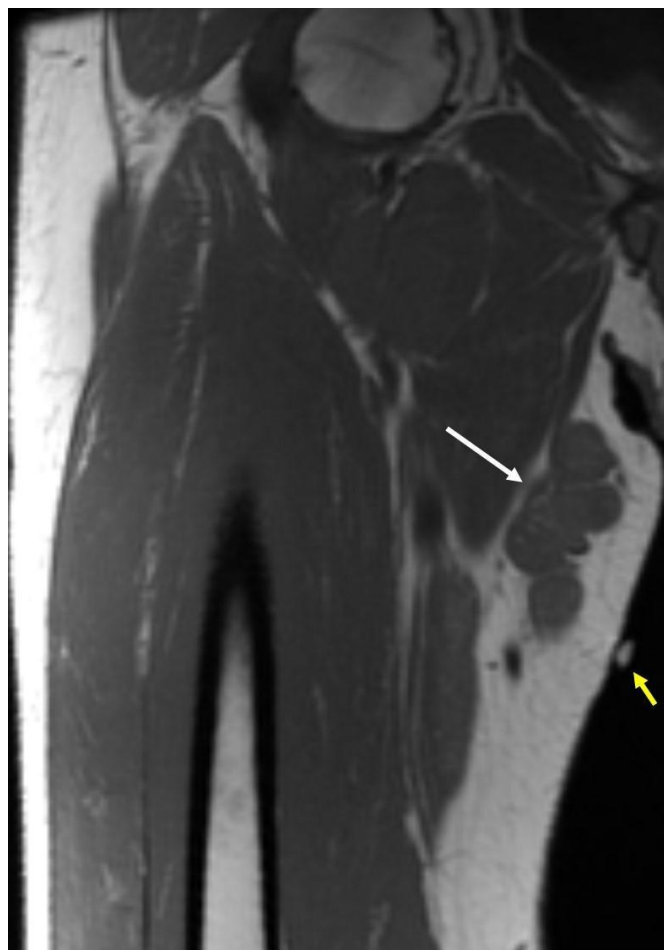1. Ruoff C, Hanna L, Wanqing Z, Shahzad G, Gotlieb V, Saif M. Cancers of the Appendix: Review of the Literatures. *ISRN Oncology*. 2011;2011:728579.
2. Komm M, Kronawitter-Fesl M, Kremer M, Lutz L, Holinski-Feder E, Kopp R. Primary Mucinous Adenocarcinoma of the Vermiform Appendix with High Grade Microsatellite Instability. *J Cancer*. 2011;2:302-306.
3. Kelly KJ. Management of Appendix Cancer. *Clinics in Colon and Rectal Surgery*. 2015;28(4):247-255.
4. Pickhardt PJ, Levy AD, Rohrmann CA, Jr, Kende AI. Primary neoplasms of the appendix: Radiologic spectrum of disease with pathologic correlation. *Radiographics*. 2003; May-Jun;23(3):645-62. Review. Erratum in: *Radiographics*. 2003 Sep-Oct;23(5):1340. PMID: 12740466.
5. Kim MK, Lee HY, Song IS, et al. A case of a giant mucocoele of the appendiceal stump presented with a palpable mass in the right thigh: pre-operative diagnosis based on characteristic multidetector CT findings. *The British Journal of Radiology*. 2010;83(994):e220-e223.
6. Li J, Zhang XY, Wang B, Cao QY. Myxoma of the upper leg originating from an appendiceal mucinous neoplasm: A case report. *Oncol Lett*. 2015 Oct;10(4):2327-2328. PMID: 26622844.
7. Tan CH, Vikram R, Boonsirikamchai P, et al. Pathways of extrapelvic spread of pelvic disease: imaging findings. *Radiographics*. 2011;31:117-133. PMID: 21257938.
8. Sugawara S, Ehara S, Hitachi S, Okada K. Patterns of soft-tissue tumor extension in and out of the pelvis. *American Journal of Roentgenology*. 2010;194(3):746-753. PMID: 20173154.
9. Abbas TO. Pelvic Primary Staphylococcal Infection Presenting as a Thigh Abscess. *Case Reports in Surgery*. 2013;2013:539737.
10. Lim H, Lee W, Kim S, Kim B, Cho J, Byun J. Primary mucinous cystadenocarcinoma of the appendix: CT findings. *AJR Am J Roentgenol*. 1999;173:1071-1074. PMID: 10511181.
11. Lee NK, Kim S, Kim HS, et al. Spectrum of mucin-producing neoplastic conditions of the abdomen and pelvis: Cross-sectional imaging evaluation. *World Journal of Gastroenterology : WJG*. 2011;17(43):4757-4771.
12. Wilson R. Primary carcinoma of the appendix. *Am J Surg*. 1962 Aug;104:238-249. PMID: 14007409.
13. Smeenk RM, van Velthuisen ML, Verwaal VJ, Zoetmulder FA. Appendiceal neoplasms and pseudomyxoma peritonei: a population based study. *Eur J Surg Oncol*. 2008 Feb;34(2):196-201. PMID: 17524597.
14. Nitecki SS, Wolff BG, Schlinkert R, Sarr MG. The natural history of surgically treated primary adenocarcinoma of the appendix. *Ann Surg*. 1994 Jan;219(1):51-7. PMID: 8297177.
15. Hata K, Tanaka N, Nomura Y, Wada I, Nagawa H. Early appendiceal adenocarcinoma. A review of the literature with special reference to optimal surgical procedures. *J Gastroenterol*. 2002;37(3):210-4. Review. PMID:11931535.
16. Gilhorne RW, Johnston DH, Clark J, Kyle J. Primary adenocarcinoma of the vermiform appendix: report of a series of ten cases, and review of the literature. *Br J Surg*. 1984 Jul;71(7):553-5. PMID: 6733432.
17. Hinson FL, Ambrose NS. Pseudomyxoma peritonei. *Br J Surg*. 1998 Oct;85(10):1332-9. Review. PMID: 9782010.
18. Omari AH, Khammash MR, Qasaimeh GR, Shammari AK, Yaseen MKB, Hammori SK. Acute appendicitis in the elderly: risk factors for perforation. *World Journal of Emergency Surgery: WJES*. 2014;9:6.
19. Sandor A, Modlin IM. A retrospective analysis of 1570 appendiceal carcinoids. *Am J Gastroenterol*. 1998 Mar;93(3):422-8. PMID: 9517651.
20. Giovannucci E, Wu K. Cancers of the colon and rectum. Schottenfeld D, Fraumeni J, eds. *Cancer. Epidemiology and Prevention*. 3rd ed. Oxford University Press; 2006.
21. Guo J, Wu G, Chen X, Li X. Primary appendiceal lymphoma presenting as suspected perforated acute appendicitis: clinical, sonography and CT findings with pathologic correlation. *Int J Clin Exp Pathol*. 2014 Sep 15;7(10):7068-71. PMID: 25400798.

FIGURES

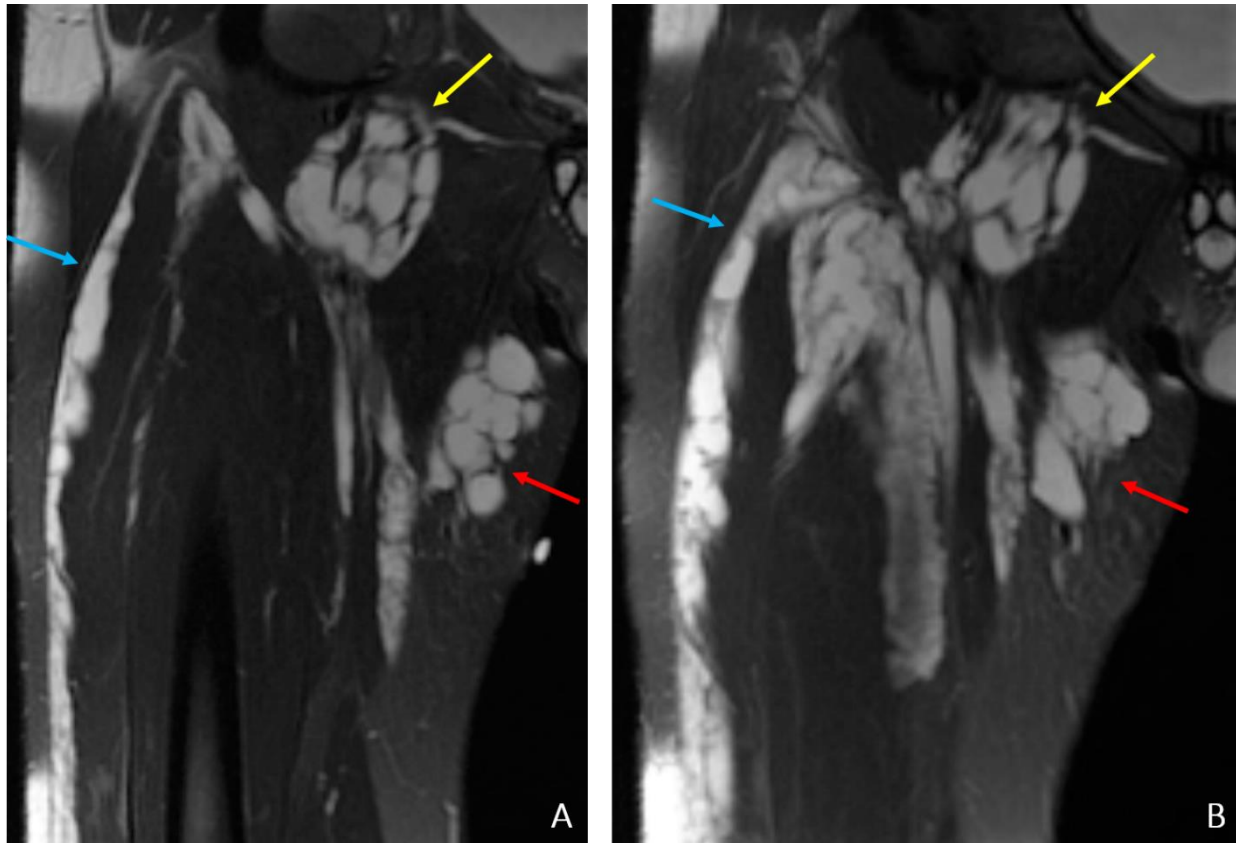


**Figure 1:** 57-year-old male patient: Diagnosis of Adenocarcinoma of the Appendix Presenting as a Palpable Right Thigh Mass  
Findings: Ultrasound images of the proximal and mid right medial thigh in the transverse plane demonstrates a cystic tubular structure with low-level internal echoes (white arrow). In greatest dimensions, the lesion measured approximately 1.8cm anteroposterior by 2.3cm transverse by 3.0cm craniocaudal. However, it was noted by the technologist that accurate measurements of the lesion were difficult to obtain. A small amount of peripheral vascularity is noted on color Doppler (yellow arrow). The lesion appears separate from the adjacent medial thigh musculature.

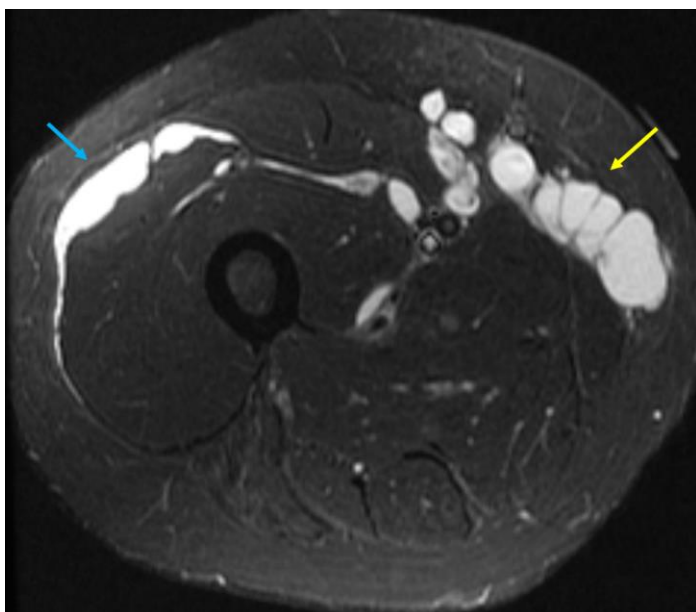
Technique: Figure 1a - B-mode sonogram of the proximal right medial thigh. Ultrasonography was performed using 13-6 MHz HFL38 linear transducer. Figure 1b - Color Doppler sonogram of the mid right medial thigh. Ultrasonography was performed using 13-6 MHz HFL38 linear transducer.



**Figure 2:** 57-year-old male patient: Adenocarcinoma of the Appendix Presenting as a Palpable Right Thigh Mass  
Findings: Coronal T1-weighted MR image of the right thigh demonstrates a multiseptated mass just superficial to the gracilis and adductor musculature, which is isointense to muscle on T1 (white arrow). This component of the lesion was at the site of the reported palpable abnormality in the region of the previously performed ultrasound (yellow arrow).  
Technique: Model: Optima MR450w 1.5 Tesla; TE: 6.50; TR: 660.

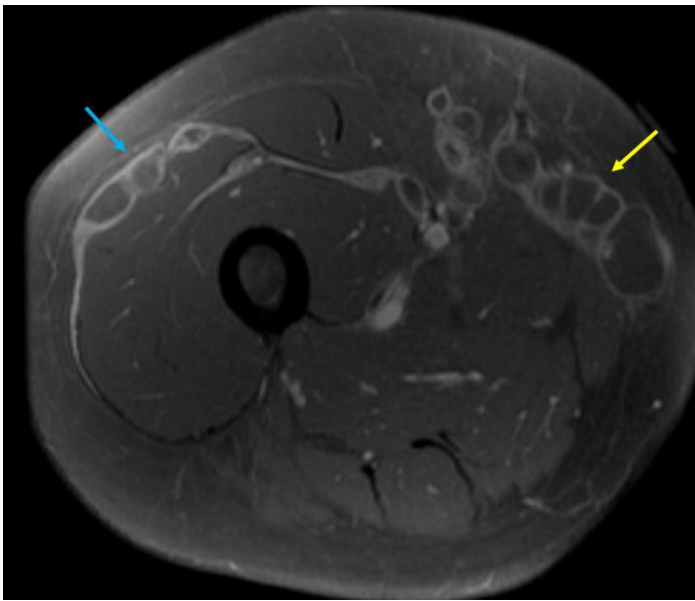


**Figure 3:** 57-year-old male patient: Adenocarcinoma of the Appendix Presenting as a Palpable Right Thigh Mass  
Findings: Coronal T2-weighted fat-saturated MR images of the right thigh demonstrate a large septated cystic mass with increased T2 signal, compatible with mucin. The mass extends from the pelvis along the course of the right iliopsoas tendon and into the thigh (yellow arrows) to insinuate just superior to the vastus intermedius and deep to the rectus femoris. A component extends superficially to the vastus lateralis (blue arrows) as well as in the thigh medially (red arrows). Accurate measurements could not be adequately obtained given the extensive spread of the lesion, however, the anteromedial aspect within the proximal thigh measured approximately 2.4cm transverse by 7.0cm in craniocaudal dimensions. The extent of the mucinous cystic lesion is better defined than on the previously performed ultrasound.  
Technique: Model: Optima MR450w 1.5 Tesla; a) TE: 78.14; TR: 4742; b) TE: 78.96; TR: 5821.

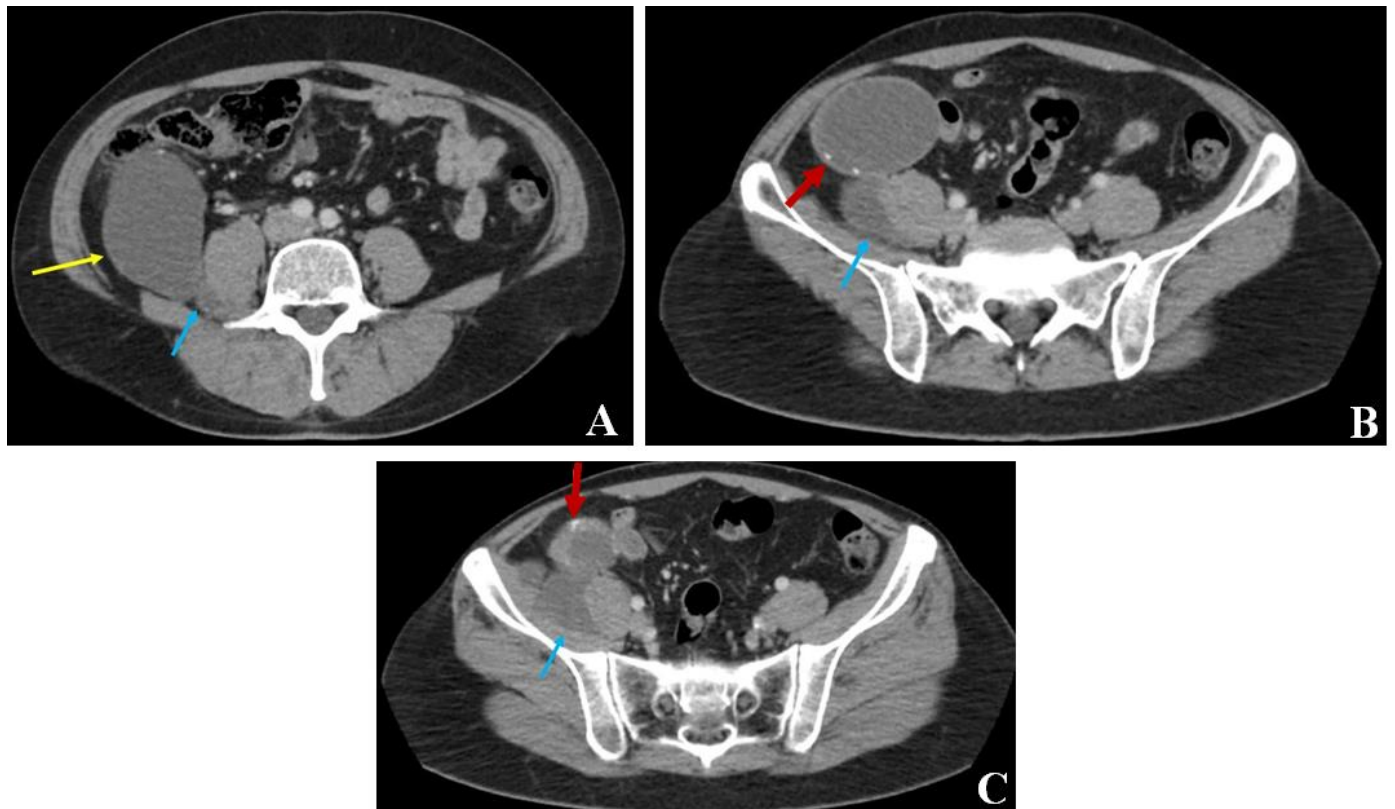


**Figure 4:** 57-year-old male patient: Adenocarcinoma of the Appendix Presenting as a Palpable Right Thigh Mass  
Findings: Axial STIR MR image of the right thigh demonstrates a large septated loculated cystic lesion interspersed in the right thigh musculature medially (yellow arrow) and laterally (blue arrow).  
Technique: Model: Optima MR450w 1.5 Tesla; TI: 140; TE: 41.56; TR: 4675.

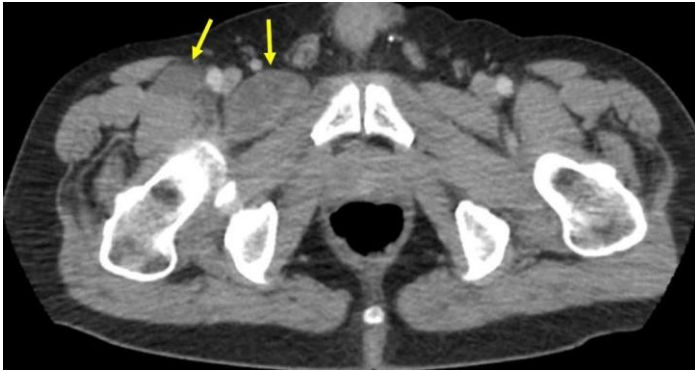




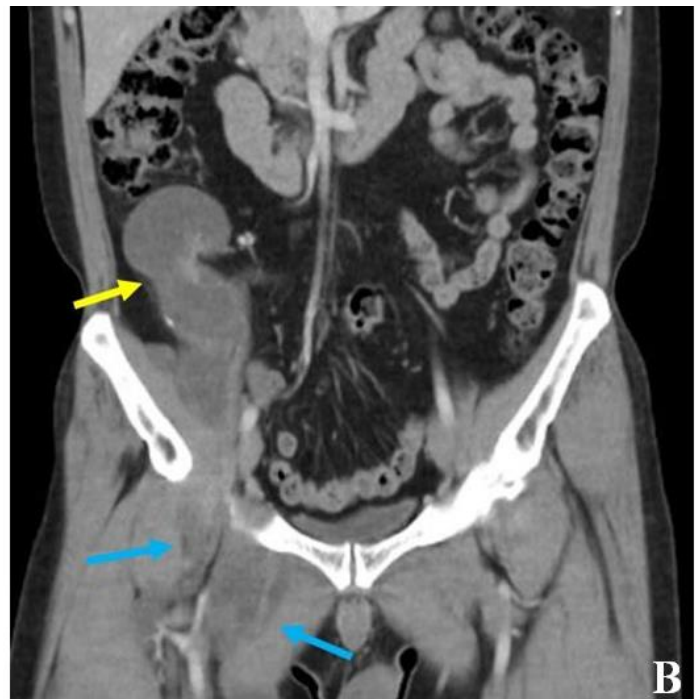
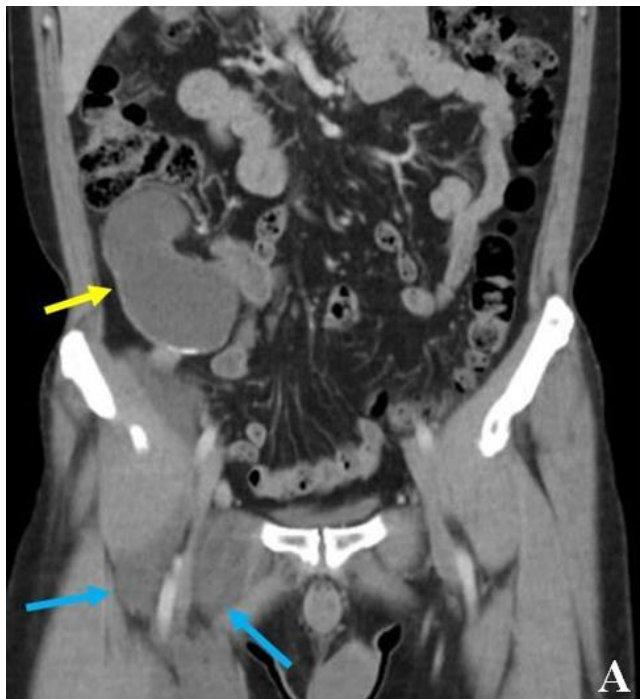**Figure 5:** 57-year-old male patient: Adenocarcinoma of the Appendix Presenting as a Palpable Right Thigh Mass  
Findings: Axial contrast-enhanced T1-weighted fat-saturated MR image of the right thigh demonstrates peripheral enhancement of the large septated loculated lesion insinuating along the thigh musculature within the medial (yellow arrow) and lateral (blue arrow) aspects.  
Technique: Model: Optima MR450w 1.5 Tesla; TE: 6.73; TR: 612; 19mL Gadavist administered.



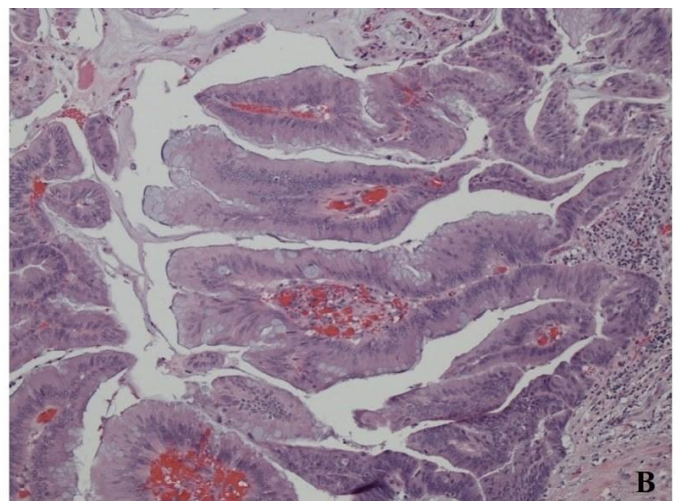
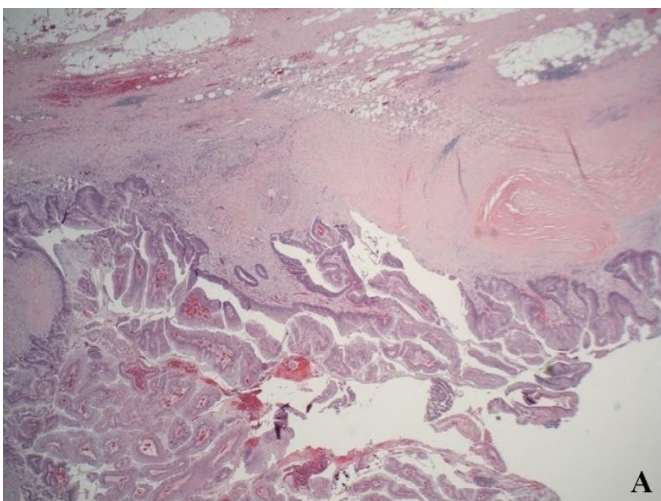
**Figure 6:** 57-year-old male patient: Adenocarcinoma of the Appendix Presenting as a Palpable Right Thigh Mass  
Findings: Axial contrast-enhanced CT images of the abdomen demonstrate a cystic mass in the right lower quadrant (yellow arrow), which is separate from the right colon and causes anterior displacement of the right colon. The largest component of the lesion measured approximately 9.3cm in anteroposterior by 5.7cm in transverse dimension. A component of the mass extends posteriorly along the right psoas muscle (blue arrows). The cystic mass contains a few scattered peripheral calcifications (red arrows). A normal appendix was not visualized.  
Technique: Venous phase; mA 120; kV 120; 5.0mm slice thickness; 100ml Omnipaque 300.



**Figure 7:** 57-year-old male patient: Adenocarcinoma of the Appendix Presenting as a Palpable Right Thigh Mass  
Findings: Axial contrast-enhanced CT of the pelvis demonstrates a cystic lesion extending from the pelvis into the right anterior thigh through the femoral canal (yellow arrows).  
Technique: Venous phase; mA 120; kV 120; 5.0mm slice thickness; 100ml Omnipaque 300.



**Figure 8:** 57-year-old male patient: Adenocarcinoma of the Appendix Presenting as a Palpable Right Thigh Mass  
Findings: Coronal contrast-enhanced CT images of the abdomen demonstrate a cystic mass in the right lower quadrant (yellow arrows) with peripheral calcifications. Extension of the mass into the right thigh is seen through femoral canal (blue arrows).  
Technique: Venous phase; mA 120; kV 120; 5.0mm slice thickness; 100ml Omnipaque 300.



**Figure 9:** 57-year-old male patient: Adenocarcinoma of the Appendix Presenting as a Palpable Right Thigh Mass  
Findings: Histologic images demonstrating mucinous adenocarcinoma of the appendix. There are pools of mucin which contain dysplastic epithelial cells dissecting into and through the appendiceal wall.



<b>Etiology</b>	Unclear
<b>Incidence</b>	0.01-0.02 per 100,000 people per year
<b>Gender Ratio</b>	No clear sex predilection
<b>Age</b>	Mean age 60 years
<b>Predilection</b>	
<b>Risk Factors</b>	Unknown
<b>Treatment</b>	Surgical excision +/- chemotherapy; right hemicolectomy is believed to be superior to appendectomy alone
<b>Prognosis</b>	Some studies report 5-year survival rate of approximately 50% in patients treated with cytoreduction debulking surgery and hyperthermic intraoperative peritoneal chemotherapy; 10-year survival rate of 0-10%
<b>Image Findings</b>	<ul style="list-style-type: none"> <li>• CT demonstrates a cystic, elongated mass in the right lower quadrant, usually greater than 2 cm with curvilinear mural calcifications, soft-tissue thickening and irregularity.</li> <li>• US demonstrates a cystic, ovoid right lower quadrant mass with possible internal echoes.</li> <li>• MRI characteristics include hyperintensity on T2 and post-contrast enhancement; T1 signal intensity dependent on mucin concentration.</li> </ul>

**Table 1:** Summary table for Mucinous Appendiceal Adenocarcinoma.

Differential Diagnosis	X-Ray	US	CT	MRI	PET
<b>Appendiceal Adenocarcinoma</b>	Possible curvilinear calcification; contrast enema may demonstrate a smooth impression on the medial wall of the cecum	Cystic, ovoid right lower quadrant mass with possible internal echoes; calcification may be seen	Cystic, elongated mass in the right lower quadrant, usually greater than 2 cm; curvilinear mural calcifications, soft-tissue thickening and irregularity; pseudomyxoma peritonei is possible	<u>T1WI</u> – Signal intensity dependent on mucin concentration <u>T2WI</u> – Hyperintense tubular distension of the appendix <u>DWI</u> – May have restricted diffusion	FDG PET/CT intense hypermetabolic activity; can be useful modality for staging
<b>Appendicitis</b>	Appendicolith in <5% of cases; possible air-fluid levels in right lower quadrant bowel	Non-compressible, tubular structure measuring greater than 6 mm; may have shadowing appendicolith; increased vascularity within wall of appendix	Dilated appendix measuring greater than 6 mm with abnormal enhancement of the wall; possible appendicolith	<u>T1WI</u> – No significant abnormal signal abnormalities <u>T2WI</u> – High luminal signal intensity, wall thickness greater than 2 mm and hyperintense adjacent fluid/edema <u>DWI</u> – Wall of appendix may be bright	FDG PET/CT demonstrates focal hypermetabolic activity overlying an enlarged and dilated appendix
<b>Cecal Carcinoma</b>	Narrowing of cecal lumen on contrast enema	Asymmetric, hypoechoic, circumferential wall thickening of the cecum with narrowing of the lumen	Asymmetric mural thickening of soft tissue density, often with adjacent lymphadenopathy	<u>T1WI</u> – Enhancing nodular mass on postcontrast imaging <u>T2WI</u> – Slightly hyperintense compared to muscularis propria <u>DWI</u> – May demonstrate restricted diffusion	FDG PET/CT demonstrates intense radiotracer uptake and is very useful for staging
<b>Appendiceal Lymphoma</b>	N/A	Diffuse, hypoechoic mural wall thickening	Enlarged appendix with increased soft tissue attenuation	<u>T1WI</u> – Hypointense <u>T2WI</u> – Slightly hyperintense <u>DWI</u> – Increased signal	FDG PET/CT may be hypermetabolic if high-grade; no abnormal hypermetabolic activity if low-grade
<b>Ovarian Cystic Mass</b>	Calcification may be seen in up to 12% of malignant ovarian masses	Malignant features include heterogenous appearance with papillary projections, thickened septa, solid components, and increased vascularity	Malignant masses may be large, heterogenous cystic adnexal lesions that may demonstrate calcification; ascites and lymphadenopathy and/or ascites	<u>T1WI</u> – Hypointense; solid malignant components demonstrate enhancement <u>T2WI</u> – Hyperintense <u>DWI</u> – Malignant components restrict	FDG PET/CT can effectively distinguish between benign and malignant lesions as malignant lesions will be hypermetabolic

**Table 2:** Differential diagnosis table for Mucinous Appendiceal Adenocarcinoma.

#### ABBREVIATIONS

cm: Centimeters  
CT: Computed Tomography  
DWI: Diffusion-Weighted Imaging  
FDG PET/CT: Fluorodeoxyglucose-18 Positron Emission Tomography  
kV: Kilovoltage  
mA: Milliampere  
MHz: Megahertz  
mm: Millimeters  
MRI: Magnetic Resonance Imaging  
N/A: Not Applicable  
STIR: Short Tau Inversion Recovery  
T1WI: T1-Weighted Imaging  
T2WI: T2-Weighted Imaging  
TI: Inversion Time  
TE: Echo Time  
TR: Repetition Time  
TNM: Tumor Node Metastasis

#### KEYWORDS

Appendix; appendiceal; adenocarcinoma; mucinous; mucocele; thigh mass; femoral canal; Computed Tomography; Ultrasonography; Magnetic Resonance Imaging

#### ACKNOWLEDGMENTS

Dr. John Donahue

#### **Online access**

This publication is online available at:  
[www.radiologycases.com/index.php/radiologycases/article/view/3087](http://www.radiologycases.com/index.php/radiologycases/article/view/3087)

#### **Peer discussion**

Discuss this manuscript in our protected discussion forum at:  
[www.radiolopolis.com/forums/JRCR](http://www.radiolopolis.com/forums/JRCR)

#### **Interactivity**

This publication is available as an interactive article with scroll, window/level, magnify and more features.  
Available online at [www.RadiologyCases.com](http://www.RadiologyCases.com)

Published by EduRad



[www.EduRad.org](http://www.EduRad.org)