

Imaging Findings of Ulceroglandular Tularemia

Neil Anand^{1*}, Osmani Deochand¹, Robyn Murphy¹

1. Department of Radiology, Morristown Medical Center, Morristown, NJ, USA

* Correspondence: Neil Anand, Morristown Medical Center, 100 Madison Ave, Morristown, NJ 07960, USA
(✉ Neil.anand@atlantichhealth.org)

Radiology Case. 2017 Jan; 11(1):1-6 :: DOI: 10.3941/jrcr.v11i1.2983

ABSTRACT

Francisella tularensis, the causative organism in Tularemia, is a relatively rare disease. There are a few radiological clues to elucidate its presence when suspicion arises. There should be strong consideration for Tularemia in the differential of any patient with its classic symptoms, diffuse cervical lymphadenopathy with evidence of necrosis, and enlarged adenoids. Ultrasound may demonstrate suppurative lymphadenopathy suggestive of infection, as in the case presented. CT often will demonstrate the extent of lymphadenopathy. On chest radiography, tularemia pneumonia is often the presenting finding, which may demonstrate bilateral or lobar infiltrates. Additionally, hilar lymphadenopathy and pleural effusions are often associated findings. Cavitory lesions may be present, which are better delineated on CT scan. We present a case of a 7-year-old male who presented with a painful right-sided palpable neck mass for 9 days, who was diagnosed with Tularemia after numerous admissions.

CASE REPORT

CASE REPORT

The authors present a case of a 7-year-old male, with no significant past medical history that presented to the ED with intermittent fever, sore throat, and a painful right-sided palpable neck mass for 9 days. The patient was initially seen in the outpatient setting and was determined to have sore throat with associated adenitis, which was treated with Augmentin ~60mg/kg.

After a 9-day course with poor response, the patient was switched to Cefdinir, during an outpatient visit. Within the following week, the patient continued to have fever up to 102.7° F and an enlarging palpable neck mass, which prompted the mother to bring the patient back to the Emergency Department. Blood work yielded a WBC count of 19,000 (normal 4,500 – 11,000) and CRP of 10 mg/L (normal 0-10mg/L), at which point the patient was admitted and started on IV Clindamycin 13mg/kg/dose q8h.

Workup for CMV, EBV, and Mycoplasma yielded negative results. Ultrasound evaluation [Figure 1a and 1b] demonstrated a hypervascular right neck mass measuring

approximately 3.8 cm x 3.0cm, corresponding to the area of palpable abnormality. A central area of decreased echogenicity within this nodal mass likely represented necrosis. Overlying subcutaneous edema was also present. Numerous other enlarged enhancing adjacent lymph nodes were identified. To a similar extent, these findings were demonstrated on the patients soft tissue neck CT [Figure 2].

Following treatment with IV Clindamycin, the patient was discharged home on PO Ciprofloxacin and Linezolid with the presumed diagnosis of Cat Scratch Disease, despite having a history of a cat bite or scratch. However, the patient was re-admitted to the hospital again, after he was found to have ulceroglandular tularemia after discharge, when the *Francisella* titers yielded positive results. Upon re-admission, a surgical consultation was obtained to perform an incision and drainage of the complex right neck suppurative lymphadenitis. Following successful incision and drainage the patient was given a PICC line, started on Gentamycin 5mg/kg/day IV q8h, and subsequently discharged.

DISCUSSION

Etiology & Demographics:

As Tularemia is a relatively rare disease, we know of few radiological clues to elucidate its presence when suspicion arises. In fact, the CDC reports approximately 200 cases per year in the US. These few cases in the literature are thus quite helpful. *F. tularensis* is a gram-negative coccobacillus, which is responsible for Tularemia. It is found most commonly in North American rabbits and ticks. Transmission may be via inhalation, ingestion, vector associated, or contact with infected tissue. Peak incidence occurs in late spring and early summer, with males and females being equally susceptible to Tularemia. While all ages are equally susceptible to Tularemia; young children and young adults are more likely to participate in activities, which would then make them susceptible to exposure. Risk factors associated with Tularemia involve certain hobbies and/or occupations. These include, but are not limited to: hunting, gardening, landscaping, veterinary medicine, and wildlife work. People living in Arkansas, Missouri, and Oklahoma are at a higher risk due to increased concentration of ticks.

Clinical & Imaging Findings:

In 1990, the journal of Pediatric Radiology published a case of a 3-year-old male with oropharyngeal tularemia [4]. The patient was found to have a normal chest radiograph, though thickening of the retropharyngeal tissues was visualized on x-ray of the lateral cervical territory. A CT scan of the neck with contrast was performed and revealed “enlarged adenoids with inhomogeneous enhancement surrounding areas of low attenuation...retropharyngeal swelling, and moderate bilateral cervical and submandibular adenopathy.” Repeat CT scan of the neck with contrast was performed weeks later and showed multiple areas of low attenuation with rim enhancement within the nodal masses and in the retropharyngeal space. The radiological report goes on to describe “multiloculated masses with low attenuation centers and enhancing septa seen in both posterior cervical nodal chains consistent with abscess formation.” The study ultimately found that there should be strong consideration for Tularemia in the differential in any patient with its classic symptoms, diffuse cervical lymphadenopathy with evidence of necrosis, and enlarged adenoids.

A case report from 2016, in the New England Journal of Medicine, provides insight into an incident of Ulceroglandular Tularemia [1]. The patient was a 58-year old female who presented to the hospital with a skin ulcer on her face, constitutional symptoms, fever, and again, cervical lymphadenopathy. CT of the head and neck was performed and demonstrated diffuse unilateral enlarged lymph nodes. They were localized to the left, lateral to the postauricular, submandibular, cervical chains, and supraclavicular territory. In fact, the left submandibular gland was displaced due to the latter lymphadenopathy. The lymph nodes demonstrated contrast enhancement, hypodensity, and with infiltration of the adjacent fat. It should be noted that chest x-rays are often negative in patients with Tularemia. This was the case in the patient presented (Figure 3).

Radiological analysis of pulmonary tularemia can best be obtained through the seminal case study by Avery and Barnett in 1966 [6]. In it, they evaluated 5 cases from North Carolina Memorial Hospital. Fox hunting and exposure to wild rabbits were among the provided histories from these patients. In case one, chest radiograph showed a uniform left lower lobe infiltrate and evidence of bilateral pleural effusions. Case two's chest x-ray revealed left hilar infiltration with peribronchial streaking and a left upper lobe density. Case three's chest radiograph was significant for left pleural thickening and pleural effusion, with questionable left lower lobe parenchymal involvement. The chest x-ray of case four demonstrated bilateral, multiple, soft, irregular nodular densities and pleural effusion. Finally, chest x-ray was obtained of the patient in case five and revealed consolidation localized to the left upper lobe, with visualization of a tiny cavitory lesion measuring 1 cm.

To summarize, ultrasound may demonstrate lymphadenopathy suggestive of infection. These nodes may be suppurative, as in the case presented. CT often will demonstrate the extent of the lymphadenopathy. On chest radiography, tularemia pneumonia is often the presenting finding, which include bilateral or lobar infiltrates, hilar lymphadenopathy, and/or pleural effusions.

Treatment & Prognosis:

General medical therapy is the mainstay of Tularemia treatment, often involving a prolonged antibiotic course. Streptomycin is considered to be the drug of choice. Relapse rates of up to 50% have been reported when using Chloramphenicol and Tetracycline. *F. tularensis* is naturally resistant to Penicillins and first generation Cephalosporins. Surgical intervention is often not needed, unless ulcerative lesions become superinfected and necessitate incision & drainage.

Tularemia generally has a benign course with a vast majority of patients making a full recovery. It is fatal in approximately 5% of untreated cases and 1% of treated cases.

Differential Diagnoses:

Tularemia should be included in the differential diagnosis for patients with necrotic lymphadenopathy of the neck who may also have lobar infiltrates and hilar lymphadenopathy. These are often nonspecific findings but when noted, should be included as a possible diagnostic consideration. Often, the pulmonary manifestations of Tularemia help differentiate it from the different disease entities in the differential. The main differential considerations for ulceroglandular tularemia include but are not limited to: Lyme disease, lymphogranuloma venereum, mononucleosis, and disseminated mycobacterial disease.

Mononucleosis

Infectious mononucleosis is an infection caused by Epstein-Barr virus, which commonly affects young adults, resulting in fever, sore throat, and enlarged lymph nodes within the neck. Infectious mononucleosis may cause hepatosplenomegaly and splenic rupture, in the setting of trauma. Like Tularemia, patients may demonstrate pronounced

cervical lymphadenopathy. As with all infectious etiologies, increased FDG avidity has been described. Diagnosis of this disease entity is based predominantly on clinical history, serology, and clinical presentation; not on imaging findings.

Lyme Disease

Lyme disease is a relative rare disease entity caused by the bacterium *Borrelia burgdorferi* and is transmitted to humans via a tick-borne vector, much like Tularemia. Often Lyme disease does not have associated imaging findings. Additionally, a joint effusion may be present of the affected joints. On MRI, cranial nerve involvement (most commonly CN7) has been described. Hyperintense lesions within the periventricular white matter and spinal cord have been described on T2WI. FDG PET/CT does not show increased radiotracer uptake. On SPECT imaging, there may be abnormal perfusion defect demonstrated on singular frontal, temporal or parietal lobe.

Lymphogranuloma venereum

Lymphogranuloma venereum is an uncommon sexually transmitted disease caused by *Chlamydia trachomatis*. Computed tomography may demonstrate colonic narrowing or ulceroglandular lymphadenopathy, most commonly within the inguinal regions. As with all infectious etiologies, increased FDG avidity has been described. Diagnosis of this disease entity is based predominantly on clinical history, serology, and clinical presentation; not on imaging findings.

TEACHING POINT

There should be strong consideration for Tularemia in the differential in any patient with the classic symptoms, diffuse cervical lymphadenopathy with evidence of necrosis, and enlarged adenoids. Ultrasound and CT may demonstrate suppurative lymphadenopathy suggestive of infection; while chest radiography may demonstrate bilateral or lobar infiltrates.

REFERENCES

1. Baggett M, Gonzalez G, Bhattacharyya R, et al. Case 4-2016. *New England Journal of Medicine*. 2016;374(6):573-581. PMID: 26863359
2. Dogan S, Ekinci A, Demiraslan H et al. Ultrasonography and contrast-enhanced CT findings of tularemia in the neck. *Diagnostic and Interventional Radiology*. 2016;22(5):430-435. PMID: 27498683
3. Treat J, Hess S, McGowan K, Yan A, Kovarik C. Ulceroglandular Tularemia. *Pediatric Dermatology*. 2010;28(3):318-320. PMID: 20678093
4. Umlas SJaramillo D. Massive adenopathy in oropharyngeal tularemia; C. T. demonstration. *Pediatric Radiology*. 1990;20(6):483-484. PMID: 2392370
5. Sjöstedt A. Special Topic on Francisella tularensis and Tularemia. *Front Microbio*. 2011;2. PMID: 21833327
6. Avery F, Barnett T. Pulmonary Tularemia: A Report of Five Cases and Consideration of Pathogenesis and Terminology. *American Review of Respiratory Disease*. 1996;95(4), 584-591. PMID: 6021119
7. Erdem H, Ozturk-Engin D, Yesilyurt M et al. Evaluation of tularaemia courses: a multicentre study from Turkey. *Clinical Microbiology and Infection*. 2014;20(12):O1042-O1051. PMID: 24975504
8. 1. Mani R, Morton R, Clinkenbeard K. Ecology of Tularemia in Central US Endemic Region. *Curr Trop Med Rep*. 2016;3(3):75-79. PMID: 27525215
9. Robson C. Imaging of Granulomatous Lesions of the Neck in Children. *Radiologic Clinics of North America*. 2000;38(5):969-977. PMID: 11054963
10. Rubin, Sanford A. Radiographic spectrum of pleuropulmonary tularemia. *American Journal of Roentgenology*. 1978 131:2, 277-281.
11. Kim, Eun A., Kyung Soo Lee, Steven L. Primack, Hye Kyung Yoon, Hong Sik Byun, Tae Sung Kim, Gee Young Suh, O. Jung Kwon, and Joungho Han. "Viral Pneumonias in Adults: Radiologic and Pathologic Findings." *RadioGraphics* 22.Suppl_1 (2002): n. pag. Web. 29 Nov. 2016.
12. Fu, XS, LM Guo, K. Lv, and L. Wang. "Sonographic Appearance of Cervical Lymphadenopathy Due to Infectious Mononucleosis in Children and Young Adults." *PubMed.gov*. US National Library of Medicine National Institutes of Health, 16 Sept. 2013. Web. 29 Nov. 2016. <<https://www.ncbi.nlm.nih.gov/pubmed/24290776>>.
13. Gurel, S, Cosgun, Z, Sezgin, S, Gurel, K, A Pictorial Review of MRI Features of Oropharyngeal Tularemia. *Radiological Society of North America 2011 Scientific Assembly and Annual Meeting, November 26 - December 2, 2011 ,Chicago IL*.<http://archive.rsna.org/2011/11010922.html> Accessed November 29, 2016
14. Nieuwenhuis, Rutger F, Ossewaarde, M. Jacobus, Gotz, Hannelore M. "Resurgence of Lymphogranuloma Venereum in Western Europe: An Outbreak of Chlamydia trachomatis Serovar L2 Proctitis in the Netherlands among Men Who Have Sex with Men. *Clinical Infectious Disease*. (2004) 39 (7): 996-1003.
15. Donta, Sam T., Richard B. Noto, and John A. Vento. "SPECT Brain Imaging in Chronic Lyme Disease." *Clinical Nuclear Medicine* 37.9 (2012): n. pag. Web. 29 Nov. 2016.

FIGURES

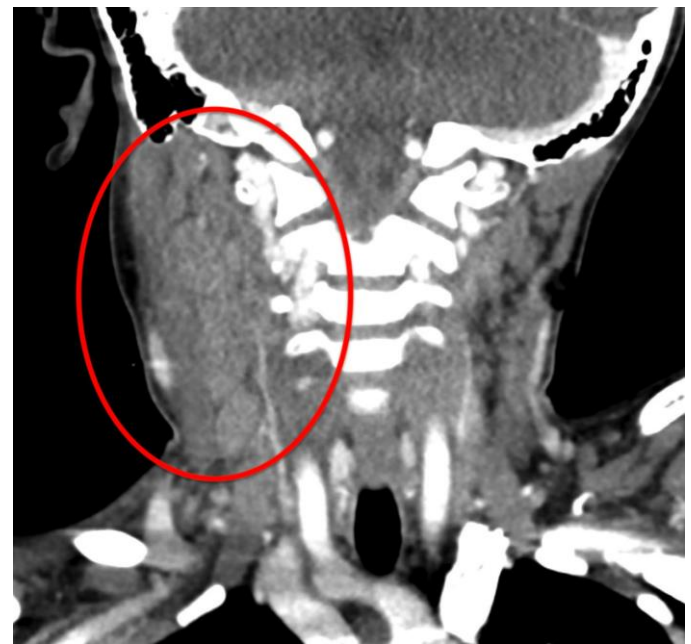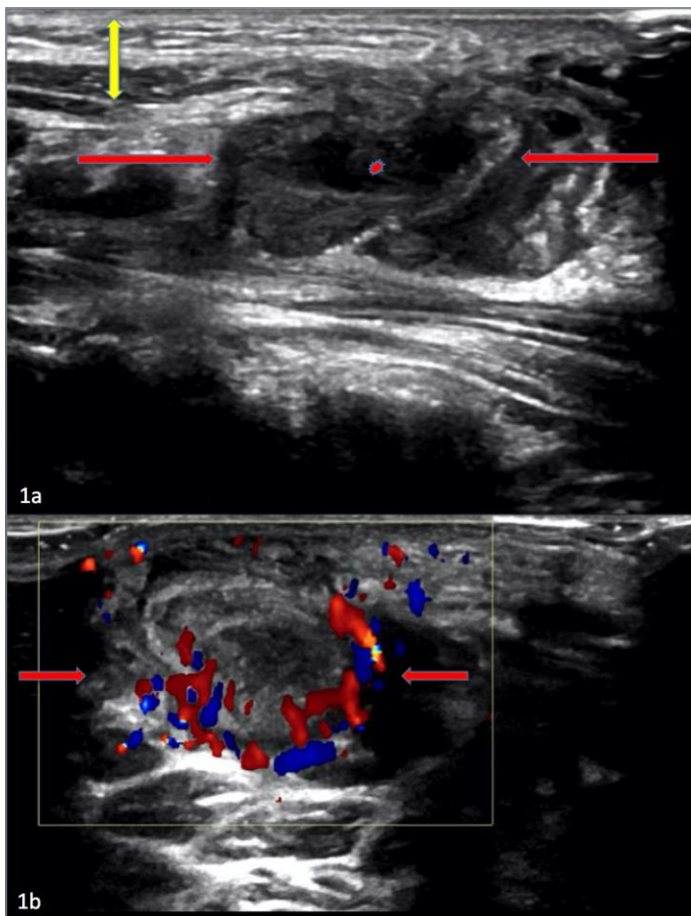


Figure 2: 7 year old male patient: Diagnosis of Ulceroglandular Tularemia

Findings: Contrast enhanced coronal CT image of the neck soft tissues, 24 days prior to the ultrasound images, demonstrate multiple enlarged, enhancing, right cervical lymph nodes [red circle]. Findings were found to be consistent with reactive lymphadenopathy, seen in the setting of Tularemia. Suppurative lymphadenopathy is not demonstrated at this time.

Technique: mA 300, kvp 100, 2.0 mm slice thickness, with 100ml, Omnipaque 350.

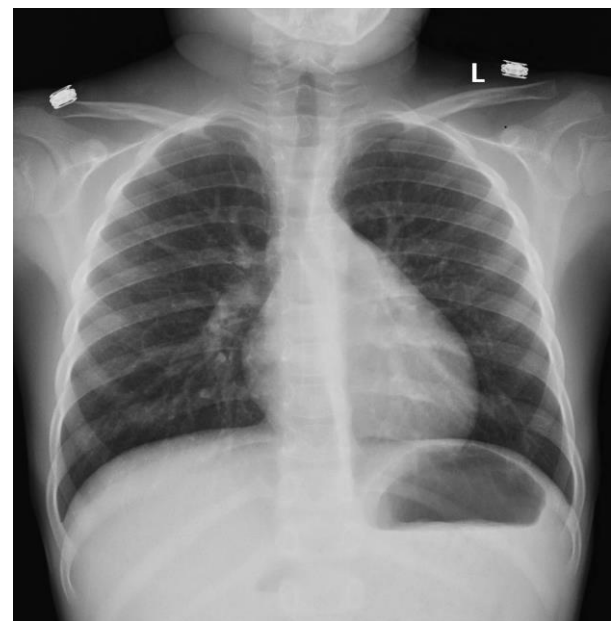


Figure 3: 7 year old male patient: Diagnosis of Ulceroglandular Tularemia

Findings: PA view of the chest demonstrates clear lung fields. Technique: Postero-anterior view of the chest.

Figure 1: 7 year old male patient: Diagnosis of Ulceroglandular Tularemia

Findings: A) Real time sonography of the neck soft tissues demonstrate a right neck mass [between red arrows] measuring approximately 3.8 cm x 3.0 cm, corresponding to the area of palpable abnormality. A central area of decreased echogenicity within this nodal mass [asterisk] likely represents necrosis. Overlying subcutaneous edema [double ended yellow arrow] is also present. Numerous other enlarged adjacent lymph nodes were identified on the real-time exam [not displayed]. Findings were found to be consistent with suppurative nodal masses, seen in the setting of Tularemia.

B) Color Doppler image of the neck soft tissues demonstrate a right neck mass [between red arrows], corresponding to the area of palpable abnormality. There is no flow within the center of this neck mass. Findings were found to be consistent with suppurative nodal masses, seen in the setting of Tularemia.

Technique: Ultrasonography was performed using a linear transducer at 12 MHz. A) B-mode Transabdominal sonogram of the neck soft tissues. B) Power Doppler sonogram of the neck soft tissues. Ultrasonography was performed using a linear transducer at 12 MHz.

Differential Diagnosis	Chest X-ray	US Neck	Chest CT	MRI	Nuclear Medicine
Tularemia	-Patchy subsegmental airspace opacities -Hilar lymphadenopathy -Pleural effusion	-Lymphadenopathy with possible central loss of echogenicity representative of necrosis/abscess formation	-Hilar mass, central necrosis -Enlarged hilar and mediastinal lymph nodes	-Lymphadenopathy: Unilateral, variable morphology from homogenous enhancement to central necrosis and peripheral enhancement -Increased signal and enhancement of adjacent soft tissue	-PET: Highly FDG avid lymphadenopathy indistinguishable from lung cancer
Lyme Disease	-Variable, may range from normal to interstitial disease findings	-Nonspecific lymphadenopathy	N/A	N/A	-SPECT: abnormal perfusion defect involving solitary frontal, temporal or parietal lobe
Lympho-granuloma venereum	-Often normal	-Nonspecific lymphadenopathy	N/A	Rectal: -Diffuse mucosal wall thickening with hyperintense T2 and hypointense T1 weighted images -Perirectal halo of infiltration and lymphadenopathy	N/A
Mononucleosis	-Mediastinal and hilar lymphadenopathy -Rarely interstitial infiltrates	Lymphadenopathy: -Round indistinct margins & heterogeneous, devoid of echogenic hilum	-Mediastinal and hilar lymphadenopathy	-Nonspecific lymphadenopathy	N/A
Disseminated mycobacterial diseases	-Consolidation may be lobar, solitary or multifocal -Pleural effusions may be present	-Lymphadenopathy -If TB: unilateral, cystic necrosis and/or calcifications	-Mediastinal lymphadenopathy -Pulmonary nodules with or without cavitation	N/A	N/A

Table 1: Differential Diagnosis table for Ulceroglandular Tularemia.

Etiology	F. Tularensis, commonly found in North American rabbits and ticks. Transmission may be via inhalation, ingestion, vector associated, or contact with infected tissue.
Incidence	Tularemia is a fairly rare disease entity; only approximately 200 cases of tularemia are diagnosed each year. Peak incidence occurs in late spring and early summer.
Gender Ratio	Both males and females are equally susceptible to tularemia.
Age Predilection	All ages are equally susceptible to Tularemia. Young children and young adults are more likely to participate in activities, which would then make them susceptible to exposure.
Risk Factors	Risk factors associated with Tularemia involve certain hobbies and/or occupations. These include, but are not limited to hunting, gardening, landscaping, veterinary medicine, and wildlife work. People living in Arkansas, Missouri, and Oklahoma are at a higher risk due to increased concentration of ticks.
Treatment	General medical therapy is the mainstay of Tularemia treatment, often involving a prolonged antibiotic course. Streptomycin is considered to be the drug of choice. Relapse rates of up to 50% have been reported when using Chloramphenicol and Tetracycline. F. tularensis is naturally resistant to Penicillins and first generation Cephalosporins. Surgical intervention is often not needed unless ulcerative lesions become superinfected and necessitate incision & drainage.
Prognosis	Tularemia generally has a benign course with a vast majority of patients making a full recovery. Tularemia is fatal in approximately 5% of untreated cases and 1% of treated cases.
Image Findings	Ultrasound may demonstrate lymphadenopathy suggestive of infection. These nodes may be suppurative, as in the case presented. CT often will demonstrate the extent of the lymphadenopathy. On Chest radiography, tularemia pneumonia is often the presenting finding, which include bilateral or lobar infiltrates. Hilar lymphadenopathy and pleural effusions are often associated findings. Cavitory lesions may be present, which are better delineated on CT scan.

Table 2: Summary table for Ulceroglandular Tularemia.

ABBREVIATIONS

- CDC: Center for Disease Control
- cm: Centimeters
- CMV: Cytomegalovirus
- CN: Cranial nerve
- CRP: C-reactive protein
- CT: Computed Tomography
- EBV: Epstein-Barr Virus
- ED: Emergency Department
- F: Fahrenheit
- IV: Intravenous
- Kg: Kilogram
- kvp: Peak kilovoltage
- mA: Milliampere
- Mg: Milligram
- MHz: Megahertz
- mL: Milliliters
- MRI: Magnetic Resonance Imaging
- N/A: Not Applicable
- PET: Positron Emission Tomography
- PICC: Peripherally Inserted Central Catheter
- PO: Per os
- T1WI: T1-Weighted Imaging
- T2WI: T2-Weighted Imaging
- US: Ultrasound
- WBC: White Blood Count

KEYWORDS

Tularemia; Rabbits; Lymphadenopathy; Suppurative; Ulceroglandular; Ultrasound; Computer Tomography; Francisella; Tularensis

Online access

This publication is online available at:
www.radiologycases.com/index.php/radiologycases/article/view/2983

Peer discussion

Discuss this manuscript in our protected discussion forum at:
www.radiolopolis.com/forums/JRCR

Interactivity

This publication is available as an interactive article with scroll, window/level, magnify and more features.
 Available online at www.RadiologyCases.com

Published by EduRad



www.EduRad.org