

Isolated Spongy Urethral Rupture from Abrupt Coital Distractive Force

Brian J McArdle^{1*}, Mark A Wille¹, Courtney MP Hollowell¹

1. Division of Urology, Cook County Health and Hospitals System, Chicago, IL, USA

* **Correspondence:** Brian J. McArdle, DO, MBA, 1900 W. Polk St. Suite 465, Chicago, IL 60612, USA
(✉ bmcardle@cookcountyhhs.org)

Radiology Case. 2017 Feb; 11(2):23-27 :: DOI: 10.3941/jrcr.v11i2.2907

ABSTRACT

The classic presentation of penile fracture is a cracking or snap sound, with sharp pain, immediate detumescence, swelling, deformation and ecchymosis. A penile fracture involves rupture of the tunica albuginea of one or both corpora cavernosa. Concomitant urethral rupture is reported to occur in 10% to 20% of penile fracture cases. Isolated urethral injury without penile fracture is extremely rare. We report the first case of isolated pendulous urethral rupture from an abrupt coital distractive force. We include a literature review and discussion of isolated urethral trauma secondary to sexual intercourse. Retrograde urethrography rendered a stunning clinical image which was integral to the diagnosis and management of this patient's injury.

CASE REPORT

CASE REPORT

A 30-year-old heterosexual male had immediate pain with urethral hemorrhage and detumescence after sudden withdrawal from vaginal intercourse in the reverse position. The patient described a ventral penile “pinprick” sensation as he withdrew while his partner contracted her pelvic floor muscles. He immediately noticed “blood filling the condom,” and presented shortly thereafter. At initial assessment, urinalysis was initially not available. His medical, surgical, family, and social histories were unremarkable. Initial inspection revealed uncircumcised phallus, with peri-meatal ecchymosis and urethrorrhagia which was exacerbated by voiding. There was no penile or perineal ecchymosis and no structural deformity. There was a tender pendulous urethral nodule at location of pain onset (Figure 1).

Under the suspicion of penile fracture with concomitant urethral rupture, retrograde urethrography was performed. Initial imaging demonstrated contrast extravasation with a small filling defect along the ventral aspect of the pendulous urethra consistent with the urethral nodule that was palpable on physical exam. A delayed exposure revealed intravasation

of contrast into the penile venous architecture via the spongy tissue of the corpus spongiosum. It also demonstrated preservation of the deep penile fascia overlaying the corpus spongiosum (Figure 2, 3).

The patient underwent flexible urethroscopy which confirmed a crescentic urethral rupture between 3 o'clock to 9 o'clock positions with clear visualization of spongy urethral tissue without obvious extension into corporal bodies. A sub-coronal circumferential incision was made and the penis was degloved to expose the ventral pendulous urethra. The tunica albuginea surrounding the corporal bodies was grossly intact and the deep penile fascia surrounding the corpus spongiosum was also confirmed to be intact. We identified the urethral nodule as a spongiosal hematoma which corresponded with the mucosal and spongiosal rupture on flexible urethroscopy. The urethral defect was poorly approximated in situ due to urethral hematoma. The hematoma was debrided and primary repair was performed with 4-0 monocryl suture. The repair was inspected and proved water tight with flexible urethroscopy. The circumcision was completed and the incision was closed with interrupted 3-0 chromic sutures. The patient was discharged with 16 French Foley catheter on postoperative day

one. Four weeks later, his repeat retrograde urethrogram was negative. The patient denied voiding difficulty or erectile dysfunction at his 6 week visit. Unfortunately, the patient was subsequently lost to follow-up.

DISCUSSION

Etiology & Demographics:

Isolated urethral injury without penile fracture during coitus is extremely rare with six male patients described in the literature [8, 9]. Mohapatra et al. described three cases of fossa navicularis injury in the reverse position [8]. Mendonça et al. reported one case of fossa navicularis injury in the reverse position [10]. Patel et al. reported an isolated urethral injury of the bulbar urethra in missionary position [11]. Chiu et al. reported one case of isolated urethral injury of the bulbar urethra in the reverse position [9]. All prior reports described the mechanism of injury as a compressive, buckling force; and none involved the pendulous urethra. In contrast, the mechanism of injury in this case involved complex vector forces: longitudinal distraction of the urethra during withdrawal, dorsal penile deflection exerted by the anterior vaginal wall, and posterior vaginal wall counter-force exerted upon the penile base. The summation of these forces exceeded the tensile strength of the urethral mucosa, causing rupture, with preservation of the deep penile fascia overlaying the corpus spongiosum. This is the first case of isolated pendulous urethral injury from an abrupt coital distractive force, and the seventh case of isolated male urethral injury in the literature to date.

Clinical & Imaging Findings:

A penile fracture involves rupture of the tunica albuginea of the corpora cavernosa. The classic presentation of penile fracture is a cracking or snap sound, associated with sharp pain, detumescence, swelling, deformation, ecchymosis, and hematoma formation [1]. Hematuria, blood at the meatus or difficult voiding should raise concern for concomitant urethral injury [2]. Concomitant urethral rupture has been reported from 10% to 20% in all penile fracture cases [3]. The most common mechanism of injury is a compressive or shearing force with tunical rupture of the contralateral corpus cavernosum. Generally, force can be correlated to the degree of injury and concomitant urethral injury is more greatly associated with bilateral corporal injury compared to unilateral corporal injury [2, 4]. Furthermore, the site of urethral injury usually corresponds to that of the corporal injury. Retrograde urethrography allows for early identification of urethral injury as demonstrated by loss of smooth contour of urethra with extravasation of contrast agent.

Differential Diagnoses:

From an anatomical aspect, we hypothesize a greater risk of distractive injury to the pendulous urethra due to its fixation to the corpora relative to the bulbar urethra. The bulbar urethra

is more prone to injury resulting from compressive forces against the inferior pubis or as a byproduct of concomitant corporal rupture. In the present case, the injury involved the fixed pendulous urethra after sudden withdrawal from the reverse position with vaginal intercourse.

Isolated urethral rupture sparing deep penile fascia

Retrograde urethrography may demonstrate extravasation from the urethra into the spongy tissue of corpus spongiosum with back-filling of the penile venous architecture. There should not be any opacification of the corporal bodies. Ultrasonography may demonstrate a hematoma.

Isolated urethral rupture involving deep penile fascia

Retrograde urethrography may demonstrate extravasation from urethra into the penile soft tissue with diffuse irregular opacification around entire penis. Ultrasonography may demonstrate hematoma. MRI may show hematoma on T2WI.

Penile fracture with concomitant urethral rupture

Retrograde urethrography may demonstrate extravasation from urethra into the corpora with partial opacification of involved corporal body. Ultrasonography may demonstrate hematoma. MRI may demonstrate discontinuity of the low signal intensity of the tunica albuginea on T1WI and T2WI sequences.

Treatment & Prognosis:

In cases of suspected penile fracture, immediate exploration and repair is advised for optimal functional outcomes. In cases of suspected urethral injury, retrograde urethrography is essential for diagnosis and management. Magnetic resonance imaging has also been demonstrated to be very accurate at diagnosing penile fracture [5]. Despite its accuracy, the relative cost and time required continue to limit the utilization of MRI in this setting. Ultrasonography has been utilized to evaluate for penile fracture in several case reports however it is operator dependent and more data is needed before we can rely on it as a modality to rule-out penile fracture. For partial urethral injury, conservative management with diverting cystostomy or prolonged urethral catheterization with delayed treatment if stricture develops has been described [6]. However, recent literature generally advocates for early surgical reapproximation of urethral injury as this favors fewer complications and better functional outcomes [2, 7]. Potential delayed complications would include urethral stricture, urethrocutaneous fistula, or erectile dysfunction.

TEACHING POINT

Providers should maintain high index of suspicion for urethral injury in all cases of penile trauma. Retrograde urethrography allows for early identification of urethral injury and appropriate surgical intervention to reduce strictures or urethrocutaneous fistulas.

REFERENCES

1. Tsang T, Demby AM. Penile fracture with urethral injury. J Urol. 1992;147:466-8. PMID: 1732623

2. El-Assmy A, El-Tholoth HS, Mohsen T, Ibrahiem el HI. Long-term outcome of surgical treatment of penile fracture complicated by urethral rupture. J Sex Med. 2010;7:3784-8. PMID: 20059653

3. Bertero EB, Campos RSM, Mattos Jr D. Penile fracture with urethral injury. Braz J Urol. 2000;26:295-7. ISSN 0100-6991

4. Fergany AF, Angermeier KW, Montague DK. Review of Cleveland clinic experience with penile fracture. Urology. 1999;54:352-5. PMID: 10443737

5. Guler I, Odev K, Kalkan H, Simsek C, Keskin S, Kilinc M. The value of magnetic resonance imaging in the diagnosis of penile fracture. International Braz J Urol. 2015, 41 (2): 325-8 PMID: 26005975

6. Maharaj D, Naraynsingh V. Fracture of the penis with urethral rupture. Injury. 1998;29:483. ISSN 0500-7208

7. Raheem AA, El-Tatawy H, Eissa A, Elbahnasy AH, Elbendary M. Urinary and sexual functions after surgical treatment of penile fracture concomitant with complete urethral disruption. PMID: 24704925

8. Mohapatra TP, Kumar S. Reverse coitus: mechanism of urethral injury in male partner. J Urol. 1990;144:1467-8. PMID: 2231946

9. Chiu HC, Chang CH, Hsieh PF. Isolated Urethral Rupture Related to Sexual Intercourse in Male and Literature Review. Urology Journal. 2015 Dec 23;12(6):2462-4. PMID: 26706747

10. De Mendonca RR, Bicudo M C, Sakuramoto PK, Bezerra C A, Pompeo A C, Wroclawski ER. Isolated anterior urethral trauma in man after coitus: a case report. Einstein. 2009; 7(4 Pt 1):503-5. PMID: 40885724

11. Patel A, Kotkin L. Isolated urethral injury after coitus-related penile trauma. J Trauma. 2010;68:E89-90. PMID: 20386267

FIGURES

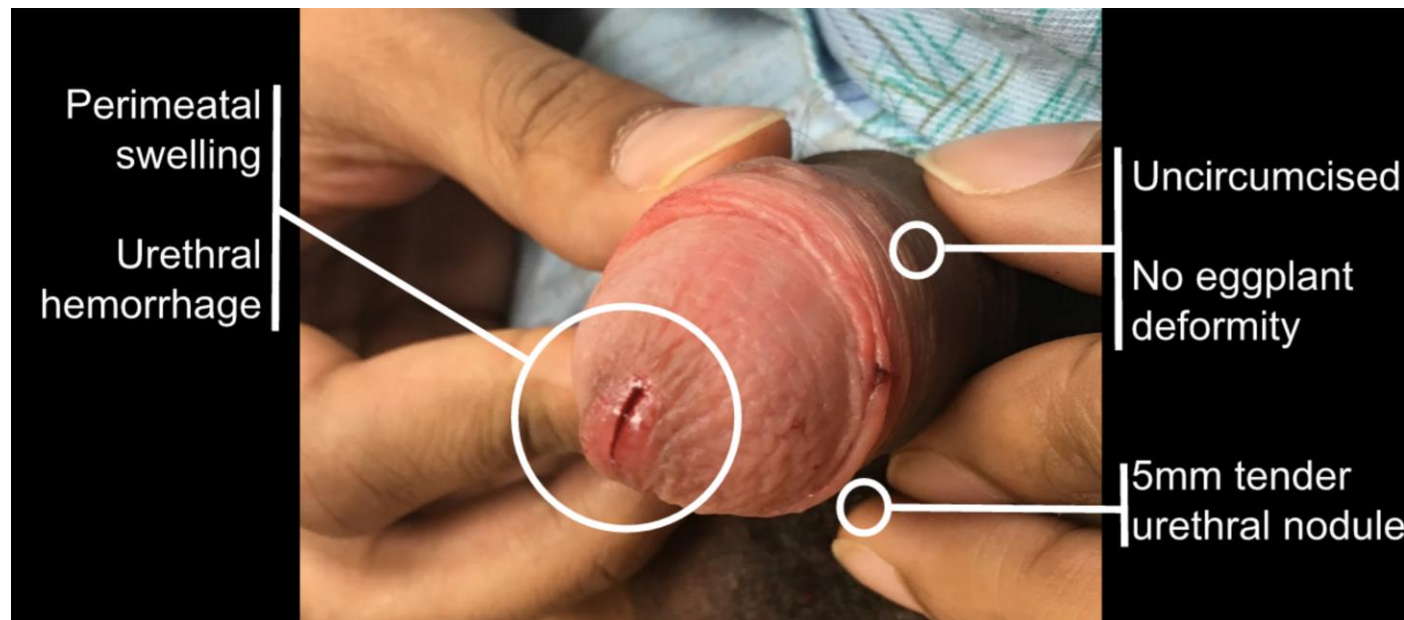


Figure 1: 30-year-old heterosexual male with isolated pendulous urethral rupture from abrupt distractive force physical exam findings.
FINDINGS: Physical exam reveals uncircumcised phallus, with peri-meatal ecchymosis and bloody urethral discharge (circled). There is no penile or perineal ecchymosis and no structural deformity.

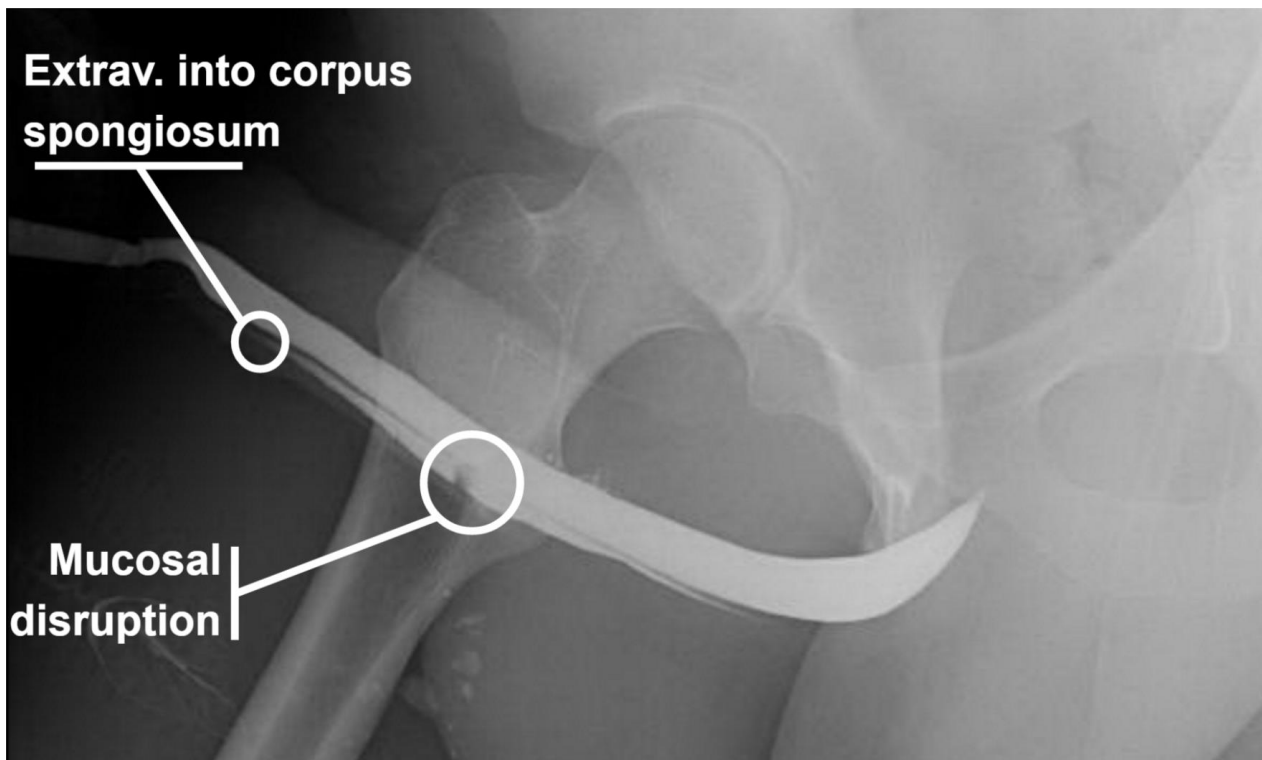


Figure 2: 30-year-old heterosexual male with isolated pendulous urethral rupture from abrupt distractive force retrograde urethrography findings.

FINDINGS: Retrograde urethrography reveals contrast extravasation with small filling defect along the ventral aspect of the pendulous urethra consistent with the urethral nodule palpated on physical exam.

TECHNIQUE: X-Ray retrograde urethrography in oblique position with iodinated radiocontrast medium

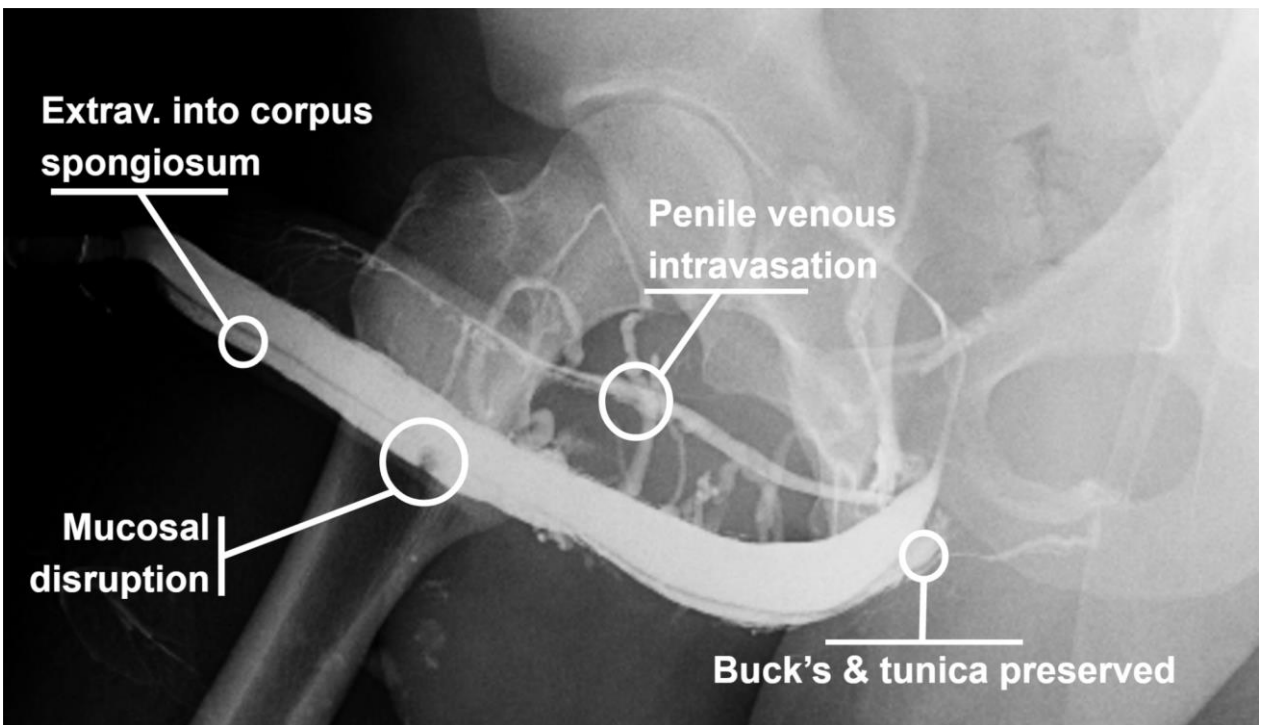


Figure 3: 30-year-old heterosexual male with isolated pendulous urethral rupture from abrupt distractive force delayed retrograde urethrography findings.

FINDINGS: Retrograde urethrography with delayed exposure reveals intravasation of contrast into the penile venous architecture via extravasation into spongy tissue of the corpus spongiosum. It also demonstrates preservation of the deep penile fascia overlaying the corpus spongiosum (circled).

TECHNIQUE: X-Ray retrograde urethrography in oblique position with iodinated radiocontrast medium

Etiology	Abrupt distractive force during intercourse overwhelming tensile strength of urethral mucosa
Incidence	Seven reported cases of isolated urethral rupture from sexual intercourse. Solitary case of pendulous urethral rupture from intercourse.
Gender ratio	Condition occurs in males only
Age predilection	Inadequate data
Risk factors	Reverse position (6 of 7 reported cases)
Treatment	Urgent penoscrotal exploration with primary repair of urethral rupture over catheter with or without circumcision
Prognosis	Risk of urethral stricture and fistula formation reduced by primary repair at time of trauma.
Imaging findings	Extravasation from urethra into spongy tissue of corpus spongiosum with filling of the penile venous architecture. No opacification of corporal bodies.

Table 1: Summary table of distractive penile urethral injury.

	Potential Findings on Retrograde Urethrography
Isolated urethral rupture sparing deep penile fascia	<ul style="list-style-type: none"> • Retrograde urethrography may demonstrate extravasation from the urethra into the spongy tissue of corpus spongiosum with back-filling of the penile venous architecture. There should not be any opacification of the corporal bodies. • Ultrasonography may demonstrate a hematoma.
Isolated urethral rupture involving deep penile fascia	<ul style="list-style-type: none"> • Retrograde urethrography may demonstrate extravasation from urethra into the penile soft tissue with diffuse irregular opacification around entire penis. • Ultrasonography may demonstrate hematoma. • MRI may show hematoma on T2WI.
Penile fracture with concomitant urethral rupture	<ul style="list-style-type: none"> • Retrograde urethrography may demonstrate extravasation from urethra into the corpora with partial opacification of involved corporal body. • Ultrasonography may demonstrate hematoma. • MRI may demonstrate discontinuity of the low signal intensity of the tunica albuginea on T1WI and T2WI sequences.

Table 2: Differential diagnosis table for penile urethral injury.

ABBREVIATIONS

MRI - Magnetic Resonance Imaging
T2WI - T2 Weighted Image
T1WI - T1 Weighted Image

KEYWORDS

Isolated Urethral Rupture; Penile Trauma; Coitus Interruptus; Coital; Extravasation; Retrograde Urethrography; Distractive Force; Pendulous Urethra; Corpus Spongiosum

Online access

This publication is online available at:
www.radiologycases.com/index.php/radiologycases/article/view/2907

Peer discussion

Discuss this manuscript in our protected discussion forum at:
www.radiolopolis.com/forums/JRCR

Interactivity

This publication is available as an interactive article with scroll, window/level, magnify and more features.
Available online at www.RadiologyCases.com

Published by EduRad



www.EduRad.org