

# Amyand's Hernia: A Case Report

Haris N. Shekhani<sup>1\*</sup>, Saurabh Rohatgi<sup>1</sup>, Tarek Hanna<sup>1</sup>, Jamlík-Omari Johnson<sup>1</sup>

1. Division of Emergency Radiology, Emory University, Atlanta, GA 30308, USA

\* **Correspondence:** Haris Naseem Shekhani, Emory Department of Radiology and Imaging Sciences, Division of Emergency Radiology, Emory University Midtown Hospital, 550 Peachtree St NE, Atlanta, GA 30308, USA

✉ [haris.shekhani@emory.edu](mailto:haris.shekhani@emory.edu)

Radiology Case. 2016 Dec; 10(12):7-11 :: DOI: 10.3941/jrcr.v10i12.2833

## ABSTRACT

Amyand's hernia is a rare and atypical hernia characterized by the herniation of the appendix into the inguinal sac. This hernia may be present without symptoms until inflammation of the appendix may lead to incarceration, strangulation, necrosis, perforation or rupture. Early symptoms include tenderness and inguinal swelling which may be misdiagnosed as a strangulated hernia. This condition can be difficult to diagnose clinically. Ultrasound and Computed Tomography may aid in diagnosis. This article presents a rare case of Amyand's hernia followed by a discussion of the epidemiology, diagnosis, imaging details and treatment options for this condition.

## CASE REPORT

### CASE REPORT

A 47-year-old male was admitted to a trauma service with history of a ground level fall at work. Computed tomography (CT) showed bilateral inguinal hernias with small bowel obstruction. A normal appearing appendix was noted extending into the right inguinal canal (figure 1-3). The patient was initially managed non-operatively, but was subsequently taken for exploratory laparotomy due to failure of conservative management. Operatively, there was chronic scarring and adhesion formation in the right lower quadrant, presumably from chronic incarceration within the right inguinal hernia. Lysis of adhesions was performed around the cicatrix around distal ileum just proximal to ileo-cecal valve. On the left, sigmoid colon was reduced from the left inguinal hernia.

### DISCUSSION

#### Etiology & Demographics:

The rare presence of the appendix in an inguinal hernia sac is known as Amyand's hernia [1-6]. This condition was first described and treated in 1735 by Claudius Amyand [1-5, 7-9]. It is most often found incidentally during hernia repair surgery [2].

Amyand's hernia accounts for between 0.4 and 1% of all inguinal hernias, and appendicitis in conjunction with Amyand's hernia accounts for 0.1% of all cases of appendicitis [3, 4]. Amyand's hernia occurs in 11% of patients with Meckel's diverticulum [2] and is three times more common in the pediatric population, due to the patency of the processus vaginalis [10]. In the pediatric population, the prevalence is 1% and occurs more often in males than females [2, 3]. Amyand's hernia typically presents on the right side. This is likely due to the normal anatomic position of the appendix [4, 7]. Although it is rare, left sided Amyand's hernias do occur and have thought to be the result of a mobile or floppy cecum, intestinal malrotation or situs inversus [1-3, 10].

The pathophysiology of Amyand's hernia is uncertain, though a few theories have been proposed. One theory by Michalinos et al. suggests a congenital herniation of the appendix due to the combination of an existing patent vaginal process and a fibrous connection between the appendix and the testes. The authors report that Amyand's hernia has been seen in neonates and 2 premature twins [3]. Another theory points to the congenital laxity of the right colon since cases of this herniation contain the caecum in addition to the appendix [7].

It is also unclear if there is a causal relationship between the herniation of the appendix and the appendicitis. Most investigators believe inflammatory swelling may lead to incarceration and subsequent impaired blood supply and bacterial overgrowth [8].

#### Clinical & Imaging Findings:

The appendix may remain in the hernia sac without symptoms throughout a patient's lifetime [3]. When symptoms do appear, they mimic an incarcerated hernia including crampy and episodic pain [3]. On physical examination there is tenderness and swelling in the inguinal or inguinoscrotal region [1, 3]. A mass-like appearance in the inguinal region may exist [3]. Rarely necrotizing fasciitis complicates Amyand's hernia [3].

It is clinically difficult to differentiate Amyand's hernia from an inguinal hernia due to their similar presentations. Imaging tests such as ultrasound (US) and computed tomography (CT) aid in distinguishing the pathologies [1, 2]. US is the initial diagnostic modality of choice in the pediatric population [1]. US shows a blind-ended tubular structure with thickened walls in connection with the cecum inside the hernia sac. CT allows direct visualization of the appendix inside the inguinal canal [3].

#### Treatment & Prognosis:

Controversy exists regarding the best treatment for Amyand's hernia. Traditionally, appendectomy with simultaneous hernioplasty has been performed prophylactically in order to prevent repeat herniation and possible future irritation, which may lead to appendicitis [1, 2, 3]. In the absence of inflammation an elective hernioplasty should be performed +/- reduction or appendectomy. The decision to keep or remove the appendix is based on the patient's age, life expectancy and risks of developing acute appendicitis. The pediatric population has a higher risk of suffering from acute appendicitis when compared to the middle age or elderly population [10]. Although the incidence of appendicitis is greater with Amyand's hernia than with the routine position of the appendix, Cigsar et al. reported that none of the 28 of 46 pediatric patients (<3.5 yrs of age) who underwent appendiceal reduction and hernioplasty presented with repeat herniation or inflammation of the appendix to date [1]. Additional, more recent, sources claim that there is no additional benefit to a prophylactic appendectomy and advocate surgery in the setting of inflammation, perforation or gangrene [1,3,11]. The degree of infection, inflammation, and perforation determine whether mesh repair is used. Typically, a mesh should not be used in circumstances of inflammation (appendicitis) because it can

cause infection, recurrence of hernia, or mesh sepsis [3,12, 13]. Recurrent herniation is also a reason to perform mesh repair [3]. When Amyand's Hernia is treated appropriately, the morbidity and mortality match the typical inguinal hernia [3].

#### Differential Diagnoses:

Differential Diagnoses include strangulated hernia, inguinal adenitis, orchiepididymitis, incompletely descended testes, acute epididymitis, testicular tumor with hemorrhage, and acute hydrocele, acute appendicitis, and Richter's hernia (parietal strangulation) [3, 6, 8]. Strangulated hernia on imaging shows a blind-ended tubular structure with bowel wall thickening, severe fat stranding, mesenteric engorgement and extraluminal fluid confined to hernia sac. Richter's hernia shows bowel loop positioned in the middle of the abdominal wall with a fascial defect with bowel entering the hernia sac. Orchiepididymitis and acute epididymitis exhibit inflammation of the epididymis and/or testis. Lastly, an incompletely descended testis on imaging will show a mass along the course of testicular descent, most commonly at the level of the inguinal canal.

#### TEACHING POINT

Amyand's hernia is a rare and atypical hernia that is difficult to diagnose clinically characterized by the herniation of the appendix into the inguinal sac. CT and US are particularly helpful in making an accurate diagnosis. Because there is no additional benefit to prophylactic surgery, surgeons should evaluate the state of the appendix before proceeding with an appendectomy, hernioplasty and mesh installation.

#### REFERENCES

1. Cigsar EB, Karadag CA, and Dokucu AI. Amyand's hernia: 11 years of experience. *J Pediatr Surg*, 2015. PMID: 26707425.
2. Tsang WK, et al. Acute appendicitis complicating Amyand's hernia: imaging features and literature review. *Hong Kong Med J*, 2014. 20(3): p. 255-7. PMID: 24914078.
3. Michalinos A, Moris D, and Vernadakis S. Amyand's hernia: a review. *The American Journal of Surgery*, 2014. 207(6): p. 989-995. PMID: 24280148.
4. Singal R, et al. An incarcerated appendix: report of three cases and a review of the literature. *Hernia*, 2012. 16(1): p. 91-7. PMID: 20740297.
5. Inan I, et al. Amyand's hernia: 10 years' experience. *The Surgeon*, 2009. 7(4): p. 198-202. PMID: 19736884.
6. D'Alia C, et al. Amyand's hernia: case report and review of the literature. *Hernia*, 2003. 7(2): p. 89-91. PMID: 12820031.
7. Ranganathan G, Kouchupapy R, and Dias S. An approach to the management of Amyand's hernia and presentation of an

interesting case report. *Hernia*, 2011. 15(1): p. 79-82. PMID: 20039085.

8. Bhide SS. Amyand's hernia. *Indian J Pediatr*, 2009. 76(8): p. 854-5. PMID: 19802555.

9. Logan MT, Nottingham JM. Amyand's hernia: a case report of an incarcerated and perforated appendix within an inguinal hernia and review of the literature. *Am Surg*, 2001. 67(7): p. 628-9. PMID: 11450774.

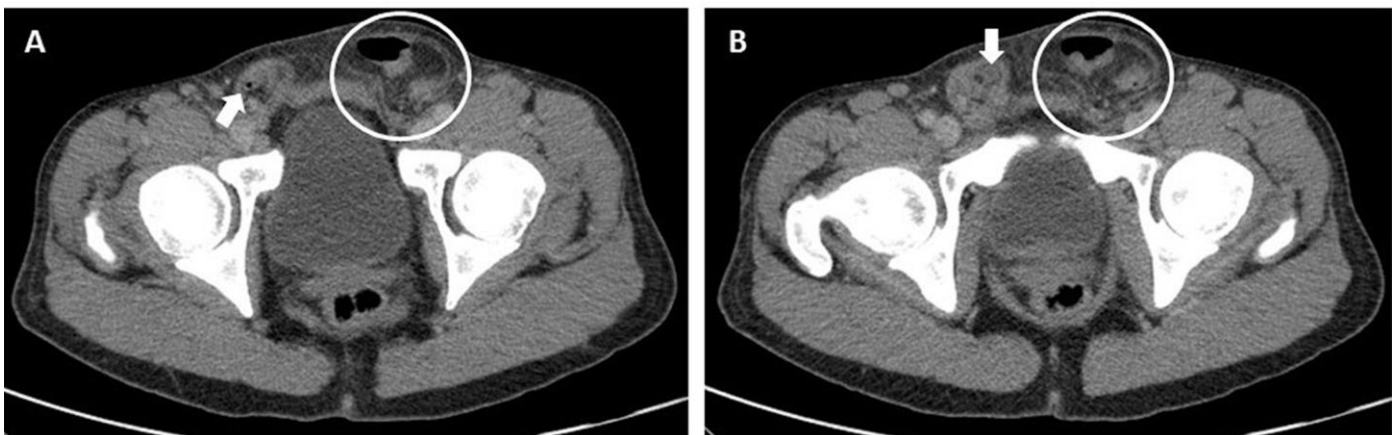
10. Losanoff JE, Basson MD. Amyand hernia: a classification to improve management. *Hernia*. 2008;12(3):325-6. PMID: 1214637.

11. Sadhu J, Samuel VM, Kodiatte T, Gaikwad P. Amyand's Hernia: Case Report -Current Dilemma in Diagnosis and Management. *J Clin Diagn Res*. 2015;9(2):PD03-4. PMID: 25859489.

12. Ivanschuk G, et al. Amyand's hernia: a review. *Med Sci Monit*, 2014. 20: p. 140-6. PMID: 24473371.

13. Singal R, Gupta S. "Amyand's Hernia" – Pathophysiology, Role of Investigations and treatment. *Maedica (Buchar)*. 2011;6(4):321-7. PMID: 22879848.

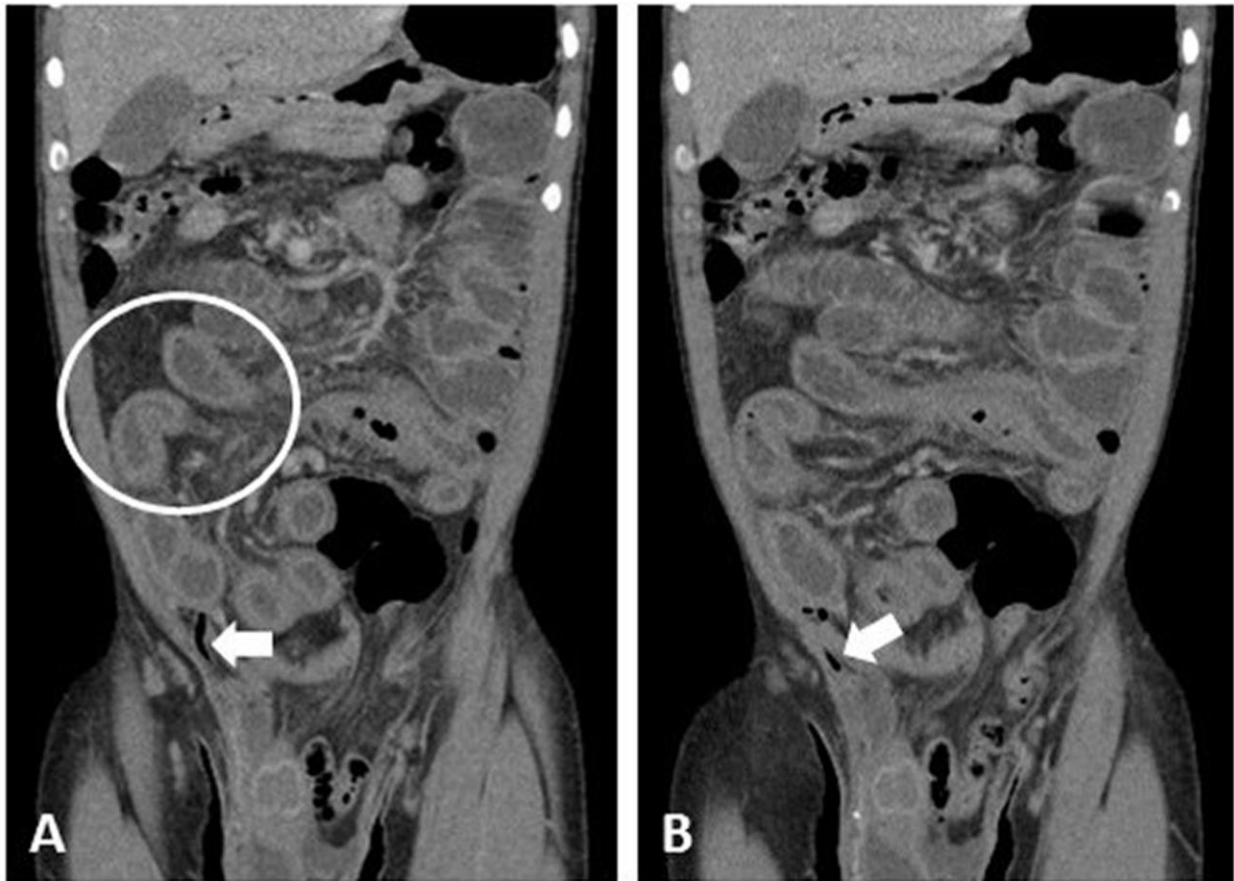
FIGURES



**Figure 1:** 47 year old male with right sided Amyand's hernia.

Findings: The appendix extends into the small right inguinal hernia (arrow; A, B) illustrated on these contrast enhanced axial CT images. Large bowel containing left inguinal hernia is marked with a circle.

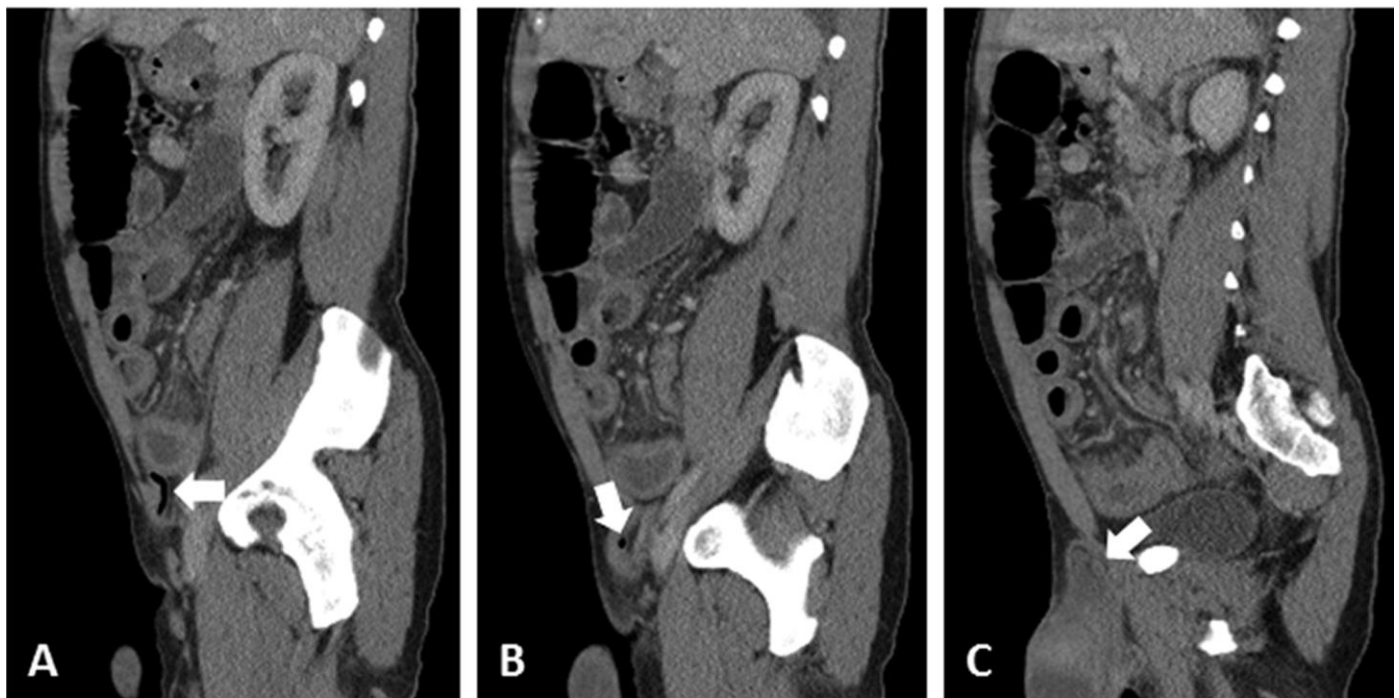
Technique: Axial contrast enhanced CT images of lower abdomen.



**Figure 2:** 47 year old male with right-sided Amyand's hernia.

Findings: A) The appendix is air filled, and shown near its entrance into the right inguinal hernia (arrow) on coronal contrast enhanced CT. White circle illustrates abnormal small bowel with wall thickening and dilatation, compatible with changes of small bowel obstruction. B) The air filled appendix just following its entrance into the right inguinal hernia.

Technique: Coronal contrast enhanced CT images of lower abdomen.



**Figure 3:** 47 year old male with right-sided Amyand's hernia.

Findings: Sagittal contrast enhanced CT images from lateral (A) to medial (C) show progression of the appendix as it extends into the right inguinal hernia. Technique: Sagittal contrast enhanced CT images of lower abdomen.

<b>Etiology</b>	Thought to be the result of a mobile or floppy cecum, intestinal malrotation or situs inversus [1-3, 10]. The pathophysiology of Amyand's hernia is uncertain, though theories proposed include an accidental herniation of the appendix, a congenital laxity of the right colon or some factor of both [1]. Michalinos et al. points to a congenital factor, noting that Amyand's hernia has been seen in neonates and a set of premature twins [3].
<b>Incidence</b>	Amyand's hernia accounts for between 0.4 and 1% of all inguinal hernias, and appendicitis in conjunction with Amyand's hernia accounts for 0.1% of all cases of appendicitis [3, 4]. 11% occurs in patients with Meckel's diverticulum [2] and is three times more common in the pediatric population, due to the patency of the processus vaginalis [10].
<b>Gender Ratio</b>	In the pediatric population, the prevalence is 1% and occurs more often in males than females [2, 3].
<b>Age predilection</b>	Pediatric population [2, 3].
<b>Risk factors</b>	Acute appendicitis and incarcerated hernia simultaneously.
<b>Treatment</b>	Controversial, appendectomy with simultaneous hernioplasty has traditionally been performed
<b>Prognosis</b>	When Amyand's Hernia is treated appropriately, the morbidity and mortality match the typical inguinal hernia [3].
<b>Findings on imaging</b>	US shows a blind-ended tubular structure with thickened walls in connection with the cecum inside the hernia sac. CT allows direct visualization of the appendix inside the inguinal canal [3].

**Table 1:** Summary table of Amyand's Hernia

Differential Diagnoses	CT Findings	US Findings
<b>Amyand's hernia</b>	Blind ending tubular structure arising from caecum and extending into inguinal sac	Blind-ended tubular structure with thickened walls in connection with the cecum inside the hernia sac
<b>Strangulated hernia</b>	Bowel wall thickening, severe fat stranding, mesenteric engorgement, and extraluminal fluid confined to the hernia sac	Thickening of the hernial sac, the presence of hyperechoic fat, fluid within the sac, and thickening of the bowel wall in bowel-containing hernias
<b>Richter's hernia</b>	Bowel loop positioned in the middle of the abdominal wall	Fascial defect is seen as well as bowel entering the hernia sac
<b>Orchiepididymitis</b>	Imaging will show inflammation of the epididymis and/or testis	
<b>Incompletely descended testis</b>	Oval soft-tissue mass along the expected course of testicular descent	Demonstrates normal low-resistance pattern of flow most commonly at the level of the inguinal canal
<b>Acute epididymitis</b>	Signs of inflammatory stranding around the spermatic cord, with or without thickening of the inguinal canal	Enlarged epididymis with a hypoechoic, hyperechoic, or heterogeneous echotexture (gray-scale ultrasonography) and increased blood flow
<b>Acute hydrocele</b>	Fluid-density hydrocele surrounded by the parietal layer of the tunica albuginea	Anechoic fluid collection between the parietal and visceral layers of the tunica albuginea, surrounding the testicle. It is avascular on Doppler evaluation

**Table 2:** Differential diagnoses table for Amyand's Hernia

#### ABBREVIATIONS

CT - Computed tomography  
US - Ultrasound

#### KEYWORDS

Amyand's hernia; appendix; inguinal hernia; hernia; amyand's; CT; case report; mesh repair; vermiform appendix; sac; hernioplasty; appendectomy

#### Online access

This publication is online available at:  
[www.radiologycases.com/index.php/radiologycases/article/view/2833](http://www.radiologycases.com/index.php/radiologycases/article/view/2833)

#### Peer discussion

Discuss this manuscript in our protected discussion forum at:  
[www.radiopolis.com/forums/JRCR](http://www.radiopolis.com/forums/JRCR)

#### Interactivity

This publication is available as an interactive article with scroll, window/level, magnify and more features.  
Available online at [www.RadiologyCases.com](http://www.RadiologyCases.com)

Published by EduRad



[www.EduRad.org](http://www.EduRad.org)