

A Torted Ruptured Intra-abdominal Testicular Seminoma Presenting As An Acute Abdomen


Oliver James Nickalls^{1*}, Char Loo Tan², Yee Liang Thian³

1. Department of Diagnostic Radiology, Singapore General Hospital, Singapore

2. Department of Pathology, National University Hospital, Singapore

3. Department of Diagnostic Radiology, National University Hospital, Singapore

* **Correspondence:** Oliver James Nickalls, Department of Diagnostic Radiology, Singapore General Hospital, Outram Road, Singapore, 169608, Singapore

 Oliver@Nickalls.org

Radiology Case. 2015 Dec; 9(12):21-28 :: DOI: 10.3941/jrcr.v9i12.2589

ABSTRACT

The susceptibility of the undescended testis to malignant transformation is well documented. The most common location of the undescended testis is within the inguinal canal, with only a minority located within the abdominal cavity. When a testicular mass develops, the risk of torsion increases. We describe a large intra-abdominal testicular seminoma that had undergone torsion, rupture and haemorrhage, presenting as an acute abdomen. A 30 year old man presented to the emergency department with right iliac fossa pain. Computed tomography in the emergency department showed haemoperitoneum and a torted large left testicular mass, likely malignant. The patient underwent laparotomy and excision of the mass. Histologic examination revealed a grossly enlarged seminomatous testis which had torted and ruptured. While pre-operative imaging diagnosis of an intra-abdominal testicular seminoma has been published, reports are few. To the best of the author's knowledge pre-operative imaging diagnosis of a malignant testicular mass with torsion and intra-abdominal haemorrhage presenting as an acute abdomen has not been described before.

CASE REPORT

CASE REPORT

A 30 year old man presented to the emergency department (ED) with sharp right iliac fossa pain associated with loss of appetite since the previous evening. He denied vomiting, change in bowel habit or urinary symptoms. He had been discharged recently from a nearby hospital for non-specific abdominal pain which resolved with conservative management. There was no other significant medical or surgical history.

In the ED his blood pressure was 142/93 mmHg, there was sinus tachycardia of 121 beats per minute and a respiratory rate of 18 per minute with an oxygen saturation of 99% on room air. He was afebrile. Initial blood tests showed a low haemoglobin of 12.2 g/dL (12.9-17.0). Clinical examination demonstrated generalized lower abdominal tenderness with guarding, slightly worse in the right iliac fossa. The initial clinical impression was abdominal pain of uncertain aetiology, possibly appendicitis. Computed Tomography (CT) of the abdomen and pelvis was therefore requested for further evaluation.

CT demonstrated a heterogeneous low density 9.9 x 9.0 x 13.1 cm mass within the abdomen (Fig. 1a-c). A vascular pedicle was identified originating from the mass in the left iliac fossa (Fig. 1b, 1c) with a vessel that could be traced back to the left renal vein (Fig 1d). The vascular pedicle vessel showed a 'swirl' configuration, suggesting torsion (Fig. 2). Surrounding dense material (60 HU) extending into the right paracolic gutter with further borderline dense ascites ranging from 20 to 35 HU (Fig. 1c) was compatible with primary clot and intraperitoneal haemorrhagic fluid. The right testicle was seen to lie within the right inguinal canal (Fig. 3). The scrotum was not completely included within the scan, however the left spermatic cord was not present within the inguinal canal (Fig. 3). The appendix showed normal features. No lymphadenopathy was evident.

A tentative diagnosis of a torted left intra-abdominal testicular mass, likely malignant, with resulting haemorrhage was made. Subsequent clinical evaluation revealed an empty scrotum.

At subsequent laparotomy a 10 x 10 cm intra-abdominal left testicular tumour was removed, weighing 314 grams. There was evident torsion, vascular congestion and focal rupture with a mixture of old blood and blood clots. The bowel loops and solid organs showed normal features.

Pathologic evaluation of the mass showed a grossly enlarged testis, completely replaced by a tan brown haemorrhagic tumour with extensive necrosis (Fig. 4), proving to be a seminoma.

Post-operative recovery was uneventful and the patient was discharged well after 3 days. Follow-up CT at 1 year showed no evidence of local or distant disease recurrence.

DISCUSSION

Etiology & Demographics:

The susceptibility of the undescended testis to malignant transformation, most commonly seminoma, is well documented [1,2]. Overall, the cancer risk in an undescended testis is approximately 2.5 to 8 times greater than in an orthotopic testis. The risk is reduced to 2 to 3 times the orthotopic testis risk if prepubertal orchidopexy is performed [1]. Rates of malignancy in intra-abdominal testes have been quoted as 5 times higher than the average rate of malignancy in all undescended testes [3]. The most common location of the undescended testis is within the inguinal canal, with only 10% located within the abdominal cavity [4]. Torsion of the undescended testis, whether in the inguinal canal or intra-abdominal, is a rare cause of abdominal pain [5] with few published cases. Routine examination of neonates and infants might be expected to diagnose cryptorchidism early in life, however, a population of adult patients with an uninvestigated absent testis remains. Development of a seminoma within an undescended testis is thought to occur at a similar age as in the normally descended testis, usually between 35 and 50 years of age [6]. Other complications of undescended testes include subfertility, inguinal hernia and susceptibility to trauma of testes within the inguinal tract.

Clinical & Imaging findings:

Patients with a torted intra-abdominal testis present with abdominal pain. Episodic pain may be caused by intermittent torsion with subsequent detorsion. Rupture of a torted intra-abdominal testis causing intraperitoneal haemorrhage may lead to hypovolaemic shock. The clinical finding of a non-palpable testis is not always available to the radiologist.

An intra-abdominal mass is usually evident at imaging, though its nature is not always clear. Intraperitoneal blood will be present in the case of rupture, possibly with sentinel clot adjacent to the mass at CT. If it can be identified, the vascular pedicle shows blood supply from the gonadal vessels. An empty hemiscrotum and inguinal canal would also be demonstrated.

Ultrasonography is the modality of choice when evaluating for torsion of the orthotopic testis. When the torted testis is intra-abdominal however, the cause of pain is not always clear and initial sonographic evaluation may only be able to demonstrate absence of the testis within the scrotum and inguinal canal. Ultrasound is not sensitive when searching for the intra-abdominal testis. Ultrasound has a sensitivity as high as 95-97% when locating an inguinal testis [1] and may have a role in planning elective surgery to find a non-palpable testis as it may also identify the 'peeping' testis (a variably palpable testis located at the deep inguinal ring, through which it can migrate back and forth). MRI may be useful in identifying an intra-abdominal testis, if not found by surgical exploration [1]. At MRI, seminoma typically has a nodular appearance and a homogenous low signal intensity on T2-weighted MRI images [7]. In the setting of the acute abdomen, CT is still the modality of choice, being better able to evaluate a wider range of pathologies than ultrasound, as well as being faster, cheaper and more readily available than MRI.

In our case, absence of the left spermatic cord within the left inguinal canal and abnormal position of the right testis were useful signs. The 'testicular vascular pedicle' sign [8] was the most important finding that confirmed testicular origin. The 'testicular vascular pedicle' sign describes the demonstration of a testicular vein draining into the left renal vein or inferior vena cava, originating from a pelvic mass, allowing the diagnosis of testicular origin of a pelvic mass. Given the vascular pedicle vessels in our case could be seen forming a 'swirl' pattern, torsion of a testicular mass was therefore considered likely. A preoperative imaging diagnosis of a ruptured, torted intra-abdominal testicular mass, likely malignant, could therefore be made. It is worth noting that the epididymis appears bulky in the CT images, though it is not clear if this is due to tumour invasion or torsion.

The increasing availability of CT scans in the ED means that emergent cases are more likely to be identified radiologically rather than at the time of surgery. Previous case reports have described similarly torted [5] and ruptured [9, 10] large intra-abdominal testicular masses, though these were diagnosed at surgery rather than at CT. Previous CT diagnosis of an uncomplicated intra-abdominal testicular seminoma in the acute setting has been described [8] but case reports are

few. There are also reports of pre-operative imaging diagnoses of uncomplicated intra-abdominal testicular seminomas presenting with hematuria [4] and also with abdominal pain and bilateral inguinal hernias [11]. These were presumptive diagnoses consisting of an intra-abdominal mass and absence of a testicle, without specific imaging findings to confirm the testicular origin of these masses. We are not aware of a similarly acutely presenting torted bleeding intra-abdominal testicular seminoma that was preoperatively diagnosed at CT. This is likely in no small part due to the improvement in image quality offered by modern CT scanners and the ease of access to pre-operative diagnostic imaging.

Treatment & Prognosis:

The initial surgical management for adults with an uncomplicated intra-abdominal testis was orchidectomy, though there is a shift towards conservative management with imaging surveillance. In patients with orthotopic testicular seminomas, approximately 80% of whom present with stage I disease, radical inguinal orchidectomy is the initial treatment of choice. Without adjuvant therapy modern surveillance programs show the relapse rate to be approximately 12–15% in the first three to four years, with a 10-year overall relapse rate of approximately 18%–20% [6]. Seminoma is exquisitely sensitive to radiotherapy and chemotherapy, and patients with stage I disease typically do well with a 5 year cause-specific survival of 99.9% and 100% when treated with adjuvant chemotherapy and radiotherapy respectively. More advanced disease may require combination chemotherapy and radiotherapy, with lymph node dissection playing a more limited role due to a low rate of viable tumour in small residual masses and increased desmoplastic reaction and fibrosis following surgery.

In our case, no lymphadenopathy or other evidence of metastatic disease was found. The patient was treated with adjuvant chemotherapy and remains well 3 years after diagnosis. The inguinal right testis showed no other suspicious feature at initial CT, and was allowed to remain within the inguinal tract. CT surveillance showed no subsequent suspicious change after 3 years.

Differential diagnoses:

Subserosal Gastro-intestinal Stromal Tumour

The main differential in this case was subserosal gastro-intestinal stromal tumour (GIST). A subserosal GIST tends to be a rounded soft tissue mass of homogeneous or heterogeneous attenuation which displaces surrounding bowel loops [12] and may be expected to show attachment to a hollow viscus. They typically show central necrosis and peripheral enhancement. MRI features include low T1-weighted signal, high heterogeneous T2-weighted signal and marked heterogeneous contrast enhancement [13]. Features suggestive of a malignant GIST include an irregular lobulated mass with low attenuation, central liquefactive necrosis, ulceration, heterogeneity, calcification or direct extension and vascular encasement [12].

Peritoneal metastases

Peritoneal metastases are usually smaller and multiple, and are associated with low density ascites rather than intra-abdominal haemorrhage. Omental caking may be evident

when the metastases are extensive. Often a primary tumour, such as ovarian or gastric carcinoma, is also present. CT and MRI features vary with extent and the histology of the primary tumour, but thickening, nodularity and enhancement are suggestive of a malignant process [14].

Small bowel lymphoma

In small bowel lymphoma there is often a large, segmental nodular wall thickening [12], sometimes with aneurysmal bowel dilatation and often accompanied by bulky retroperitoneal lymphadenopathy. Less often, lymphoma may present as a polypoidal or eccentric solid mass, but it should still be inseparable from a small bowel loop. MRI features tend to show low T1 and T2-weighted signal with mild heterogeneous enhancement [13]. Small bowel lymphomas may be associated with HIV, organ transplantation, coeliac or Crohn's disease, as well as extra-intestinal lymphoma.

Desmoid tumours

Desmoid tumours are rare, but are the most common tumour of the mesentery. They most often involve the small bowel mesentery and are more common in patients with Gardner's syndrome. At CT they mostly appear as a well-circumscribed soft tissue mass of variable attenuation, and may enhance [15]. Some may appear more aggressive, with infiltrative margins. MRI may demonstrate heterogeneous signal and homogeneous enhancement. T2-weighted and proton density images usually show intermediate signal intensity [15], sometimes with hypointense bands.

TEACHING POINT

The take-home message is that in a patient with an empty inguinal canal and abdominal mass, an intra-abdominal testicular mass should be considered. Torsion may be demonstrated by a swirl of vessels in a twisted vascular pedicle.

REFERENCES

1. Ashley RA, Barthold JS, Kolon TF. Cryptorchidism: pathogenesis, diagnosis, treatment and prognosis. *Urol Clin North Am.* 2010 May; 37(2):183-93. PMID: 20569797
2. Woodward PJ. Case 70: Seminoma in an undescended testis *Radiology.* 2004 May; 231(2):388-92. PMID: 15128985
3. Nader AM, Moaath AM, Jamal AK, Mujalli MM. Giant Intra-abdominal Seminoma. *Saudi Med J.* 2009 Mar; 30(3):441-2. PMID: 19271081
4. Miller FH, Whitney WS, Fitzgerald SW, Miller EI. Seminomas complicating undescended intraabdominal testes in patients with prior negative findings from surgical exploration. *AJR Am J Roentgenol.* 1999 Feb; 172(2):425-8. PMID: 9930796
5. Chua W, Engledow A, Raptis D, Obichere A. Torted intra-abdominal testicular tumour mimicking an appendix mass.

Grand Rounds. 2007; vol. 7, pages 48-50. Available at: www.grandroundsjournal.com/articles/gr070013. Accessed April 04, 2015. DOI: 10.1102/1470-5206.2007.0013

6. Alexander EJ, White IM, Horwich A. Update on management of seminoma. *Indian J Urol.* 2010 Jan-Mar; 26(1): 82-91. PMID: 20535292

7. Adham WK, Raval BK, Uzquiano MC, Lemos LB. Best cases from the AFIP: bilateral testicular tumors: seminoma and mixed germ cell tumor. *Radiographics.* 2005 May-Jun; 25(3):835-9. PMID: 15888629

8. Karcaaltincaba M, Kaya D, Ozkan OS, Akhan O. Preoperative multidetector computed tomography diagnosis of a seminoma originating from an undescended testis by "testicular vascular pedicle" sign. *J Comput Assist Tomogr.* 2006 Sep-Oct; 30(5):794-5. PMID: 16954931

9. Kucuk HF, Dalkilic G, Kuroglu E, Altuntas M, Barisik NO, Gulmen M. Massive bleeding caused by rupture of intra-abdominal testicular seminoma: Case report. *J Trauma.* 2002 May; 52(5):1000-1. PMID: 11988673

10. Singh P, Bajaj K, Kaur R, Mishra A, Riar HK. Ruptured seminoma of undescended testis presenting as acute abdomen: Case report with literature review. *Ann Med Health Sci Res.* 2013 Jan; 3(1):108-9. PMID: 23634342

11. Thirunavukkarasu S, Robert K. Spontaneous Rupture of Intra-Abdominal Seminoma: A Case Report. *OSR-JDMS* 2015 Jan; 14(1):33-35. Available at: journals.indexcopernicus.com/issue.php?id=952&id_issue=876621. Accessed September 05, 2015. DOI: 10.9790/0853-14183335

12. Buckley JA, Fishman EK. CT evaluation of small bowel neoplasms: spectrum of disease. *Radiographics.* 1998 Mar-Apr; 18(2):379-92. PMID: 9536485

13. Masselli G, Colaiacomo MC, Marcelli G, et al. MRI of the small-bowel: how to differentiate primary neoplasms and mimickers. *Br J Radiol.* 2012 Jun; 85(1014):824-37. PMID: 22422388

14. Levy AD, Shaw JC, Sobin LH. Secondary tumors and tumorlike lesions of the peritoneal cavity: imaging features with pathologic correlation. *Radiographics.* 2009 Mar-Apr; 29(2):347-73. PMID: 19325052

15. Shinagare AB, Ramaiya NH, Jagannathan JP, et al. A to Z of desmoid tumors. *AJR Am J Roentgenol.* 2011 Dec; 197(6):W1008-14. PMID: 22109314

FIGURES

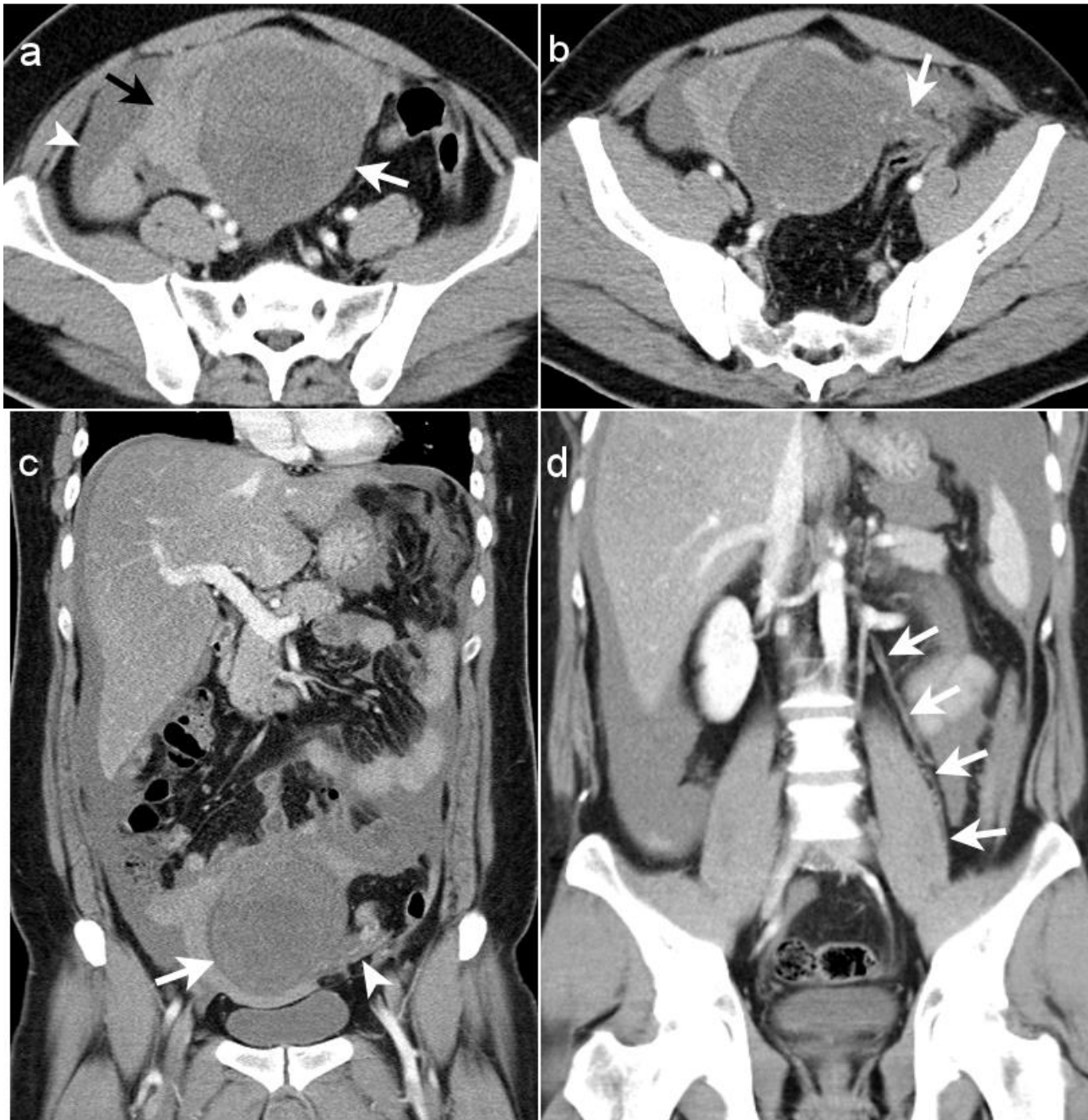


Figure 1: 30 year old male with torted and ruptured intra-abdominal testicular seminoma.

FINDINGS:

A: Axial portal venous phase CT image. A 9.9 x 9.0 x 13.1 cm slightly heterogeneous low density mass lies within the abdominal cavity (white arrow), with surrounding dense material (black arrow) compatible with acute blood. Lower density intraperitoneal fluid (approximately 26 HU) representing haemorrhagic fluid (white arrowhead).

B & C: Axial and coronal reconstructed portal venous phase CT images show the heterogeneous low density mass in image C (white arrow) displacing the adjacent bowel loops and indenting the dome of the urinary bladder. The vascular pedicle (image B white arrow, image C white arrowhead) arises from the left lateral aspect of the mass, before passing posteriorly. The acute clot surrounding the mass and more extensive lower density intraperitoneal haemorrhagic fluid ranging from 20 to 35 HU are again demonstrated. Incidentally, the liver shows diffuse low density in keeping with fatty change.

D: Oblique coronal reconstructed CT images demonstrating the continuation of the vascular pedicle vein passing along the anterolateral aspect of the psoas muscle, and reaching the left renal vein (white arrows). A more prominent vein can be seen merging with the left renal vein medially. This vessel passed inferiorly then posterior to the aorta to join the IVC (not shown), probably representing an IVC anomaly.

TECHNIQUE: CT (Siemens Sensation 64), 120 kVp, 574 mAs, 5 mm slice thickness reconstructed in axial and coronal planes, 100 mls Omnipaque 300.

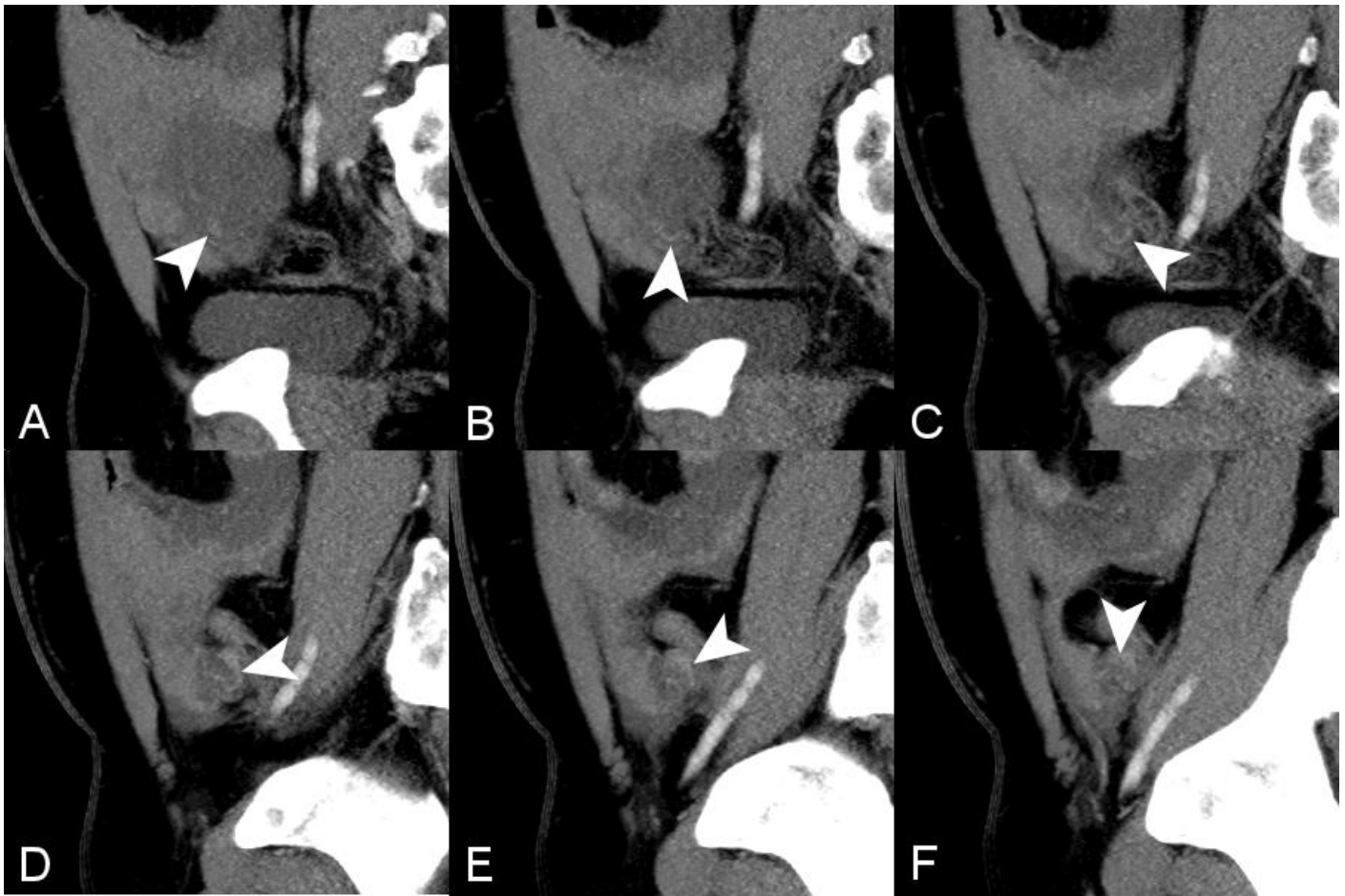


Figure 2: 30 year old male with torted and ruptured intra-abdominal testicular seminoma.

FINDINGS: Sagittal thick slice reformatted contrast enhanced CT images in the portal venous phase show the anticlockwise 'swirling' of vessels in the torted pedicle (arrowheads) from medial to lateral (A to F).

TECHNIQUE: CT (Siemens Sensation 64), 120 kVp, 574 mAs, 15 mm slice thickness reconstructed in the sagittal plane, 5 mm interval, 100 mls Omnipaque 300.

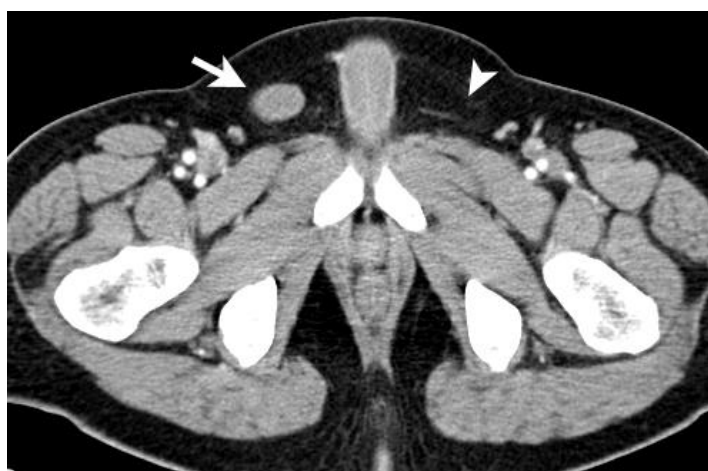


Figure 3 (left): 30 year old male with torted and ruptured intra-abdominal testicular seminoma.

FINDINGS: Axial contrast enhanced CT image of the lower pelvis in the portal venous phase shows the right testis (arrow) lying within the inguinal canal, with no features to suggest an associated mass. No spermatic cord is seen within the left inguinal canal (arrowhead).

TECHNIQUE: CT (Siemens Sensation 64), 120 kVp, 574 mAs, 5 mm slice thickness, axial plane, 100 mls Omnipaque 300.

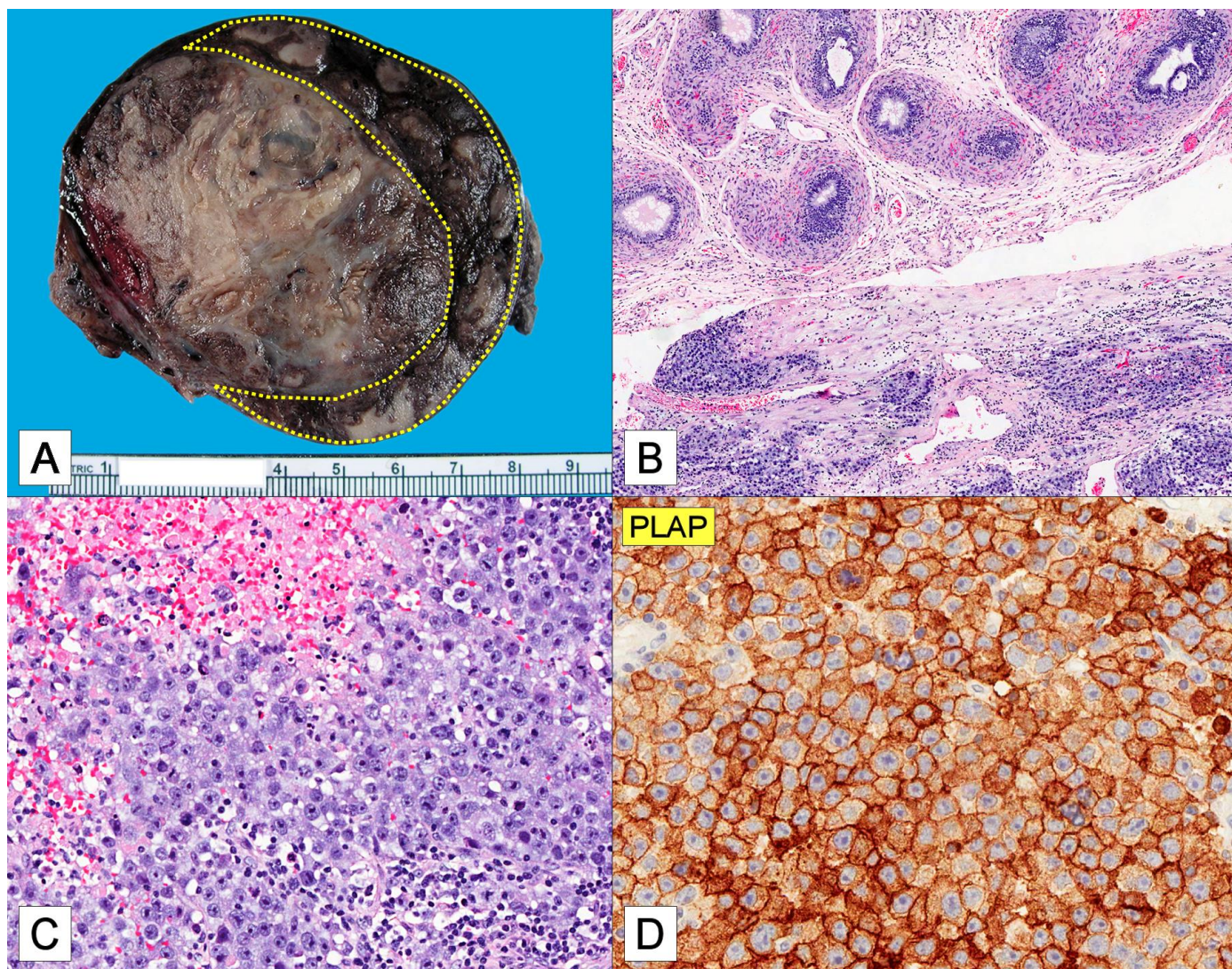


Figure 4: 30 year old male with torsed and ruptured intra-abdominal testicular seminoma.
 A: Gross photograph of the excised mass shows testis and epididymis (round dot dashed line) with large area of necrosis and haemorrhage.
 B: Histology section of the epididymis (top) and testicular tissue which is entirely replaced by tumour (bottom). (Haematoxylin & eosin, Magnification 50x).
 C: The tumor is composed of polygonal cells with round nuclei, prominent nucleoli and finely vacuolated cytoplasm, with brisk mitosis and lymphocytic infiltrate. Area of necrosis is present at the top left corner. (Haematoxylin & eosin, Magnification 200x).
 D: The tumour shows diffuse immunopositivity for placental alkaline phosphatase (PLAP) and CD117 (not shown). (Immunohistochemistry, PLAP. Magnification

Aetiology	Torsion of an intra-abdominal testicular seminoma
Incidence	Unknown incidence in adults, but more likely with a large testicular mass. Malignancy, usually seminoma, is 5 times more frequent in the intra-abdominal testis than in the undescended testis within the inguinal tract.
Gender Ratio	Exclusive to males
Age predilection	Unknown. It is probably associated with the age of seminomatous conversion, which is often 35-50 years, but may occur at any age.
Risk Factors	For congenital cryptorchidism: Low birth weight, premature birth and small size for gestational age, family history of undescended testicle, abdominal wall defect.
Treatment	Surgical excision, chemotherapy
Prognosis	Good, particularly if diagnosed before metastatic spread
Findings on imaging	Absence of a normally located testis and spermatic cord. Testicular vessels extend to an intraperitoneal soft tissue mass. Swirling of vessels within the vascular pedicle may be evident.

Table 1: Summary table for torsion of an intra-abdominal testicular seminoma.

Entity	Contrast CT	MRI
Intra-abdominal testicular seminoma	Absence of the normally located testicle and spermatic cord. Testicular vessels extend to the mass (testicular pedicle sign) which is not necessarily related to the gastrointestinal tract.	Testicular seminomas (not specifically intra-abdominal) typically demonstrate a homogenous low T2-weighted signal intensity
Subserosal Gastro-intestinal stromal tumor	A rounded soft tissue mass lesion, usually arising from a hollow viscus. Not related to the gonadal vessels. Often peripheral enhancement due to central necrosis.	Low T1 and high T2--weighted signal, with marked heterogeneous enhancement.
Peritoneal metastases	Multiple enhancing peritoneal thickenings or small nodules, often with low-density intra-peritoneal free fluid. There is often an evident intra-abdominal primary tumour. Omental caking may be evident when the metastases are extensive.	Variable and dependent on the primary tumour. Features such as nodular peritoneal thickening with enhancement are suspicious.
Small bowel lymphoma	Variable, but include a large segmental nodular wall thickening, sometimes forming an aneurysmal dilatation. Often with bulky retroperitoneal lymphadenopathy. Eccentric or polypoidal masses may form. Typically homogeneously enhancing.	Low T1 and T2-weighted signal with mild heterogeneous enhancement.
Intra-abdominal desmoid tumour	Usually well-circumscribed soft tissue mass of variable attenuation, and may enhance. Some may show infiltrative margins.	Heterogeneous signal and homogeneous enhancement. T2-weighted and proton density images usually show intermediate signal intensity, sometimes with hypointense bands.

Table 2: Differential diagnosis table for intra-abdominal testicular seminoma.

ABBREVIATIONS

CT = Computed tomography
ED = Emergency Department
GIST = Gastro-Intestinal Stromal Tumour
MIP = Maximum Intensity Projection

KEYWORDS

Cryptorchidism; undescended testis; testicular torsion; intra-abdominal testicular torsion; intra-abdominal testicular seminoma; CT; intraperitoneal haemorrhage; acute abdomen

Online access

This publication is online available at:
www.radiologycases.com/index.php/radiologycases/article/view/2589

Peer discussion

Discuss this manuscript in our protected discussion forum at:
www.radiopolis.com/forums/JRCR

Interactivity

This publication is available as an interactive article with scroll, window/level, magnify and more features.
Available online at www.RadiologyCases.com

Published by EduRad



www.EduRad.org