


Isolated Fallopian Tube Torsion With Fimbrial Cyst In A 10 Year-old Girl Diagnosed By Ultrasound: A Case Report

Maria Constanca Olveda Ormasa^{1*}, Ehab Shaban Mahmoud Hamouda¹, Jacqueline Jung²

1. Department of Diagnostic and Interventional Imaging, KK Women's and Children's Hospital, Singapore

2. Department of Obstetrics and Gynecology, KK Women's and Children's Hospital, Singapore

* **Correspondence:** Maria Constanca Olveda Ormasa, Department of Diagnostic and Interventional Imaging, KK Women's and Children's Hospital, 100 Bukit Timah Road, Singapore 229899, Singapore
 maria_constancia_ormasa@ttsh.com.sg

Radiology Case. 2015 Dec; 9(12):29-36 :: DOI: 10.3941/jrcr.v9i12.2565

ABSTRACT

Torsion of the fallopian tube without the involvement of the ipsilateral ovary is a rare but important cause of acute abdominal pain in women as it is a surgical emergency. Although uncommon, it should be considered as one of the differential diagnosis in female children presenting with acute lower abdominal or pelvic pain. The diagnosis of isolated fallopian tube torsion is difficult pre-operatively and is often made during laparoscopic or surgical exploration because diagnostic features are usually non-specific. In this report, we present a case of isolated fallopian tube torsion with fimbrial cyst in a young female patient diagnosed pre-operatively by ultrasound.

CASE REPORT

CASE REPORT

A 10-year-old girl presented with acute severe abdominal pain and vomiting of less than one day. There was no associated fever, diarrhea or loss of appetite. The onset of pain was sudden. The pain was described as cramp like and significantly worsened after few hours. It was localized to the right lower abdominal quadrant. Patient was brought to a general hospital and initial laboratory examinations showed elevated total white cell count of 11.7 (nv: 4.5-10 x 10³/L) and increased CRP of 5.3 (nv: <3.0 mg/L). The presumptive diagnosis was acute appendicitis. Patient was then referred to our institution for further evaluation and management.

The physical examination revealed no tenderness, guarding or distention. The urine pregnancy test was negative. Chest and abdominal radiographs were normal and showed no evidence of pneumoperitoneum (Fig. 1). An ultrasound study of the abdomen and pelvis was done which showed normal uterus and left ovary with preserved venous flow (Fig. 2). The

right ovary was also normal in appearance with preserved venous flow. There was a large unilocular pouch of Douglas cyst (probably a paraovarian/fimbrial cyst) (Fig. 3). There was a convoluted echogenic structure (twisted pedicle) between the normal appearing right ovary and the pouch of Douglas cyst (Fig. 4). The appendix was not visualized. The ultrasound findings were reported as suspicious of isolated tubal torsion with paraovarian/fimbrial cyst.

A laparoscopy was performed in lieu of the ultrasound findings. Laparoscopy demonstrated 1080 degrees (3x) torsion of the right fallopian tube. Detorsion of the right fallopian tube was performed. Circulation of the right fallopian tube was normal after detorsion (Fig. 5). The uterus and both ovaries are normal. A right fimbrial cyst was also noted. The fimbrial cyst was ruptured and clear fluid was seen oozing out (Fig. 6). Cystectomy was performed. No other pathology was seen in the pelvis. The collapsed cystic structure was sent for histopathological examination. Histopathology showed fibrous

cyst wall lined by tubal type ciliated columnar epithelium. No atypical features or malignancy was identified (Fig. 7).

Post-operatively, the patient had no complication. Patient was discharged well on third post-operative day.

DISCUSSION

Etiology & Demographics:

Isolated fallopian tube torsion (IFTT) is a rare entity that was first described in literature by Bland-Sutton in 1890. It is an important cause of acute abdominal or pelvic pain with incidence of 1 in 1.5 million women [1]. It occurs primarily in reproductive age women and is uncommon in post-menopausal women. It is rare in pediatric population. In our review of literature, there have been 48 cases of IFTT in children.

The exact cause of isolated fallopian tube torsion is unknown. Predisposing intrinsic and extrinsic factors have been reported. The intrinsic factors are congenital anomalies (excessive length or spiral course of the tube), acquired pathology (hydrosalpinx, hematosalpinx, neoplasm or surgery) and autonomic dysfunction or abnormal peristalsis. The extrinsic factors include changes in the neighboring organs (neoplasm, adhesions or pregnancy), mechanical factors, movement or trauma to pelvic organs and pelvic congestion. However, IFTT can also be found in normal fallopian tube [2, 3]. The right fallopian tube is more commonly affected. This is likely due to cushioning effect of the sigmoid colon on the left side and due to the fact that right-sided pathology is more often evaluated to rule out appendicitis [4].

Paraovarian/fimbrial cysts comprise about 5-20 % of all adnexal masses. Other adnexal masses include follicular cyst, corpus luteum cyst, tubo-ovarian abscess and neoplasms. The paraovarian/fimbrial cysts represent group of cystic masses that are adjacent to the ovary and the fallopian tube [5]. They arise from Müllerian or Wolffian structures and are uncommon in children. There are rare cases that have been reported in association with IFTT [6].

Clinical & Imaging findings

Isolated fallopian tube torsion can present without any obvious pathognomonic clinical signs or symptoms. The most common symptom is sudden severe lower abdominal pain. The pain has been described as constant and dull or paroxysmal and sharp, radiating to the thigh or groin. Other presenting sign and symptoms include nausea, vomiting, peritoneal signs and discrete adnexal mass. Fever, tachycardia, leukocytosis and slightly elevated erythrocyte sedimentation rate may be present. Our patient presented with acute right lower quadrant pain. With leukocytosis and elevated CRP, acute appendicitis was the initial diagnosis. However, the physical findings are equivocal for our patient and further evaluation with abdominal and pelvic ultrasound was done.

Diagnostic imaging may be done in the form of ultrasound, CT or MRI scan of the abdomen and pelvis. The most common ultrasound finding is cystic pelvic mass in midline position, either in the cul-de-sac or superior to the

uterus, with normal appearing ovary with normal flow. Other ultrasound findings of isolated fallopian tube torsion include free fluid, dilated fallopian tube with thickened echogenic walls and internal debris [7]. Doppler study findings that are indicative sign of tubal torsion include high-impedance or absence of flow in a tubular structure. In presence of normal ovaries and dilated fallopian tube, whirlpool sign on either side of the tube is specific for fallopian tube torsion [8]. CT scan findings include adnexal cystic mass, twisted appearance of the fallopian tube, dilated tube greater than 15 mm, thickened and enhancing tubal wall, and luminal CT attenuation greater than 50 HU, consistent with hemorrhage [7]. MRI appearances of IFTT include non-enhancement of fallopian tube, enlarged and tortuous fallopian tube with normal ipsilateral ovary and an equivocal mass near the uterus [9].

As findings in the physical examination and diagnostic imaging are usually non-specific, the diagnosis is often made during laparoscopy or exploratory surgery. However in our patient, the ultrasound study revealed a heterogeneous convoluted echogenic structure (twisted pedicle) in the right adnexal region, with normal right ovary and a paraovarian cyst (fimbrial cyst). These ultrasound findings led to the diagnosis of isolated right fallopian tube torsion with fimbrial cyst.

Differential Diagnosis

The differential diagnoses of acute abdominal/pelvic pain in female patients are broad and gastrointestinal and gynecologic causes should be considered [10]. These includes acute appendicitis, pelvic inflammatory disease, ectopic pregnancy, ovarian torsion, twisted ovarian cyst, degenerative leiomyoma and although rare, isolated fallopian tube torsion. Given the ultrasound finding of an adnexal cyst, the differential diagnoses for our patient includes isolated fallopian tube torsion with paraovarian/fimbrial cyst, torsion of ovary with cyst and isolated torsion of paraovarian/fimbrial cyst.

In ovarian torsion, the sonographic appearances vary according to the duration and degree of torsion, and the presence or absence of an ovarian lesion. The most common finding is a unilateral enlarged ovary. Other sonographic findings include ovarian edema manifesting as hypoechoic or heterogeneous central stroma with small peripherally located follicles, ovarian enlargement relative to contralateral unaffected ovary, ovarian cyst or mass, abnormal ovarian location (midline, anterior to or above the uterus or in pouch of Douglas), presence of free fluid and evidence of distended fallopian tube [11]. An underlying ovarian lesion may be seen as possible lead point for torsion. A long-standing infarcted ovary may have a more complex appearance with cystic or hemorrhagic degeneration. The ovary should be tender to transducer pressure [12]. Doppler ultrasound also helps in the diagnosis of ovarian torsion. Doppler findings include little or no intra-ovarian venous flow (which is common), absent arterial flow (which is less common but is a poor prognostic sign), absent or reversed diastolic flow. As a caveat, normal vascularity does not exclude intermittent torsion. Normal Doppler flow can be also occasionally found due to dual supply from both the ovarian and uterine arteries. Whirlpool sign refers to concentric low echoic intra-pedicular structures

identified as vascular structures on color Doppler sonography and is indicative of a twisted vascular pedicle [13]. The CT and MRI findings include deviation of the uterus to the twisted side, engorged blood vessels on the twisted side and complete absence of enhancement of the affected ovary [14].

In isolated paraovarian/fimbrial cyst torsion, the sonographic appearance include cyst in the adnexal or pouch of Douglas with adjacent fluid, and normal appearance and flow of ipsilateral ovary and fallopian tube [15]. CT and MRI study also shows cystic adnexal mass separate from the normal ovary [16, 17]. Torsion is suggested if a twisted pedicle is seen.

Treatment & Prognosis

Prompt diagnosis of isolated fallopian tube torsion is important because immediate intervention is necessary to preserve future conception capacity of the patient especially in children. Laparoscopy should be considered as first intervention especially at early stage. It is considered the method of choice for the definitive diagnosis and treatment of IFTT [18]. The treatment options for IFTT are complete or partial salpingectomy in cases of ischemic and irreversible changes in the tubal wall, and detorsion in cases where circulation can be restored and fallopian tube is viable. Recurrent torsions have been reported in cases following conservative treatment (detorsion) [19].

TEACHING POINT

In cases of acute severe lower abdominal/pelvic pain and vomiting in children, isolated fallopian tube torsion is an important differential diagnosis. Ultrasound findings of a convoluted adnexal structure (twisted pedicle) with paraovarian/fimbrial cyst in the presence of normal ipsilateral ovary are suggestive of isolated fallopian tube torsion.

REFERENCES

1. Gross M, Blumstein SL, Chow LC. Isolated fallopian tube torsion: a rare twist on a common theme. *Am J Roentgenol.* 2005 Dec; 185 (6): 1590-2. PMID: 16304018
2. Krissi H, Shalev J, Bar-Hava I, et al. Fallopian tube torsion: laparoscopic evaluation and treatment of a rare gynecological entity. *J Am Board Fam Pract.* 2001; 14 (4): 274-7. PMID: 11458970
3. Ardicci B, Ekinici S, Oguz B, et al. Laparoscopic detorsion of isolated idiopathic fallopian tube torsion: conservative treatment in a 13-year-old girl. *Turk J Pediatr.* 2013 Jul-Aug; 55 (4): 451-4. PMID: 2429044
4. Erickci VS, Hosgor M. Isolated salpingeal torsion in children: a case series and review of the literature. *Ulus Travma Acil Cerr Derg.* 2014 Jan; 20 (1): 75-8. PMID: 24639322

5. Savelli L, Ghi T, De Iaco P, et al. Paraovarian/paratubal cysts: Comparison of transvaginal sonographic and pathologic findings to establish diagnostic criteria. *Ultrasound Obstet Gynecol.* 2006; 28: 330-4. PMID: 16823765
6. Kisku S, Thomas RJ. An uncommon twist: Isolated fallopian tube torsion in an adolescent. *Case Rep Surg.* 2013; 509424. PMID: 24024061
7. Ghossain M, Buy J, Bazot M, et al. CT in adnexal torsion with emphasis on tubal findings: correlation with US. *J Comput Assist Tomogr.* 1994; 18: 619-25. PMID: 8040449
8. Vijayaraghavan S, Senthil S. Isolated torsion of the fallopian tube: the sonographic whirlpool sign. *J Ultrasound Med.* 2009; 28: 657-62. PMID: 19389905
9. Jalaguier-Coudray A, Thomassin-Naggara I, Chereau E, et al. A case of isolated torsion of the fallopian tube: added value of magnetic resonance imaging. *European Journal of Radiology Extra.* 2011 Jul; 19(1): e1-e4. doi:10.1016/j.ejrex.2011.03.007.
10. Wong SW, Suen SH, Lao T, et al. Isolated fallopian tube torsion: a series of six cases. *Acta Obstet Gynecol Scand.* 2010; 89: 1354-6. PMID: 20726829
11. Mashiach R, Melamed N, Gilad N, et al. Sonographic diagnosis of ovarian torsion: accuracy and predictive factors. *J Ultrasound Med.* 2011 Sep 30 (9): 1205-10. PMID: 21876091
12. Amirbekian S, Hooley RJ. Ultrasound evaluation of pelvic pain. *Radiol Clin North Am.* 2014; 52 (6): 1215-35. PMID: 25444102
13. Lee EJ, Kwon HC, Joo HJ, et al. Diagnosis of ovarian torsion with color Doppler sonography: depiction of twisted vascular pedicle. *J Ultrasound Med.* 1998; 17 (2): 83-9. PMID: 9527577
14. Kimura I, Togashi K, Kawakami S, et al. Ovarian torsion: CT and MR imaging appearance. *Radiology.* 1994 Feb; 190 (2): 337-41. PMID: 8284378
15. Rathi M, Najam R, Budania SK, et al. Twisted fimbrial cyst (paraovarian cyst): a rare cause of acute abdomen. *Clin Med Insights Case Rep.* 2013 Dec 18; 6: 205-7. PMID: 24385716
16. Potter A, Chandrasekhar C. US and CT evaluation of acute pelvic pain of gynecologic origin in non-pregnant premenopausal patients. *Radiographics.* 2008 Oct; 28 (6): 1645-59. PMID: 18936027
17. Kier R. Non-ovarian Gynecologic Cyst: MR imaging findings. *Am J Roentgenol.* 1985; 144: 83-6. PMID: 1590120
18. Romano M, Noviello C, Mariscollini F, et al. Role of laparoscopy in the management of isolated fallopian tube torsion in Adolescents. *Journal of Endoscopic and Minimally Invasive Surgery in Newborn, Children and Adolescent.* ISSN 2283-7116.

19. Boukaidi S, Delotte J, Steyaert H, et al. Thirteen cases of isolated tubal torsions associated with hydrosalpinx in children and adolescents, proposal for conservative management: retrospective review and literature survey. J Pediatr Surg. 2011 Jul; 46 (7): 1425-31. PMID: 21763846

FIGURES

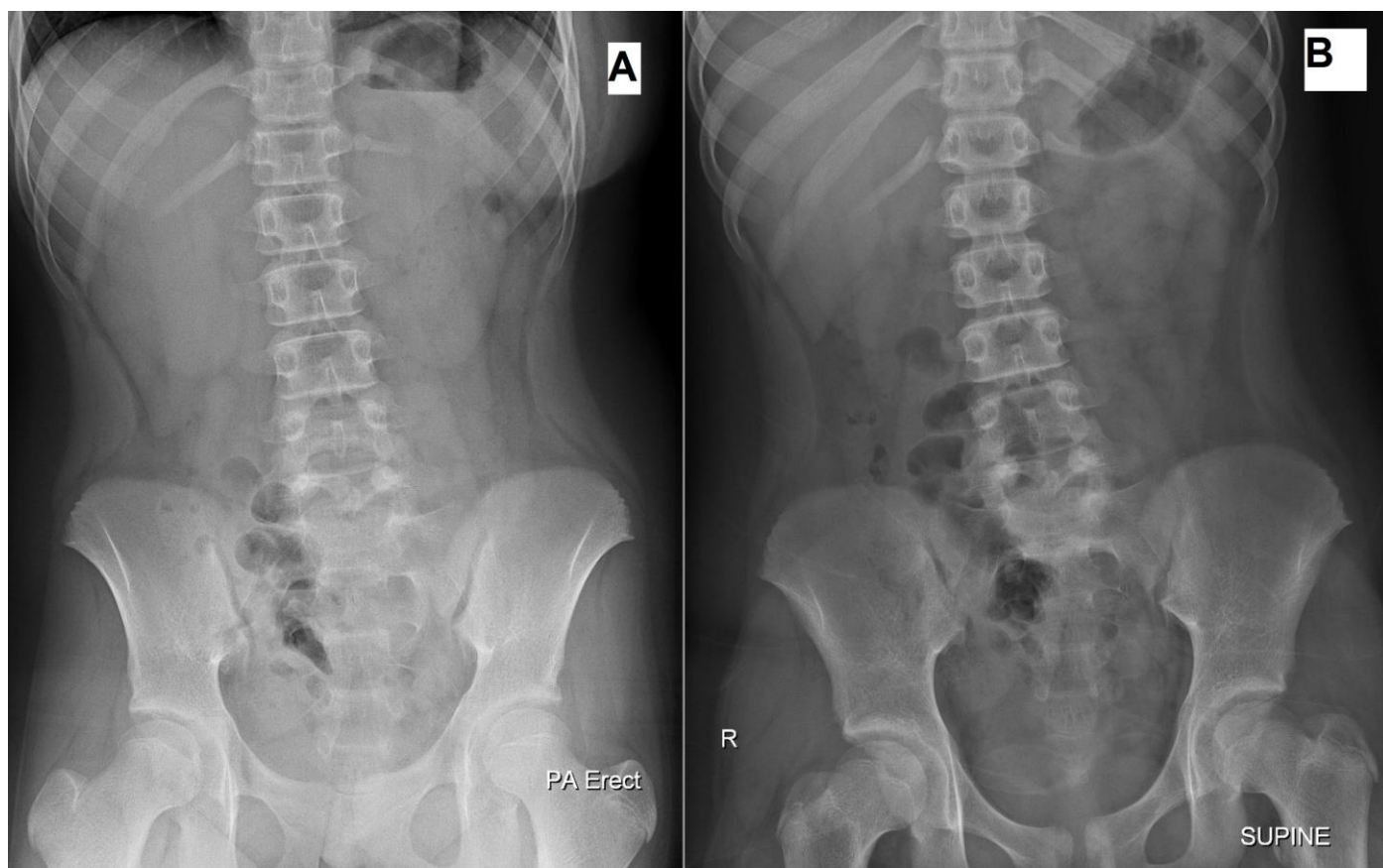


Figure 1: 10 year-old girl with isolated right fallopian tube torsion with fimbrial cyst.

Technique: Radiography. Siemens Ysio with kVP 70 and mAs 5

Findings: Abdominal radiographs. Erect (A) and Supine (B) projections showed no pneumoperitoneum and no dilated bowel loops.

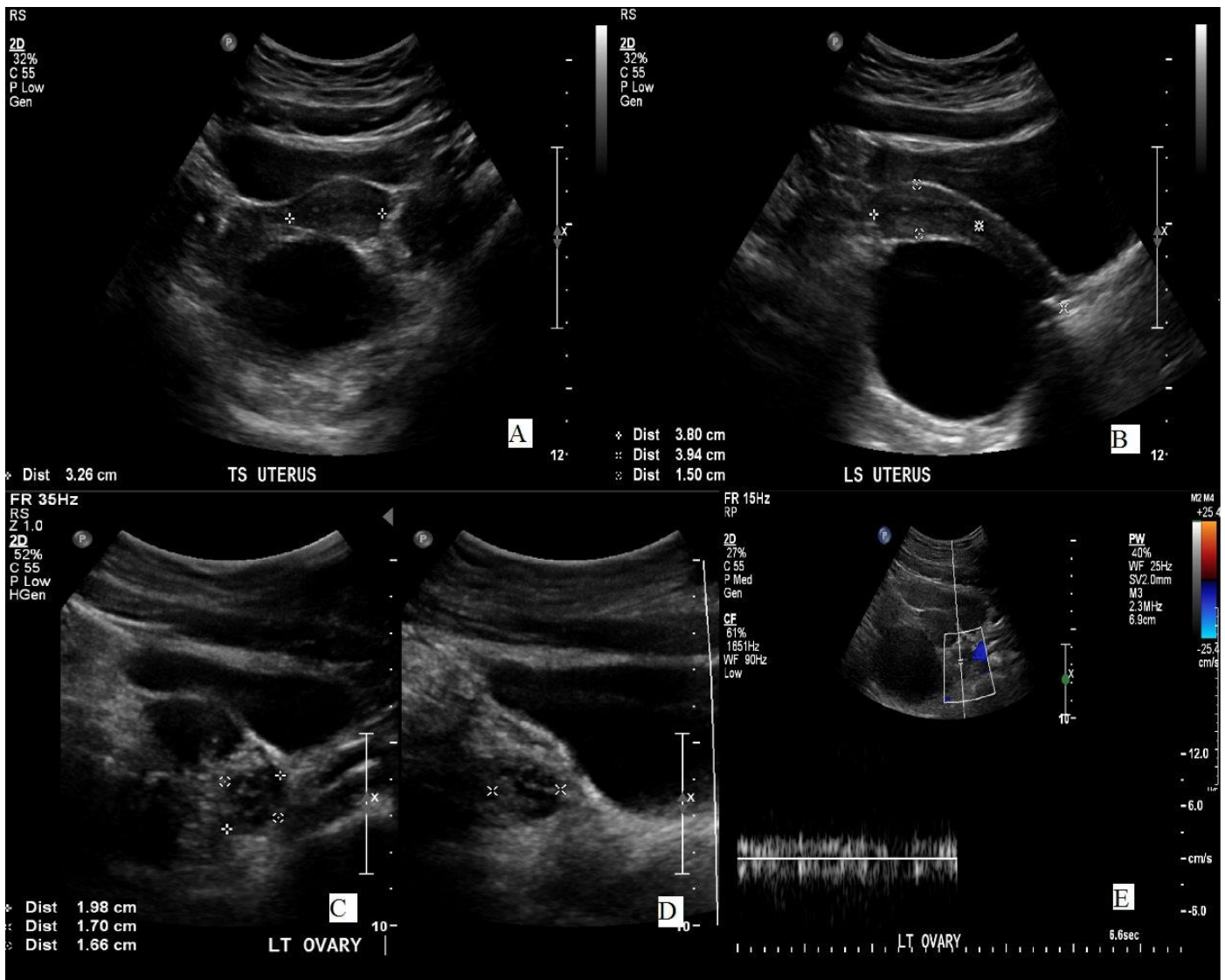


Figure 2: 10 year-old girl with isolated right fallopian tube torsion with fimbrial cyst.
Technique: Transabdominal ultrasonography performed on Philips iU22 ultrasound machine using a 5 MHz curved transducer.
Findings: Transverse and longitudinal views demonstrate normal anteverted uterus (A and B) measuring 7.7 x 3.3 x 1.5 cm. The left ovary measures 2.0 x 1.7 x 1.7 cm (C and D). Color Doppler US (E) shows normal venous flow on the left ovary.

Journal of Radiology Case Reports

www.RadiologyCases.com

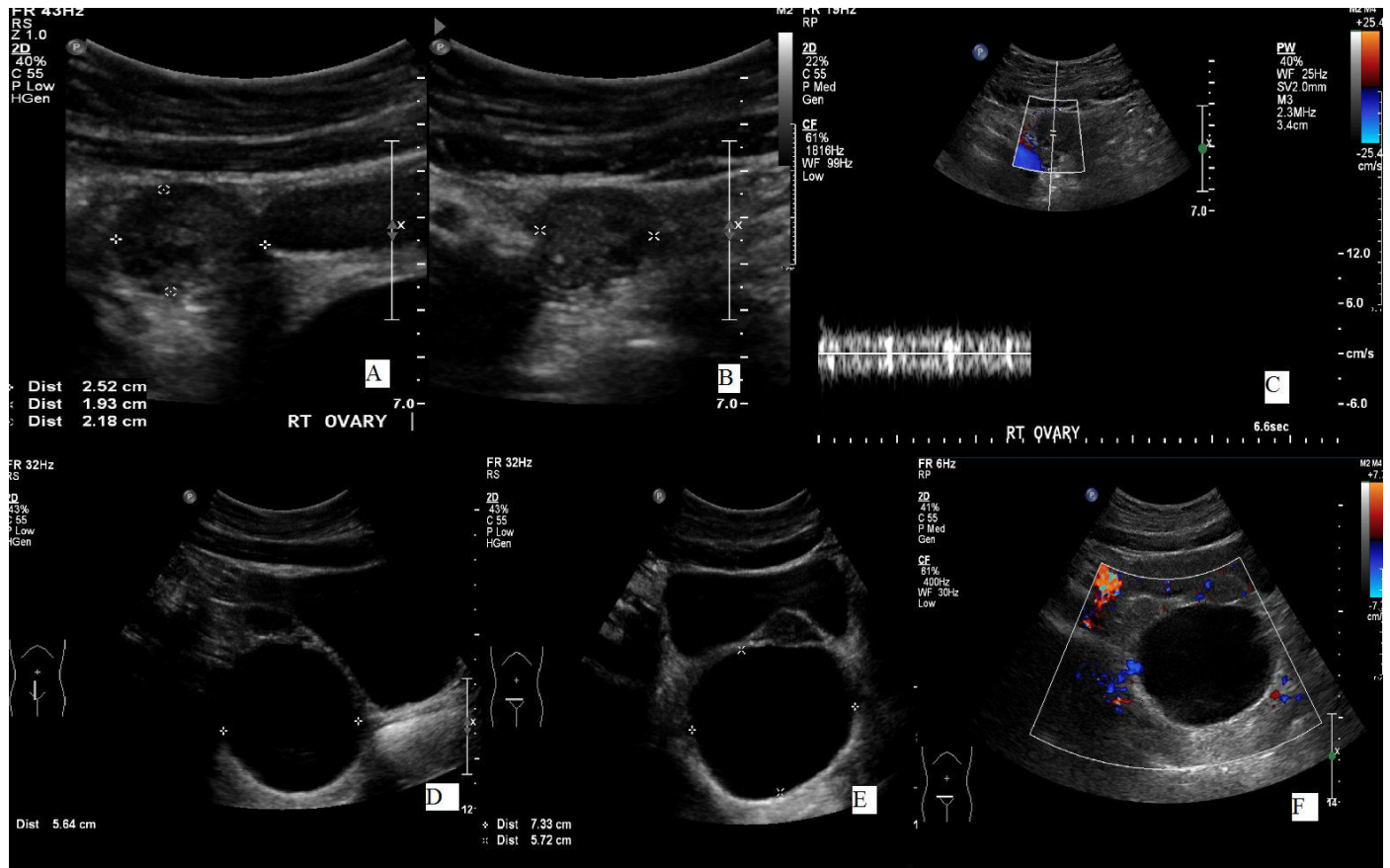


Figure 3: 10 year-old girl with isolated right fallopian tube torsion with fimbrial cyst.

Technique: Transabdominal ultrasonography performed on Philips iU22 ultrasound machine using a 5 MHz curved transducer. Findings: Transverse and longitudinal views demonstrate normal right ovary (A and B) measuring 2.5 x 1.9 x 2.2 cm. Color Doppler US (C) shows normal venous flow on the right ovary. Longitudinal and transverse views demonstrate a large unilocular cystic structure (D and E) in the pouch of Douglas measuring 5.6 x 7.3 x 5.7 cm. Color Doppler US (F) shows no significant vascularity in the cystic lesion.

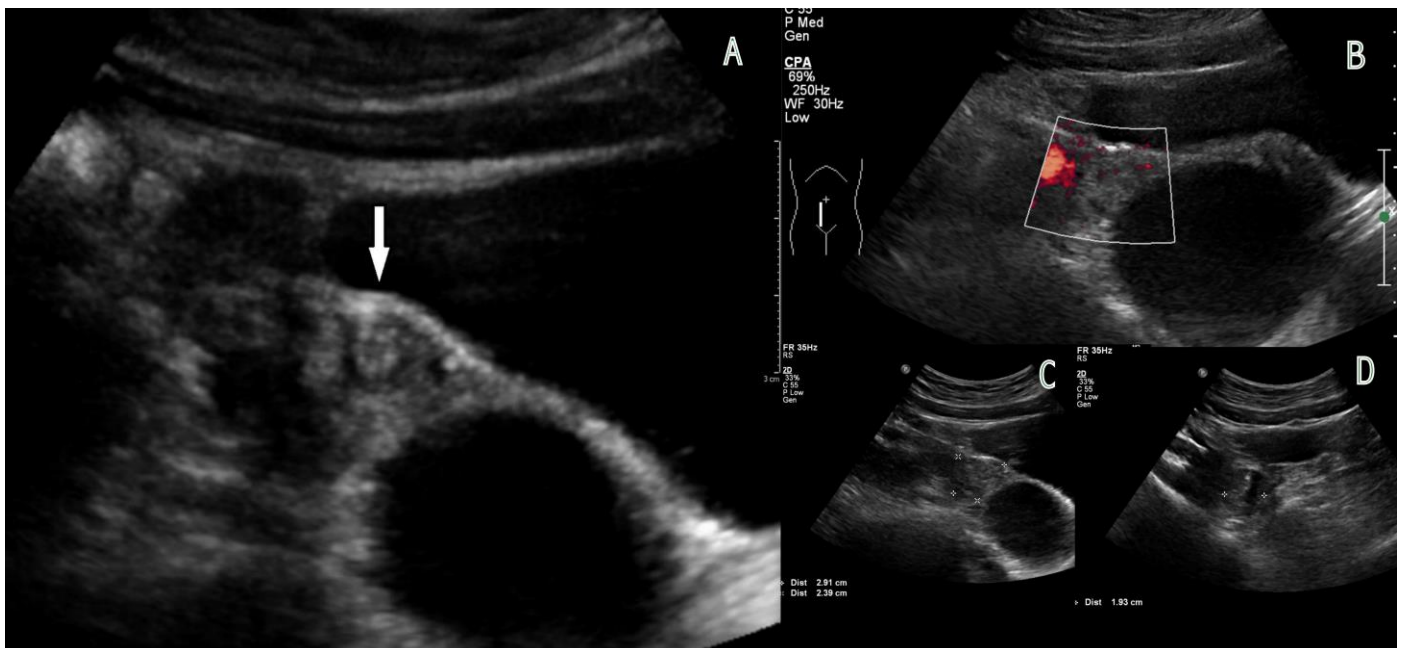


Figure 4: 10 year-old girl with isolated right fallopian tube torsion with fimbrial cyst.

Technique: Transabdominal ultrasonography performed on Philips iU22 ultrasound machine using a 5 MHz curved transducer. Findings: Transverse view (A) shows a convoluted echogenic structure (white arrow). Transverse and longitudinal views (C and D) showed convoluted echogenic structure between the normal right ovary and the pouch of Douglas cyst measuring 2.9 x 2.4 x 1.9 cm. Color Doppler US (B) shows no significant vascularity in the convoluted echogenic structure.

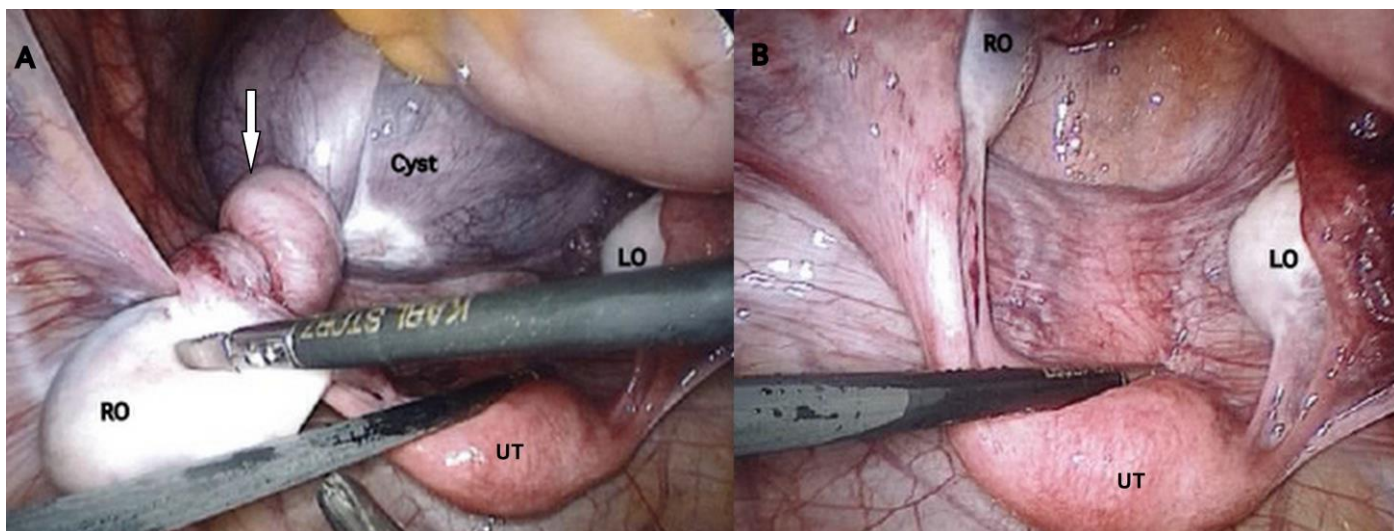


Figure 5: 10 year-old girl with isolated right fallopian tube torsion with fimbrial cyst. Findings: There is 1080degrees (3x) torsion of the right fallopian tube (A). The fimbrial cyst is seen adjacent to the torted fallopian tube (cyst). The right ovary (RO), uterus (UT) and left ovary (LO) are normal in appearance. Circulation of the right fallopian tube was normal after detorsion (B).

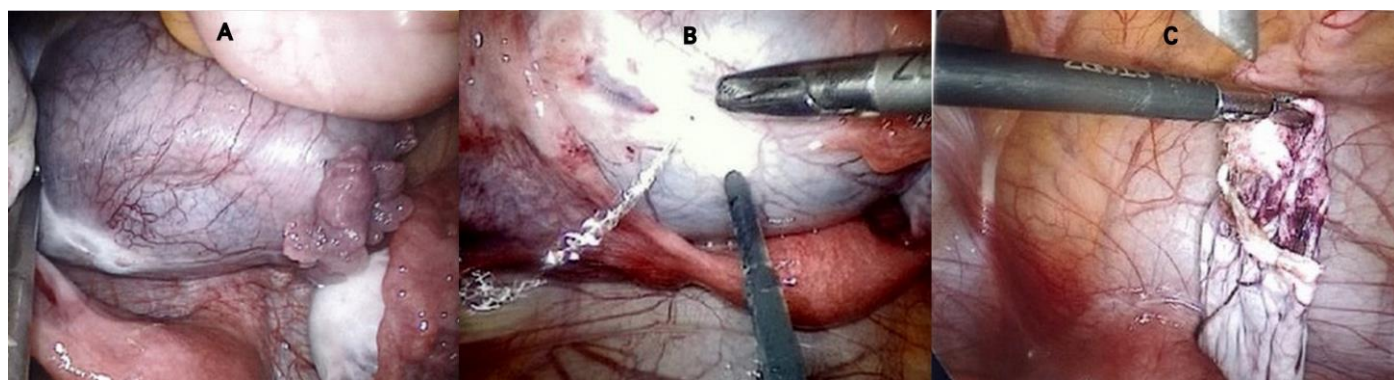


Figure 6: 10 year-old girl with isolated right fallopian tube torsion with fimbrial cyst. Findings: There is large fimbrial cyst seen in the right adnexal region (A). The fimbrial cyst was ruptured and clear fluid was seen oozing out (B). The collapsed cyst was removed and sent for histopathological examination (C).

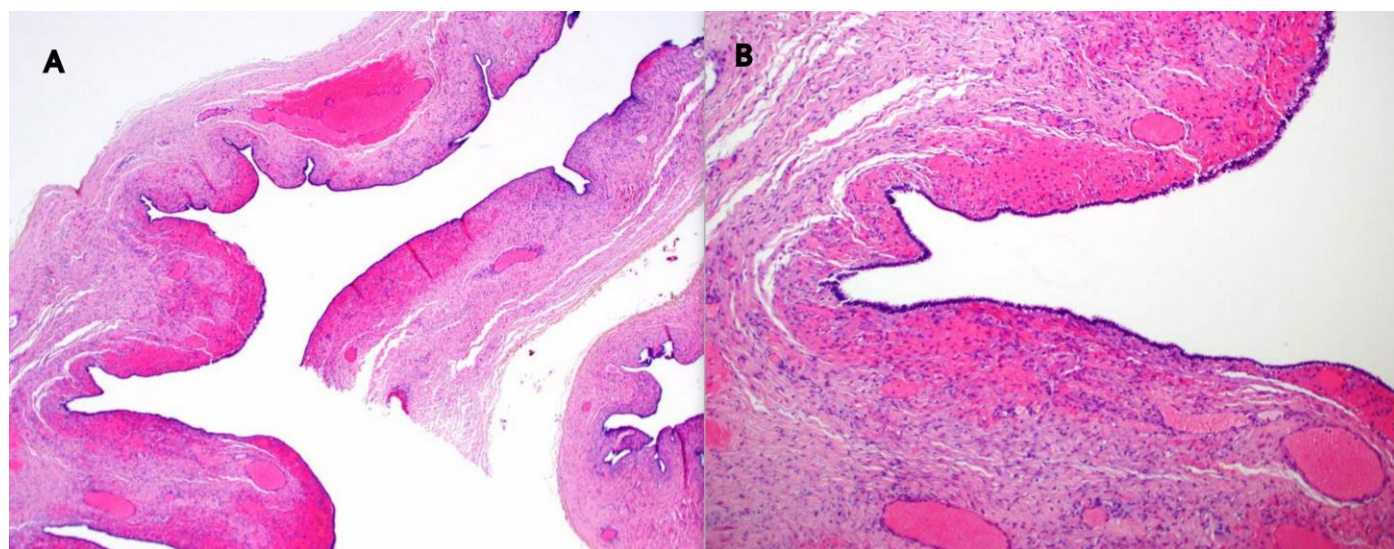


Figure 7: 10 year-old girl with isolated right fallopian tube torsion with fimbrial cyst. Findings: Histopathologic examination. Hematoxylin-eosin, x40 (A) and x100 (B) showed fibrous cyst wall lined by tubal type ciliated columnar epithelium. No atypical features were seen. No malignancy was identified.

ETIOLOGY	Uncertain
INCIDENCE	1 in 1.5 million women
GENDER RATIO	Female patients
AGE PREDILECTION	Common in reproductive age group women, uncommon in post –menopausal women and children
RISK FACTORS	<p>Extrinsic factors: changes in the neighboring organs (neoplasm, adhesions or pregnancy), mechanical factors, movement or trauma to pelvic organs and pelvic congestion</p> <p>Intrinsic factors: congenital anomalies (excessive length or spiral course of the tube), acquired pathology (hydrosalpinx, hematosalpinx, neoplasm or surgery) and autonomic dysfunction or abnormal peristalsis</p>
TREATMENT	Complete or Partial Salpingectomy, Detorsion
PROGNOSIS	Recurrence after detorsion has been reported.
FINDINGS ON IMAGING	<ul style="list-style-type: none"> • Ultrasound: normal appearing ovaries with normal flow, free fluid, dilated fallopian tube with thickened echogenic walls and internal debris; convoluted structure (twisted pedicle) or whirlpool sign on either side of the tube • Doppler study: shows high -impedance or absence of flow in a tubular structure • CT: adnexal cystic mass, twisted appearance of the fallopian tube, dilated tube greater than 15 mm, a thickened and enhancing tubal wall, and luminal CT attenuation greater than 50 HU, consistent with hemorrhage • MRI: non-enhancement of fallopian tube, enlarged and tortuous fallopian tube with normal ipsilateral ovary and an equivocal mass near the uterus

Table 1: Summary table of key aspects of isolated fallopian tube torsion.

	Isolated Fallopian Tube Torsion with Fimbrial cyst	Torsion of Ovary with Ovarian cyst	Isolated Paraovarian/Fimbrial cyst torsion
Ultrasound	Cyst in cul-de-sac or superior to uterus,; convoluted structure (twisted pedicle) in adnexal region; normal ovary with flow	Enlarged and edematous ovary, ovarian cyst, abnormal ovarian location, free fluid	Adnexal cyst separate from ovary, fluid in the pouch of Douglas
Doppler Study	High impedance or absence of flow in a tubular structure	Little or no intra-ovarian venous flow, absent arterial flow, absent or reversed diastolic flow, or normal flow (occasionally)	Normal flow on ovary and fallopian tube
CT Scan	Adnexal cystic mass, twisted appearance of fallopian tube, dilated tube greater than 15 mm, thickened and enhancing tubal wall, and luminal CT attenuation >50 (hemorrhage)	Enlarged ovary, ipsilateral ovarian cyst, deviation of the uterus to and engorged blood vessels on the twisted side, complete absence of enhancement	Hypodense cystic mass separate from the ovary, twisted pedicle
MRI	Non-enhancement of fallopian tube, enlarged and tortuous fallopian tube with normal ipsilateral ovary and an equivocal mass near the uterus	Same as CT scan findings	Adnexal cyst that is separate from the ovary, twisted pedicle

Table 2: Differential diagnosis table for isolated fallopian tube torsion with fimbrial cyst.

ABBREVIATIONS

CRP - C-reactive protein
 CT - Computed tomography
 IFTT - Isolated fallopian tube torsion
 MRI - Magnetic resonance imaging
 NV - normal value
 US – Ultrasound

KEYWORDS

isolated torsion; fallopian tube torsion; adnexal torsion; fimbrial cyst; paraovarian cyst; ultrasound

ACKNOWLEDGEMENTS

We would like to acknowledge Dr. Leong May Ying from the Department of Pathology KK Women's and Children's Hospital, Singapore, for providing the histopathological images of the fimbrial cyst used in this paper.

Online access

This publication is online available at:
www.radiologycases.com/index.php/radiologycases/article/view/2565

Peer discussion

Discuss this manuscript in our protected discussion forum at:
www.radiopolis.com/forums/JRCR

Interactivity

This publication is available as an interactive article with scroll, window/level, magnify and more features.
 Available online at www.RadiologyCases.com

Published by EduRad



www.EduRad.org