

# Pulmonary Embolism following Endovenous Laser Ablation (EVLA) of the Great Saphenous Vein

Nnamdi Nwaejike<sup>1,2</sup>, Paul D. Srodon<sup>1</sup>, Constantinos Kyriakides<sup>1,2\*</sup>

1. Department of Vascular and Endovascular Surgery, Bart's and the London NHS Trust, The Royal London Hospital, London, UK.

2. Queen Mary's School of Medicine and Dentistry, University of London, London, UK

\* **Correspondence:** *Constantinos Kyriakides, Department of Vascular and Endovascular surgery, Bart's and the London NHS Trust, The Royal London Hospital, Whitechapel, London, E1 1BB, UK*

(✉ [constantinos.kyriakides@bartsandthelondon.nhs.uk](mailto:constantinos.kyriakides@bartsandthelondon.nhs.uk))

Radiology Case. 2008 Aug; 2(2):9-12 :: DOI: 10.3941/jrcr.v2i2.25

## ABSTRACT

A 70yr old lady presented to accident and emergency with sudden onset pleuritic chest pain. A pulmonary embolus (PE) was diagnosed by CTPA. Ten days earlier she had bilateral EVLA for recurrent great saphenous vein disease. Confounding risk factors for pulmonary embolism included bilateral ligation and stripping of the great saphenous vein a year earlier, malignancy, EVLA and phlebotic tributary varices. EVLA has been shown to be an effective treatment for superficial venous insufficiency with low morbidity and high patient satisfaction. The investigation of confounding risk factors and possible causes should not compromise the initial treatment of PE.

## CASE REPORT

A 70 year old lady presented to accident and emergency complaining of sudden onset pleuritic chest pain. Ten days prior she had undergone elective bilateral EVLA (Fig. 1) with avulsion phlebectomies of varices for recurrent varicose vein disease as an outpatient procedure. There were a number of phlebotic tributary varices that could not be avulsed at the time of surgery. Post operative on-table duplex ultrasound had confirmed collapse of the treated great saphenous vein with some intra-mural thrombus which did not extend into the femoral vein.

Her past medical history included previous bilateral ligation and stripping of the great saphenous vein (1yr ago); radiation therapy for laryngeal carcinoma (11yrs ago); Naevus Lipomatosis Superficialis excised from left forearm (this year); distal radius fracture (7yrs ago) and a hospital admission for severe pneumonia (1yr ago).

There was no family history of venous thrombosis. She had one son and there was no history of miscarriages. She stopped smoking twelve years ago, drinks very little alcohol and has a reasonable diet.

She had no clinical signs of a DVT, Well's score calculated by the Wells diagnostic algorithm<sup>1</sup> was 4.5, arterial blood gases showed respiratory acidosis and initial ECG and chest x-rays (Figs. 2, 3) were un-remarkable compared to pre-operatively.

The Wells diagnostic algorithm is a validated diagnostic scoring system whereby patients are classified as having a high, intermediate or low probability of developing DVT based on history and clinical examination. A score of 3 or more indicates a high risk<sup>1</sup>.

CT pulmonary angiogram (CTPA) revealed thrombus within the upper segmental branches of the right lower lobar pulmonary artery (Figs. 4, 5). She was admitted, commenced on intra-venous heparin then discharged to be on warfarin for six months. She made a full recovery with no adverse side-effects.

Duplex ultrasound scan three months later revealed no thrombus in the deep veins of the leg and a ventilation/perfusion scan seven months later showed small mismatches at the right lung apex and superior segment of the right lower lobe, but ventilation was within normal limits (Fig. 6).

## DISCUSSION

Endovenous laser ablation (EVLA) is a percutaneous minimally invasive technique where the target vein is cannulated under duplex ultrasound guidance (Fig. 1) and ablated with laser energy. First described by Navarro et al in 2001<sup>2</sup>, its use is gradually becoming more widespread as its benefits become widely apparent. EVLA ablation for superficial venous insufficiency has been approved by NICE since March 2004<sup>3</sup>, and has had FDA approval since 2002<sup>4</sup>. It is increasingly requested by patients as it is well tolerated and minimally invasive. Compared to open ligation and stripping of the vein, EVLA is a more accurate procedure and associated with less recurrence, reduced risk of iatrogenic injury, no scars, quicker recovery, less time off work for the patient and quicker throughput for the provider<sup>4-6</sup>.

Heat is delivered by laser energy from the tip of the laser fibre and is conducted to the intima of the vein resulting in functional occlusion of the superficial vessel with a residual intra-mural thrombus. The intra-mural thrombus is reorganized and reabsorbed in time. To minimize the risk of propagation of thrombus into the deep veins two procedural precautions are recommended. First, the tip of the laser should be positioned at least 2cm distal to the sapheno-femoral junction; and second, the patient should be in the Trendelenberg position to collapse the veins prior to activation of the laser. With the veins collapsed there is less blood coagulated by the heating action of the laser on activation, hence a smaller volume of residual intra-mural thrombus which can be a potential source of emboli. Patients should have full length Thromboembolism Deterrent (TED) stockings applied at the end of the procedure. The TED stockings should be worn 24hrs a day for the first week, then at night for the second week. Pre-operative duplex ultrasound scans are used to confirm competent deep venous systems and the absence of deep venous thrombosis (DVT); and the patient is mobilized immediately post-procedure<sup>5,6</sup>.

There are very few reports of pulmonary embolism following EVLA but in this patient there were a number of confounding factors<sup>7,8</sup>. Factors thought to contribute to the formation of thrombi and emboli include increased blood coagulability, reduced mobility and abnormalities of the vessel wall<sup>7</sup>. Specific risk factors for pulmonary embolism in this patient included malignancy, previous varicose vein surgery and superficial venous thrombosis/phlebitis<sup>8</sup>. Pulmonary embolism presents in a variety of ways clinically and doctors need to be aware of the risk factors, maintain a high index of suspicion, and recognize the different presentations. Pulmonary embolisms may be "silent", and many are diagnosed only at postmortem<sup>8</sup>.

Treatment of pulmonary embolism is based on clinical assessment and can be aided by imaging results. Patients may require cardio-pulmonary resuscitation (CPR) on presentation and if so should have a secure airway, good ventilation, assessment of circulation, IV access and appropriate intravenous fluids and inotropes if required. Suspect a massive PE if blood pressure <90mmHg, or a fall of 40mmHg for 15mins not due to other causes<sup>8</sup>.

The BTS guidelines suggest that all patients with a suspected pulmonary embolism on presentation should have a clinical assessment (e.g. Wells diagnostic algorithm<sup>1</sup>). If the patient is high risk it is recommended to start heparin before

proceeding to isotope scan or CTPA if and when the patient is haemodynamically stable.

The BTS guidelines recommend an isotope scan of the lungs if available and there is no prior history of lung disease or the patient has a normal chest xray. If not, CTPA is recommended. Our patient had a history of radiation therapy for laryngeal carcinoma and had been recently admitted with severe pneumonia so a CTPA was the preferred option.

If intermediate risk on clinical assessment and the patient is haemodynamically stable, there may be time to wait for D-Dimer results. If D-Dimer is positive, commence heparin and proceed to imaging. If D-Dimer is negative, an alternative diagnosis must be sought. Where there is a low risk of PE and patient is haemodynamically stable, D-Dimers must be obtained first and the patient managed according to the results as in intermediate risk<sup>8</sup>.

Quite significantly there were no clinical signs of a DVT when our patient presented with pleuritic chest pain; nor was there evidence of such on immediate post-EVLA ultrasound. The patient had been wearing TED stockings continuously since EVLA treatment. A duplex ultrasound on presentation, looking for propagation of thrombus from the treated great saphenous vein to the femoral vein, would have confirmed if the PE was directly due to EVLA. This would suggest that the pulmonary embolus may have been caused by a combination of all the other confounding factors. Guidelines for the diagnosis and management of a PE<sup>8</sup> ( a medical emergency) emphasize the prompt commencement of anti-coagulation once the diagnosis of PE is made. A duplex ultrasound of the deep leg veins is not recommended initially and was not performed. A duplex ultrasound would have been for educational purposes and not in the best interests of the patient and could potentially have dislodged further thrombi (if present) to the pulmonary circulation. Duplex ultrasound of the leg veins three months later on follow-up showed no DVT or superficial venous thrombi; and ventilation/perfusion scan showed satisfactory lung function.

In conclusion, potential complications following surgery can occur despite good pre-operative investigation, a well-execute procedure and good post-operative care.

## TEACHING POINT

PE is a medical emergency and it is imperative to institute treatment as soon as the diagnosis is confirmed. The treatment of pulmonary embolism is based on clinical assessment and can be aided by imaging results. The investigation of confounding risk factors and possible causes should not compromise the initial treatment of the PE.

## ABBREVIATIONS

EVLA = Endovenous Laser Ablation  
 PE = Pulmonary Embolism  
 ECG = Electrocardiogram  
 CTPA = Computer Topography Pulmonary Angiogram  
 FDA = Food and Drug Administration  
 NICE = National Institute for Clinical Excellence  
 TED = Thromboembolism Deterrent

REFERENCES

1. Wells PS, Ginsberg JS, Anderson DR, Kearon C, Gent M, Turpie AG, et al. Use of a clinical model for safe management of patients with suspected pulmonary embolism. *Ann Intern Med* 1998;129(12):997-1005.
2. Navarro L, Min R, Bone C. Endovenous laser: a new minimally invasive method of treatment for varicose veins--preliminary observations using an 810 nm diode laser. *Dermatol Surg* 2001;27:117-122.
3. IPG052 Endovenous laser treatment of the long saphenous vein - information for people considering the procedure, and for the public (<http://www.nice.org.uk/nicemedia/pdf/IPG052publicinfo.pdf>): National Institute for Clinical Excellence, March 2004.
4. Min R, Khilnani N, Zimmet S. Endovenous Laser Treatment of Saphenous Vein Reflux: Long-Term Results. *J Vasc Interv Radiol* 2003;14:991 - 996.
5. Durai R, Srodon PD, Kyriakides C. Endovenous laser ablation for superficial venous insufficiency. *Int J Clin Pract* 2008.
6. Nwaejike N, Srodon PD, Kyriakides C. Endovenous Laser Ablation for Short Saphenous Vein Incompetence. *Ann Vasc Surg* 2008.
7. Virchow RLK. Thrombose und Embolie. Gefässentzündung und septische Infektion. *Gesammelte Abhandlungen zur wissenschaftlichen Medicin. Frankfurt am Main: Von Meidinger & Sohn* 1856:219-732.
8. The British Thoracic Society Standards of Care Committee PEGDG. BTS Guidelines for the Management of Suspected Acute Pulmonary Embolism, 2003. *Thorax* 2003;48:470-484.

FIGURES

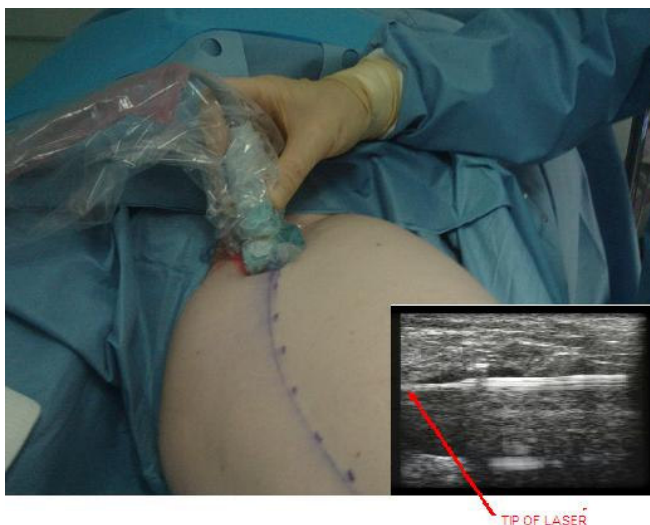

Figure 1: EVLA under ultrasound control

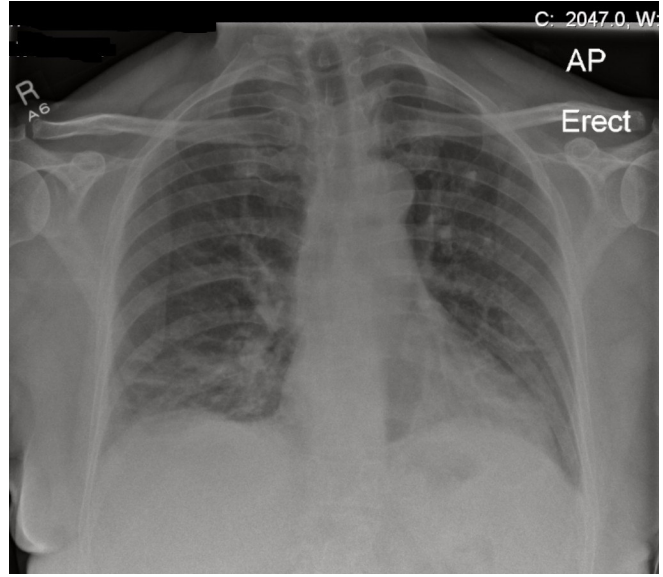


Figure 2: Pre-operative CXR

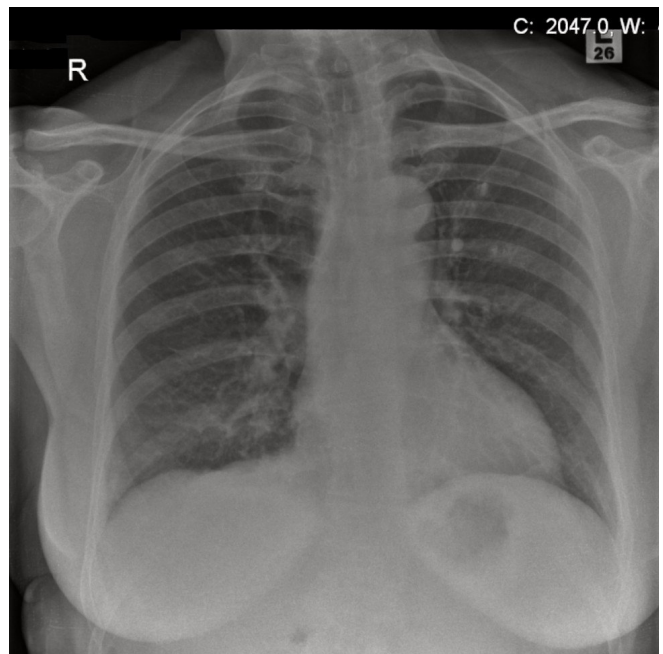


Figure 3: CXR on presentation with PE

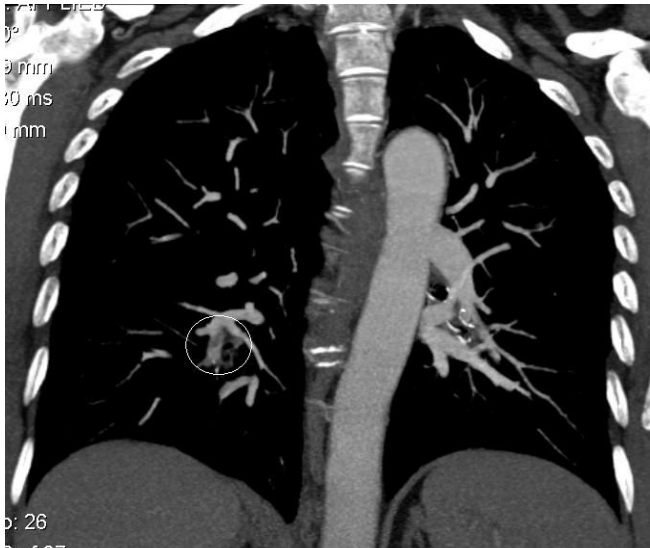

Figure 4: Coronal reformat CTPA showing thrombus within an upper segmental branches of the right lower lobar pulmonary artery (white circle).

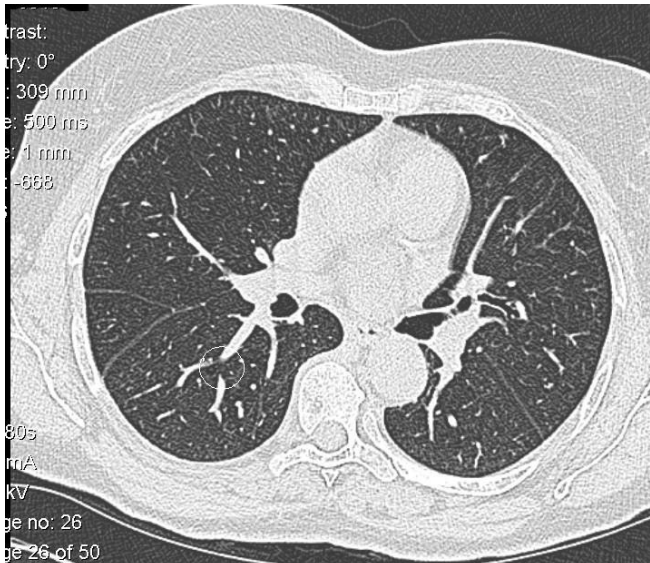


Figure 5: Transverse CTPA cut showing thrombus within an upper segmental branch of the right lower lobar pulmonary artery (white circle).

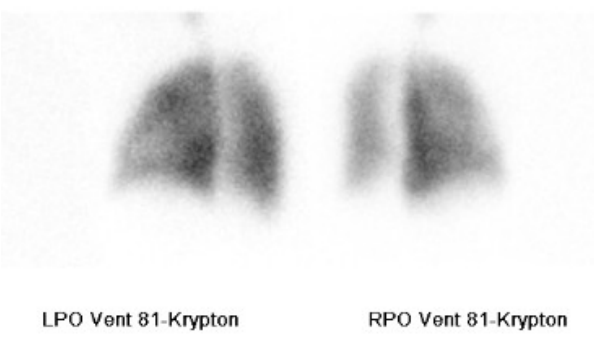
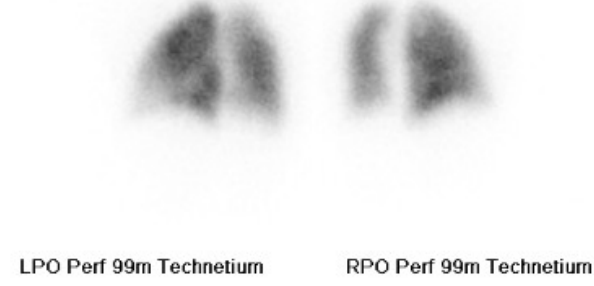
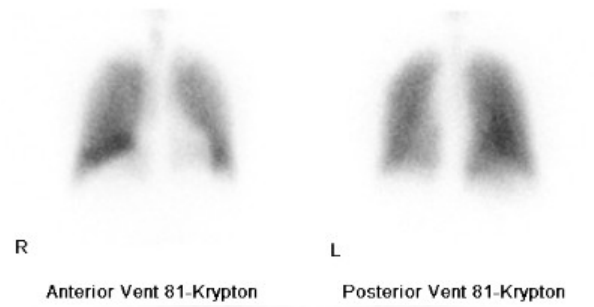
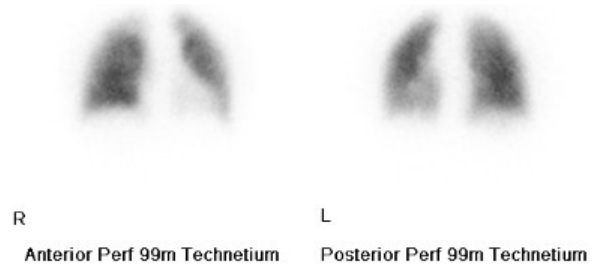


Figure 6: Ventilation Perfusion Scan 7months post diagnosis of PE, demonstrating small mismatches at the right lung apex and superior segment of the right lower lobe.

ACKNOWLEDGEMENTS

We would like to thank Dr S. Spencer and Dr Niall Power (Radiologists who performed the CT Pulmonary Angiogram)

URL of this article:

www.radiologycases.com/index.php/radiologycases/article/view/25

Published by EduRad



www.EduRad.org