

Testicular relapse of non-Hodgkin Lymphoma noted on FDG-PET

Stephen D. Scotti^{1*}, Jennifer Laudadio²

1. Department of Radiology, North Carolina Baptist Hospital, Winston-Salem, NC, USA

2. Department of Pathology, Wake Forest University Baptist Medical Center, Winston-Salem, NC, USA

* **Correspondence:** Stephen D. Scotti, M.D., Department of Radiology, North Carolina Baptist Hospital, Medical Center Blvd., Winston-Salem, NC 27157, USA (✉ [sscotti@sscotti.org](mailto:sscott@sscotti.org))

Radiology Case. 2009 Aug; 3(8):18-24 :: DOI: 10.3941/jrcr.v3i8.242

ABSTRACT

Testicular relapse of leukemia and lymphoma is a well-recognized phenomenon, with testicular relapse of lymphoma being more common in the adult population and leukemia relapse being more common in the pediatric population. With the advent of F-18 fluoro-2-deoxyglucose (FDG) positron emission tomography (PET) in the evaluation of lymphoma it is possible to evaluate testicular uptake of FDG and to detect primary testicular lymphoma or testicular relapse on the FDG-PET examination. Testicular relapse of non-Hodgkin lymphoma (NHL) detected on FDG-PET has been reported previously. We report an additional case in which there was testicular activity at presentation, a response to therapy (orchietomy not performed) and then testicular relapse followed by orchietomy. We review the literature with regard to testicular recurrence and testicular uptake of FDG-PET. There have been studies that have examined normal standardized uptake value maximum (SUVmax) values in the testicle, with normal values ranging from 2.81 (30-39 years) to 2.18 (80-89 years), depending upon age. However, it should be noted that there could be considerable variability in SUVmax values depending upon the units used (e.g. normalized to lean body mass vs. body weight) and depending upon examination variables such as dietary conditions, muscle uptake or extravasation of FDG. Elevated activity or lateralizing activity should be viewed with suspicion, with etiologies including primary testicular tumor, primary or secondary testicular lymphoma and metastatic disease with other etiologies less likely.

CASE REPORT

CASE REPORT

The patient was a 50-year-old male at presentation when he began experiencing low back pain, weight loss, abdominal pain, early satiety and dysuria. A computed tomography (CT) scan was performed and demonstrated retroperitoneal and abdominal adenopathy (Fig 1). A positron emission tomography-computed tomography (PET/CT) performed the following day demonstrated the same findings with posterior

mediastinal adenopathy, abdominal adenopathy and right testicular involvement with a SUVmax of 9.6 (Fig 2). Biopsy of a retroperitoneal lymph node at this time revealed non-Hodgkin's lymphoma, large cell type. He then underwent chemotherapy with Rituxan followed by Etoposide, Vincristine, Adriamycin, Prednisone and Cyclophosphamide (EPOCH), followed by additional cycles of Rituxan/EPOCH. A followup PET/CT performed 3 months after presentation demonstrated positive response of the adenopathy to therapy

and testicular uptake that was more symmetric, with SUVmax 5.3 on the right and SUVmax 4.2 on the left (Fig 3). PET/CT performed 7 months after presentation demonstrated some mild asymmetric activity in the testicles with SUVmax on the right of 4.4 and SUVmax on the left of 3.7 (Fig 4). No other active disease by PET/CT was reported. PET/CT performed 11 months after presentation demonstrated recurrent isolated uptake in the right testicle with SUVmax of 12.4 (Fig 5). This was followed by an ultrasound examination (Fig 6 and Fig 7) and orchiectomy which showed diffuse large B-cell lymphoma infiltrating the testicle and staining positive for CD20, a B-cell antigen and B-cell tumor antigen against which Rituxan is directed (Fig 8 and Fig 9).

DISCUSSION

Testicular lymphoma can be either primary or secondary. Lymphoma (primary and secondary) of the testis accounts for 5% of all testicular malignancies and 1% of all lymphomas. It is the most common testicular malignancy in patients older than 60 years of age. (1).

In one study examining 388 male patients with non-Hodgkin lymphoma from 1975 to 1988, 8 patients (2%) had testicular involvement. 2 cases were considered to be primary, 4 systemic disease and 2 as secondary or late complications. 203 autopsies from the same study examining 124 male patients found 11 cases (8.9%) with testicular involvement, with only 2 of these known prior to autopsy (2).

An early study examining autopsy findings in leukemia and lymphoma found testicular involvement in 64.3% of 140 male patients with acute leukemia, 22.4% of 76 male patients with chronic leukemia and 18.6% of patients with lymphosarcoma (NHL). None of the 44 patients with Hodgkin's disease had testicular involvement (3).

In primary testicular lymphoma involvement of extranodal sites such as the contralateral testis, CNS, skin and Waldeyer's ring is common and there is a high incidence of relapse, with the CNS sometimes being the only site of recurrence (1). Whether the lymphoma is secondary or primary there is some resistance to treatment related to the blood-testis barrier. This normally functions to protect developing germ cells against harmful agents and immunological influences, although this is problematic in the treatment of testicular tumors and testicular lymphoma (4). In our case the involvement was likely secondary and was likely present at presentation with an initial response to therapy and eventual relapse within the testicle.

The metabolic activity within the testicles is usually somewhat higher than background or blood pool activity. In a study examining 406 testes in 203 patients undergoing PET/CT for other indications (117 lung cancer, 16 head and neck, 12 colorectal, 6 gastric, 5 melanoma, 4 pancreas, 3 esophagus, 5 other) the SUVmax was 2.44, with the value ranging from 2.81 (30-39 years) to 2.18 (80-89 years) (5). It should be noted that there could be significant variability in SUVmax values within a given institution and between

institution depending upon equipment, the units used for SUVmax values (e.g. normalized to lean body mass or body weight), dietary factors, muscle uptake, blood glucose levels or extravasation of FDG. Any significant elevation in the SUVmax value or asymmetric activity should be viewed with suspicion. One should be familiar with the normal range for testicular activity using their institutional protocols and equipment since values may vary.

TEACHING POINT

NHL testicular lymphoma is FDG avid and can be detected on PET or PET/CT being performed for staging or follow-up of non-Hodgkin lymphoma. An elevated SUVmax value or asymmetric activity should be viewed with suspicion, although one should be cognizant of pitfalls with relying on SUVmax values alone. The testis is an immunologically privileged site and the blood-testis barrier interferes with the delivery of chemotherapeutic agents, making the testis a potential site for relapse.

REFERENCES

1. Even-Sapir E, Lievshitz G, Perry C, Herishanu Y, Lerman H, Metser U. Fluorine-18 Fluorodeoxyglucose PET/CT Patterns of Extranodal Involvement in Patients with Non-Hodgkin Lymphoma and Hodgkins Disease. *PET Clinics* 1(3):251--263.
2. Roho J, Sales V, Paredes A, Soriano J. Non-Hodgkins lymphoma (NHL) of the testicle. A clinicopathologic study of 19 patients. *In Vivo*, 5(3):297-9.
3. Givler RL. Testicular Involvement in Leukemia and Lymphoma. *Cancer* 23(6), 1290-95.
4. Bart J, Groen HJ, van der Graaf WT, Hollema H, Hendrikse NH, Vaalburg W, Sleijfer DT, de Vries EG. An oncological view on the blood-testis barrier. *The Lancet Oncology* 3(6), 357-363.
5. Kitajima K, Nakamoto Y, Senda M, Onishi Y, Okizuka H, Sugimura K. Normal uptake of F18-FDG in the testis: an assessment by PET/CT. *Ann Nucl Med*(41), 405-410.

FIGURES

Figure 1 (right): 50 year old male with retroperitoneal and mediastinal adenopathy. Initial axial chest CT scan with contrast at the level of the splenic vein showing right retrocrural, celiac and mesenteric adenopathy with a "misty" appearance of mesenteric fat. This was the inferior most slice on the scan.

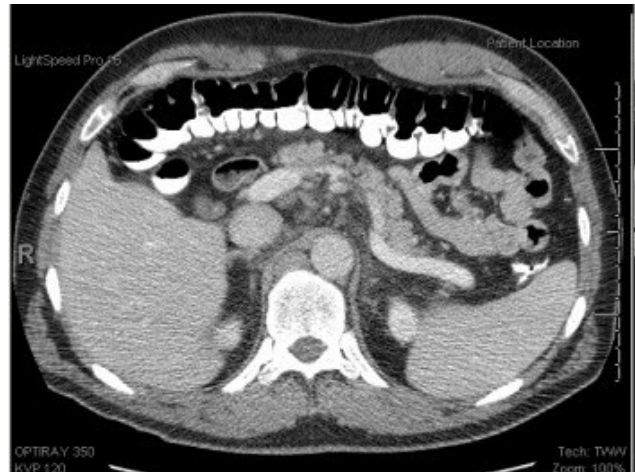

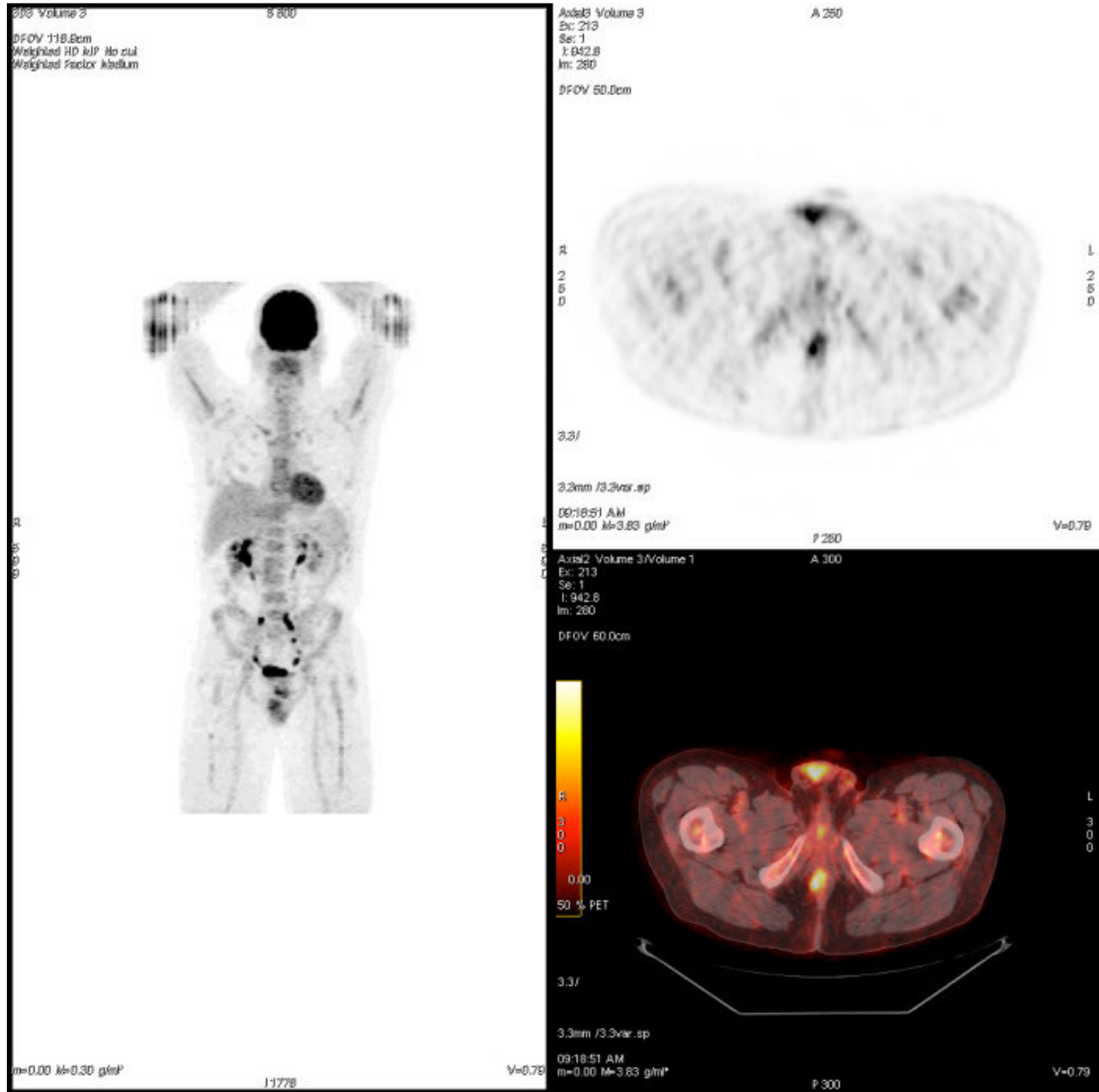
Figure 2 (bottom): 50 year old male with retroperitoneal and mediastinal adenopathy. Coronal MIP, axial PET and axial fused PET/CT performed 1 day after initial chest CT at the level of the testicles after intravenous administration of 14.4 mCi of FDG demonstrating marked hypermetabolic abdominal adenopathy, mediastinal adenopathy and right testicular uptake with SUVmax of 9.6.

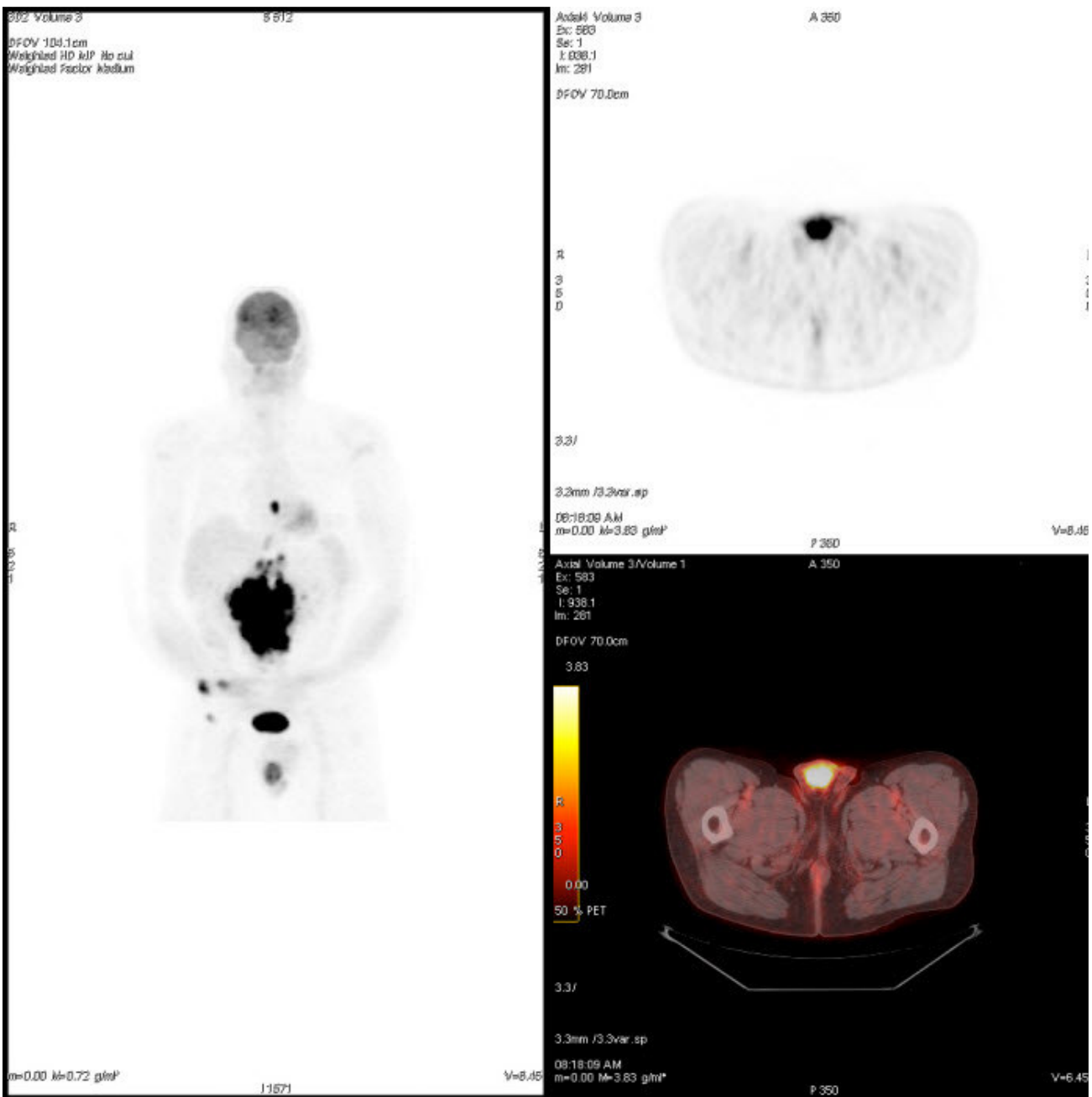



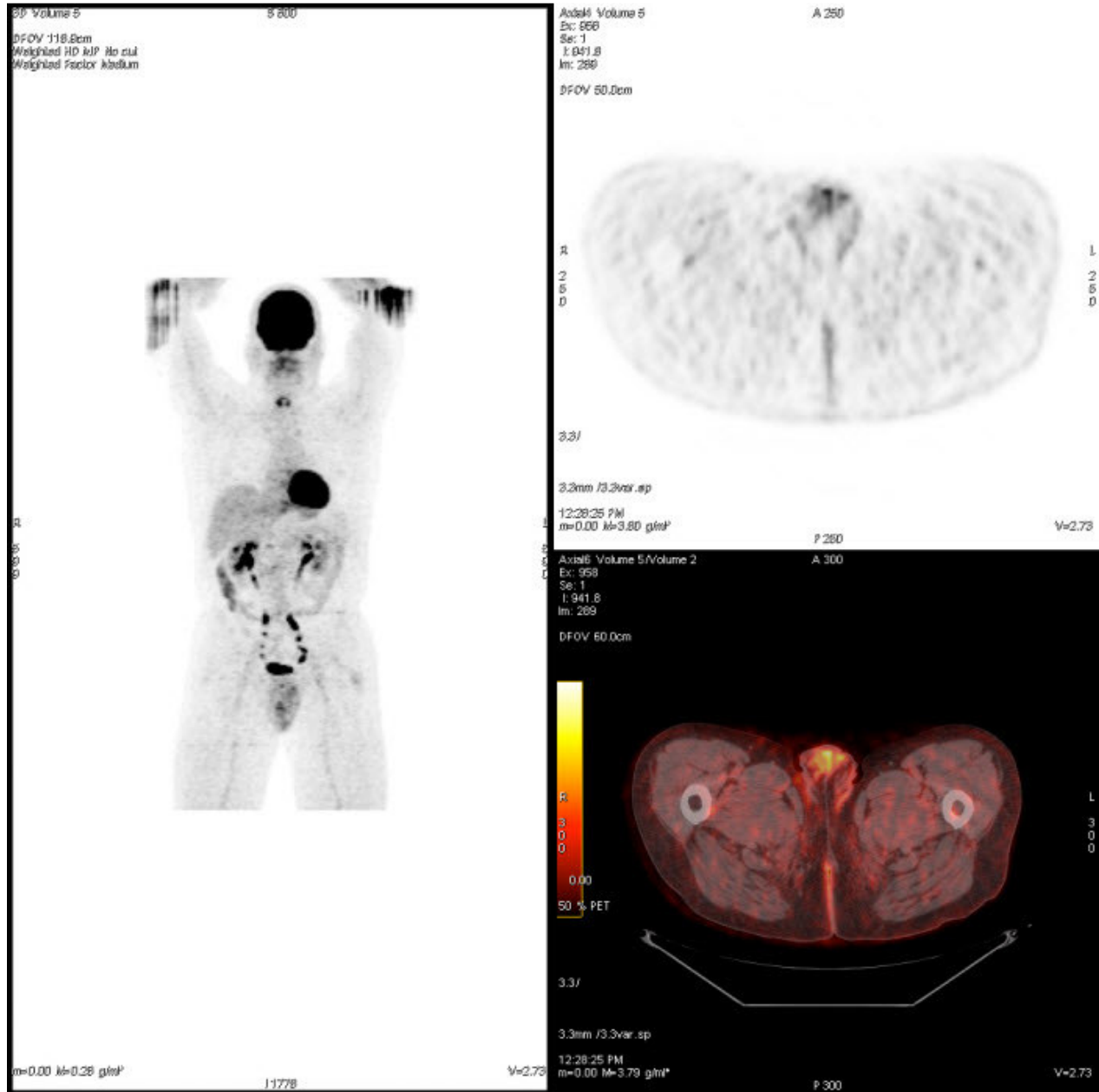


Figure 4: 51 year old male with diffuse large B-cell non-Hodgkin's lymphoma. Coronal MIP, axial PET and axial fused PET/CT performed 7 months after initial chest CT at the level of the testicles after intravenous administration of 14.2 mCi of FDG demonstrating continued response to therapy but with some small residual asymmetric uptake of FDG in the right testicle with SUVmax on the right of 4.4 and SUVmax on the left of 3.7

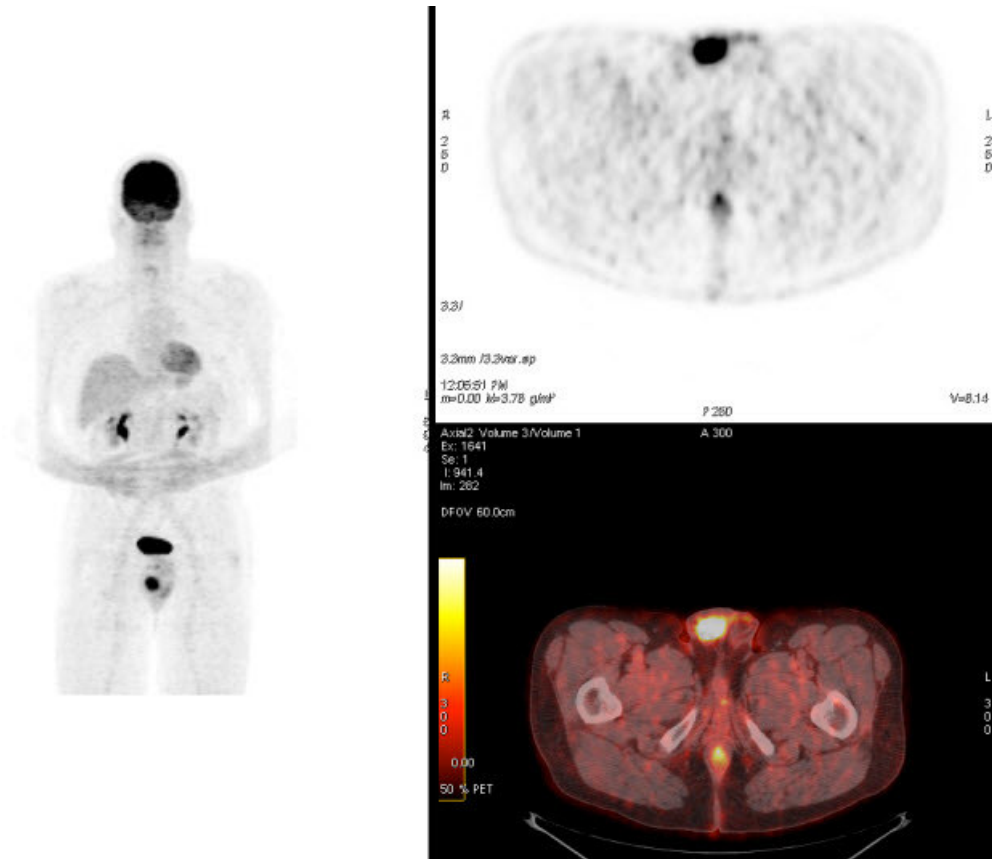


Figure 5: 51 year old male with diffuse large B-cell non-Hodgkin's lymphoma. Coronal MIP, axial PET and axial fused PET/CT performed 11 months after initial chest CT at the level of the testicles after intravenous administration of 15.965 mCi of FDG demonstrating isolated relapse within the right testicle with SUVmax now of 12.4.

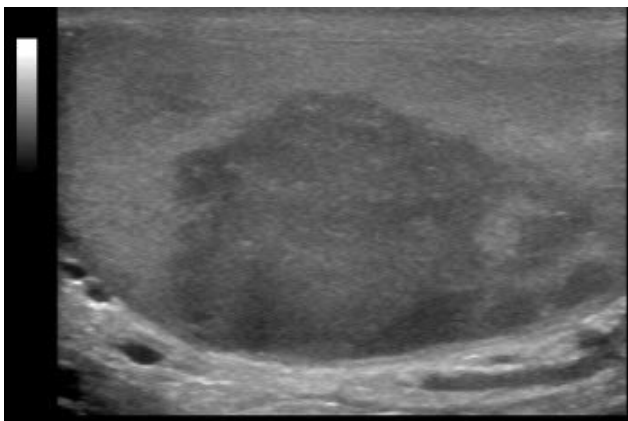


Figure 6: 51 year old male with diffuse large B-cell non-Hodgkin's lymphoma. Sagittal ultrasound using 9 MHz linear GE transducer of the right testicle performed 11 months after initial chest CT showing a hypoechoic mass with irregular lobular margins in the posterior aspect of the right testicle.

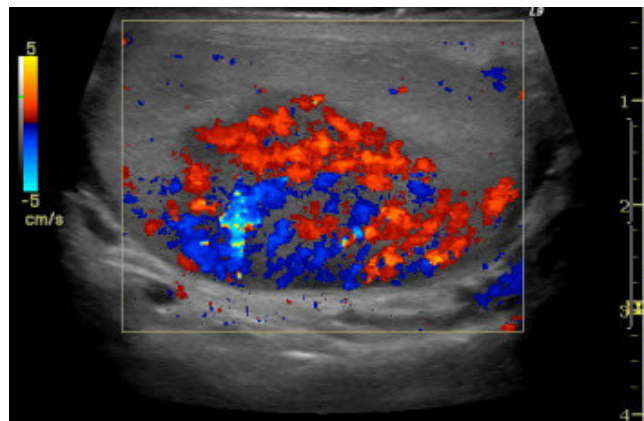


Figure 7: 51 year old male with diffuse large B-cell non-Hodgkin's lymphoma. Sagittal ultrasound using 9 MHz linear GE transducer of the right testicle performed 11 months after initial chest CT with color Doppler at the same level showing the hypervascular nature of the hypoechoic mass in the posterior aspect of the right testicle.

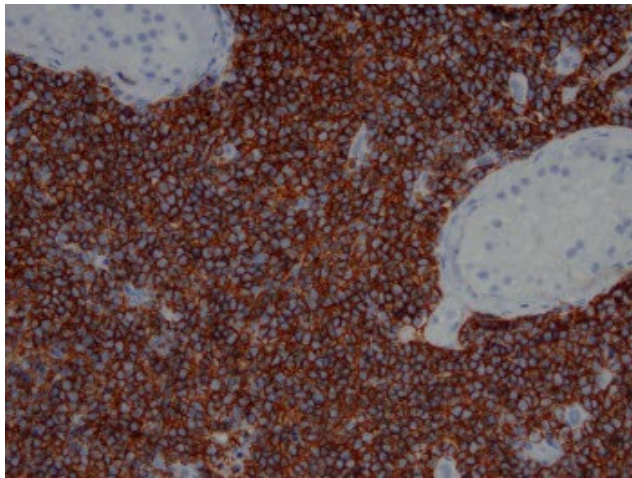


Figure 8: 51 year old male with diffuse large B-cell non-Hodgkin's lymphoma. Right testicular pathologic specimen. H&E 4x - low power view, lymphomatous involvement on right with large atypical lymphocytes infiltrating around and destroying seminiferous tubules. Back to back seminiferous tubules on left side of image showing area without lymphomatous involvement.

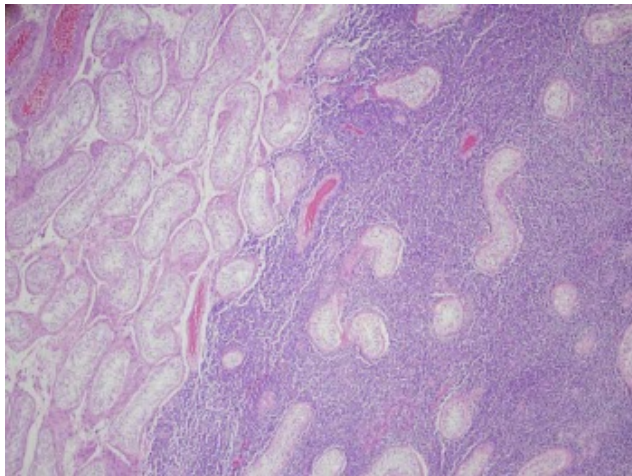


Figure 9: 51 year old male with diffuse large B-cell non-Hodgkin's lymphoma. Right testicular pathologic specimen. 20x CD20 immunohistochemical stain for B-cells showing positivity of the lymphoma cells for CD20.

ABBREVIATIONS

EPOCH: Etoposide, Vincristine, Adriamycin, Prednisone and Cyclophosphamide
 FDG: F-18 fluoro-2-deoxyglucose
 mCi: milliCurie
 MHz: Megahertz
 MIP: Maximum Intensity Projection
 NHL: non-Hodgkin lymphoma
 PET: positron emission tomography
 PET/CT: positron emission tomography-computed tomography
 SUVmax: standardized uptake value maximum

KEYWORDS

Non-Hodgkin's Lymphoma, testicular lymphoma, PET/CT, PET

Online access

This publication is online available at:
www.radiologycases.com/index.php/radiologycases/article/view/242

Interactivity

This publication is available as an interactive article with scroll, window/level, magnify and more features.
 Available online at www.RadiologyCases.com

Published by EduRad



www.EduRad.org