

# Incidental Anterior Cruciate Ligament Calcification: Case Report

Hisami Hayashi<sup>1\*</sup>, Hans Fischer<sup>1</sup>

*1. Department of Radiology, UCLA Harbor Medical Center, Torrance, USA*

\* **Correspondence:** Hisami Hayashi, 1000 West Carson Street Hospital 2nd floor, Box 27 Torrance, CA 90509, USA  
(✉ [hhayashi@dhs.lacounty.gov](mailto:hhayashi@dhs.lacounty.gov))

Radiology Case. 2016 Mar; 10(3):20-27 :: DOI: 10.3941/jrcr.v10i3.2319

## ABSTRACT

The calcification of knee ligaments is a finding noted only in a handful of case reports. The finding of an anterior cruciate ligament calcification has been reported once in the literature. Comparable studies involving the posterior cruciate ligament, medial collateral ligament and an ossicle within the anterior cruciate ligament are likewise discussed in reports of symptomatic patients. We report a case of incidentally discovered anterior cruciate ligament calcification. We discuss the likely etiology and clinical implications of this finding.

## CASE REPORT

### CASE REPORT

An 82-year-old male with a history of hypertension, diabetes and unconfirmed asbestosis was a restrained driver in a motor vehicle accident. The patient presented with lacerations to his face, right upper and lower extremities. The patient was found to have sustained a tibial plateau fracture and a non-operable right transverse process fracture at L2 and L3. In addition to the comminuted Schatzker II fracture of the lateral right tibial plateau with depression, chondrocalcinosis and severe joint disease, calcification of the anterior cruciate ligament was found. The patient did not report knee trauma prior to his motor vehicle accident and presentation to the emergency room, he stated only that he was a retired brick layer with to-be-expected joint pain.

On admission, antero-posterior and lateral radiographs of the right knee demonstrated the tibial plateau fracture (figure 2). A CT of his lower extremity revealed a comminuted fracture of the lateral right tibial plateau with depression, chondrocalcinosis of the medial meniscus, severe degenerative disease and calcification of the anterior cruciate ligament (figure 1).

Shortly thereafter, the patient underwent open reduction internal fixation of his tibial plateau fracture. Submeniscal

arthrotomy revealed a medially displaced lateral meniscus with displaced and depressed fracture fragments some of which were intraarticular. Fragments were pinned, a lateral tibial plateau periarticular nonlocking plate was implanted and lateral meniscus was repositioned and sutured in place. Provided the various traumatic injuries the anterior cruciate ligament calcification could not be appreciated. Unfortunately, pathological tissue could not be acquired for histological examination.

Blood tests performed during his 7 day hospital stay revealed normal range calcium at 9.2 mg/dL. The patient had normocytic anemia with hemoglobin of approximately 10 gm/dL. Glucose ranged from 136 to 201 in the setting of acute trauma. The patient developed a mild leukocytosis following his operation which normalized. Hematologic and biochemical tests were otherwise within normal limits.

Antero-posterior and lateral radiographs of the right knee following the procedure demonstrated the tibial plateau fracture in near anatomic alignment with hardware in place (figure 2).

Following the surgery, the patient was able to perform range of movement exercises without difficulty and basic transfer of weight exercises with minimal assistance. The

patient refused acute inpatient rehabilitation and so was discharged. He failed to return 2 weeks after discharge to orthopedic clinic for wound check and staple removal. As such, delayed post-procedure imaging could not be attained.

## DISCUSSION

Few cases involving largely isolated symptomatic calcifications of a ligament within the knee have been reported. Of note, trauma is not clearly identified in all cases as the clear etiology [1, 2]. In each case with exception of the medial collateral ligament wherein calcification is restricted in location to the femoral attachment without involvement of the whole ligament and discrete from the synovium, pain is assumed to be derived from increased pressure on the synovium which is exerted from deposition of calcium within the ligament [3].

### Etiology & Demographics:

As calcification of the anterior cruciate ligament is a rare occurrence in the literature discussed only in select case reports, determination of incidence, sex and age predilection is limited and unknown.

Trauma is the most likely predisposing factor for calcification within the ligaments in our patient population with mechanical stress to joints up-regulating mRNA for bone morphogenic proteins which play an important role in bone formation during development and fracture repair but can also induce ectopic osteogenesis [4, 5]. Other possible etiologies discussed in the literature include various endocrine disorders including thyroid disorders with associated osteopenia and traumatic sequelae, hypoparathyroidism which is associated with calcium deposition in various organ systems not excluding ligaments and diabetes. Vitamin D resistance which is thought to be associated with low calciuric response is implicated in the progression of ligament calcification, specifically of the spinal ligaments. Medication induced hypercalcemia and hypomagnesemia may contribute to ligament calcification in concert with trauma. Hypervitaminosis A administered to animal models in excess results in osteophytes and heterotopic ossification in tendons and joint capsules. Hormone supplementation, normal cyclic fluctuations of sex hormones and total estrogen levels are positively correlated with the extent of ossification of the posterior longitudinal ligament [4, 6].

In our study, a calcified anterior cruciate ligament was discovered in the context of a post traumatic tibial plateau fracture. The patient though not clearly asymptomatic, had not pursued treatment for knee pain nor had he reported prior trauma. However, the severe degenerative disease of the knee joint seen on imaging may be consequence of his previous profession as a brick layer. With degenerative changes taken into account, traumatic etiology and prior hemorrhage cannot be excluded as a possible cause for the calcification within the ligament. Also of note, the incidental finding of chondrocalcinosis of the medial meniscus may be sporadic in 7-10% of patients over 60 years in age and bears association to

osteoarthritis [2]. Less likely is the supposition that the chondrocalcinosis is secondary to calcium pyrophosphate disease provided a lack of supporting history. The association of incidental chondrocalcinosis and separate calcification of a ligament is not well established although, if all causes for calcium deposition are to be entertained, affliction with both in this patient helps to direct suspicion of potential disease processes. Both chondrocalcinosis and calcification within ligaments and tendons is appreciated with hypoparathyroidism and hypothyroidism. However, these causes will be excluded based on the patient's lack of supporting history and limited blood work including normal calcium levels.

Patients with diabetes mellitus have an increased risk of extraskelatal calcification. Studies have implicated diabetes in the development of hydroxyapatite crystal deposition disease [7], diffuse idiopathic skeletal hyperostosis [8], calcific shoulder peri-arthritis [9], and ossification of the posterior longitudinal ligament [10]. While the etiology by which diabetes mellitus incites these disease entities is not fully understood, studies have shown that diabetes induced angiopathy and associated decrease in blood flow may precipitate calcification of tendons [9]. The decrease in cellular response to insulin or insulin deficiency in diabetics may contribute to the calcification of connective tissue and endochondral calcification as glycosaminoglycan production, collagen synthesis and hastening of the senescence of fibroblasts is retarded [9]. Our patient does have a history of diabetes however; his initial glucose of 136 and high of 201 is not highly suspicious in the setting of his recent trauma and hospitalization. Unfortunately hemoglobin A1c was not attained and further conjecture can not be made on the role of diabetes on the development of his anterior cruciate ligament calcification. Ultimately, his history for repetitive overuse of his joints is most convincing as a cause for all of his incidental findings.

### Clinical & Imaging Findings:

Calcification within a ligament can be seen on various modalities [5]. As calcifications may be diffuse or speckled and evaluation of the joint space limited by technique, plain radiographs may not be as helpful in evaluation for calcification within a ligament. While ultrasound is infrequently the modality of choice for joint pain, calcification within the ligaments has been demonstrated as echogenic foci within the area of interest with variable presentation of acoustic shadowing. Computed tomography, a common modality for early evaluation of the extremity demonstrates calcium within the ligament; Hounsfield units are typically in excess of 200. Provided that the calcification of the ligament is a chronic and benign process, contrast administration should not result in enhancement within the region of calcification. While magnetic resonance imaging was not pursued in our case, a full evaluation of the tendons and ligaments would have been reasonable in our patient. MRI is often pursued in cases of ligamentous calcification as these patients will often present with chronic joint pain. Calcium within the ligament in a diffuse or speckled pattern appears dark on T1, T2 and PD imaging. While there are no reports within the literature of evaluation of anterior cruciate ligament calcification with positron emission tomography or other nuclear medicine

modality, one would assume that based on likely chronicity and benignity of this finding that evaluation with PET would not be informative. Radiopharmaceuticals and fludeoxyglucose uptake should not be abnormal with exception of varied uptake secondary to trauma or arthritis.

In our study, antero-posterior and lateral radiographs of the right knee demonstrated the tibial plateau fracture but failed to show the anterior cruciate ligament calcification (figure 2). A subsequent CT of the lower extremity revealed a comminuted fracture of the lateral right tibial plateau with depression, chondrocalcinosis, severe degenerative disease and the calcification of the anterior cruciate ligament (figure 1).

#### Differential Diagnosis:

The differential diagnosis for calcification of the anterior cruciate ligament is limited. Ossicles within the ligament, osteochondritis dissecans, chondrocalcinosis and joint space mass with associated calcification may be considered when confronted with what appears to be a calcification within the joint space.

#### ***Ossicle within the ligament, loose body, osteochondritis dissecans***

Both an ossicle within the ligament and osteochondritis dissecans with avulsed fragments may appear as radiopaque loose bodies within the region of a ligament on plain film [1]. These benign calcifications may not look particularly dissimilar to calcified ligaments on ultrasound, computed tomography or magnetic resonance imaging. An ossicle however even within the ligament will appear as a well-defined calcification with possible bone marrow signal on MR in contrast to the speckled and diffuse appearance of the calcified ligament we have discussed in this case report. Osteochondritis dissecans can be differentiated typically by localization of the bone fragments which may be near impossible on plain films and ultrasound but should not be particularly difficult on CT or MRI. MRI may demonstrate a structure isointense to bone marrow with or without a hypointense rim within the region of interest. Like ligament calcifications, nuclear medicine studies will only be helpful in identifying inflammatory changes, trauma and arthritis in association with ossicles, loose bodies and bone fragments from osteochondritis dissecans.

#### ***Chondrocalcinosis, renal osteodystrophy***

In regards to calcification, chondrocalcinosis and renal osteodystrophy may present as radiopaque structures within the ligamentum flavum, joint capsule, menisci/hyaline cartilage, and within soft tissues and ligaments [11].

Based on the propensity for chondrocalcinosis and renal osteodystrophy to involve other ligamentous and cartilaginous structures, this etiology should only be entertained in the context of appropriate and contributory medical history and physical exam. If chondrocalcinosis and renal osteodystrophy is the suspected etiology of a calcification within a ligament, it will present very much like the benign calcification of the anterior cruciate ligament discussed in this case. Again, a calcification within a ligament secondary to chondrocalcinosis or renal dystrophy will not typically present as an isolated finding. Nuclear medicine imaging in this instance may be

helpful in ascertaining the full extent of bone and soft tissue involvement. Erosive and inflammatory changes in addition to the potential for a superscan and pseudofractures may be evaluated on bone scan.

#### ***Soft tissue lesion/mass with calcification***

A number of rare soft tissue tumors may involve the joint space; necrosis and subsequent calcification may mimic the appearance of a solitary ligament calcification on plain film and occasionally on ultrasound [12]. Synovial sarcoma may involve the joint typically secondary to local invasion from a juxtaarticular soft tissue primary which is readily identified on CT/MRI or nuclear medicine study. Malignant peripheral nerve sheath tumor is frequently associated with calcification but again an infiltrative mass should be seen on CT/MRI. Extraskelatal osteosarcoma has a soft tissue preference while extraskelatal mesenchymal chondrosarcoma typically occurs in the head and neck. Pleomorphic sarcoma (malignant fibrous histiocytoma) and solitary fibrous tumor may also exhibit calcifications but soft tissue components should not be missed on CT/MRI.

These soft tissue lesions are varied in appearance, etiology, incidence and require histologic examination for full evaluation. Scintigraphy and PET scan may be pursued and will demonstrate varied radiopharmaceutical and FDG uptake depending on aggressiveness and blood supply.

#### Treatment & Prognosis:

Unfortunately, the anterior cruciate ligament could not be examined intraoperatively, nor could a sample for histologic examination be attained from this patient.

In prior studies, histologic examination of removed material yielded calcium deposits and samples resembling that acquired from calcifying tendinitis [12, 13]. Previous case reports have reported that arthroscopic treatment and debridement of the calcium deposits have relieved pain in symptomatic patients [14]. Destruction of calcium deposits may make it possible for calcium remnants to diffuse and reabsorb. Of note, extracorporeal shock wave lithotripsy has been pursued for complications of arthroplasty however, data supporting the use of lithotripsy for ligament calcifications is still lacking.

Regardless, this truly incidental finding of a calcified anterior cruciate ligament in the context of numerous findings suggestive of chronic degenerative change does not necessarily warrant intervention. Physical therapy may be a reasonable first step in a treatment plan and as pain from ligament calcification is thought to be secondary to increased pressure on the synovium, anti-inflammatory medication may serve some benefit. In terms of prognosis, it would seem that for both those patients wherein treatment through debridement is warranted and for those where it is not, prognosis is promising.

TEACHING POINT

The significance of rarely discussed calcification within knee ligaments is uncertain with previous case reports drawing conclusions about the clinical implications of ligament calcifications based on symptomatic relief following surgical removal. Incidentally discovered and asymptomatic anterior cruciate ligament calcifications raise the possibility that such a finding when encountered in practice may represent a chronic benign condition of little to no clinical significance.

REFERENCES

1. Devgan A, Mukhopadhyay R, Singh A, Gogna P, Singla R, Kumar Magu N. Ossicle in Anterior Cruciate Ligament: A Rare Occurrence. *Case Reports in Orthopedics*. 2014 April 13; 2014. PMID: 24822144
2. Seeger L, Sako E, Motamedi K, Levine B, Hame S. Intra-articular calcifications following arthroscopic ACL reconstruction: prevalence and possible significance. *Skeletal Radiology*. 2014 Feb 7; 43(2):209-12. PMID: 24318070
3. Koukoulis N, Papastergiou S. Isolated posterior cruciate ligament calcification. *BMJ Case Reports*. 2011 Dec. PMID: 22669889
4. Li H, Jiang L, Dai L. Hormones and growth factors in the pathogenesis of spinal ligament ossification. *European Spine Journal*. 2007 Aug; 16(8): 1075–1084. PMID: 26210684
5. O'Brien EJ, Frank CB, Shrive NG, Hallgrímsson B, Hart DA. Heterotopic mineralization (ossification or calcification) in tendinopathy or following surgical tendon trauma. *International Journal of Experimental Pathology*. 2012 Oct; 93(5):319-31. PMID: 22974213
6. Harvie P, Pollard TC, Carr AJ. Calcific tendinitis: natural history and association with endocrine disorders. *Journal of Shoulder and Elbow Surgery*. 2007 Mar-Apr; 16(2):169-73. PMID: 17188907
7. Garcia GM, McCord GC, Kumar R. Hydroxyapatite crystal deposition disease. *Seminars In Musculoskeletal Radiology*. 2003 Sep; 7(3):187–193. PMID: 14593560
8. Resnick D, Shaul SR, Robins JM. Diffuse idiopathic skeletal hyperostosis (DISH): Forestier's disease with extraspinal manifestations. *Radiology*. 1975; 115:513–24. PMID: 1129458
9. Mavrikakis ME, Drimis S, Kontoyannis DA, Rasidakis A, Mouloupoulou ES, Kontoyannis S. Calcific shoulder periarthritis (tendinitis) in adult onset diabetes mellitus: a controlled study. *Annals of the Rheumatic Diseases*. 1989 Mar; 48(3):211–214. PMID: 2930276
10. Kobashi G, Washio M, Okamoto K, Sasaki S, Yokoyama T, Miyake Y, Sakamoto N, Ohta K, Inaba Y, Tanaka H. High body mass index after age 20 and diabetes mellitus are

independent risk factors for ossification of the posterior longitudinal ligament of the spine in Japanese subjects: a case-control study in multiple hospitals. *Spine*. 2004 Apr; 29(9):1006–1010. PMID: 15105673

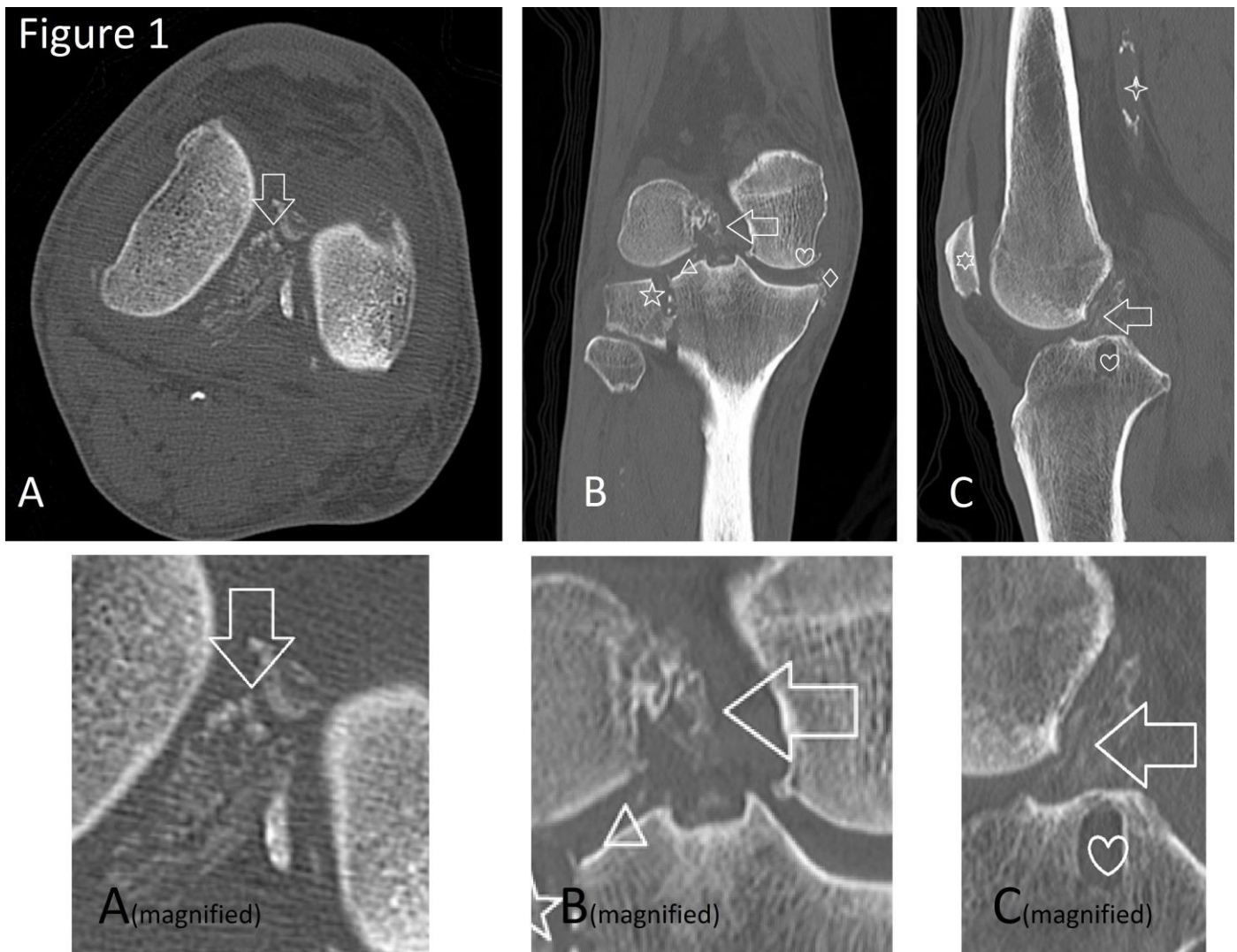
11. Ea HK, Lioté F. Diagnosis and Clinical Manifestations of Calcium Pyrophosphate and Basic Calcium Phosphate Crystal Deposition Diseases. *Rheum Disease Clinic North America*. 2014 May; 40(2):207-229. PMID: 24703344

12. Banks KP, Bui-Mansfield LT, Chew FS. A compartmental approach to the radiographic evaluation of soft-tissue calcifications. *Seminars in Roentgenology*. 2005; 40 (4): 391-407. PMID: 16218555

13. Oliva F, Via A, Maffulli N. Calcific Tendinopathy of the Rotator Cuff Tendons. *Sports Medicine & Arthroscopy Review*. 2011 Sept; 19(3): 237–243. PMID: 21822107

14. Tsujii A, Tanaka Y, Yonetani Y, Iuchi R, Shiozaki Y, Horibe S. Symptomatic calcification of the anterior cruciate ligament: A case report. *Knee*. 2012; 19(3): 223–225. PMID: 21821419

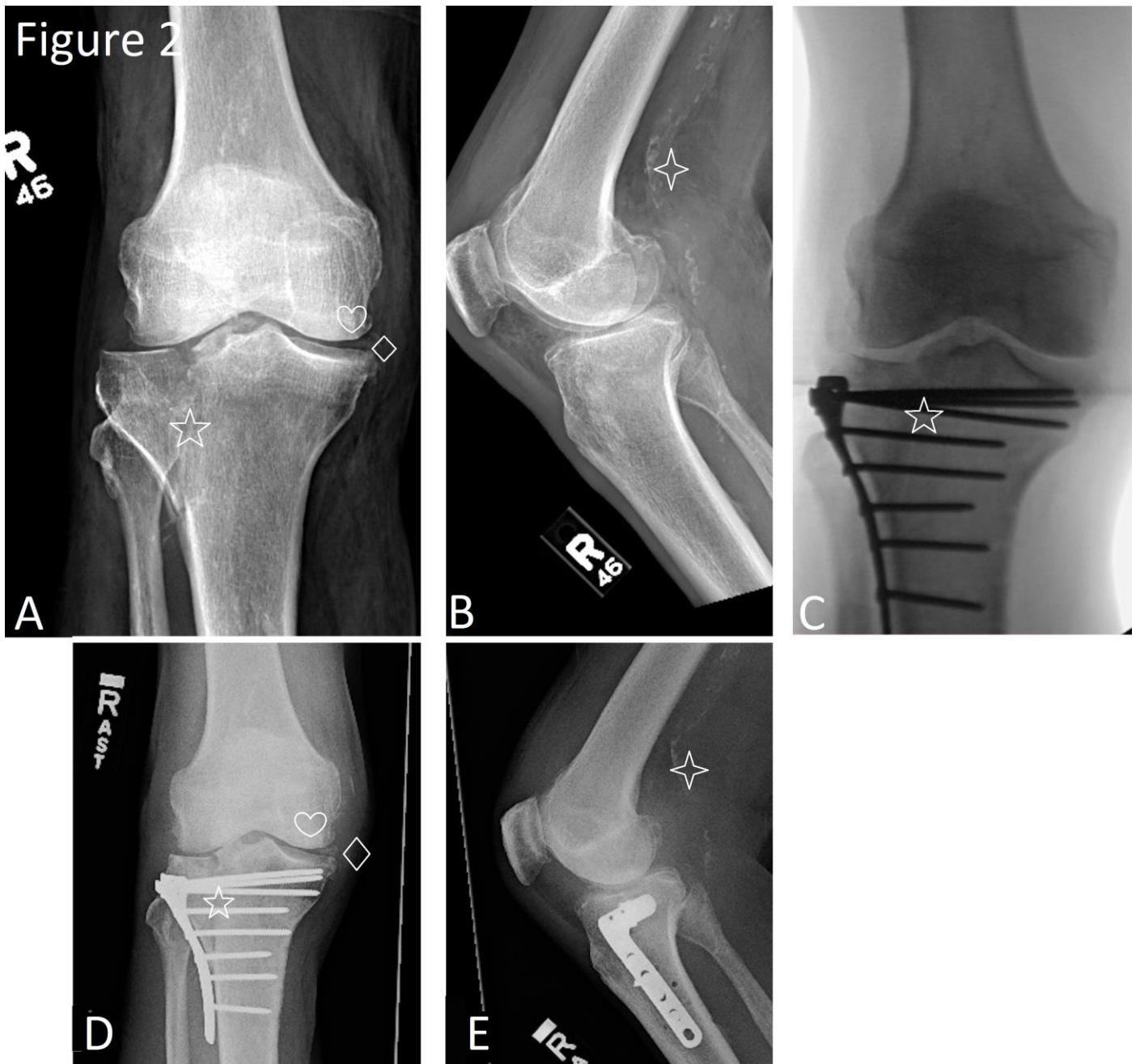FIGURES



**Figure 1:** 82-year-old male restrained driver in a motor vehicle accident with incidentally discovered calcification of the anterior cruciate ligament.

Findings: CT of the right lower extremity without contrast. A.) Axial view of the knee reveals calcification of the anterior cruciate ligament at the arrow. B.) Coronal view demonstrates a comminuted fracture of the lateral tibial plateau with depression and lateral deviation of fracture fragments as denoted by the star symbol. Fracture fragments within the joint space and about the intercondylar eminence (triangle symbol). Severe joint disease with subchondral cyst and osteophyte development (heart symbol) and chondrocalcinosis of the medial meniscus as denoted by the diamond symbol. An arrow points to the calcification of the anterior cruciate ligament. C.) Sagittal view reveals a patella alta at the six pointed star symbol, atherosclerosis (four pointed star symbol), subchondral cyst (heart symbol) and confirms again calcification of the anterior cruciate ligament further delineated by an arrow. Magnified views of the calcification are provided beneath each corresponding figure.

Technique: Axial CT on a Toshiba Aquilion Prime CT scanner with coronal and sagittal reformats without contrast. 200 mAs, 120 kV, 3 mm slice thickness, dose: CTDIvol 15 mGy, DLP 447.9 mGy x cm



**Figure 2:** 82-year-old male with a comminuted Schatzker II fracture of the lateral right tibial plateau with depression and incidentally discovered calcification of the anterior cruciate ligament.

**Findings:** Antero-posterior and lateral radiographs of the right knee. A.) Preoperative antero-posterior radiograph demonstrating the tibial plateau fracture (star symbol), degenerative changes of the medial compartment (heart symbol) and chondrocalcinosis of the medial meniscus (diamond symbol). Of note, calcification of the anterior cruciate ligament is not visualized. B.) Preoperative lateral radiograph demonstrating atherosclerosis (four pointed star symbol). Again, calcification of the anterior cruciate ligament is not visualized. C.) Intraoperative antero-posterior radiograph demonstrating tibial plateau fracture (star symbol) adjacent origin of anterior cruciate ligament with poorly visualized ligament and calcification. D.) Antero-posterior and E.) lateral radiographs of the right knee following the fixation of the fracture with plate and screws demonstrate the tibial plateau fracture in near anatomic alignment with hardware in place as denoted by the star symbol. Degenerative changes of the medial compartment (heart symbol), chondrocalcinosis of the medial meniscus (diamond symbol) and atherosclerosis (four pointed star symbol) remain unchanged. Of note, in this view, the anterior cruciate ligament is still poorly visualized and calcification within the region cannot be confirmed.

	<b>Anterior cruciate ligament calcification, ligament calcification</b>	<b>Ossicle within the ligament, loose body and osteochondritis dissecans</b>	<b>Chondrocalcinosis, renal osteodystrophy</b>	<b>Soft tissue lesion/mass with calcification</b>
<b>X-Ray</b>	<ul style="list-style-type: none"> <li>Poorly visualized</li> </ul>	<ul style="list-style-type: none"> <li>May appear as a radiopaque loose body within the ligament of interest.</li> </ul>	<ul style="list-style-type: none"> <li>Radiopacity of the ligamentum flavum, joint capsule, menisci/hyaline cartilage, ligaments and soft tissues.</li> </ul>	<ul style="list-style-type: none"> <li>Varied appearance depending on degree of calcification.</li> </ul>
<b>US</b>	<ul style="list-style-type: none"> <li>Calcified densities on ultrasound are seen as echogenic foci with variable acoustic shadow.</li> <li>Calcium will be seen within the ligament in a diffuse or speckled pattern.</li> </ul>	<ul style="list-style-type: none"> <li>Echogenic focus within versus adjacent the ligament of interest.</li> </ul>	<ul style="list-style-type: none"> <li>Echogenic foci with variable acoustic shadowing within the hyaline cartilage.</li> </ul>	<ul style="list-style-type: none"> <li>Echogenic foci will be seen in relation to soft tissue density</li> </ul>
<b>CT</b>	<ul style="list-style-type: none"> <li>Calcium on CT is bright with Hounsfield units typically in excess of 200.</li> <li>Calcium will be seen within the ligament in a diffuse or speckled pattern.</li> </ul>	<ul style="list-style-type: none"> <li>Hyperattenuating focus within versus adjacent the ligament of interest.</li> </ul>	<ul style="list-style-type: none"> <li>Hyperattenuation within hyaline cartilage</li> </ul>	<ul style="list-style-type: none"> <li>Hyperattenuation may be seen secondary to calcium and blood flow.</li> </ul>
<b>MRI</b>	<ul style="list-style-type: none"> <li>Calcium appears dark on T1, T2, PD imaging.</li> <li>Calcium will be seen within the ligament in a diffuse or speckled pattern.</li> </ul>	<ul style="list-style-type: none"> <li>Focus of dark signal within versus adjacent the ligament of interest.</li> <li>Possible isointensity to the normal bone marrow with a hypointense rim.</li> </ul>	<ul style="list-style-type: none"> <li>Abnormally dark signal may be appreciated within hyaline cartilage.</li> </ul>	<ul style="list-style-type: none"> <li>Soft tissue component associated with dark/calcified structure of interest.</li> </ul>
<b>Pattern of contrast enhancement</b>	<ul style="list-style-type: none"> <li>None</li> </ul>	<ul style="list-style-type: none"> <li>None</li> </ul>	<ul style="list-style-type: none"> <li>Enhancement may be associated with erosive and or inflammatory changes.</li> <li>Contrast uptake may be avid, homogenous or heterogeneous.</li> </ul>	<ul style="list-style-type: none"> <li>Enhancement is variable depending on aggressiveness of the lesion and blood supply.</li> <li>Contrast uptake may be avid, homogenous or heterogeneous.</li> </ul>
<b>Scintigraphy and PET</b>	<ul style="list-style-type: none"> <li>Radiopharmaceutical and FDG uptake should not be abnormal with exception of varied uptake secondary to trauma or arthritis.</li> </ul>	<ul style="list-style-type: none"> <li>Radiopharmaceutical and FDG uptake should not be abnormal with exception of varied uptake secondary to trauma or arthritis.</li> </ul>	<ul style="list-style-type: none"> <li>Radiopharmaceutical and FDG uptake will be appreciated in association with erosive and/or inflammatory changes.</li> <li>Superscan, pseudofractures and soft tissue components may be appreciated on bone scan.</li> </ul>	<ul style="list-style-type: none"> <li>Radiopharmaceutical and FDG uptake is variable depending on aggressiveness of the lesion and blood supply.</li> </ul>

**Table 1:** Differential diagnosis table for anterior cruciate ligament (ACL) calcification

<b>Etiology</b>	<ul style="list-style-type: none"> <li>• Trauma (with possible hemorrhagic component).</li> <li>• Possible etiologies discussed in the literature include various endocrine disorders (including thyroid disorders, diabetes, hypoparathyroidism), medication induced hypercalcemia, vitamin D resistance, hypervitaminosis A, hypomagnesemia and hormone supplementation</li> </ul>
<b>Incidence</b>	<ul style="list-style-type: none"> <li>• Unknown, as this finding is noted only in a handful of case reports</li> </ul>
<b>Gender ratio</b>	<ul style="list-style-type: none"> <li>• Unknown</li> </ul>
<b>Age predilection</b>	<ul style="list-style-type: none"> <li>• Unknown</li> </ul>
<b>Risk factors</b>	<ul style="list-style-type: none"> <li>• Repetitive trauma and various medical comorbidities as discussed above including but not limited to diabetes, renal disease and hormone supplementation.</li> </ul>
<b>Treatment</b>	<ul style="list-style-type: none"> <li>• No treatment is recommended for asymptomatic patients.</li> <li>• For symptomatic patients, arthroscopic treatment and debridement of calcium deposits may be performed.</li> <li>• It is supposed that debridement may also allow calcium remnants to diffuse into the joint and thereby aide in absorption.</li> </ul>
<b>Prognosis</b>	<ul style="list-style-type: none"> <li>• Good</li> </ul>
<b>Findings on imaging</b>	<ul style="list-style-type: none"> <li>• Anterior cruciate ligament calcifications may appear diffuse or speckled on plain radiograph.</li> <li>• Ultrasound demonstrates echogenic foci within the area of interest with variable acoustic shadow.</li> <li>• Computed tomography demonstrates calcium within the ligament; Hounsfield units are typically in excess of 200.</li> <li>• Magnetic resonance imaging will show calcium within the ligament in a diffuse or speckled pattern; calcium appears dark on T1, T2 and PD imaging.</li> </ul>

**Table 2:** Summary table for anterior cruciate ligament (ACL) calcification

**ABBREVIATIONS**

CT = Computer tomography  
 MRI = Magnetic resonance imaging  
 XR = X-Ray  
 US = Ultrasound  
 PET = Positron emission tomography  
 FDG = Fludeoxyglucose  
 L2/3 = Lumbar spine 2/3  
 mg = milligram  
 gm = gram  
 dL = deciliter  
 mRNA = messenger ribonucleic acid

**KEYWORDS**

Anterior cruciate ligament; posterior cruciate ligament; knee; calcification; deposition; trauma; computed tomography

**Online access**

This publication is online available at:  
[www.radiologycases.com/index.php/radiologycases/article/view/2319](http://www.radiologycases.com/index.php/radiologycases/article/view/2319)

**Peer discussion**

Discuss this manuscript in our protected discussion forum at:  
[www.radiolopolis.com/forums/JRCR](http://www.radiolopolis.com/forums/JRCR)

**Interactivity**

This publication is available as an interactive article with scroll, window/level, magnify and more features.  
 Available online at [www.RadiologyCases.com](http://www.RadiologyCases.com)

Published by EduRad



[www.EduRad.org](http://www.EduRad.org)