


# Sialadenitis following low dose I-131 diagnostic thyroid scan with Thyrogen® (recombinant human thyroid stimulating hormone - thyrotropin alfa)

Marta E Gonzalez<sup>1\*</sup>, Thomas Jose Eluvathingal Muttikkal<sup>1</sup>, Patrice K Rehm<sup>1</sup>

*1. Department of Radiology and Medical Imaging University of Virginia, USA*

\* **Correspondence:** Marta E. Gonzalez MD, Department of Radiology and Medical Imaging University of Virginia, 1215 Lee Street  
Charlottesville, VA 22903, USA  
 [mgonzalezrcr@yahoo.com](mailto:mgonzalezrcr@yahoo.com)

Radiology Case. 2015 Jun; 9(6):44-49 :: DOI: 10.3941/jrcr.v9i6.2220

## ABSTRACT

Salivary dysfunction and sialadenitis are well known complications of radioiodine treatment for thyroid cancer. The parotid gland is more frequently affected and the salivary gland injury is dose related. The symptoms may develop shortly after therapeutic Iodine 131(I-131) administration or months later and progress with time. The development of unilateral parotiditis following a low dose, diagnostic I-131 scan performed following Thyrogen stimulation in a patient without prior history of sialadenitis is rare in our experience, and has not been reported in the medical literature.

## CASE REPORT

### CASE REPORT

A 75-year-old female patient presented for follow up diagnostic I-131 scan a year after radio-iodine treatment for papillary carcinoma of thyroid gland. Her past medical history included right hemithyroidectomy, which was done 50 years ago for benign nodule. She was diagnosed with papillary carcinoma and had completion thyroidectomy in November 2010, the pathology of which revealed two foci of follicular variant of papillary carcinoma. She had radioiodine therapy with 104.4 millicurie (mCi) of I-131 sodium iodine in February 2011. She had tolerated the radio-iodine ablation well, without any clinically overt complications.

The diagnostic I-131 scan was done with Thyrogen® (recombinant human thyroid stimulating hormone- thyrotropin alfa) stimulation as per package insert; intramuscular administration of 0.9 mg Thyrogen® on day 1 and day 2, followed by administration of 4.16 mCi of I-131 on day 3 and whole body I-131 scan and assay of thyroglobulin level on day 5. Preceding unstimulated thyroglobulin level was <0.1 ng/ml (normal reference value for athyrotic patients, <2 ng/ml). The

patient had normal renal function, blood urea nitrogen was 11 mg/dl and creatinine was 0.6 mg/dl. At the time of the scan, she reported pain, swelling and tenderness of the left parotid gland which had started on second day following the I-131 administration. There was no pain or swelling in the right parotid and bilateral submandibular glands. The whole body I131 scan showed intense uptake of radioiodine in the left parotid gland, due to retention of radioactive iodine in the salivary gland (Figures 1a, 1b). The study was negative for residual or recurrent thyroid cancer; scan results correlated with the Thyrogen-stimulated thyroglobulin level of <0.1 ng/ml (normal reference value for athyrotic patients, <2 ng/ml). The post- therapy 131 I scan which was done 7 days after her radio-iodine treatment one year prior was reviewed. It demonstrated uptake in the thyroid bed consistent with residual thyroid tissue (Figures 2a, 2b). To further characterize the process in the left salivary gland, SPECT/CT was done which demonstrated increased radiotracer uptake compared to the right (Figure 3a). The CT portion of the study showed enlarged left parotid gland without any evidence of calculus or other pathology (Figure 3b).

Patient was advised to have sour drops/chew gum after she complained about pain and parotid swelling at the time of whole body scan done 48 hours after I-11 administration, in addition to Ibuprofen (400 mg three times a day,) parotid massage, and alternate hot and cold compresses. There was improvement of pain and swelling, however she had worsening of her symptoms after a week. The patient was started on oral prednisolone (initially 20 mg /day tapered over 7 days), with decrease in pain, swelling and tenderness. Her symptoms recurred within a few days of stopping the steroids. Patient also developed slight altered taste sensation, especially for coffee. She was assessed by an ENT (Ear Nose and Throat) doctor and a dentist; no additional diagnosis was made. Patient consequently had two more courses of steroids with improvement of pain and swelling. She had mild residual taste disturbance and dryness of mouth especially in the morning.

## DISCUSSION

### Etiology and demographics

Radioactive iodine was first suggested for the treatment of differentiated thyroid cancer (papillary and follicular) after thyroidectomy in the 1940s and has an established role in the management of differentiated thyroid cancer which accounts for about 90 % of thyroid cancers [1]. The most common complication of I-131 therapy is sialadenitis, with an incidence of 11.5% according to Allweiss et al [2]. It is estimated that the radiation dose delivered to the salivary glands of an athyrotic patient to be 700 rads during the first 12 hours after administration of a 100- to 200-mCi dose of radioactive iodine [3]. Other investigators have estimated that in patients with intact thyroid glands, a 5-mCi oral dose of I-131 could deliver a radiation dose of 250 rads to the salivary glands causing functional and histological damage [4, 5].

The capacity of the salivary glands to concentrate iodine selectively is unknown [6]. This can be due to functional expression of NIS (sodium iodine symporter) and metabolism related to or the retention of excreted iodine. Expression of NIS in salivary glands has been demonstrated (7). The epithelial lining of the intralobular ducts of the salivary glands extracts the iodine from the periductal capillaries and secretes it into the duct lumen [6]. The iodine is secreted in the saliva in inorganic form; concentration varies from 18 to 100 times compared to serum levels [1]. Approximately 24% of the administered I-131 dose for thyroid cancer therapy is lost in the saliva [6]. Generally, the sialadenitis due to radioactive iodine begins within 24 hours of treatment. It is usually transient, lasting for a week [4]. In some patients these effects can appear months or years after treatment and can persist leading to chronic glandular changes [6]. Elevated concentrations of sodium and chloride levels in the saliva are seen because of loss of normal ability of ducts to resorb these electrolytes in addition to plasma proteins due to loss of normal filtration. Salivary phosphate levels are decreased when the damaged epithelium of the intralobular duct wall fails in its normal function to transport phosphate into the saliva. Simultaneously, a decrease in salivary amylase activity

occurs after damage to the amylase-synthesizing acinar cells. These changes are dose dependent [1, 4, 6].

Salivary gland dysfunction worsens with cumulative dose [8]. Mandel et al suggests that the longer elapsed time between iodine administration and intervention for sialadenitis allowed for continued progression of gland degeneration [6].

The parotid gland is more predisposed to injury than other salivary glands, with involvement of the parotid gland in 81% cases and the submandibular gland in 13% [9]. The parotid gland has predominantly serous cells, in contrast to the submandibular and the sublingual glands which consist of a mixture of serous and mucinous cells. The mucinous-secreting glands increase their secretion rate after irradiation. Also the submandibular glands have a higher continuous unstimulated secretion than the parotid gland [1, 8]. The serous cells have greater ability to concentrate iodine than mucous cells [1]. These explain the preferential sialadenitis of parotid gland with sparing of the other salivary glands in our patient, which is supported by the literature.

Secondary complications of radiation sialadenitis include xerostomia, taste alterations, increase in incidence of dental caries, facial nerve involvement, stomatitis, candidiasis, and neoplasia [6].

### Clinical and Imaging findings

The clinical presentation of sialadenitis is nonspecific. Patients present with pain and tenderness of the affected salivary gland with no cervical adenopathy. Such was the case of our patient. In our patient, the therapeutic dose I-131 administered one year earlier likely caused subclinical injury to the parotid gland, just short of clinical expression. The small diagnostic dose of 4.16 mCi given for the follow up scan resulted in progression of the changes leading to clinically overt sialadenitis. The patient had only one diagnostic I131 Iodine scan after treatment, and did not have any further follow up diagnostic I-131 Iodine scan.

CT scan done as part of SPECT/CT did not reveal salivary duct calculus or salivary gland tumor in our patient. Patient was also seen by her dentist and her ENT specialist who excluded other etiologies and concurred with diagnosis of sialadenitis.

Imaging findings of sialadenitis are non-specific. Nuclear medicine studies demonstrate enlargement of the salivary glands with increased FDG uptake on PET CT and avid on radioiodine thyroid scans in the acute and sub-acute phases. SPECT-CT is used for accurate localization and better characterization of the lesions [10]. The degree of FDG uptake and avidity in the thyroid scans depends of the degree of inflammation.

Sialography is contraindicated in acute sialadenitis because it can worsen the inflammation. In acute sialadenitis the affected gland appears enlarged, hypoechoic and hyperemic on ultrasound. Per CT the salivary glands appear enlarged with low attenuation, indistinct margin and vivid contrast enhancement with associated adjacent fat stranding

and/or thickening of deep cervical fascia that is typically unilateral. MRI is not routinely used in sialadenitis. During the acute phase, the salivary glands appear enlarged with low signal on T1 weighted images and high signal on T2 but signal characteristics in majority of cases tend to be heterogeneous.

#### Treatment and prognosis

Preventive methods include drinking lots of fluid, sucking candy, chewing gum for at least 7 days which follow the Society of Nuclear Medicine and Medical Imaging (SNMMI) Guidelines [11]. Traditional treatment modalities involve conservative methods such as aggressive external massage, nonsteroidal anti-inflammatory medications, and cholinergic medication. Steroid medications are added, if the pain and the swelling of the involved gland do not subside within 48 hours after treatment with Ibuprofen. Sour drops and other methods (sucking candy/chewing gums) to stimulate salivary secretion prevents the stasis of radioactive iodine in the salivary glands, thus decreasing the chance of radiation induced inflammation. Stasis of radioactive iodine in salivary glands can lead to inflammation of the salivary gland duct, which in turn lead to further retention of radioactive iodine within the salivary gland which worsens the inflammation. By stimulating salivary secretion and drainage, using sour drops/candies, this vicious cycle is interrupted, resulting in improvement of the sialadenitis which results in reduced inflammation of salivary gland duct, which further reduces the retention and sialadenitis. Amifostine as a free radical scavenger has been shown to prevent salivary gland damage after the administration of high doses of radioiodine treatment [6, 12]. Regardless of the safety record, there is some hesitancy to prescribe amifostine because many practitioners are not convinced that it does not inhibit the radioiodine's therapeutic efficacy [6]. It has its own side effects, and has not been widely adopted. Another treatment option available for chronic sialadenitis is sialoendoscopic intervention, using ballooning methods, to open up salivary duct. The success rates vary from 50 to 87% [13, 14, 16]. Kim et al concluded that interventional sialoendoscopy is a suitable choice of treatment in selected cases of sialadenitis such as partial ductal stenosis but is ineffective in total obstructive cases [13]. Surgical resection may be considered in patients with severe symptoms that are not controlled by conservative methods including sialoendoscopy.

#### Differential diagnosis

Post-radiation sialadenitis secondary to I-131 is generally bilateral [2, 6, 17, 18]. Unilateral parotid uptake of radiotracer following diagnostic I-131 scan has been mentioned in two cases in literature, one of which was due to parotid neoplasm [19]. The other patient already had chronic sialadenitis following prior I-131 treatment [18]. The differential diagnosis of unilateral asymmetric radiotracer uptake includes a blocked parotid duct secondary to a stone (sialolithiasis), stricture or tumor and metastases [19, Table 2]. Salivary gland stones most commonly affect the submandibular salivary duct in 80-90% with almost all the remaining cases located in the parotid gland. The stones can be visualized by using plain film, sialography (as filling defects), ultrasound, CT and MRI. The clinical presentation of sialadenitis is typically with pain, tenderness and no cervical adenopathy. Neoplasms tend to be

painless [19]. Obtaining a thorough clinical history, imaging studies and the histopathological results will definitely differentiate neoplasm, unilateral metastases and unilateral post-radiation sialadenitis. In a patient with recent history of radioiodine ingestion, with pain and parotid swelling, without demonstrable obstructive calculus in the salivary duct, the cause for unilateral increased radioiodine uptake in parotid gland is radiation induced sialadenitis, which also results in salivary duct obstruction leading to retention of radioactive iodine in the salivary gland.

Radioiodine therapy can result in subclinical sialadenitis, which may become manifest as clinically overt sialadenitis at a later time. In this case, our patient who had no salivary gland complaints prior to or following her I-131 therapy with 100 mCi one year prior, unexpectedly developed overt unilateral sialadenitis following low dose of I-131 diagnostic scan. Our case illustrates that clinicians should be aware of the possibility that sialadenitis can occur following a low dose of I-131 for scintigraphy in a patient who tolerated I-131 therapy without symptoms, specifically 4 mCi in conjunction with Thyrogen® stimulation. Recognition of sialadenitis is important, in order to institute appropriate anti-inflammatory and supportive measures to minimize morbidity and long term sequelae.

#### TEACHING POINT

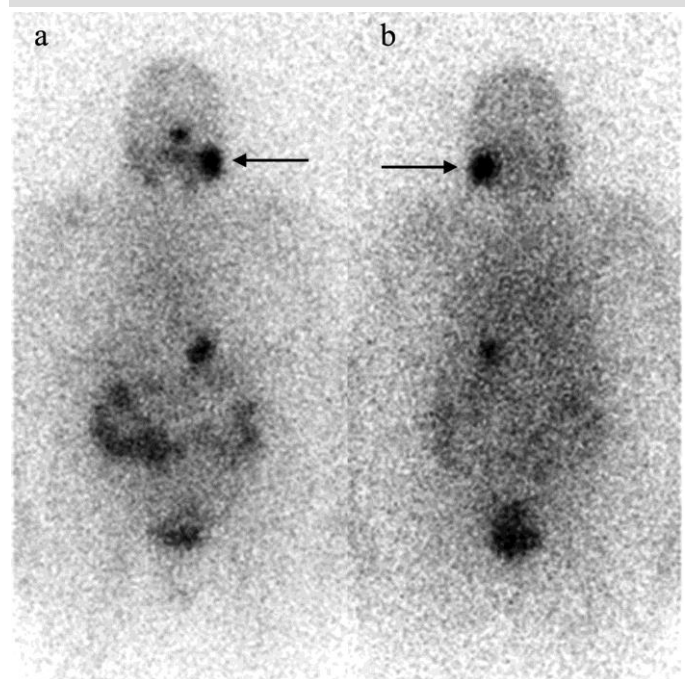
Radiation induced sialadenitis can occur following low dose I-131 administration for diagnostic purposes. It is important to recognize that subclinical sialadenitis may occur as a consequence of radioiodine therapy and it may be triggered as clinically overt sialadenitis by follow up diagnostic I-131 radioiodine scan. This should be identified as soon as possible and treated to prevent long term morbidity.

#### REFERENCES

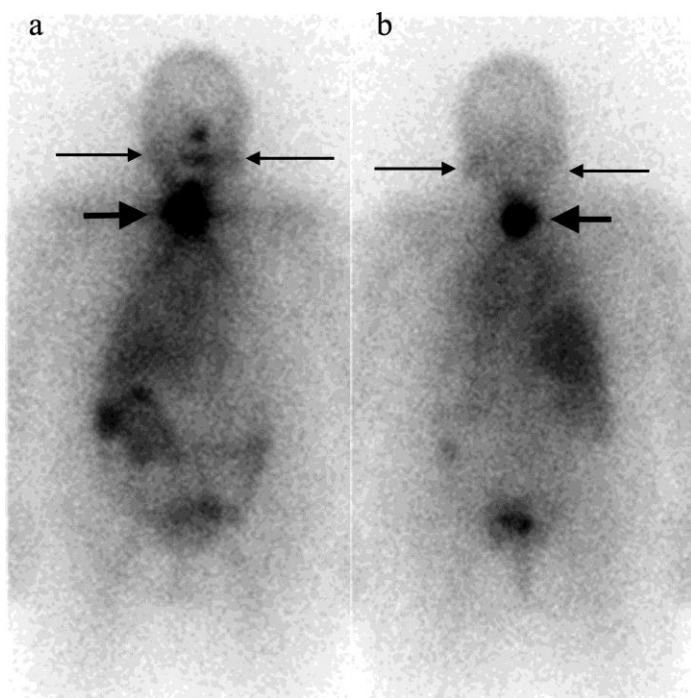
1. Mandel S, Mandel L. Persistent sialadenitis after radioactive iodine therapy: Report of two cases. *J Oral Maxillofac Surg.* 1999; 57:738-42. PMID: 10368102.
2. Allweiss P, Braunstein G, Katz A, Waxman A. Sialadenitis following I-131 therapy for thyroid carcinoma: Concise communication. *J Nucl Med.* 1984; 25:755-8. PMID: 6737074.
3. Golden A. The use of radioactive iodine in thyroid carcinoma. *Eur J Cancer Clin Oncol.* 1988; 24(2):339-43. PMID: 3281849.
4. Carlisle MR, McDougall IR. Dramatic parotid uptake of I-131 on a diagnostic whole-body scan. *Clin Nucl Med.* 2000 Nov; 25(11):895-7. PMID: 11079586.

5. Doniach I. Biologic effects of radiation on the thyroid. In: Werner SC, Ingbar SH, eds. *The Thyroid*. New York: Harper & Row. 1978:274-83. PMID: not available.
6. Mandel S, Mandel L. Radioactive iodine and the salivary glands. *Thyroid*. 2003; 13:265-71. PMID: 12729475.
7. Oh JR, Ahn BC. False-positive uptake on radioiodine whole-body scintigraphy: physiologic and pathologic variants unrelated to thyroid cancer. *Am J Nucl Med Mol Imaging* 2012; 2(3):362-385. PMID: 23133823.
8. Jentzen W, Schneider E, Freudenberg L, Eising E, Görges R, Müller S, et al. Relationship between cumulative radiation dose and salivary gland uptake associated with radioiodine therapy of thyroid. *Nuclear Medicine Communications*. 2006; 27:669-76. PMID: 16829767.
9. Caglar M, Tuncel M, Alpar R. Scintigraphic evaluation of salivary gland dysfunction in patients with thyroid cancer after radioiodine treatment. *Clin. Nucl. Med.* 2002; 27(767):771. PMID: 12394122.
10. Glazer DI, Brown RK, Wong KK, Savas H, Gross MD, Avram AM. SPECT/CT evaluation of unusual physiologic radioiodine biodistributions: pearls and pitfalls in image interpretation. *Radiographics*. 2013; 33(2):397-18. PMID: 2347970.
11. Silberstein EB, Alavi A, Balon HR, et al. The SNMMI practice guideline for therapy of thyroid disease with I-131 3.0. *J Nucl Med*. 2012; 53 (10): 1633-51. PMID: 22787108.
12. Bohuslavizki K, Klutmann S, Bleckmann C, Brenner W, Cassmann S, Mester J, et al. Salivary gland protection by amifostine in high-dose radiotherapy of differentiated thyroid cancer. *Strahlenther Onkol* 1999; 175(2):57-61. PMID: 10065139.
13. Kim J, Han G, Lee S, Lee D, Kim Y, Sialoendoscopic treatment for radioiodine Induced sialadenitis. *The Laryngoscope*. 2007; 117:133-6. PMID: 17202942.
14. Kim JW, Kim DH, Kim KT, Kim TY, Ko KJ, Choi JS, Kim YM. Sialoendoscopy: Endoscopic diagnosis and treatment of the salivary gland disease. *Korean J Otolaryngol-Head Neck Surg*. 2005; 48(3):373-9. PMID: not available.
15. Nahlieli O, Baruchin A. Sialendoscopy: Three years' experience as a diagnostic and treatment modality. *J oral Maxillofac Surg*. 1997; 55(9):912-18. PMID: 9294498
16. Nahlieli O, Baruchin A. Long-term experience with endoscopic diagnosis and treatment of salivary gland inflammatory diseases. *Laryngoscope*. 2010; 110 (6):988-93 PMID: 10852519.
17. Alexander C, Bader J, Schaefer A, Finke C, Kirsh C. Intermediate and long-term side effects of high-dose radioiodine therapy for thyroid carcinoma. *J Nucl Med*. 1998; 39:1551-4. PMID: 9744341.
18. Kolla IS, Alazraki NP, Watts NB. Sialadenitis mimicking metastatic thyroid carcinoma. *Clin Nucl Med*. 1989 Aug; 14(8):564-6. PMID: 2805535.
19. Frew j, Mallick U, Perros P. Patient with asymmetric parotid uptake on a diagnostic iodine-131 scan during thyroid cancer follow-up. *Thyroid*. 2007; 17(8):801-2. PMID: 17725441.

FIGURES



**Figure 1:** Whole body diagnostic thyroid scan of the follow up with Thyrogen, done 48 hours after administration of 4 mci of I-131 in a 75 year old female with unilateral sialadenitis. **TECHNIQUE:** Anterior and posterior planar projections of the whole body, neck and chest were performed on a Siemens dual head gamma camera. **FINDINGS:** a) Anterior view shows abnormal increased uptake in the left parotid gland (arrow). b) Posterior view shows abnormal increased uptake in the left parotid gland (arrow).

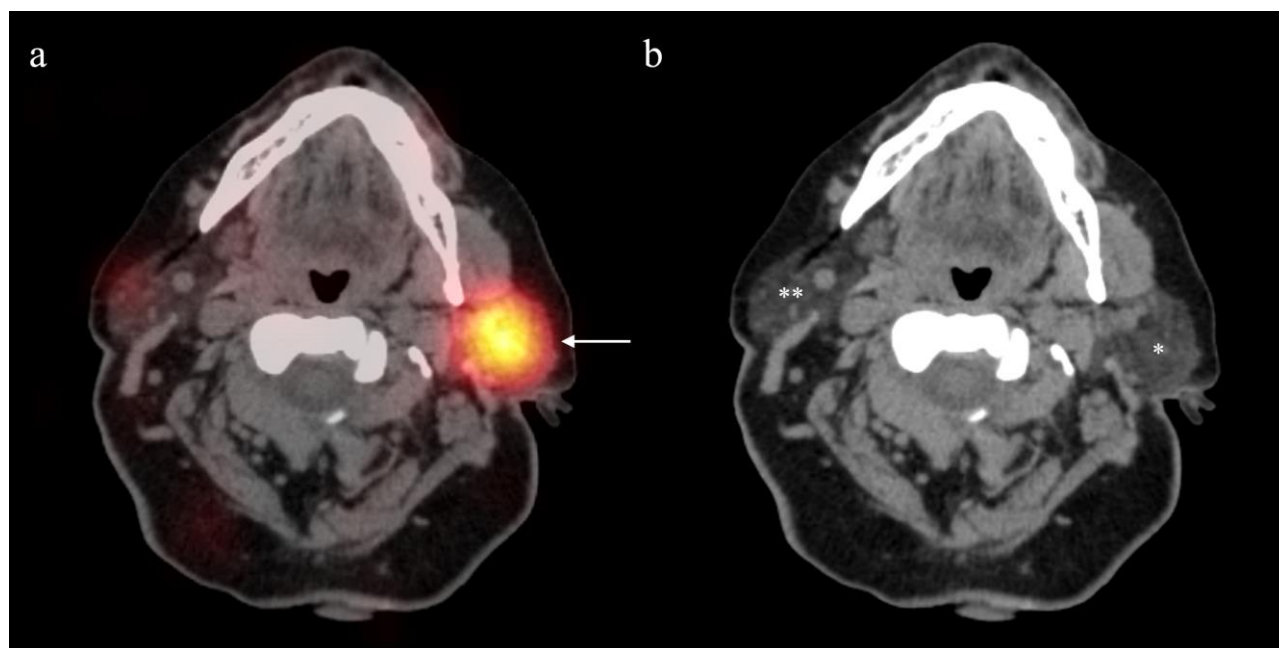


**Figure 2 (left):** Whole Body Thyroid Scan, done 7 days after administration of therapeutic dose of 100 mCi I131 in a 75 year old female with unilateral sialadenitis. **TECHNIQUE:** Anterior and posterior planar projections of the whole body, neck and chest were performed on a Siemens dual head gamma camera.

**FINDINGS:** a) Anterior view shows normal uptake in the salivary glands (long thin arrows) and uptake in the residual thyroid tissue in the thyroid bed (short thick arrow).

Fig b) Posterior view shows normal uptake in the salivary glands (long thin arrows) and uptake in the residual thyroid tissue in the thyroid bed (short thick arrow).

**Figure 3 (bottom):** SPECT-CT done 48 hours after administration of 4 mci of I131 in a 75 year old female with unilateral sialadenitis. **TECHNIQUE:** Siemens Symbia-High Definition SPECT-CT T6 Scanner, 1.25 mm slice thickness, 130 KVP. 71 mAs, without intravenous contrast. **FINDINGS:** a) Axial view of the fused SPECT-CT shows increased I131 uptake in the left parotid gland (arrow). b) Axial CT portion of SPECT-CT showing relative increased size of left parotid gland (single asterisk) compared to the right (double asterisks).



<b>Incidence</b>	11.5%
<b>Gender ratio</b>	No gender ratio
<b>Age Predilection</b>	No age predilection
<b>Risk factors</b>	Prior treatment with RAI and sialadenitis
<b>Treatment</b>	Preventive methods and traditional conservative methods: external massage, NSAIDs, steroid and cholinergic medication. Other including: Amifostine, sialoendoscopic intervention and surgical resection.
<b>Prognosis</b>	Variable. Sialendoscopy has a success rate from 50 to 87%
<b>Findings of Imaging</b>	Imaging findings: non-specific with enlarged salivary glands. <b>PET-CT:</b> Enlarged salivary glands with increased metabolism by using PET CT. <b>Thyroid scan:</b> Enlarged glands with avid uptake scans during the acute and sub-acute phases. <b>US:</b> Enlarged glands, hypoechoic and hyperemic on ultrasound. <b>CT:</b> Enlarged salivary glands with abnormal attenuation, indistinct margin and vivid contrast enhancement with associated adjacent fat stranding and/or thickening of deep cervical fascia that is typically unilateral. <b>MRI:</b> Enlarged glands with low signal on T1 weighted images and high signal on T2 but signal characteristics in majority of cases tend to be heterogeneous.

**Table 1:** Summary table of post radiation Sialadenitis (post Iodine-131 therapy).

Entity	PET-CT	Iodine Thyroid Scan	Ultrasound	CT	MRI
<b>Post-radiation sialadenitis</b>	<ul style="list-style-type: none"> <li>Typically enlarged</li> <li>Avid to FDG during the acute and sub-acute phases</li> </ul>	<ul style="list-style-type: none"> <li>Enlarged glands</li> <li>Increased uptake of the radiotracer during the acute and sub-acute phase</li> </ul>	<ul style="list-style-type: none"> <li>Enlarged glands</li> <li>Hypochoic</li> <li>Increased blood flow during the acute phase</li> </ul>	<ul style="list-style-type: none"> <li>Enlarged glands</li> <li>Abnormal attenuation</li> <li>Indistinct margins</li> <li>Peri-glandular stranding</li> <li>Contrast enhancement</li> </ul>	<ul style="list-style-type: none"> <li>Enlarged glands</li> <li>Signal heterogeneity in majority of cases)</li> <li>Low T1 WI and high T2WI</li> </ul>
<b>Sialolithiasis</b>	<ul style="list-style-type: none"> <li>Not used</li> <li>If inflammation is present: positive FDG uptake</li> </ul>	<ul style="list-style-type: none"> <li>Not used</li> </ul>	<ul style="list-style-type: none"> <li>Typically the stones appear as strongly hyperechoic lines or points with distal acoustic shadowing.</li> <li>Enlarged gland in acute obstructive cases.</li> </ul>	<ul style="list-style-type: none"> <li>Typically the stones are seen obstructing the ducts</li> <li>Salivary glands are enlarged, hyperdense and associated with stranding and enhancing following contrast administration</li> </ul>	<ul style="list-style-type: none"> <li>Large stones are visualized</li> <li>Map the ductal anatomy and asses the gland.</li> <li>Can distinguish acute from chronic obstruction</li> <li>Acute settings: Enlarged gland with reduced T1 weighted images compared to the contralateral side. T2 –increased (best seen on fat suppressed sequences.</li> </ul>
<b>Salivary glands neoplasm</b>	<ul style="list-style-type: none"> <li>Typically malignant tumors demonstrate increased FDG uptake.</li> </ul>	<ul style="list-style-type: none"> <li>Not used</li> </ul>	<ul style="list-style-type: none"> <li>Typically enlarged gland</li> <li>Distinguishes cystic from solid and focal from diffuse disease neoplasms.</li> <li>Assess vascularity</li> <li>Typically sonographic characteristics depend of whether the tumor is benign or malignant.</li> <li>As a guide for fine-needle aspiration biopsy</li> </ul>	<ul style="list-style-type: none"> <li>If suspicious for inflammatory disease or in patients with contraindications for MRI.</li> <li>Usually enlarged gland with a focal lesion</li> <li>Assess extend of the disease</li> <li>Pre- and post-contrast studies must be performed in order to detect calcifications.</li> <li>Typically enhancement in malignant neoplasm.</li> </ul>	<ul style="list-style-type: none"> <li>Method of choice for palpable masses</li> <li>Typically an enlarged gland with a focal lesion.</li> <li>Remaining MRI findings depend of whether the lesion is benign or malignant, focal or diffuse.</li> </ul>

**Table 2:** Differential diagnosis of Sialadenitis.

ABBREVIATIONS

CT = Computed Tomography  
 ENT = Ear Nose and Throat  
 I-131 = Iodine 131  
 mCi = millicurie  
 Mg/dl = milligrams per deciliter  
 Ng/ml = nanograms per milliliters  
 NIS = Sodium iodine symporter  
 NSAIDs = Non-steroidal anti-inflammatory drugs  
 RAI = radioactive iodine  
 SNMMI = Society of Nuclear Medicine and Medical Imaging  
 SPECT = Single Photon Emission Computed Tomography  
 Thyrogen® = Recombinant human thyroid stimulating hormone - thyrotropin alfa  
 US = Ultrasound

KEYWORDS

Iodine-131; Thyrogen; diagnostic; salivary glands; sialadenitis

ACKNOWLEDGEMENTS

To Andrey Escolar MD for his collaboration with the figures.

**Online access**

This publication is online available at:  
[www.radiologycases.com/index.php/radiologycases/article/view/2220](http://www.radiologycases.com/index.php/radiologycases/article/view/2220)

**Peer discussion**

Discuss this manuscript in our protected discussion forum at:  
[www.radiolopolis.com/forums/JRCR](http://www.radiolopolis.com/forums/JRCR)

**Interactivity**

This publication is available as an interactive article with scroll, window/level, magnify and more features.  
 Available online at [www.RadiologyCases.com](http://www.RadiologyCases.com)

Published by EduRad



[www.EduRad.org](http://www.EduRad.org)