

Goldenhar syndrome with contralateral pulmonary aplasia: a rare association

Tejeshwar Singh Jugpal¹, Jyoti Kumar^{1*}, Swati Gupta¹, Anju Garg¹

1. Department of Radiodiagnosis, Lok Nayak Hospital, New Delhi, India

* Correspondence: Jyoti Kumar, Room No 125, Department of Radiodiagnosis, Lok Nayak Hospital, New Delhi-02, India
(✉ drjyotikumar@gmail.com)

Radiology Case. 2016 Jan; 10(1):35-40 :: DOI: 10.3941/jrcr.v10i1.2113

ABSTRACT

We present a case of a 13-year-old boy with clinical features of Goldenhar syndrome (hemifacial microsomia with malformed ears) and associated contralateral pulmonary aplasia. The patient did not have any associated respiratory symptoms. Pulmonary aplasia is an uncommon association of Goldenhar Syndrome. A case of contralateral pulmonary aplasia has been rarely reported in the literature to the best of our knowledge.

CASE REPORT

CASE REPORT

A 13-year-old boy presented to the department of plastic and reconstructive surgery with complaints of asymmetric face and malformed bilateral ears. The patient was born to non-consanguineous parents at full term. There was no history of infection or drug intake by the mother during pregnancy. Two younger siblings of the patient were healthy and did not show any similar clinical features.

On examination, the patient had a thin narrow face with asymmetrical flattening of right side. The right pinna was malformed with loss of identifiable helix, antihelix and tragus with non-visualization of the right external auditory meatus (Fig.1). The left pinna had an identifiable helix, antihelix and tragus; however the external auditory meatal opening was absent and there was an associated pre-auricular skin tag.

Imaging Findings

Radiographs of face and cervical spine were obtained. The radiograph of face revealed hypoplasia of right mandibular ramus and right zygoma (Fig 2a). The cervical spine radiograph depicted C2-C3 block vertebra (Fig 2b). Computed tomography (CT) of head and neck showed hypoplasia of right zygoma and right maxilla. The right mandibular ramus and its coronoid and condylar processes were hypoplastic with shallow right glenoid fossa (Fig 2c).

Chest radiograph showed deformed left hemithorax with crowding of ribs. There was associated tracheo-mediastinal shift towards the left side (Fig 3a). The chest CT scan showed complete absence of left lung parenchyma with marked tracheo-mediastinal shift towards left side and compensatory hyperinflation of right lung with its trans-mediastinal herniation into the left thoracic cavity. The left mainstem bronchus was atretic and left pulmonary artery and vein were absent (Fig 3b, c).

On high resolution computed tomography (HRCT) of bilateral temporal bones (Fig. 4), there was non-visualization of bilateral external auditory canal with an atretic bony plate covering the middle ear cavity. The ear ossicles on the right side appeared dysplastic. The left sided ossicular chain and bilateral inner ear structures appear normal. The ultrasonography revealed normal abdominal organs.

On the basis of these findings, a diagnosis of pulmonary aplasia with Goldenhar Syndrome was made.

Management & Follow up

The patient did not have any pulmonary or hearing complaints currently therefore no active medical or surgical intervention was sought. The patient was advised for the surgical correction of the facial dysmorphic features. As the guardian refused any cosmetic reconstructive surgery, the patient was discharged and was advised follow up if any chest symptoms develop.

DISCUSSION

Etiology & Demographics:

Goldenhar syndrome, also called as Oculo-auriculo-vertebral (OAV) dysplasia was first described in 1952 by Maurice Goldenhar. It is an incompletely understood spectrum of disorders of unknown etiology. It is a complex malformation of varying severity involving the structures arising from first and second branchial arches, first pharyngeal pouch, first branchial cleft, and primordia of the temporal bone [1]. The estimated incidence of the syndrome ranges from 1 in 3500 to 5600 live births. Most cases occur sporadically in children.

Clinical & Imaging findings:

Goldenhar syndrome has a heterogenous phenotype with patients presenting with a spectrum of anomalies. A patient with classical Goldenhar syndrome presents with following characteristics:

- Preauricular skin tags, microtia or other external ear malformations including aplasia, and atresia of the external meatus; middle and occasionally inner ear anomalies.
- Epibulbar dermoid, colobomas or other eye anomalies like microphthalmia, anophthalmia, blepharophimosis etc.
- Hemifacial microsomia which includes unilateral facial hypoplasia, hypoplasia of the zygoma, maxilla and mandible.
- Vertebral column anomalies (atlas occipitalization, hemivertebrae, fused vertebrae and bifid spine).

There may be an association with other major organ system anomalies including cardiac structural defects, renal agenesis, pulmonary agenesis, vascular anomalies etc. [2, 3, 4]. There have been only few reports of Goldenhar syndrome with associated pulmonary anomalies in the literature [5,6,]. Most of the cases have been seen in infants. Usually, there is involvement of the lung on the same side as that of facial anomalies [7,8,9]. Rarely contralateral pulmonary involvement has also been reported [10]. This is similar to what we observed in our case.

Treatment & Prognosis:

The facial and external auricular malformation requires reconstructive surgery to repair the asymmetry and produce cosmetically acceptable outcome. Most cases with pulmonary aplasia present with respiratory distress in the neonatal period and recurrent chest infections thereafter and therefore require proper medical management to control the infection.

However, our child had no history of perinatal respiratory distress or recurrent chest infection. The child was completely asymptomatic for respiratory complaints and the associated left lung aplasia was an incidental finding.

Differential Diagnosis:

Due to a diverse assortment of clinical anomalies the differential diagnosis of Goldenhar syndrome can be difficult.

A wide range of complex OAV spectrum of anomalies can occur where hemifacial microsomia lies on one side of the

spectrum whereas classical Goldenhar syndrome as discussed above lies on the other side. A variety of associated systemic anomalies like cardiovascular defects, pulmonary anomalies can also occur with classical Goldenhar syndrome.

Treacher Collins syndrome also called Mandibulofacial Dysostosis may be a differential diagnosis. This is a genetic abnormality due to bilateral malformation of 1st and 2nd branchial arches. It has an autosomal dominant mode of inheritance arising due to genetic mutation involving chromosome 5. The patient presents with facial, aural and ocular malformation similar to the child with Goldenhar syndrome but the presence of bilateral malformation strongly suggest a diagnosis of Treacher Collins syndrome [11]. It is important to recognise this entity as genetic counselling may be provided to the parents.

TEACHING POINT

Goldenhar syndrome is a complex malformation involving the structures arising from the first and second branchial arches and primordia of the temporal bone. There is also association with other major organ system anomalies including cardiac structural defects, renal agenesis and pulmonary agenesis. Therefore, a patient with this anomaly should be thoroughly investigated for any systemic abnormality even if they are asymptomatic.

REFERENCES

1. Berker N, Acaroglu G, Soykan E. Goldenhar's Syndrome (oculo-auriculo-vertebral dysplasia) with congenital facial nerve palsy. *Yonsei Med J.* 2004;45(1):157-160. PMID: 15004885.
2. Kokavec R, Goldenhar Syndrome with Various Clinical Manifestations. *The Cleft Palate-Craniofacial Journal* 2006; 43(5): 628-34. PMID: 16986988.
3. Greenough A, Ahmed T, Broughton S. Unilateral pulmonary agenesis. *J Perinat Med* 2006;34:80-1. PMID: 16502557.
4. Fischer M, Gorenflo M, Eichhorn J. First description of unilateral lung agenesis and anomalous pulmonary venous connection in a newborn with Goldenhar syndrome. *Cardiol Young.* 2012 Jun;22(3):344-5. PMID: 22309948.
5. Ermis B, Oztas N, Yildirim M, Hosnuter M, Yavuz T. Pulmonary hypoplasia in a newborn with Goldenhar Syndrome. *J Pediatr.* 2010 Jan; 156(1):161. PMID: 20006771.
6. Downing GJ, Kilbride H. An interesting case presentation: pulmonary malformations associated with oculoauriculo-vertebral dysplasia (Goldenhar anomaly). *J Perinatol.* 1991;11:190-192. PMID: 1890482.
7. Milani D, Selicorni A. Right pulmonary agenesis with ipsilateral microtia: a new laterality association or part of the

oculoauriculovertebral spectrum? Prenat Diagn 2002;22:1053-4. PMID: 12424776.

8. Cunningham ML, Mann N. Pulmonary agenesis: A predictor of ipsilateral malformations. Am J Med Genet 1997;70:391-8. PMID: 9182780.

9. Ermis B, Oztas N, Yildirim M, Hosnuter M, Yavuz T. Pulmonary hypoplasia in a newborn with Goldenhar syndrome. J pediatr. 2010 Jan;156(1):161. PMID: 20006771.

10. Cekmez F, Ince EZ, Coban A, Yildirim S, Bulut EO, Kayserili. Goldenhar syndrome: a new case expanding the phenotype by costal agenesis and pulmonary hypoplasia. Eur Rev Med Pharmacol Sci. 2012 Sep;16(9):1307-8. PMID: 23047519.

11. Tiner BD, Quaroni AL. Facial asymmetries in hemifacial microsomia, Goldenhar syndrome, and Treacher Collins syndrome. Atlas Oral Maxillofac Surg Clin North Am. 1996;4(1):37-52. PMID: 11873461.

FIGURES

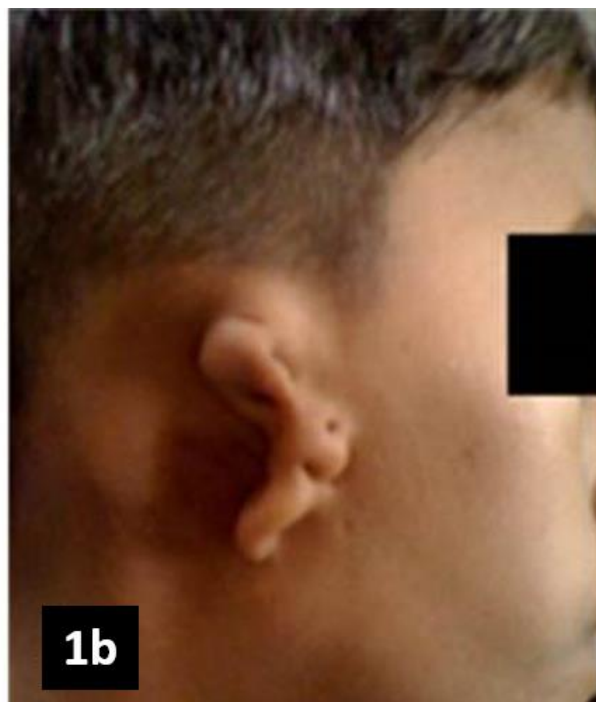
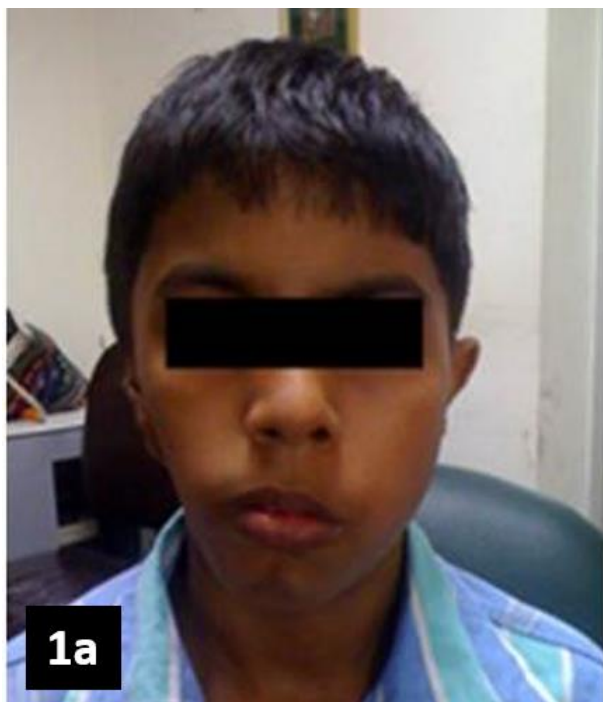
Figure 1: 13-year old boy with Goldenhar syndrome.

FINDINGS:

Frontal (a) and lateral (b) photograph showing facial asymmetry with flattening of the right side and ipsilateral microtia.

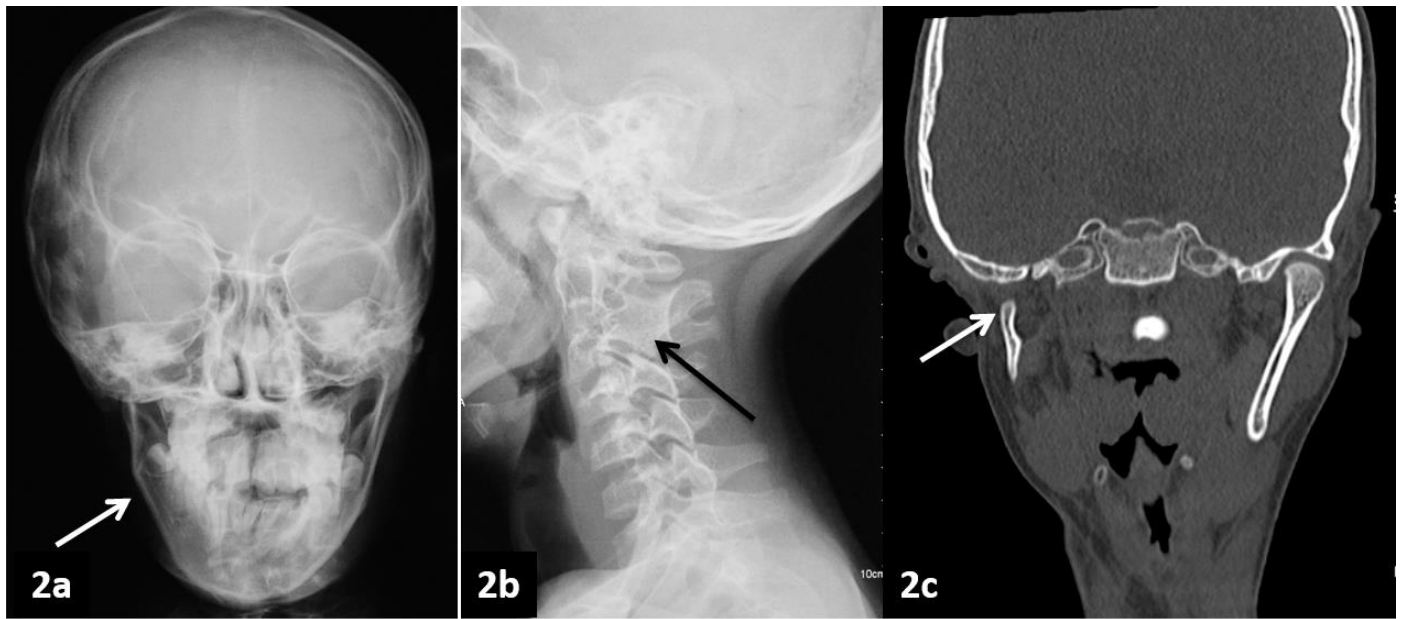


Figure 2: 13-year old boy with Goldenhar syndrome.

FINDINGS:

a. Frontal radiograph of face demonstrates hypoplasia of mandible on right side (white arrow). **TECHNIQUE:** Postero-anterior views of skull, kV: 73, mAs:4.35.

b. Lateral cervical spine radiograph reveals C2-C3 block vertebrae (black arrow). **TECHNIQUE:** Lateral view of cervical spine, kV: 73, mAs:1.64.

c. Coronal CT Bone window settings(Width:1500, Centre:450) scans of Face shows hypoplastic right mandibular condylar process with shallow right glenoid fossa (white arrow). **TECHNIQUE:** Coronal CT, kV:120 mAs:150, 1 mm slice thickness.

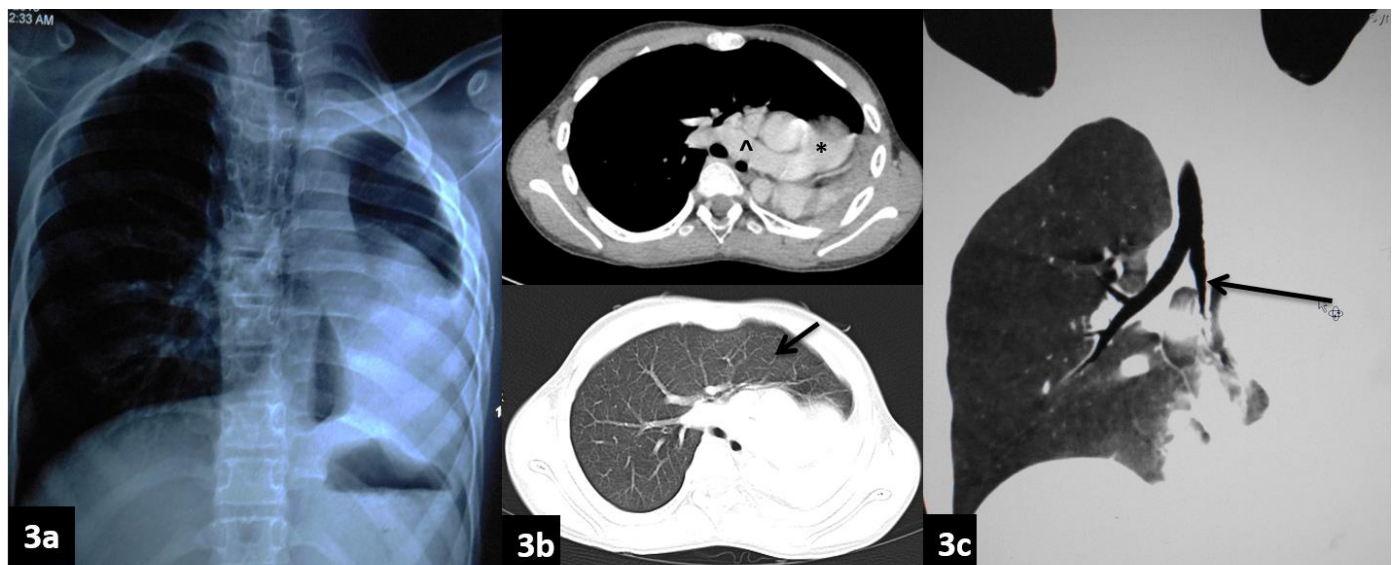


Figure 3: 13-year old boy with Goldenhar syndrome.

FINDINGS:

a. Chest radiograph PA view reveals small left hemithorax with crowding of ribs. There is tracheo-mediastinal shift and trans-mediastinal herniation of right lung towards left side (black arrow). **TECHNIQUE:** Posteroanterior view of chest, kV: 125, mAs: 1.11.

b. Axial contrast enhanced CT in mediastinal (Width: 400, Centre: 40) and lung (Width:1200, Centre:-600) window settings reveals absent left pulmonary artery with retrosternal herniation of right lung into left hemithorax (arrow). Main Pulmonary Trunk (*) and Right Pulmonary Artery (^) **TECHNIQUE:** Axial CT, kV: 120, mAs: 150, 1 mm slice thickness.

c. Coronal Minimum Intensity Projection (MinIP) image shows aplasia of left lung with atretic left main bronchus (black arrow). **TECHNIQUE:** Coronal CT, kV: 120, mAs: 150, 1 mm slice thickness.

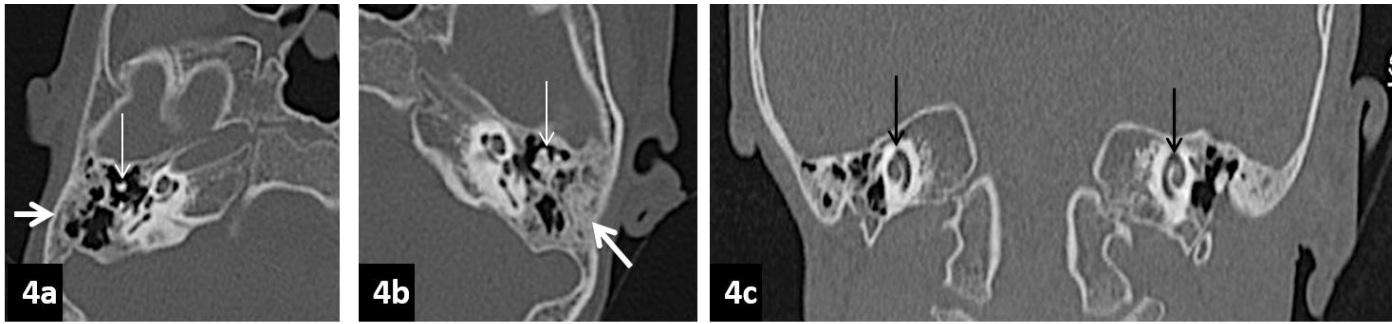


Figure 4: 13-year old boy with Goldenhar syndrome.

FINDINGS:

a and b. Bilateral Temporal Bones HRCT axial sections reveal bilateral external auditory canal atresia with bony atretic plate covering the middle ear cavity (thick white arrow). Right sided ear ossicles are dysplastic (thin white arrow) with normal "ice-cream cone" appearance of left ear ossicles (thin arrow in 4b). **TECHNIQUE:** Axial HRCT Temporal bones, kV: 140, mAs:220, 0.6mm slice thickness.

c. Bilateral Temporal Bones HRCT coronal sections reveal normal bilateral cochlea (arrow). **TECHNIQUE:** coronal HRCT Temporal bones, kV: 140, mAs:220, 0.6mm slice thickness.

Etiology	Not completely understood
Incidence	1 in 3500 to 5600 live births
Gender Ratio	No gender predilection
Age	Congenital; present since birth
Predilection	
Risk Factors	No known risk factors known
Treatment	Depends on the clinical symptoms: <ul style="list-style-type: none"> • Hearing aid for deafness. • Reconstructive surgery for aural and facial deformity. • Medical management if pulmonary symptoms occur.
Prognosis	Is not a life threatening condition; the deformity however is permanent.
Imaging findings	<p><u>X-ray:</u></p> <ul style="list-style-type: none"> • Unilateral hypoplasia of mandibular ramus and zygoma, segmentation anomaly (block vertebra) of cervical vertebrae. • Chest: small unilateral hemithorax with crowding of ipsilateral ribs and ipsilateral tracheo-mediastinal shift. <p><u>CT:</u></p> <ul style="list-style-type: none"> • Unilateral hypoplasia of zygoma, maxilla, and mandible including ramus, coronoid and condylar processes with shallow right glenoid fossa. • Chest: absence of unilateral lung with atretic bronchus and absent ipsilateral pulmonary artery and vein. There is tracheo-mediastinal shift towards ipsilateral side and compensatory hyperinflation of contralateral lung with its trans-mediastinal herniation. • HRCT Temporal bone: non-visualization of bilateral external auditory canal with an atretic bony plate covering the middle ear cavity and dysplastic ear ossicles.

Table 1: Summary table of Goldenhar Syndrome.

	Clinical Entity	Clinical findings	Imaging findings
1.	Oculo-auriculo-vertebral (OAV) Spectrum Anomalies		
a.	Hemifacial Microsomia	Unilateral asymmetric facies	X-ray and CT: Unilateral hypoplasia of facial bones.
b.	Classical Goldenhar syndrome	<ul style="list-style-type: none"> • Aural: Preauricular skin tags, microtia or other external ear anomalies-aplasia/atresia of external ear; middle & inner ear anomalies. • Ocular: Epibulbar dermoid, coloboma, microphthalmia • Hemifacial microsomia. • Vertebral segmentation anomalies 	X-Ray: Unilateral hypoplasia of facial bones and segmentation vertebral anomalies. CT: <ul style="list-style-type: none"> • Face: unilateral hypoplasia of facial bones including zygoma, maxilla and mandible • HRCT Temporal bone: external auditory canal aplasia/ atresia with dysplastic ear ossicles.
c.	Associated major organ system anomalies	<ul style="list-style-type: none"> • Includes cardiac structural defects, renal agenesis, pulmonary agenesis etc. 	
2.	Treacher Collins syndrome (Mandibulofacial Dysostosis)	<ul style="list-style-type: none"> • Autosomal dominant genetic syndrome. • Bilateral malformation of 1st and 2nd branchial arches. 	<ul style="list-style-type: none"> • Imaging findings similar to Goldenhar syndrome but seen bilaterally.

Table 2: Differential diagnosis for Goldenhar Syndrome.

ABBREVIATIONS

CT = Computed Tomography
 HRCT = High Resolution Computed Tomography
 OAV = Oculo-auriculo-vertebral

KEYWORDS

Goldenhar syndrome; oculoauriculovertebral dysplasia; hemifacial microsomia; pulmonary aplasia; computed tomography

Online access

This publication is online available at:
www.radiologycases.com/index.php/radiologycases/article/view/2113

Peer discussion

Discuss this manuscript in our protected discussion forum at:
www.radiolopolis.com/forums/JRCR

Interactivity

This publication is available as an interactive article with scroll, window/level, magnify and more features.
 Available online at www.RadiologyCases.com

Published by EduRad



www.EduRad.org