

Currarino Syndrome and the Effect of a Large Anterior Sacral Meningocele on Distal Colostogram in an Anorectal Malformation

Jason K Lee^{1*}, Alexander J Towbin¹

1. Department of Radiology, Cincinnati Children's Hospital Medical Center, Cincinnati, Ohio, USA

* **Correspondence:** Jason K. Lee, Cincinnati Children's Hospital Medical Center, Department of Radiology, 3333 Burnet Avenue, ML 3051, Cincinnati, Ohio 45229, USA
(✉ Jason.Lee@CCHMC.org)

Radiology Case. 2016 Jun; 10(6):16-21 :: DOI: 10.3941/jrcr.v10i6.2068

ABSTRACT

Currarino syndrome is a congenital disorder, consisting of a triad of anomalies including an anorectal malformation, sacral anomaly, and a presacral mass. Anterior sacral meningoceles are the most common presacral mass. A young child presented to our institution with an unrepaired anorectal malformation and a large anterior sacral meningocele. We describe how the anterior meningocele affected the imaging work-up.

CASE REPORT

CASE REPORT

A 2-year-old male with a history of a complex anorectal malformation (ARM) consisting of a rectourethral fistula and a large anterior sacral meningocele was initially treated with a double-barrel colostomy at another institution. He was then referred to our facility for simultaneous definitive colorectal and neurosurgical repair. Prior to surgical intervention, imaging of the gastrointestinal tract, genitourinary tract, and spine was performed.

Clinical & Imaging Findings:

An MR of the pelvis was first performed (Fig.1, 2, & 3) utilizing the following sequences: coronal T1, coronal 3D proton density, axial and sagittal T2 with and without fat saturation, direct coronal T2, and a coronal T2 oblique to the plane of the rectum. Images from this study showed a large anterior sacral meningocele displacing the bladder anteriorly, superiorly, and towards the right side of the pelvis. The bladder had a vertical appearance and the bladder neck was elongated. As is typical on MRI, the fistula was not visible. In this case, the large meningocele and distorted bladder made visualization impossible.

One day later, the patient underwent a high-pressure distal colostogram. In order to perform this procedure, an 8 -French Foley catheter was inserted into the ostomy of the distal colon and the balloon was inflated with 2 ml of air just beneath the skin surface to prevent leakage. With the patient supine, the catheter was injected with 60 mL water soluble contrast (Fig. 4). The initial images showed a long segment of distal colon traversing from the ostomy to the rectum. Approximately 2 cm from the ostomy site, the colon folded back upon itself. This fold made it impossible to generate the pressure required to distend the distal rectum; therefore, the Foley catheter was advanced so that the tip was beyond the fold (Fig. 5). At this point, contrast was again injected through the catheter and the rectum was able to be distended.

The patient was then moved to the left lateral decubitus position to best see the rectourinary fistula. With continued pressure, a small linear area of contrast was seen overlying the pubic symphysis. In order to fully visualize the fistula, the patient was then placed into a right posterior oblique position which showed a rectourethral fistula. As contrast was continued to be injected, a small amount began to pool over the right iliac crest in the region of the urinary bladder (Fig. 6).

Several days after the performance of the distal colostogram the patient underwent cystoscopy, a posterior sagittal anorectoplasty for a rectoprostatic urethral fistula, as well as a suprapubic catheter placement. At the time of repair the patient was noted to have a large anterior meningocele, which was partially repaired several months earlier, but was still large enough to compress the descending colon and rectum toward the left, and displace the bladder superiorly and anteriorly. It was also noted that a lot of fibrotic tissue was encountered at the time of dissection and that the anatomy was clearly abnormal due to the presence of anterior meningocele.

DISCUSSION

Etiology & Demographics:

ARMs are congenital anomalies that occur in approximately 1 in 5000 live births and range in severity from anal stenosis or imperforate anus to complex deformities such as cloacal exstrophy [1]. Risk factors for an ARM include genetic predisposition, prenatal exposure to nicotine, alcohol, caffeine, or illicit drugs, maternal obesity and maternal diabetes mellitus [2]. Children with an ARM may also present with other associated anomalies. The Currarino syndrome is a triad of anomalies consisting of an ARM, sacral defect, and presacral mass [3]. It occurs in approximately 1 in 100,000 people [4]. Anterior sacral meningoceles are the most common presacral mass in patients with Currarino syndrome occurring in 60% of patients; and its presence may affect the surgical management of these patients [5, 6]. Other potential presacral masses include a presacral teratoma or an enteric cyst.

Treatment & Prognosis:

Palliative surgery is initially performed in an infant born with an ARM to divert the colon and allow the patient to mature before definitive surgery [1]. The initial palliative surgery of an imperforate anus includes a colostomy to allow enteric contents to evacuate while an additional stoma is created for the distal colon [1].

Patients with an underlying diagnosis of an ARM must undergo multiple radiologic examinations prior to definitive repair including abdominal radiograph to evaluate for masses and vertebral anomalies, abdominal and pelvic ultrasound to evaluate for urological abnormalities, fluoroscopic imaging of the genitourinary tract in order to evaluate the bladder and urethra, and an MRI of the abdomen, pelvis, and spine to evaluate the complexity of the malformation and pelvic musculature. A high pressure distal colostogram is also performed to identify if a fistulous tract from the rectum to either the bladder or urethra is present. While there is one report of MRI being used to define the fistula [7], we do not believe that this technique allows for adequate distension of the rectum or the fistula. In one study, the lack of a high pressure distal colostogram lead to misdiagnoses and an insufficient repair requiring reoperation [8]. Once all imaging is obtained and the anatomy is appropriately defined, a roadmap and clinical decision can be made for an appropriate surgical plan.

In this patient, the presence of a large anterior sacral meningocele altering the bladder anatomy affected the performance of the high-pressure distal colostogram. Normally, when performing a high-pressure distal colostogram the patient is placed in a true lateral position in order to optimally demonstrate the recto-urinary fistula. This allows the radiologist to determine if the fistula connects with the bladder or the urethra. Because of this patient's altered anatomy, the fistula could not be demonstrated with the patient in the true lateral position. However, when the patient was placed in the right posterior oblique position, the fistula was most apparent.

The long segment of distal colon with a proximal fold made it difficult to generate the pressure needed to distend the rectum. When performing a high-pressure distal colostogram, the rectum must be distended so that it appears rounded in its most distal portion. This ensures that the rectum is completely distended and helps to open the distal fistula. In our patient we were not able to generate the pressure to distend the rectum until the catheter was advanced beyond the proximal fold. Once the catheter was beyond this point and the rectum was distended, the fistula began to opacify. The second factor that made it difficult to identify the fistula in this patient was the large meningocele distending and distorting the bladder. Typically, when the bladder is at midline, the rectovesicular or rectourethral fistula is seen extending anteriorly from the rectum. Imaging the patient in the left lateral decubitus position helps to best display the fistula. In our patient, the anterior meningocele displaced the bladder anteriorly, laterally, and superiorly. This made it impossible to view the entire fistula in the left lateral decubitus position; instead, the patient was placed in the right posterior oblique position and the entire fistula was imaged.

The major risk of performing a high-pressure distal colostogram is bowel perforation. While enough hydrostatic pressure must be created during the distal colostogram to evaluate for the presence of a communicating fistula, the fluoroscopist must be wary that the colon is not over-distended. Thus, injection of contrast should continue until the rectal vault appears rounded in its distal-most portion on the lateral view. If a fistula is not present at this time, the study should be aborted. Typically, the risk of bowel perforation increases with increasing length of the distal colon. Given the length of the distal bowel in this patient, we were aware of the possibility for perforation during the procedure. When contrast began to pool in the right lower quadrant, we were concerned that a small perforation had occurred. Review of the preprocedural MRI along with rotating the patient helped to confirm that the pool of contrast was within the bladder and caused by the rectourethral fistula.

The MRI was used to help define the altered anatomy. It showed the anterior sacral meningocele displacing the bladder anteriorly, laterally, and superiorly distorting the bladder neck and proximal urethra. Once contrast started pooling in the right lower quadrant, knowledge of the appearance and location of the bladder was useful to confirm that the distal colon had not ruptured.

The location of the rectourethral or rectovesicular fistula is crucial for surgical planning. The high-pressure distal colostogram helps to define the patient's anatomy and provides the colorectal surgeon with a detailed road map prior to surgery. This roadmap allows the surgeon to determine if the definitive surgical repair should be performed via an intraabdominal incision or a posterior sagittal anorectal pull through approach. Although many ARMs can be safely repaired via a posterior sagittal approach, in patients with anterior sacral meningoceles, repair of the meningocele is performed first. This helps to prevent meningitis which can occur when the surgeries are performed simultaneously [3].

TEACHING POINT

Patients with a Currarino triad present with a spectrum of anomalies including a sacral defect, a presacral mass, and an anorectal malformation. Pelvic MRI and high-pressure distal colostogram are often needed in order to effectively diagnose and care for these patients.

REFERENCES

1. Levitt, MA. , and Pena, A. Anorectal Malformations. *Orphanet J Rare Dis.* 2007 Jul 26; 2:33. PMID: 17651510.
2. Zwink N, Jenetzky E, Brenner H. Parental risk factors and anorectal malformations: systematic review and meta-analysis. *Orphanet J Rare Dis* 2011 May 17; 6:25. PMID: 21586115.
3. Lee, SC, Chun, YS, Jung, SE, Park, KW, and Kim, WK. Currarino Triad: Anorectal Malformation, Sacral Bony Abnormality, and Presacral Mass-A Review of 11 Cases. 1997 Jan; 32(1): 58-61. PMID: 9021570.
4. Orphanet Report Series. Prevalence of Rare Diseases: Bibliographic Data 2014 http://www.orpha.net/orphacom/cahiers/docs/GB/Prevalence_of_rare_diseases_by_alphabetical_list.pdf. Accessed February 24, 2015.
5. Emans PJ, van Aalst J, van Heurn EL, Marcelis C, Kootstra G, Beets-Tan RG, Vles JS, Beuls EA. The Currarino triad: neurosurgical considerations. *Neurosurgery* 2006 May; 58(5):924-9. PMID: 16639328.
6. Samuel M, Hosie G, Holmes K. Currarino triad--diagnostic dilemma and a combined surgical approach. *J Pediatr Surg* 2000 Dec; 35(12):1790-4. PMID: 11101738.
7. Kavalcova L, Skaba R, Kyncl M, Rouskova B, Prochazka A. The diagnostic value of MRI fistulogram and MRI distal colostogram in patients with anorectal malformations. *J Pediatr Surg* 2013 Aug; 48(8):1806-9. PMID: 23932626.
8. Peña A, Grasshoff S, Levitt M. Reoperations in anorectal malformations. *J Pediatr Surg* 2007 Feb; 42(2):318-25. PMID: 17270542.

FIGURES

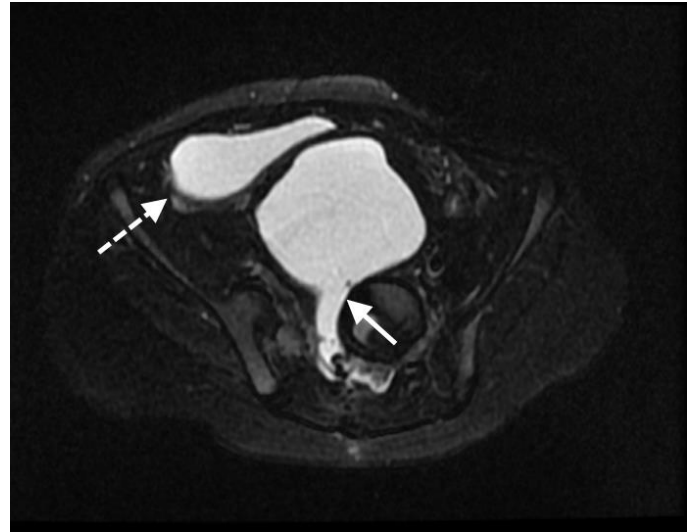


Figure 1: 2-year-old male with an anorectal malformation and large anterior sacral meningocele. MRI of the pelvis performed on 1.5 Tesla GE Scanner. **FINDINGS:** Axial T2 weighted image demonstrates a large anterior sacral meningocele (arrow) arising from the spine. The meningocele displaces the urinary bladder (dashed arrow) anteriorly and to the right of midline. **TECHNIQUE:** T2 FSE, TE 80, TR 3000, slice thickness 4 mm

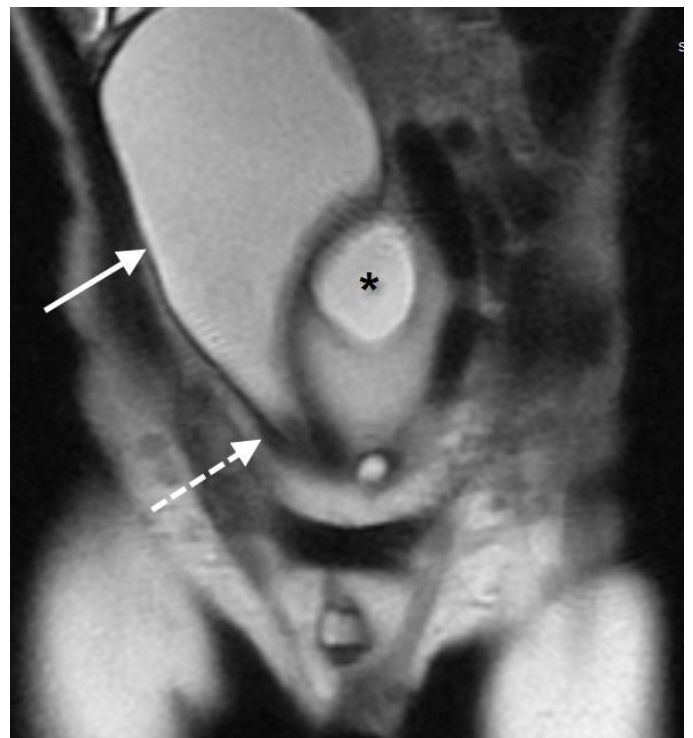


Figure 2: 2-year-old male with an anorectal malformation and large anterior sacral meningocele. MRI of the pelvis performed on 1.5 Tesla GE Scanner. **FINDINGS:** Coronal T2-weighted image of the lower abdomen and pelvis shows the elongated bladder (arrow) being displaced superiorly and to the right by the meningocele (dashed arrow)

(*). The bladder neck (dashed arrow) is stretched and narrowed.

TECHNIQUE: T2 FSE Coronal, TE 100, TR 1171, slice thickness 4 mm

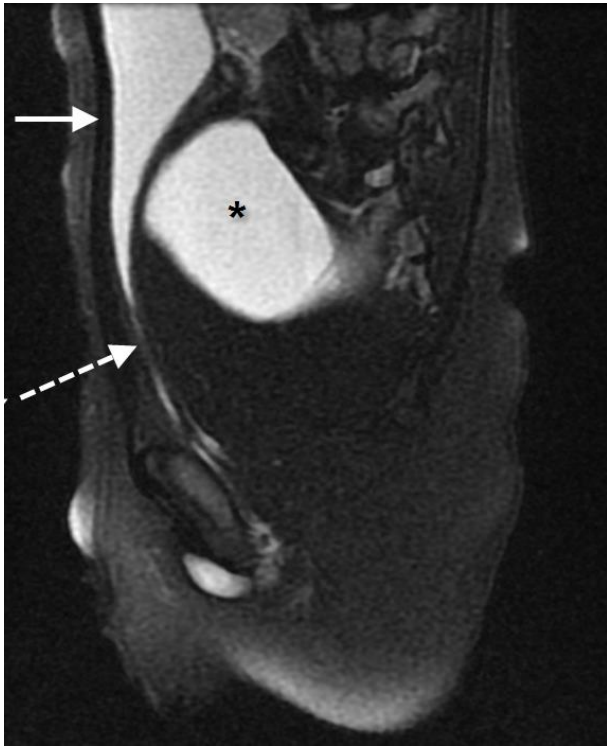

Figure 3: 2-year-old male with an anorectal malformation and large anterior sacral meningocele. MRI of the pelvis performed on 1.5 Tesla GE Scanner.

FINDINGS: Sagittal T2-weighted image shows the bladder (arrow) being displaced anteriorly and superiorly by the anterior meningocele (*). The bladder neck (dashed arrow) is stretched and elongated.

TECHNIQUE: T2 FSE Saggital, TE 82, TR 4000, slice thickness 4 mm

Figure 5 (right): 2-year-old male with an anorectal malformation and large anterior sacral meningocele. A total of 60 mL of Visipaque water soluble contrast media was hand injected through an 8 Fr Foley catheter inflated within the mucous fistula.

FINDINGS: Supine image from the distal colostogram performed after the Foley catheter was advanced shows improved distension of the distal colon. The recto-urinary fistula is now visible (arrow) appearing as a linear area of contrast extending over the pubic symphysis. Also note that contrast is now present in the penile urethra (arrowheads) and the urinary bladder (dashed arrow).

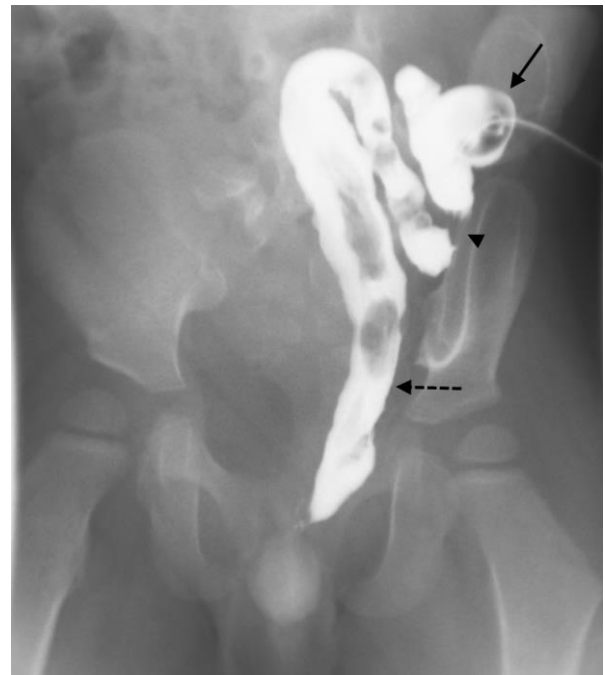


Figure 4: 2-year-old male with an anorectal malformation and large anterior sacral meningocele. A total of 60 mL of Visipaque water soluble contrast media was hand injected through a 8 Fr Foley catheter inflated within the mucous fistula.

FINDINGS: Supine image from a high-pressure distal colostogram performed in the same patient shows the balloon of the Foley catheter (arrow) in the proximal colon near the ostomy. The distal colon and rectum (dashed arrow) is displaced to the left of midline due to mass effect from the anterior meningocele. The rectum is not able to be distended to the length of the colon and the fold (arrowhead) near the Foley catheter balloon. Note that the sacrum has a sickle shape and is curved with the distal sacrum pointing towards the right.

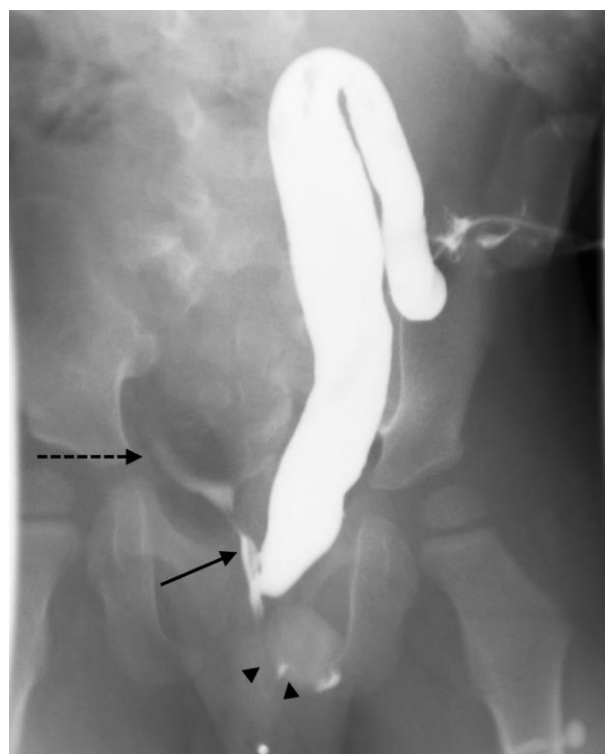

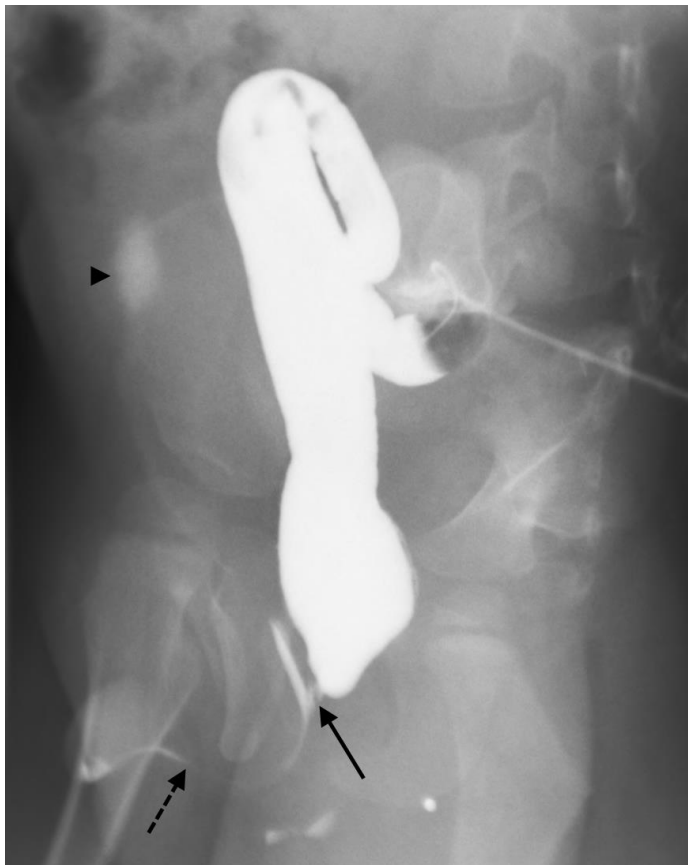


Figure 6 (left): 2-year-old male with an anorectal malformation and large anterior sacral meningocele. A total of 60 mL of Visipaque water soluble contrast media was hand injected through a 8 Fr Foley catheter inflated within the mucous fistula.

FINDINGS: Oblique image performed during the distal colostogram shows the rectourinary fistula (arrow). Contrast is also present within the penile urethra (dashed arrow) and urinary bladder (arrowhead). The contrast in the urinary bladder is amorphous and was initially concerning for perforation. Knowledge of the patient's anatomy on the MRI allowed us to confidently state that this contrast was in the bladder.

Etiology	Hereditary disorder caused by a mutation in the coding sequence of <i>HLXB9</i> , localized to chromosome 7q36. The disorder can be inherited in an autosomal dominant fashion or may be due to a sporadic mutation.
Incidence	Anorectal malformations occur in 1 in 5000 live births. Currarino syndrome is a spectrum of anomalies that occur in 1-9 of 100,000 people.
Gender ratio	Female to male ratio in pediatric cases is 2:1 Female to male ratio in adult cases is 6:1
Age Predilection	The majority of patients are diagnosed at birth due to the presence of an imperforate anus
Risk Factors	None
Treatment	Excision of presacral mass. Repair of anorectal malformation.
Prognosis	Early diagnosis can improve patient prognosis due to the potential risk of a delayed diagnosis of a sacrococcygeal teratoma
Findings on Imaging	<ul style="list-style-type: none"> • Radiography in the immediate neonatal period demonstrates a sickle-shaped sacrum and dilated and distended air-filled loops of bowel. Once the colon is diverted, the bowel distension resolves. • MRI shows the sacral abnormality and the presence of a presacral mass. Anterior sacral meningoceles appear as a fluid signal collection arising from the anterior aspect of the spine at the level of a vertebral defect. Presacral teratomas are often multiseptated cystic masses. They can have variable amounts of soft tissue and fat making their appearance heterogeneous. • High-pressure distal colostogram shows a small, unused sigmoid colon. A rectourethral fistula is almost always present.

Table 1: Summary table for Currarino Syndrome.

	Anterior Sacral Meningocele	Presacral Teratoma
X-ray	See vertebral anomaly	May see soft tissue mass or speckled calcifications. Mass is usually completely internal in patients with an anorectal malformation
Ultrasound	Anechoic	Heterogeneous with portions that are anechoic, portions that are hypoechoic, and portions that are hyperechoic
CT	Fluid density	Heterogeneous with fluid, soft tissue, fat, and or calcium density
MRI-T1	Hypointense, fluid signal	Heterogeneous. Cystic areas are fluid signal; solid areas are usually isointense compared to muscle; calcification and fat (if not fat saturated) can be hyperintense.
MRI-T2	Hyperintense, fluid signal	Heterogeneous. Cystic areas are fluid signal; solid areas are usually hyperintense compared to muscle; calcification and fat (if fat saturated) can be hypointense.
Contrast enhancement	None	Tumor is often highly vascular

Table 2: Differential diagnosis table for presacral mass as part of Currarino Syndrome.

ABBREVIATIONS

ARM = Anorectal malformation
 MRI = Magnetic Resonance Imaging

KEYWORDS

anorectal malformation; meningocele; colostogram; Currarino triad; MRI

Online access

This publication is online available at:
www.radiologycases.com/index.php/radiologycases/article/view/2068

Peer discussion

Discuss this manuscript in our protected discussion forum at:
www.radiolopolis.com/forums/JRCR

Interactivity

This publication is available as an interactive article with scroll, window/level, magnify and more features.
 Available online at www.RadiologyCases.com

Published by EduRad



www.EduRad.org