

Anaplastic Cutaneous Lymphoma Mimicking an Infection

Luciana Barbosa^{1*}, Manuel João Brito², Inês Balaco³, Maria José Noruegas¹

1. Radiology Department, Centro Hospitalar e Universitário de Coimbra, Coimbra, Portugal

2. Pediatric Oncology Department, Centro Hospitalar e Universitário de Coimbra, Coimbra, Portugal

3. Pediatric Orthopedic Department, Centro Hospitalar e Universitário de Coimbra, Coimbra, Portugal

* **Correspondence:** Luciana Bernardes Barbosa, Radiology Department, Centro Hospitalar e Universitário de Coimbra, Quinta dos Vales, 3041-801 S. Martinho do Bispo - Coimbra, Portugal
(✉ lucianabernardesbarbosa@gmail.com)

Radiology Case. 2014 Mar; 8(3):39-47 :: DOI: 10.3941/jrcr.v8i3.1934

ABSTRACT

We present a case of a 17-year-old boy who presented with a skin lesion with extension to the soft tissues of the left thigh. On ultrasound, a homogeneous and hypoechoic expansile formation in the subcutaneous tissue was found, measuring 6.5 × 5 × 3.5 cm, with scarce vascularization. Computed tomography showed a low attenuating neof ormation with surrounding edema. An inflammatory disorder was the first diagnosis, but the absence of improvement with antibiotics led us to perform magnetic resonance imaging that showed a high signal lesion on T2-weighted imaging and low intensity signal on T1-weighted imaging and surrounding contrast uptake. Positron emission tomography and computed tomography showed uptake of 18F-fluorodeoxyglucose by the lesion. The final diagnosis was anaplastic cutaneous lymphoma.

CASE REPORT

CASE REPORT

A 17 year old boy visited the Emergency Department (Fig. 1) for complaints of slight pain and swelling of the anterior aspect of his left thigh for two weeks. He did not have flushing and denied any injury. He previously practiced cycling. One week earlier central small serous looking vesicles surrounded by scaly skin had appeared. In the following days new small vesicles appeared and the skin shedding increased; associated pruritus also developed. At this point, he was prescribed with oral antibiotics for a presumed skin infection. He did not have fever or any other symptoms.

He returned to hospital because there was a gradual increase of skin flushing.

Imaging workup: An ultrasound study was performed (Fig. 2) that showed a homogeneous and hypoechoic expansile formation in the subcutaneous tissue, with relatively well-

defined contours, measuring 6.5 × 5 × 3.5 cm. The periphery was highly vascularized, which raised the suspicion of an abscess. He was admitted and intravenous antibiotics and antifungal therapy were begun. During his stay in hospital he spiked a fever (38.2°C).

A computed tomography (CT) scan (Figures 3 and 4) was performed and showed, a low attenuating mass between the medial and intermedius vastus muscles of his left thigh that demonstrated peripheral enhancement after iodine contrast. There were no structural changes in the left femoral diaphysis, suggesting the absence of bone involvement.

Magnetic resonance (MR) images (Figures 5 and 6) showed an evident heterogeneous neof ormation with high signal on T2-weighted imaging (WI) and low intensity signal on T1-WI. There was mild edema in surrounding tissue. There was no gadolinium uptake inside the lesion, and there was some gadolinium uptake in surround tissue.

Pathologic evaluation: The patient first underwent an ultrasound-guided 18-gauge biopsy, which was non-diagnostic, then a surgical biopsy and partial excision. Histological analysis showed the presence of large cell anaplastic lymphoma of the soft tissue of the left thigh (Fig. 7). The specimen was antiendomysial antibody (EMA) and anaplastic lymphoma kinase (ALK) negative.

The patient underwent Positron Emission Tomography (PET) one week after partial surgical excision (before chemotherapy); scan showed extension of the tumor size similar to pre-excision (Fig. 8) and corroborated re-growth of the mass.

Follow-up: Chemotherapy with pediatric Non-Hodgkin Lymphoma Berlin-Frankfurt-Münster (NHL-BFM) protocol was initialized with good clinical analytic response.

DISCUSSION

Etiology, demographics and prognosis

Anaplastic large cell lymphoma (ALCL) is a high-grade lymphoma with a survival rate around 75% [1]. Cutaneous anaplastic large cell lymphoma (C-ALCL) (Table 1) is a subtype of T-cell lymphoma, that comprises 1.7 % of all these pathologies [2]. Prognosis depends on whether a patient is ALK-positive or -negative. ALK-positive disease responds well to chemotherapy, most patients respond with long-term remission or cure. Most people with ALK-negative ALCL respond to chemotherapy, but many will relapse within five years. Furthermore, they are sometimes treated more aggressively, often with stem cell transplant.

The ALK-positive subtype usually affects children and young adults. The ALK-negative subtype is more commonly found in patients over age 60. However, in the pediatric age group, ALK is not a prognostic factor [3,4]. Event-free 5-year survival of C-ALCL is around 90% [5].

Male to female ratio is from 1.5 to 2.0:1 [3]. A relationship between ALCL and insect bites has been proposed by some authors [6] who reported that the initial diagnosis of these lesions was consistent with nonmalignant inflammatory disease, similar to our case. Our patient has denied history of an insect bite.

Clinical and imaging findings

Subcutaneous masses are extremely common in ALCL. Deep-seated soft tissue masses (intermuscular, intramuscular or intrarticular) are usually found by imaging because of inadequate clinical assessment. One should start with ultrasonography because this is an inexpensive and accessible modality.

When ALCL presents in the skin it is called primary cutaneous ALCL and follows a less aggressive course. In approximately 10% of patients, primary cutaneous ALCL extends beyond the skin to lymph nodes or organs. If this occurs, it is usually managed similarly to the systemic form of

ALCL. Furthermore, ALCL can occur in virtually any location of the body.

Clinically this neoplasm is characterized by skin plaques or nodules [2]. In older adults, it usually manifests as a primary cutaneous disease with a solitary lesion. C-ALCLs are rare in the pediatric age group [7]; in a few cases of C-ALCL the disease is disseminated [8].

The skin alterations of C-ALCL are often mistaken for many other dermatologic conditions, including skin infections. Ultrasound is a rapid and effective technique to evaluate soft tissue pathologies; therefore, it is a feasible method to initially evaluate these lesions. Fever and other constitutional symptoms are common in ALCL, but not in C-ALCL.

Differential Diagnoses (Table 2)

The major differential diagnoses are neoplastic and inflammatory diseases. Three principle neoplastic diagnoses should be considered for patients of this age group (a lymphoproliferative disorder, including ALCL, a metastasis and rhabdomyosarcoma).

A. Inflammatory disorders

One should consider inflammatory disorders, abscess and phlegmonous tissue, which usually presents with a typical history of local inflammation (redness, swelling, pain) and fever.

1. Phlegmon

On ultrasound we usually find heterogeneous hypoechoic walled-off infiltrative tissue without positive internal Doppler, but with high external vascularization. CT should show infiltrative soft tissue attenuating mass. MR imaging (MRI) may show high signal on T2-WI and low intensity signal on T1-WI; rim enhancement is typical. PET usually shows typical avid 18F-FDG uptake.

2. Abscess

On ultrasound we usually find a well-circumscribed fluid collection that may contain "solid" echoes and high external vascularization. CT should show a fluid attenuating lesion, with or without necrosis and gas; edema is usually present in the surrounding tissue. MRI may show high signal on T2-WI and low intensity signal on T1-WI; rim enhancement and no uptake inside an abscess are typical. PET usually shows typical avid 18F-FDG uptake.

B. Neoplastic disorder

One should consider the following neoplastic disorders in pediatric patients: lymphoproliferative disorders, rhabdomyosarcoma and metastasis.

1. Lymphoproliferative disorders (including C-ALCL)

These are more common in adolescents. On ultrasound, we usually find a solid expansile mass with positive internal Doppler, the intensity depends on the etiology. They usually have scarce vascularization. On CT we find a mild attenuation neoformation; surrounding edema may be present. MRI shows a heterogeneous neoformation; edema in surrounding tissue might be present. T1-WI usually shows a hypointense signal and T2-WI shows a hyperintense signal. The pattern of contrast enhancement on CT depends on the type of

lymphoproliferative disorder; uptake is often avid. PET usually shows 18F-FDG uptake.

2. Rhabdomyosarcoma

This tumor usually occurs in younger patients. On ultrasound, we usually find a solid heterogeneous expansile mass with positive internal Doppler inside, which might have bizarre vessels. On CT we find a heterogeneous mass with low to mild attenuation. MRI might show a heterogeneous neof ormation; T1-WI may show hypointense signal and T2-WI may show hyperintense signal. Rhabdomyosarcoma has heterogeneous contrast uptake and PET usually shows 18F-FDG uptake.

3. Metastasis

Metastases appear in patients with a known primary neoplastic condition. On US we find a solid mass, usually with central vascularization. On CT we may find a low attenuation heterogeneous mass and on MR a heterogeneous neof ormation with edema in surrounding tissue might be present; T1-WI may show hypointense signal and T2-WI hyperintense signal except, for example, a melanoma metastasis that usually shows high intensity on T1-WI and low signal on T2-WI. The pattern of contrast enhancement depends on the etiology of the primary tumor; often there is contrast uptake. Usually there are multiple locations of 18F-FDG uptake on PET.

Although CT is usually a good method to diagnose and stage C-ALCL, in our case it was the MRI that led to the suspicion of an expansile neoplasm.

Currently PET-CT is the method most often used to stage ALCL and it was mandatory in our case because of systemic symptoms [9]. The uptake of 18F-FDG by tissues is a marker for the tissue uptake of glucose, which in turn is closely correlated with tissue metabolism. Indeed, findings after 18F-FDG injection are similar for all differential diagnoses.

Probably if the diagnosis of our patient would have been made earlier, the usual therapeutic to C-ALCL would have been followed. However, our patient's tumor had a more aggressive behavior than had been reported [4].

Treatment

Although histological features in our case favored the diagnosis of the cutaneous form, clinical behavior, with fever and regrowth of tumor, led us to choose treatment with systemic chemotherapy [10,11]. The diagnosis was delayed by the initial hypothesis of an inflammatory disorder, which is one of the principal differential diagnoses.

ALCL is treated with systemic chemotherapy; C-ALCL can usually be managed with surgery or radiotherapy only.

TEACHING POINT

Anaplastic large cell cutaneous lymphoma is a relatively rare lymphoma subtype. In approximately 10 % of patients, anaplastic large cell cutaneous lymphoma extends beyond the skin to lymph nodes or organs. In those cases, it is usually managed similarly to the systemic form of anaplastic large cell cutaneous lymphoma.

REFERENCES

1. Lowe EJ, Sposto R, Perkins SL et al. Intensive chemotherapy for systemic anaplastic large cell lymphoma in children and adolescents: final results of Children's Cancer Group Study 5941. *Pediatr Blood Cancer.* 2009 Mar. PMID 18985718.
2. Stein H, Foss HD, Dürkop H, et al. CD30+ anaplastic large cell lymphoma: a review of its histopathologic, genetic, and clinical features. *Blood* 2000 vol 96 no 12, 3681-95. PMID 11090048.
3. Liu HL, Hoppe RT, Kohler S, Harvell JD, Reddy S, Kim YH. CD30+ The Stanford experience in lymphomatoid papulosis and primary cutaneous anaplastic cutaneous lymphoproliferative disorders. *J Am Acad Dermatol.* 2003 1049-58. PMID 14639383.
4. Ait-Tahar K, Damm-Welk C, Burkhardt B, et al.: Correlation of the autoantibody response to the ALK oncoantigen in pediatric anaplastic lymphoma kinase-positive anaplastic large cell lymphoma with tumor dissemination and relapse risk. *Blood* 115 (16): 3314-9, 2010. PMID 20185586.
5. DeCoteau JF, Butmarc JR, Kinney MC, Kadin ME. The t(2;5) chromosomal translocation is not a common feature of primary cutaneous CD30+ lymphoproliferative disorders: comparison with anaplastic large-cell lymphoma of nodal origin. *Blood* 1996 87: 3437-41. PMID 8605362.
6. Lamant L, Pileri S, Sabattini E, Brugieres L, Jaffe ES, Delsol G. Cutaneous presentation of ALK-positive anaplastic large cell lymphoma following insect bites: evidence for an association in five cases. *Haematologica.* Mar 2010;95(3):449-55. PMID: 19951975.
7. Leboit PE, et al. Lymphomatoid papulosis and cutaneous CD30+ lymphoma. *Am J Dermatopathol* 1996; 18:221-35. PMID 8806956.
8. Beljaards RC, Kaudewitz P, Berti E, et al. Primary Cutaneous CD30-Positive Large Cell Lymphoma: Definition of a New Type of Cutaneous Lymphoma with a Favorable Prognosis. *Cancer* 1993 vol 71 no 6, 2097-2104. PMID 8382999.
9. Otero HJ, Jagannathan JP, Prevedello LM, et al. CT and PET/CT Findings of T-Cell Lymphoma. *AJR* 2009 vol. 193 no. 2 349-358. PMID 19620431.
10. Link MP, Shuster JJ, Donaldson SS, Berard CW, Murphy SB. Treatment of children and young adults with early stage non-Hodgkin lymphoma. *N Engl J Med* 1997; 337:1259-66. PMID 9345074.
11. Reiter A, Schrappe M, Ludwig WD, et al.: Intensive ALL-type therapy without local radiotherapy provides a 90% event-free survival for children with T-cell lymphoblastic lymphoma: a BFM group report. *Blood* 95 (2): 416-21, 2000. PMID 10627444.

FIGURES

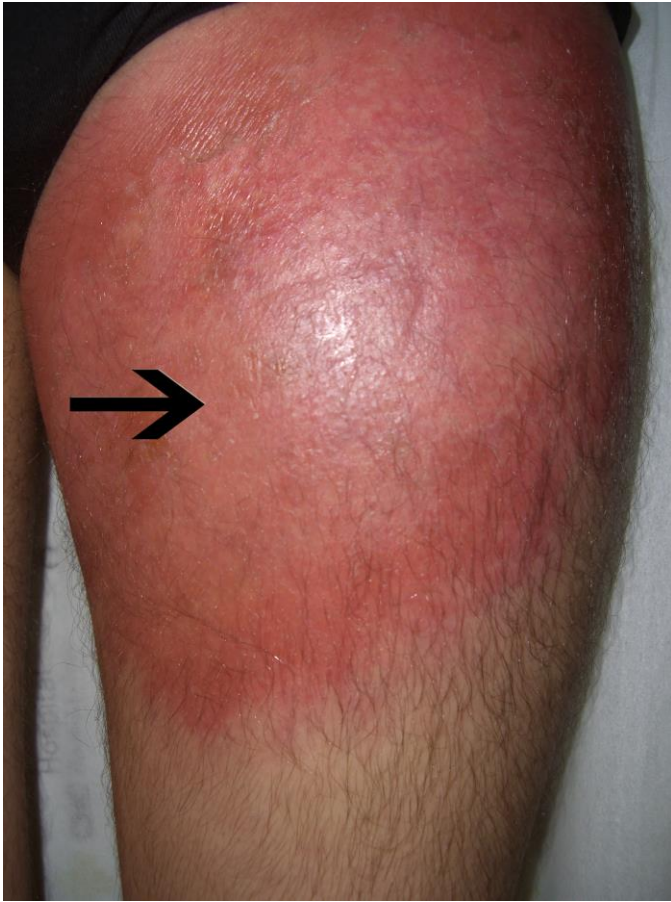

Figure 1 (left): Seventeen-year-old male with anaplastic large cell cutaneous lymphoma. Presentation photograph of the thigh at time of presentation to the Emergency Department: Swelling and redness with central small serous vesicle (arrow) surrounded by scaly skin.

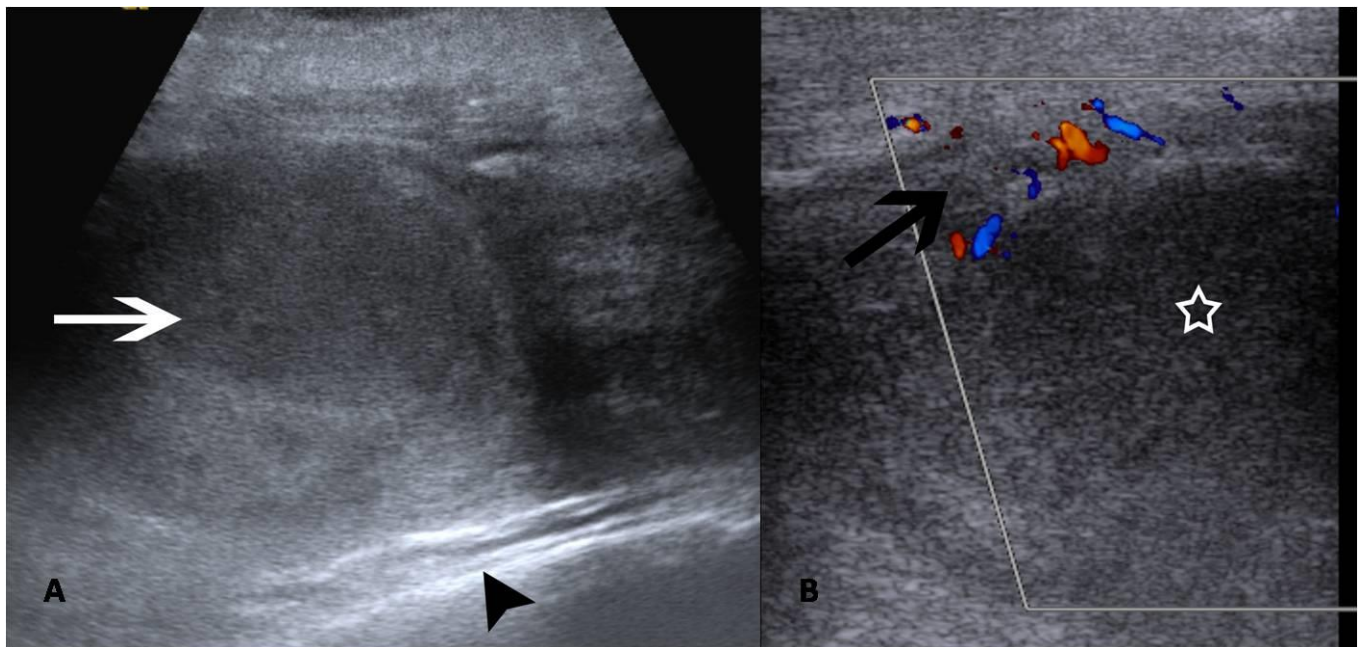


Figure 2 (bottom): Seventeen-year-old male with anaplastic large cell cutaneous lymphoma. A) Ultrasound (Siemens S2000) revealed a subcutaneous homogeneous and hypoechoic expansile formation (white arrow) with relatively well-defined contours, measuring $6.5 \times 5 \times 3.5$ cm. Arrow head indicates femur beneath the lesion. B) The periphery was highly vascularized (black arrow).

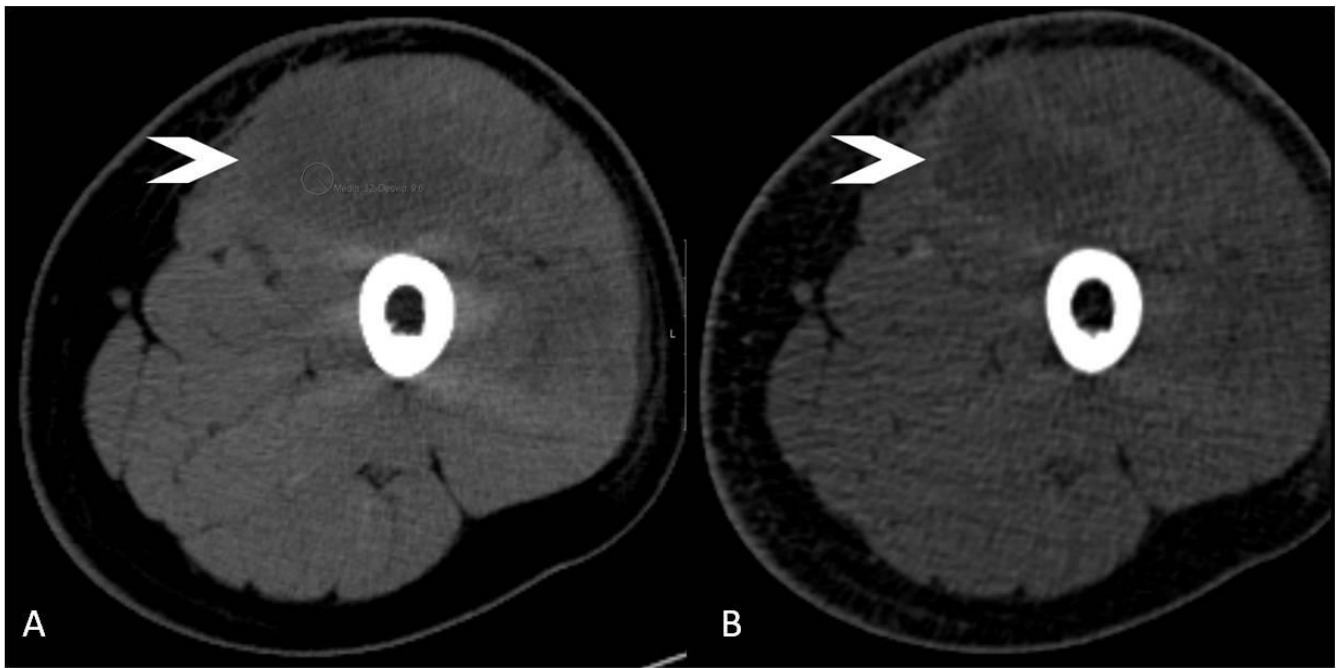


Figure 3: Seventeen-year-old male with anaplastic large cell cutaneous lymphoma. A) Non-contrast CT (Siemens 64 slice, protocol 120kVp, axial, 2 mm) shows an expansile soft tissue lesion between the medial and intermedius vastus muscles (arrow head). B) Contrast enhanced CT (Siemens 64 slice, protocol 120kVp, 75 ml ultravist i.v. contrast, venous phase) axial (2 mm) shows discrete peripheral enhancement, indicated by arrow.

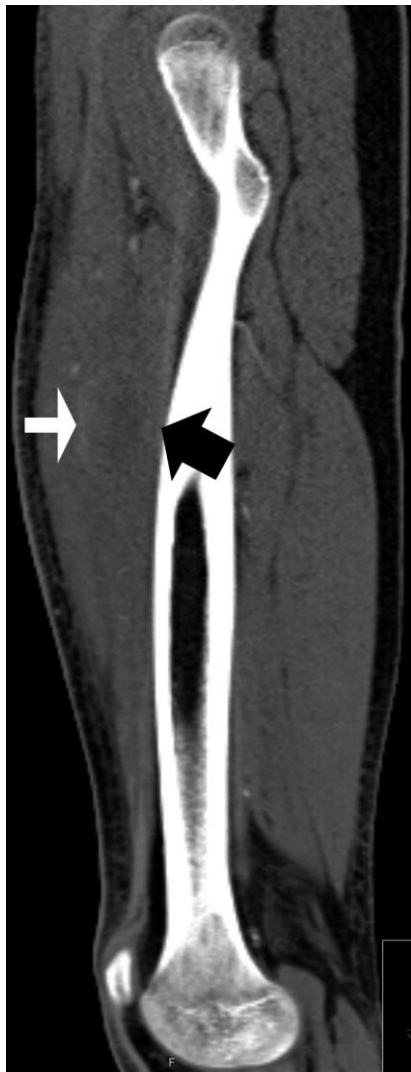

Figure 4 (left): Seventeen-year-old male with anaplastic large cell cutaneous lymphoma. Contrast enhanced CT (CECT) (Siemens 64 slice, protocol 120kVp, 75 ml ultravist i.v. contrast, venous phase, sagittal plane) shows an expansile soft tissue lesion between the medial and intermedius vastus muscles (white arrow) and no structural changes in the left femoral diaphysis (black arrow), suggesting the absence of bone involvement.

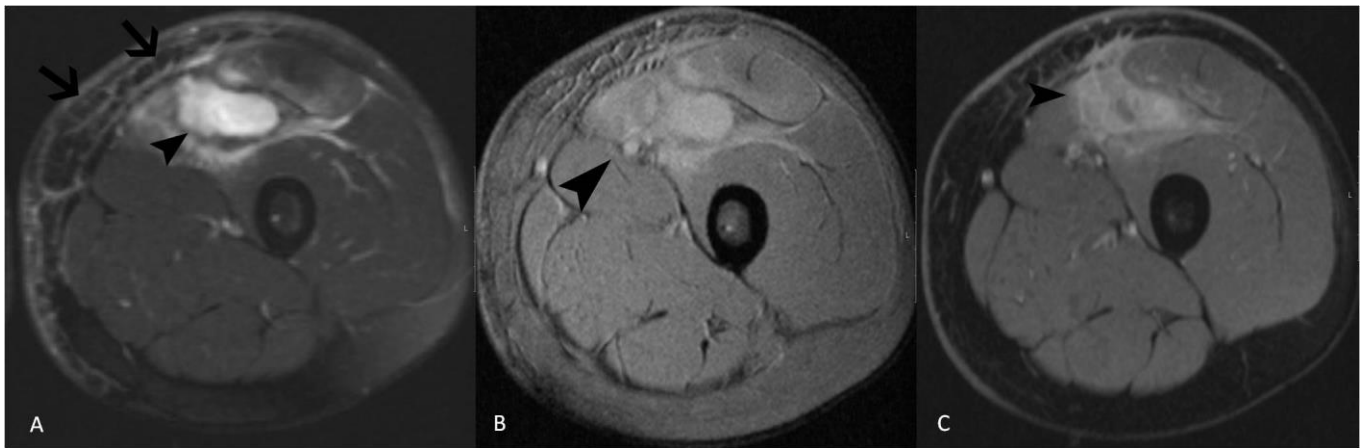


Figure 5: Seventeen-year-old male with anaplastic large cell cutaneous lymphoma. 1.5 Tesla Siemens magnetic resonance, fat saturated images. A) T2-weighted (TE80/TR5100). B) T1-weighted (TE15/TR755). C) T1-weighted image (TE9/TR340) after 7 ml gadolinium injection in venous phase. Images show a heterogeneous neoformation (arrow heads) between medial and intermedial vastus muscles measuring $6.5 \times 5 \times 3.5$ cm, with mild surrounding edema (black arrows). There was no gadolinium uptake inside the lesion, but some gadolinium uptake in surround tissue.

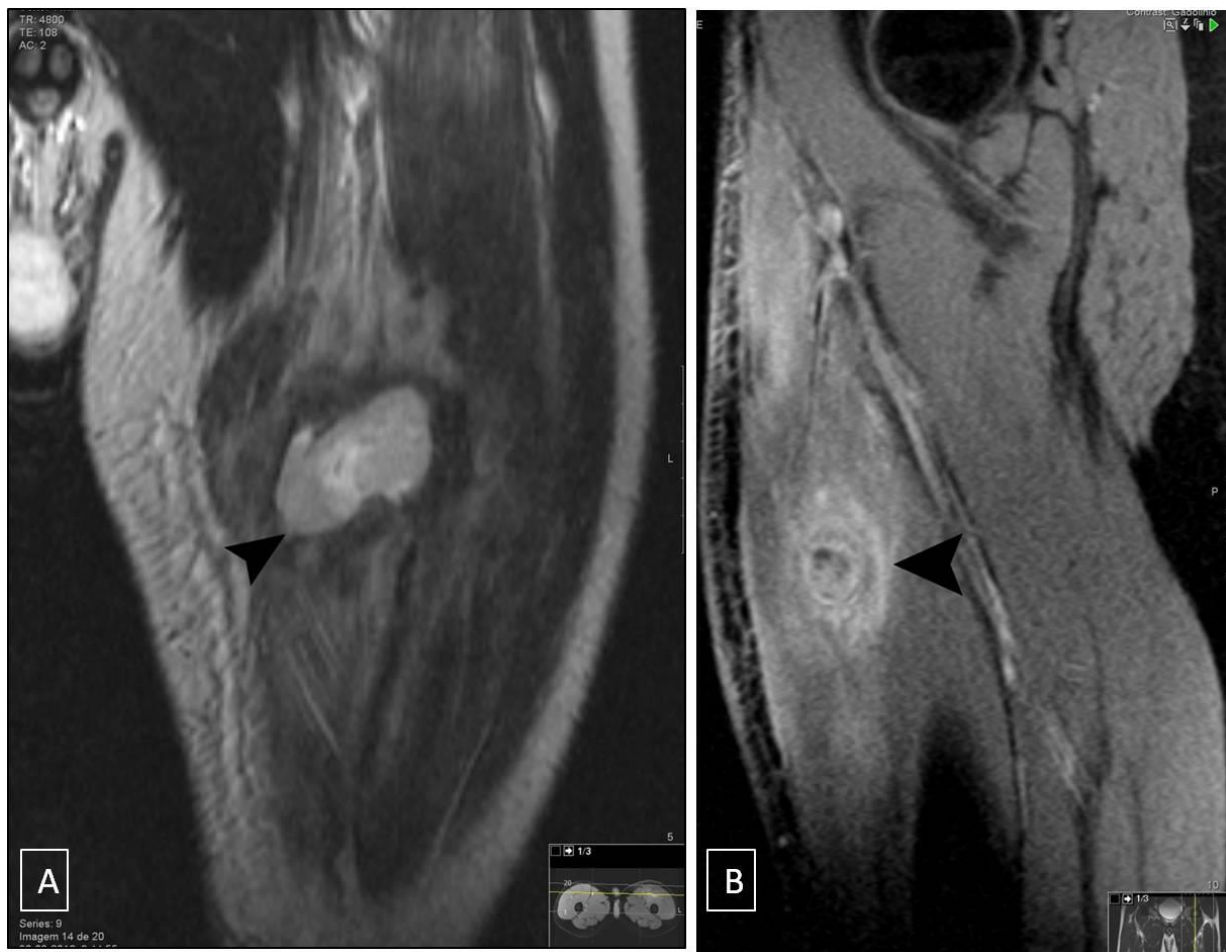


Figure 6: Seventeen-year-old male with anaplastic large cell cutaneous lymphoma. 1.5 Tesla Siemens magnetic resonance. A) T2-weighted image (TE108/TR4800). B) T1-weighted fat saturated image (TE9/TR340) after 7 ml gadolinium injection in venous phase. Images show a heterogeneous neoformation (arrow heads) between medial and intermedial vastus muscles measuring $6.5 \times 5 \times 3.5$ cm, with mild surrounding edema. There was no gadolinium uptake inside the lesion, and there was some gadolinium uptake in surrounding tissue.

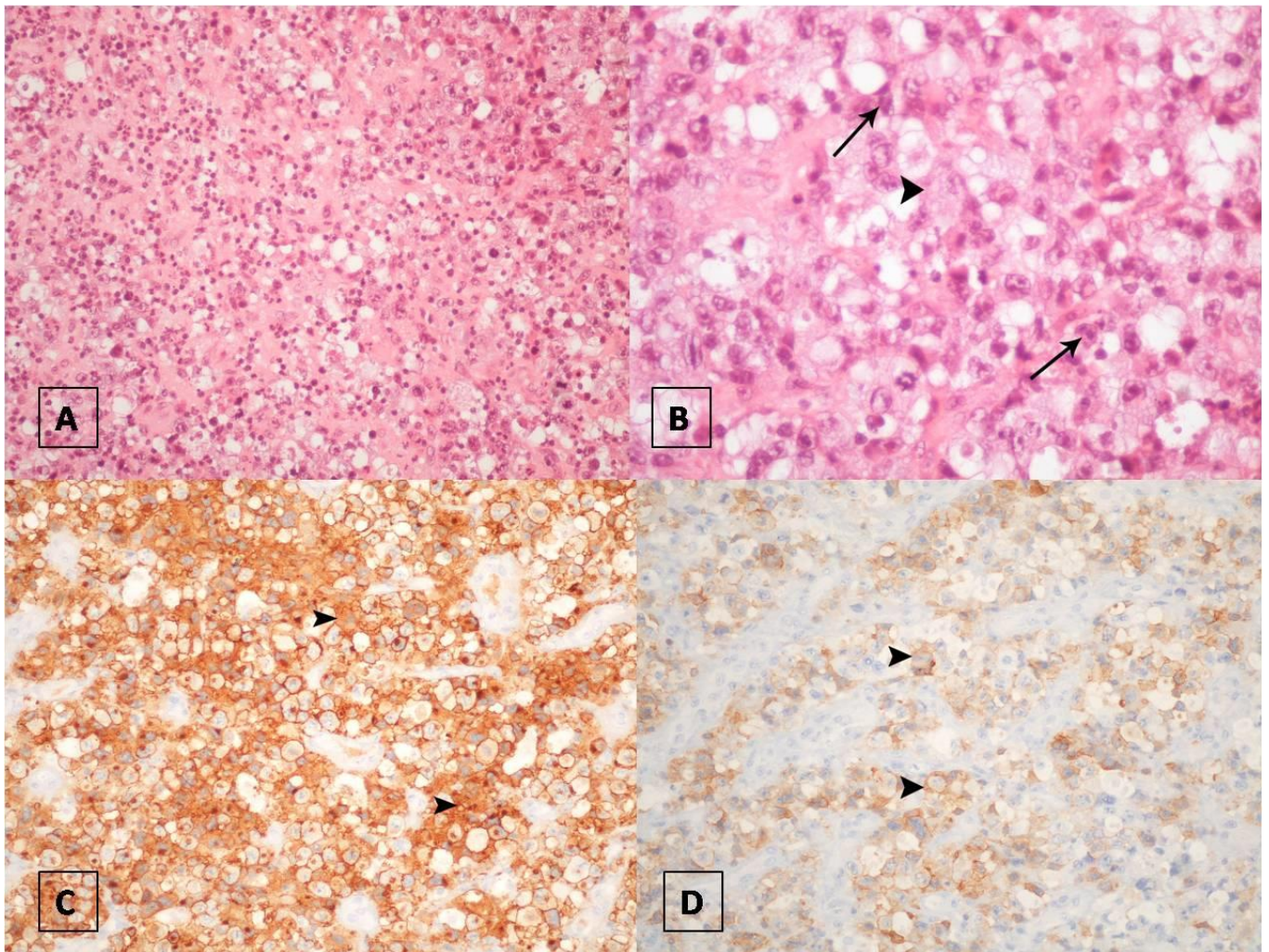


Figure 7: Seventeen-year-old male with anaplastic large cell cutaneous lymphoma. Histopathology. A) Hematoxylin and eosin staining 200x magnification. B) Hematoxylin and eosin staining, 400x magnification, shows a high cell density neoplasm, large core elements (arrow), pleomorphism and clear cytoplasm with poorly defined limits (arrow head). C) Immunohistochemical staining for CD30, 200x magnification. Neoplastic cells are strongly immunoreactive for CD30 (arrow head). D) Immunohistochemical staining for CD5, 200x magnification. Positive immunostaining for CD5, indicates T immunophenotype (arrow head).

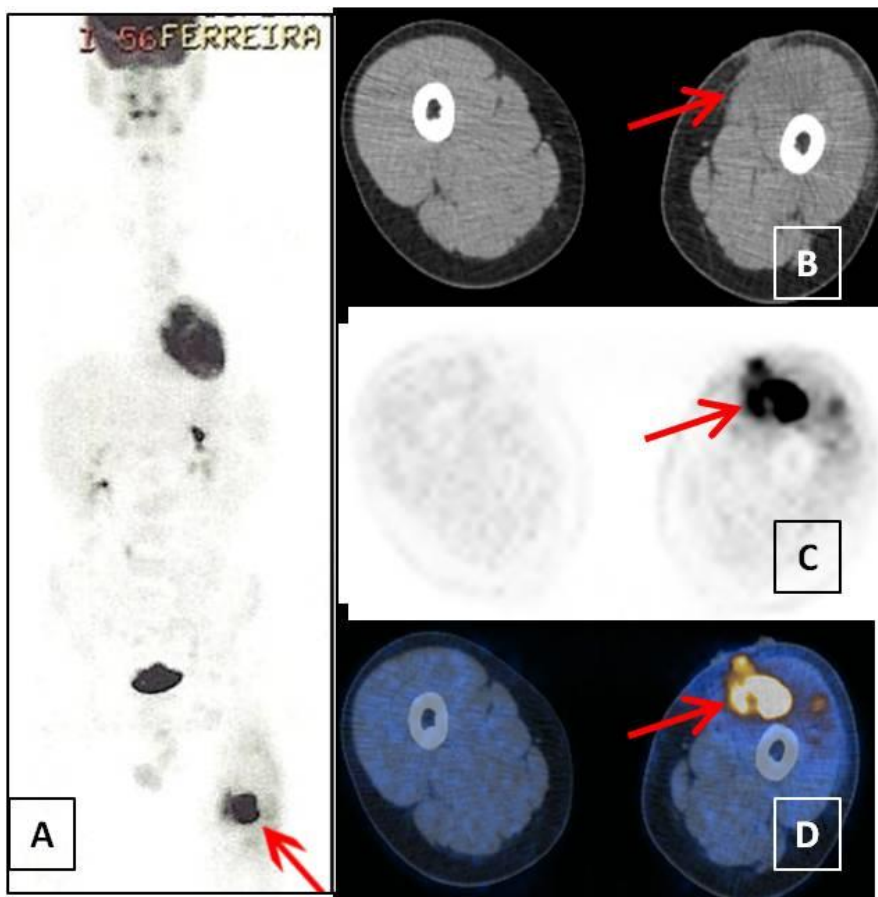


Figure 8: Seventeen-year-old male with anaplastic large cell cutaneous lymphoma. Positron Emission Tomography (PET), performed 60 minutes after administration of 7.8mCi of 18F-Fludeoxyglucose, demonstrates heterogeneous uptake in the anterior left thigh (arrow), meaning hypermetabolic involvement. No other anomalous uptake was found. A) Coronal PET image. B) Axial CT image. C) Axial PET image. D) Fused PET/CT image.

Etiology	Rare and high-grade non-Hodgkin lymphoma
Incidence	Comprises 1.7 % of T-Cell Lymphomas.
Clinical types	Subtype of anaplastic large cell lymphoma follows a less aggressive course than the systemic subtype. In approximately 10% of patients, primary cutaneous anaplastic large cell lymphoma extends beyond the skin to lymph nodes or organs. In such cases, it is usually managed similarly to systemic anaplastic large cell lymphoma.
Gender ratio	Male to female ratio is 1.5–2.0:1.
Age predilection	<ul style="list-style-type: none"> • Anaplastic lymphoma kinase-positive subtype usually affects children and young adults. • Anaplastic lymphoma kinase-negative subtype is more frequent in patients over age 60.
Treatment	<ul style="list-style-type: none"> • Subtype confined to the skin: surgery, radiation therapy. • Systemic subtype: chemotherapy.
Prognosis	Anaplastic lymphoma kinase status is an important prognostic indicator for the systemic form. Anaplastic lymphoma kinase-positive disease responds well to chemotherapy; most patients respond with long-term remission or cure. Anaplastic lymphoma kinase-negative anaplastic large cell lymphomas usually respond to chemotherapy, but many will relapse within five years. Because of this, they are sometimes treated more aggressively, often with stem cell transplant. Their 5-year survival rate is around 90%.
Imaging	<ul style="list-style-type: none"> • Ultrasound: homogeneous and hypoechoic expansile formation • Computed tomography: low attenuating neof ormation with surrounding edema • Magnetic resonance: high signal on T2-weighted imaging and low intensity signal on T1-weighted Imaging • Surrounding contrast uptake • Positron emission tomography: ¹⁸F-fluorodeoxyglucose uptake.

Table 1: Summary table for Anaplastic Large Cell Cutaneous Lymphoma.

	Lymphoproliferative disorders (including Anaplastic Large Cell Cutaneous Lymphoma)	Rabdomyosarcoma	Metastasis	Phlegmonous tissue	Abscess
History/Clinical Features	Single or localized cluster of erythematous skin nodules	Children	Patients with a primary neoplastic pathology.	Walled-off inflammatory mass Local inflammatory process (redness, swelling, pain) Fever	Local inflammatory process (redness, swelling, pain) Fever
Ultrasound	Solid expansile mass, scarce internal vascularization.	Heterogeneous variable Nonspecific texture and bizarre vessels.	Heterogeneous variablen nonspecific texture.	Hypoechoic heterogeneous mass, without internal positive Doppler, but high external vascularization.	Fluid collection, well circumscribed, may contain “solid” echoes, and high external vascularization.
CT	Heterogeneous neof ormation with mild attenuation. Edema in surrounding tissue may be present.	Heterogeneous mass with low to mild attenuation.	Heterogeneous mass with low attenuation.	Soft tissue, attenuating.	Fluid attenuation. Necrosis and gas centrally. Edema in surrounding tissue is usually present.
MRI	Heterogeneous neof ormation. Edema in surrounding tissue may be present. T1 – Hypointense T2 - Hyperintense	T1 - Hypointense T2 - Hyperintense	Usually : T1 - Hypointense T2 - Hyperintense	T1 - Hypointense T2 - Hyperintense	Heterogeneous neof ormation. Edema in surrounding tissue is usually present. T1 – Hypointense T2 - Hyperintense
Contrast Enhancement	Depends on type of lymphoproliferative disorder. Contrast uptake is often avid.	Heterogeneous enhancement.	Image depends on type of primary tumor. Usually there is contrast uptake.	Rim enhancement.	Rim enhancement. No contrast uptake inside an abscess.
PET	Usually ¹⁸ F-FDG uptake.	Usually ¹⁸ F-FDG uptake.	Usually there are multiple locations of ¹⁸ F-FDG uptake.	Typically avid ¹⁸ F-FDG uptake.	Typically avid ¹⁸ F-FDG uptake.

Table 2: Differential Diagnosis table for expansile soft tissue lesion in an adolescent.
¹⁸F-FDG = ¹⁸F-Fluorodeoxyglucose

ABBREVIATIONS

- 18F-FDG = 18F-Fluorodeoxyglucose
- ALCL = Anaplastic Large Cell Lymphoma
- ALK = Anaplastic Lymphoma Kinase
- BFM = Berlin-Frankfurt-Münster
- C-ALCL = Anaplastic Large Cell Cutaneous Lymphoma
- CT = Computed Tomography
- EMA = Antiendomysial Antinbodies
- MIP = Maximum Intensity Projection
- MR = Magnetic Resonance
- NHL = Non-Hodgkin Lymphoma
- PET = Positron Emission Tomography
- T1WI = T1 weighted imaging
- T2WI = T2 weighted imaging

KEYWORDS

Anaplastic Lymphoma; Ultrasound; Computed Tomography; Magnetic Resonance; Positron Emission Tomography

Online access

This publication is online available at:
www.radiologycases.com/index.php/radiologycases/article/view/1934

Peer discussion

Discuss this manuscript in our protected discussion forum at:
www.radiopolis.com/forums/JRCR

Interactivity

This publication is available as an interactive article with scroll, window/level, magnify and more features.
Available online at www.RadiologyCases.com

Published by EduRad



www.EduRad.org