

# Tracheal agenesis - a report of two cases

Jörg Daniel Geisler<sup>1\*</sup>, Bjarne Smevik<sup>1</sup>

*1. Division of Medical Imaging and Intervention, Oslo University Hospital, Oslo, Norway*

\* **Correspondence:** Dr. Jörg Daniel Geisler, Section of Pediatric Radiology, Division of Medical Imaging and Intervention, Oslo University hospital, Rikshospitalet, Oslo, Norway (✉ [Jorg.Geisler@Rikshospitalet.no](mailto:Jorg.Geisler@Rikshospitalet.no))

Radiology Case. 2009 Jul; 3(7):11-16 :: DOI: 10.3941/jrcr.v3i7.172

## ABSTRACT

Tracheal agenesis is a rare and in most cases lethal anomaly. It may be suspected because of lack of audible crying, and is often diagnosed right after birth with water soluble contrast medium injected into the oesophagus. We report two cases which were identified at our institution in the last 10 years. Imaging studies and medical records were reviewed in both cases. Patient number one was studied with a single slice computed tomography, patient number two with multislice detector computed tomography (MDCT) with 64 rows. The advantage of MDCT in demonstrating the rare condition of tracheal agenesis and with the same examination showing other coexisting anomalies is discussed. Conclusion: MDCT with 64 rows is an excellent diagnostic tool in diagnosing tracheal agenesis and showing other coexisting anomalies at the same time.

## CASE REPORT

### CASE REPORT

#### Case 1:

Our first patient was a female who was born prematurely at 28 weeks of gestation (GA), birth weight 1200g. The APGAR score was 3/5, and there was severe respiratory distress and bradycardia. An obstruction below the larynx prevented rapid intubation. After several attempts the patient got an emergency tracheostomy with a veneflon, which was replaced after several hours by a thin tracheostomy tube. A chest radiograph from the day of birth reports a tube position approximately 1 cm cranial to the carina and generally opaque lungs. An ultrasonographic study (US) of the neck about three days after birth showed no air filled structure at the place of the trachea. A cardiologist found a holosystolic murmur, compatible with an open ductus arteriosus. No other anomalies were reported. An oesophagus contrast study was undertaken four days after birth because of the ultrasonographic findings. This study demonstrated a tracheo-oesophageal fistula (Fig. 1)

A CT of the neck confirmed the US and x-ray findings with a tracheal agenesis and a tracheo-oesophageal fistula. Laryngoscopy showed edema in the larynx area and a blind-ending laryngeal pouch. The infant remained on ventilator support for 6 days until she died.

#### Case 2:

The second patient was a premature boy, with a GA of 32 weeks + 2 days, weighing 1540 g. Ultrasonography before birth had revealed polyhydramnion, a severe heart defect and possible anomalies of the intestine. APGAR score was 4-7-8 mostly because of bradycardia and no spontaneous respiration. After nasal intubation, the patient still had low oxygenation values, but the heart rhythm was more stable. Clinically no other anomalies were seen than an anal atresia. The first chest and abdominal x-ray from the day of birth (Fig 2) reports an intact carina with a tube position at the level of the fourth thoracic vertebra, just above the carina, and generally reduced

air content in both lungs. Later the same day the chest x-ray (Fig 3) showed more air in the ventricle and the possibility of a tracheo-oesophageal fistula was discussed.

Echocardiography confirmed severe heart anomalies, and ultrasonography of the abdomen revealed a bilateral hydronephrosis without other pathology.

On day two of life, the patient was transferred to our institution. The same day a sigmoidostomy was performed because of increasing symptoms of ileus. After surgery the chest radiograph showed normal lungs with correct position of the tube (Fig. 4).

Two days later there was increased respiratory distress with low blood oxygenation, and new infiltrates were seen on the chest x-ray around both hili and in the periphery of the left lung. An oesophagogram on the same day demonstrated a tracheo-oesophageal fistula to the carina (Fig. 5). Because of the multiple anomalies, a 64 row MDCT scan of the thorax was performed, clearly depicting the heart anomalies and the fistula to the trachea. MDCT also revealed the tracheal agenesis (Fig. 6). On the basis of these findings the intensive care was stopped, the patient was extubated and died one hour later.

## DISCUSSION

In 1900 Payne (1) described the first case of tracheal agenesis. Since this time, more than 150 cases of tracheal agenesis have been published in the literature. Floyd et al (2) described three different anatomic patterns of tracheal agenesis (Fig 7) Type 2 is the most common with a complete agenesis of the trachea with a fistula between the oesophagus and carina from which the right and left main bronchi originate. This type represents over 60% of cases.

It is in most cases a lethal anomaly. In over 90% of cases it is combined with other congenital anomalies. Most common are cardiovascular and gastrointestinal anomalies. The incidence is approximately 1:50 000 with a male/female ratio of 2:1 (3-5).

Usually it is diagnosed immediately after birth. The diagnosis is based on clinical signs as cyanosis, severe respiratory distress, absence of audible crying and difficult/impossible intubation.

Until a few years ago an examination with water soluble contrast medium injected in the oesophagus was the main radiological examination to confirm the tracheal agenesis. In the last few years there are some reports about the advantage of CT, especially MDCT, in these patients (6-8).

Usually, the tracheal agenesis is associated with a fistula from the oesophagus to the trachea, enabling air exchange. Even if there are some reports about a few long term survivors (9-12), most of the children cannot be treated because of the complex nature of the other anomalies. Most of the patients die right after birth within a few hours.

We have identified two cases at our institution during the last 10 years. One was suspected of having a stenosis in the proximal trachea because initial intubation did not succeed. The second patient was diagnosed with 64 slice MDCT.

In 1998 we diagnosed the tracheal agenesis with the oesophagus contrast examination and a single slice CT study. We believe this patient had a Floyd type II anomaly without a trachea, a normal carina with normal bronchial tree and a direct fistula from the oesophagus to the carina.

A contrast examination of the oesophagus on the patient from 2006 was misinterpreted as a much more common fistula from the oesophagus to the trachea. When we reviewed the oesophagus contrast study after the diagnosis was made by MDCT, tracheal agenesis as a potential differential diagnosis should have been included. The MDCT showed that this patient also had a Floyd type II anomaly.

A MDCT study should be considered the first choice of examination in a patient with clinical signs of this condition. The patient will tolerate the study better than contrast study of the oesophagus, and additional pathology in neighbouring organs will be better appreciated. This is especially true with the newest generation of MDCT who can perform an examination within 2-3 seconds with a higher spatial resolution than the first and second generation MDCT with 4-8 rows. Maybe MRI in the near future will have a good enough spatial resolution to give us the same information as the MDCT does now. This will be even more important when we can offer these children a therapy.

It is important to make a rapid diagnosis of tracheal agenesis since there is no potential treatment at the present time, especially in those with multiple other anomalies.

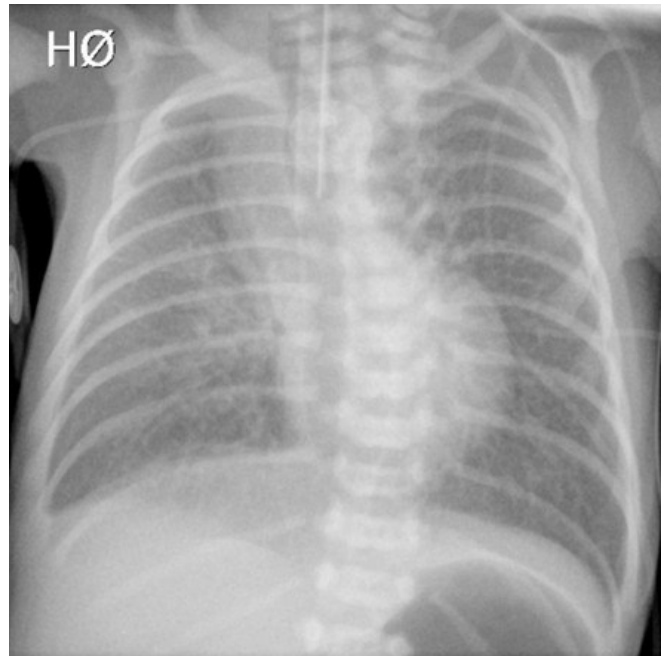
## TEACHING POINT

MDCT should be the examination of choice in patients with possible tracheal agenesis. It is a fast examination which demonstrates both the tracheal agenesis and eventually other combined anomalies in critically ill patients.

## REFERENCES

1. Payne WA. Congenital absence of the trachea. *Brooklyn Med J*. 1900; 14:568
2. Floyd J, Campbell DC, Dominy DE. Agenesis of the trachea. *Am Rev Respir Dis*. 1962; 86: 557-60
3. van Veenendaal MB, Liem KD, Marres HA. Congenital absence of the trachea. *Eur J Pediatr*. 2000; 159 (1-2):8-13.
4. Evans JA, Greenberg CR, Erdile L Tracheal agenesis revisited: analysis of associated anomalies. *Am J Med Genet*. 1999; 82: 415-22.
5. Milstein JM, Lau M, Bickers RG Tracheal agenesis in infants with VATER association. *Am J Dis Child*. 1985; 139(1):77-80.

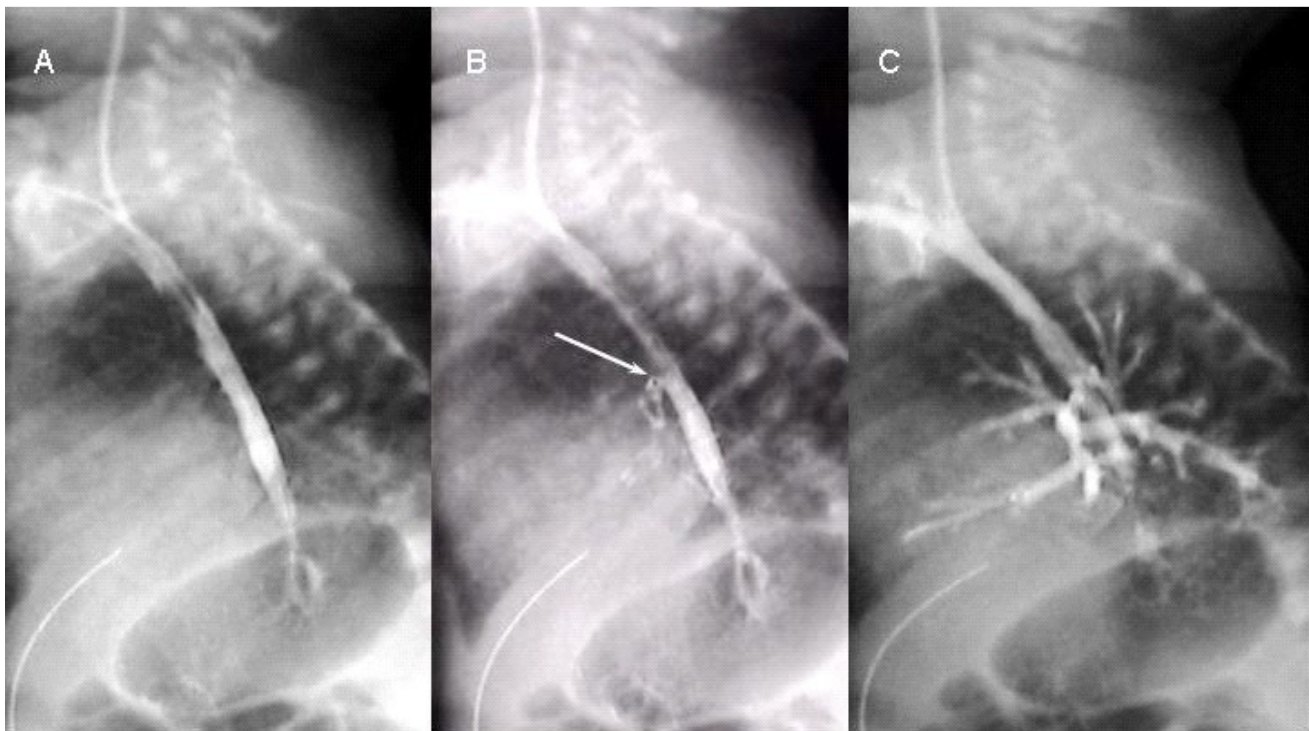
6. Pumberger W, Metz V, Birnbacher R, Hörmann M Tracheal agenesis: evaluation by helical computed tomography. *Pediatr Radiol.* 2000; 30; 200-3
7. Chaumofre K, Vialet R, Merrot T, Amous Z, Panuel M (Tracheal agenesis: CT diagnosis) *J Radiol.* 2004; 85(7-8):1064-66.
8. Strouse PJ, Newman B, Hernandez RJ, Afshani E, Bommaraju M?? CT of tracheal agenesis. *Pediatr Radiol.* 2006; 36: 920-6
9. Baroncini-Cornea S, Fae M, Gargiulo G, Gentili A, Lima M, Pigna A, Pilu S, Tancredi S, Turci G Case report: Tracheal agenesis: management of the first 10 months of life. *Ped Anest.* 2004; 14: 774-7
10. Hill SA, Milam M, Manaligod JM Tracheal agenesis: diagnosis and management. *Int J Pediatr Otorhinolaryngol.* 2001; 59(1): 63-8
11. Soh H, Kawahawa H, Imura K, et alt. Tracheal agenesis in a child who survived for 6 years. *J Pediatr Surg.* 1999; 34(10): 1541-3
12. Das BB, Nagaraj A, Rao AH, Rajegowda BK Tracheal Agenesis: Report of Three Cases and Review of the Literature. *Am J Perinatol.* 2002; 19(7):395-400.

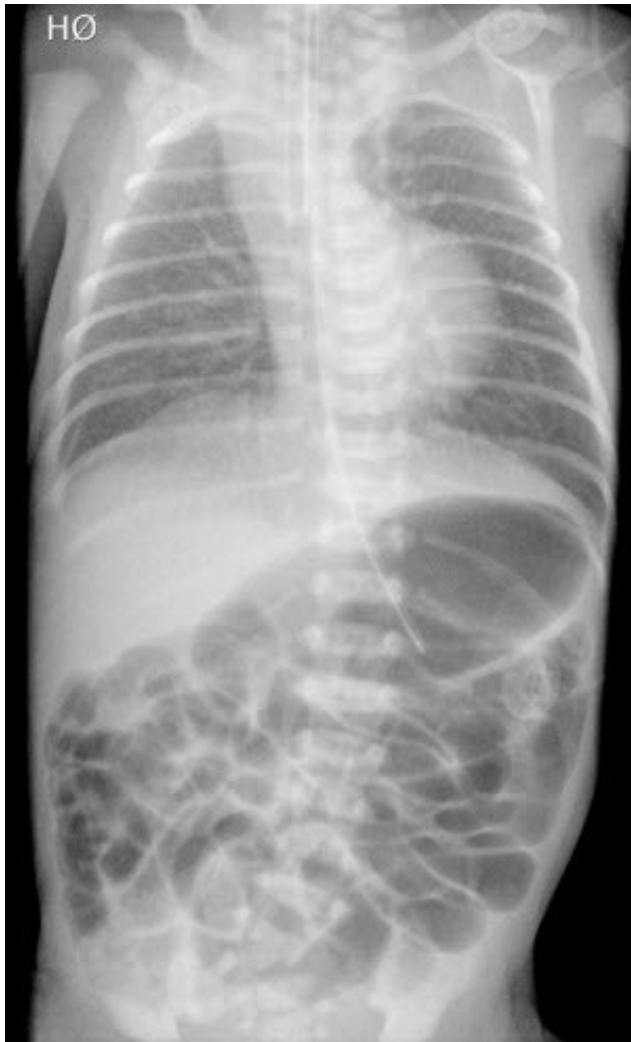


**Figure 2:** Tracheal agenesis. Boy on his first day of life. Conventional x-ray front of the chest. He is intubated with the tracheal tube in the level of fourth thoracic vertebra. The lungs have reduced air content.

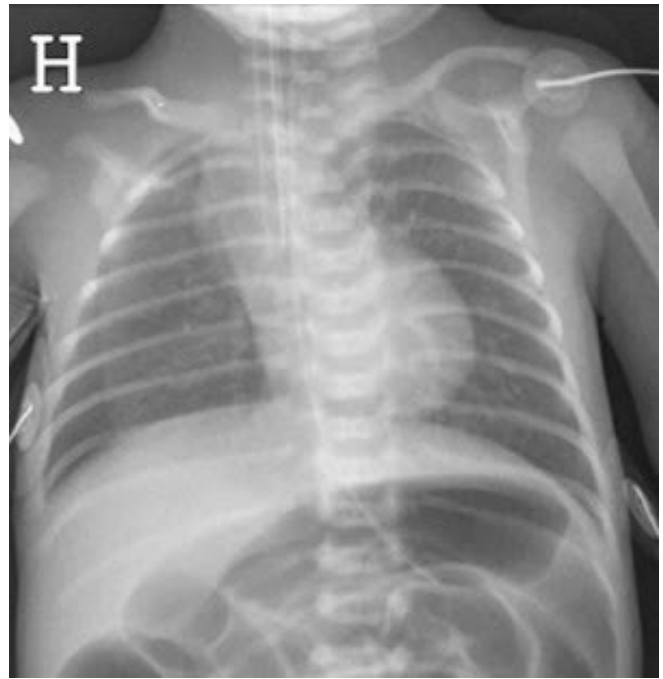
FIGURES

**Figure 1 (bottom):** Tracheal agenesis. 4 days old girl. Study of the oesophagus. The sequence shows filling of a fistula (arrow) from the oesophagus to the trachea (B) and gradual filling of a almost normal bronchial tree (C).



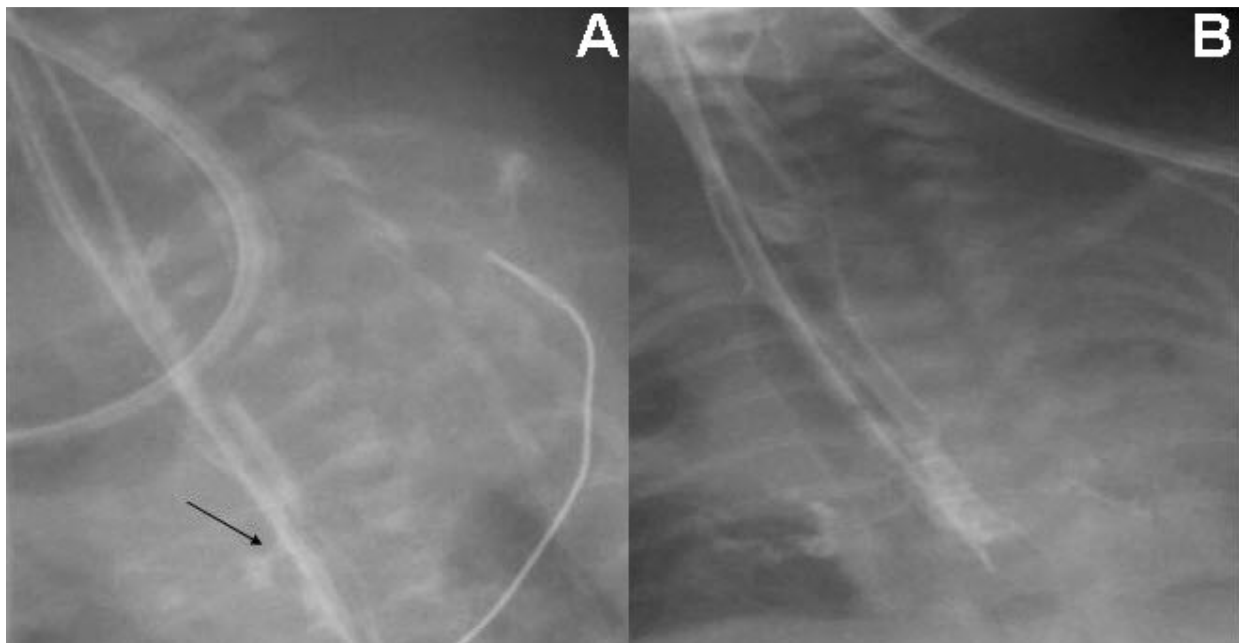


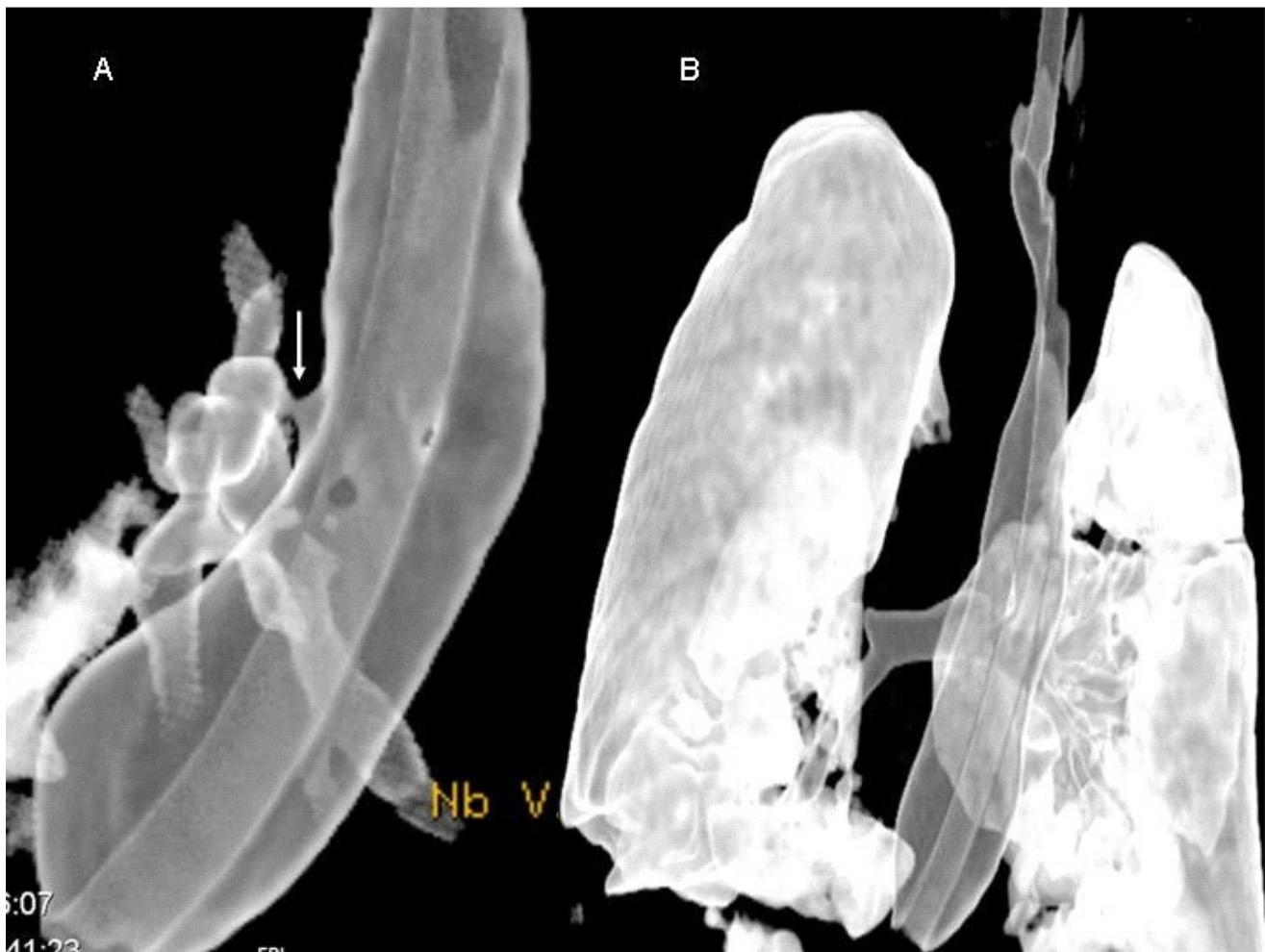
**Figure 3:** Tracheal agenesis. Boy on his first day of life, second picture. X-ray of the thorax and abdomen. Unchanged position of the tracheal tube. Inserted gastric tube in good position, but this does not prevent air filling the stomach and small intestine.



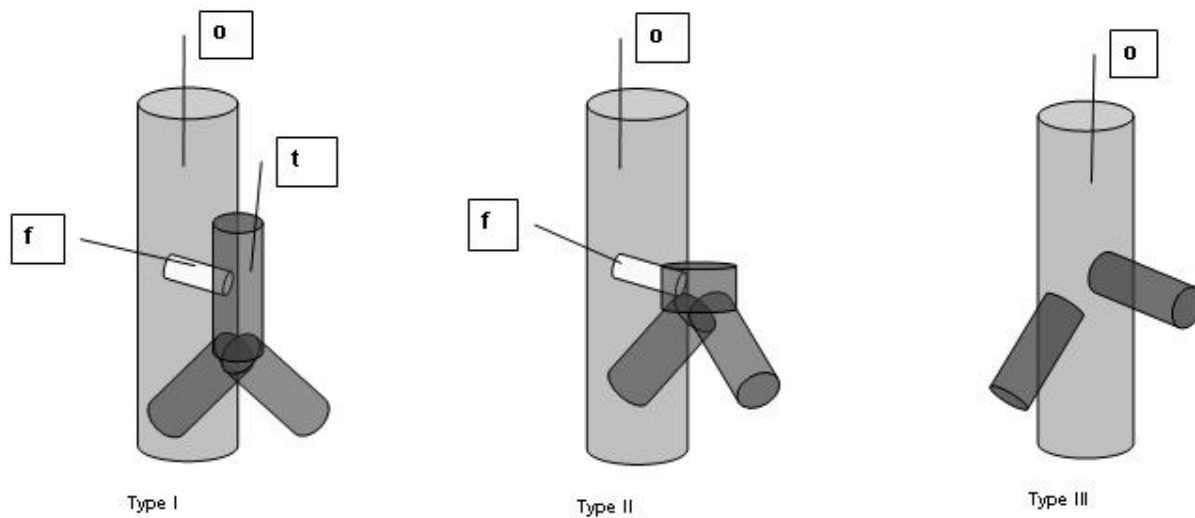
**Figure 4:** Tracheal agenesis. Boy 2 days old. Chest x-ray shows quite good air content in both lungs, but with a small atelectasis on the left side. Tracheal tube with the tip at the level of the carina.

**Figure 5 (bottom):** Tracheal agenesis. Boy on the 4th day of life. Contrast study of the oesophagus. In (A) the contrast medium fills the fistula (arrow) to the carina (B) shows filling of the bronchi.





**Figure 6:** Tracheal agenesis. Boy on his 4th day of life. MDCT scan of the chest, 3D reconstruction, with air algorithm. (A) demonstrates the tracheo-oesophageal fistula (arrow). The 3D reconstruction in (B) demonstrates the normal anatomy in the periphery of the lungs.



**Figure 7:** Floyd's classification of tracheal agenesis. Type I has an atresia of part of the trachea (t), a remaining short trachea and normal bronchi. A tracheo-oesophageal fistula (f) is present. Type II has a complete atresia of the trachea but normal bifurcation and bronchi. There may, or may not be a tracheo-oesophageal communication. Type III has a complete agenesis of the trachea. The bronchi arise directly from the oesophagus (o).

ABBREVIATIONS

MDCT = multislice detector computed tomography  
GA = gestational age  
US = ultrasonographic study

KEYWORDS

Tracheal agenesis, MDCT, Trachea, Anomaly, Newborn

**Online access**

This publication is online available at:  
[www.radiologycases.com/index.php/radiologycases/article/view/172](http://www.radiologycases.com/index.php/radiologycases/article/view/172)

**Interactivity**

This publication is available as an interactive article with  
scroll, window/level, magnify and more features.  
Available online at [www.RadiologyCases.com](http://www.RadiologyCases.com)

Published by EduRad



[www.EduRad.org](http://www.EduRad.org)