

Cardiac metastases of melanoma as first manifestation of the disease

Adriana Villa^{1*}, Esmeralda Eshja¹, Silvia Dallavalle², Emilio Maria Bassi¹, Annalisa Turco³

1. Department of Radiology, IRCCS S. Matteo, Pavia, Italy

2. Department of Radiology, Broni and Stradella hospital, Pavia, Italy

3. Department of Cardiology, IRCCS S. Matteo, Pavia, Italy

* **Correspondence:** Dr. Adriana Villa, MD, Flat 5, Tachbrook court, Tachbrook street, Sw1v 2jt, London
(✉ adriana.d.m.villa@gmail.com)

Radiology Case. 2014 Apr; 8(4):8-15 :: DOI: 10.3941/jrcr.v8i4.1700

ABSTRACT

Cardiac metastases are rare, but more common than primary cardiac tumours, and metastatic melanoma involves heart or pericardium in greater than 50% of the cases, although cardiac metastasis are rarely diagnosed ante mortem because of the lack of symptoms. A multimodality approach may help to obtain a more timely diagnosis and in some cases a quicker and better diagnosis can enable a surgical resection to prevent cardiac failure or to reduce the tumour before chemotherapy. We present a case of a patient with cardiac metastasis as first evidence of a malignant melanoma: in this case the patient underwent echocardiography, cardiac magnetic resonance and computed tomography. This case underlines the importance of advanced diagnostic techniques, such as cardiac magnetic resonance, not only for the detection of cardiac masses, but also for a better anatomic definition and tissue characterization, to enable a quick and accurate diagnosis which can be followed by appropriate treatment.

CASE REPORT

CASE REPORT

A 61-year-old Caucasian male was admitted to the emergency room of our hospital with shortness of breath and fainting, without chest pain; he did not report any other symptoms. The patient had no relevant past medical history; in particular, no previous cardiac diseases were reported. The physical examination was normal. However, a cutaneous lesion was found in sacral region where some years before a nevus had been resected with a histologic diagnosis of blue nevus without any evidence of mitotic activities or necrotic phenomena.

Imaging findings

Chest X-ray and laboratory tests were normal.

The first electrocardiogram (ECG) showed atrial flutter 2:1. Figure 1 is a following ECG, when the patient was in

sinus rhythm, which showed diffused alteration of ventricular repolarization: cardiac hypertrophy and left ventricular (LV) overload were suspected.

Transthoracic and transesophageal echocardiography revealed a normal LV function with what appeared to be a concentric biventricular hypertrophy; interatrial and interventricular septum showed increased thickness and echogenicity and these findings were at first related to hypertrophy. Moreover the echo pointed out the presence of an irregular mass occupying the right atrium (RA), near the superior vena cava (SVC) (fig. 2).

The patient was referred for cardiac magnetic resonance (CMR) in order to assess the suspected myocardial hypertrophy and to characterize the atrial mass. An ECG-gated CMR was performed.

Steady state free precession (SSFP) cine vertical long axis and horizontal short axis demonstrated normal left ventricular contractility. All myocardial walls had an irregular, heterogeneous, thickened appearance, excepted for free left atrium wall; in particular lateral wall, free right ventricular wall and distal interventricular and interatrial septum, were involved by nodular deposits in the myocardial muscle layers with variable penetration into the endocardium and epicardium (fig. 3). The atrial polypoid mass was located in the posterior wall of right atrium, near SVC. The cardiac valves appeared normal. The intramyocardial and right atrial masses showed different intensity, but most of them were hyperintense on both T1 and T2 weighted (T1w and T2w) images (fig. 4). On the late gadolinium enhancement (LGE) sequences, the masses showed a significant contrast uptake (fig. 5). There was a small pericardial effusion, but pericardial layers were disease-free.

In conclusion, the CMR demonstrated the presence of masses in the interatrial septum and in the right atrium and solid tissue infiltrating the ventricular myocardium bilaterally: this tissue showed MRI characteristics of mixed structure.

The multifocal localization correlates more likely with metastases than primary tumour and the myocardial infiltration suggests haematogenous diffusion, so the most likely diagnosis was cardiac metastases or sarcoma.

To study in deep the case and for a likely staging of cancer, a total body computed tomography (CT) was performed. CT confirmed the polymorphism of cardiac masses, both infiltrating and vegetating (fig. 6) and demonstrated cerebral, hepatic and adrenal glands metastases (fig. 7).

Management and follow-up

Biopsy of the hepatic lesion confirmed it was a metastatic lesion and the histologic examination of the sacral skin lesion diagnosed a rare melanoma variant, malignant blue nevus. The patient started chemotherapy treatment, but unfortunately died around 1 year after the diagnosis.

DISCUSSION

Aetiology and demographics

Melanoma is a common neoplasm with a propensity to metastasize to the heart. Metastases of the cardiac structures are rare, but 20 to 40 times more common than primary cardiac tumours.

Clinical and imaging findings

Cardiac metastases are typically multifocal and may involve any portion of the heart (epicardium, myocardium and/or pericardium). Tumour cells may reach and involve heart and pericardium by four different pathways:

1. Haematogenous spread (most of the cases of melanoma) [1].
2. Retrograde lymphatic extension (in particular lymphoma).
3. Direct extension (breast and lung cancer).
4. Transvenous extension (renal cell cancer) [2, 3].

Melanoma cells usually spread by the haematogenous pathway and infiltrate myocardium and epicardium through the coronary arteries or, less frequently, through the vena cava leading to a multifocal distribution, as in our case report. Valves and endocardium involvement is uncommon, while the right atrium is the most common site [4]. Cardiac metastases are often associated with haematogenous metastases to other organs, as in our case.

Metastatic melanoma involves heart or pericardium in greater than 50% of the cases, although cardiac metastasis are rarely diagnosed ante mortem [5]. Metastatic cardiac melanoma is often clinically silent and signs and symptoms are typically non-specific: dyspnoea, pedal oedema, cough, tachycardia, dysrhythmia and chest pain [6]. Because of the lack of symptoms in most of the cases cardiac metastasis are diagnosed post mortem, but a multimodality approach may help to obtain a more timely diagnosis. In rare cases cardiac metastasis can be the first manifestation of a tumour of unknown primary origin [2].

The first approach is often echocardiography, but the evaluation of the right ventricle and right atrial appendage can be limited. CT and CMR may highlight some important imaging findings.

CT is generally used for total body staging, but some findings can lead to the diagnosis of metastatic melanoma (for example, a haemorrhagic pericardial effusion). Nowadays, ECG-gated cardiac computed tomography angiography (CCTA) could be a valid diagnostic method due a spatial resolution higher than CMR; moreover, the high-resolution three-dimensional images can be produced with a low dose of ionizing radiation.

CMR has some important advantages: the lack of ionizing radiation, which is a substantial difference with CT, and a better contrast resolution that allows a more accurate tissue characterization of the aetiology of cardiac and pericardial masses. Indeed, T1w and T2w sequences and LGE sequences enables a better anatomic definition and tissue characterization, whilst cine gradient echo sequences assess the functional impact. Melanin is a natural paramagnetic substance and causes T1 shortening, so we expect melanoma to be T1 hyperintense and T2 hypointense, but only a small percentage of melanoma metastasis have the classic findings: for example, amelanotic melanoma may be T1 iso- or hypo-intense. Usually the melanoma metastases show a diffuse and avid gadolinium enhancement.

Fluorine-18-fluorodeoxyglucose positron emission tomography (FDG-PET) can be helpful for body staging of melanoma because the metastases are usually FDG avid and SUV (standardized uptake value) can be an important tool to differentiate the normal cardiac uptake and any abnormalities.

Positron emission tomography-computed tomography (PET/CT) is a combined method that could be useful for the diagnosis, staging and follow up of patient with metastatic melanoma, thanks to its high sensitivity and specificity: in particular, this imaging method could be able to highlight a

biologic alteration before any anatomic alteration could be seen, which is relevant for the treatment of these patients.

Treatment and prognosis

Cardiac metastases from malignant melanoma usually occurs in the setting of disseminated disease and are often identified during post mortem examination because they usually occur without clinical manifestations [7], so it is quite uncommon to have ante mortem diagnosis, as in our case, and it is frequently related to symptomatic cardiac involvement, even when primary melanoma is not yet identified and there is no prior history of melanoma. Even if most of the patients are at an advanced disease stage at the time of the diagnosis of the cardiac metastasis, in some cases a quicker and better diagnosis can enable a surgical resection to prevent cardiac failure or to reduce the tumour before chemotherapy.

Differential diagnoses

Cardiac metastases are generally hypointense on T1w images and hyperintense on T2w images, while melanoma metastases are generally hyperintense on T1w images due to their high melanin content, but only a small percentage of cases have the classic findings. In our case, most of the lesions were hyperintense on T1w images, although some of them have a very heterogeneous signal in T1w and T2w images.

In our case, the multifocal localization correlates more likely with metastases than primary tumour and the myocardial infiltration suggests haematogenous diffusion.

Finally, in the sequence after the intravenous administration of gadolinium contrast agent, the contrast agent uptake depends on the vascularization of the primary tumour: melanoma is a hyper-vascularized tumour, so we expect to see considerable contrast enhancement in the metastases and this is what we found in our case.

TEACHING POINT

Advanced diagnostic techniques, such as cardiac magnetic resonance, are important for the detection of cardiac masses, but also for a better anatomic definition and tissue characterization, to enable a quick and accurate diagnosis which can be followed by appropriate treatment. Multifocal localization correlates more likely with metastases than primary tumour and the myocardial infiltration suggests haematogenous diffusion; melanoma metastases are generally hyperintense on T1w images, but frequently they have a very heterogeneous signal in T1w and T2w images and a considerable contrast enhancement.

REFERENCES

- Young JM, Goldman IR, Tumor metastasis to the heart. *Circulation* 1954; 9 (2): 220-9. PMID: 13127183.
- Savoia P, Fierro MT, Zaccagna A, Berengo MG, Metastatic melanoma of the heart, *J surg Oncol* 2000; 75 (3): 203-7. PMID: 11088053.
- Chiles C, Woodard PK, Gutierrez FR, Link KM, Metastatic involvement of the heart and pericardium: CT and MR imaging, *Radiographics* 2001; 21 (2): 439-449. PMID: 11259706.
- Wood A, Markovic SN, Best PJ, Erickson LA, Metastatic malignant melanoma manifesting as an intracardiac mass, *Cardiovasc Pathol* 2010; 19 (3): 153-7. PMID: 19211272.
- Grebenc ML, de Christenson R, Burke AP, Green CE, Galvin JR, Primary cardiac and pericardial neoplasms. Radiologic-pathologic correlation, *Radiographics* 2000; 20 (4):1073-103. PMID: 10903697.
- Gulati G, Sharma S, Kothari SS, Juneja R, Saxena A, Talwar KK, Comparison of echo and MRI in the imaging evaluation of intracardiac masses, *Cardiovasc intervent radiol*, 2004, 27 (50): 459-469. PMID: 15383848.
- Auer J, Schmid J, Berent R, Niedermair M, Cardiac metastasis of malignant melanoma mimicking acute coronary syndrome, *Eur Heart J*. 2012 Mar; 33(5): 676. PMID: 21846676.
- Sparrow P, Kurian J, Jones TR, Sivananthan MU, MR Imaging of cardiac tumors, *Radiographics* 2005; 25 (5): 1255-1276. PMID: 16160110.
- Tesolin M, Lapierre C, Oligny L, Bigras JL, Champagne M, Cardiac metastases from melanoma, *RadioGraphics* 2005; 25 (1): 249-253. PMID: 15653599.
- Luna A, Ribes R, Caro P, Vida J, Erasmus JJ, Evaluation of cardiac tumors with magnetic resonance imaging, *Eur Radiol* 2005, 15 (7): 1446-1455. PMID: 15627179.
- Allen BC, Mohammed TL, Tan CD, Miller DV, Williamson EE, Kirsch JS, Metastatic Melanoma to the Heart, *Curr Probl Diagn Radiol*, 2012; 41 (5): 159-164. PMID: 22818836.
- Glancy DL, Roberts WC, The heart in malignant melanoma. A study of 70 autopsy cases, *Am J Cardiol.*, 1968 Apr; 21(4): 555-71. PMID: 5650736.
- Grebenc ML, Rosado de Christenson ML, Burke A, Green CE, Galvin JR, Primary cardiac and pericardial neoplasms. Radiologic-pathologic correlation, *Radiographics* 2000; 20 (4): 1073-103. PMID: 10903697.
- Chiles C, Woodard PK, Gutierrez FR, Link KM, Metastatic Involvement of the Heart and Pericardium: CT and MR Imaging, *Radiographics* 2001; 21 (2): 439-449. PMID: 11259706.
- Fishman LK, Kublman JE, Schuchter LM, Miller III JA, Magici D, MD, CT of Malignant Melanoma in the Chest, Abdomen, and Musculoskeletal System, *Radlographics* 1990; 10 (4): 603-620. PMID: 2198632.

16. Sparrow PJ, Kurian JB, Jones TR, Sivananthan MU, MR
 Imaging of Cardiac Tumors, RadioGraphics 2005; 25 (5):
 1255-1276. PMID: 16160110.493

FIGURES

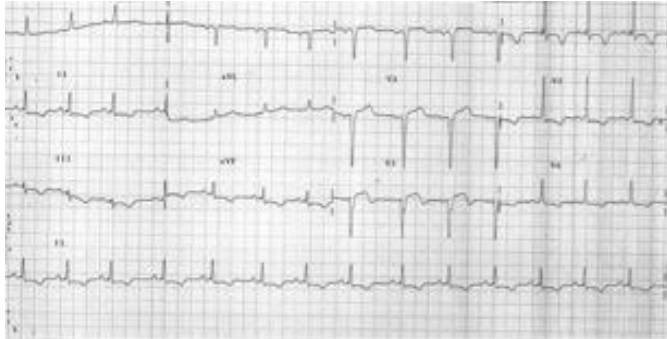


Figure 1 (left): 61-year-old male with cardiac metastases of melanoma. ECG shows Q waves in V1 to V3 and diffuse repolarization abnormalities.

Figure 2 (middle row): 61 year old male with cardiac metastases of melanoma. Echocardiography, transthoracic cardiac probe, 2-4 MHz, A: 4 chamber transthoracic view, B: parasternal long axis transthoracic view, C: transesophageal echocardiography. The exams show biventricular increased thickness and echogenicity and a rounded mass in the right atrium (arrows).

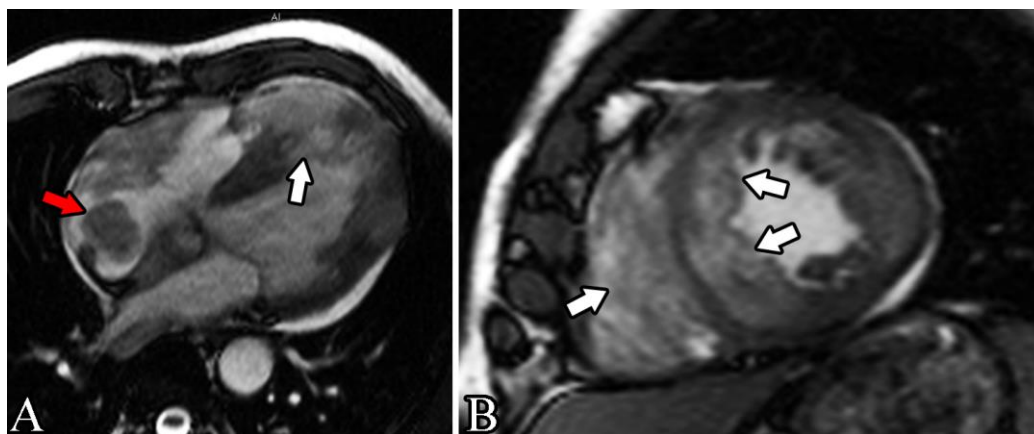
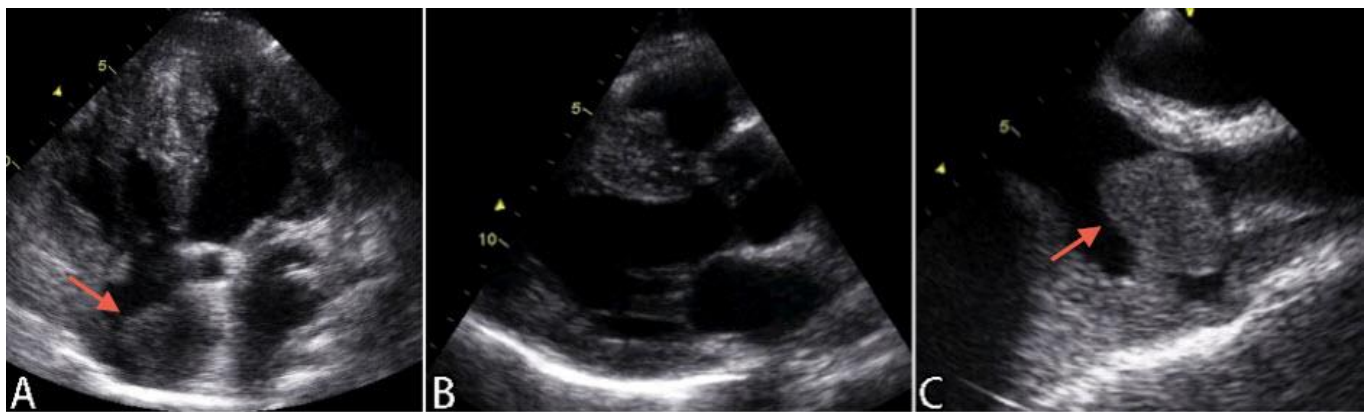

Figure 3: 61 year old male with cardiac metastases of melanoma. Findings: 4 chamber and short axis views cine images show irregular, heterogeneous and thickened appearance of the myocardial wall and several nodular deposits throughout the myocardium, with variable penetration: the biggest lesion has maximum diameters around 45x50 mm, infiltrates the interventricular septum and extends to the right cardiac apex (white arrows).

There is also an atrial polypoid mass in the right atrium (around 19x20 mm)(red arrow), near superior vena cava. The cardiac valves appeared normal.

Technique: cardiac magnetic resonance, 1.5 T MR System (Siemens, Symphony, Germany) with breath-holding technique. A: steady-state free-precession (SSFP) gradient echo (GE) cine image in 4 chamber view before the administration of contrast agent, TE 1.6 ms, TR 48.3 ms. B: steady-state free-precession (SSFP) gradient echo (GE) cine image in short axis view before the administration of contrast agent. TE 1.6 ms. TR 46.8 ms.

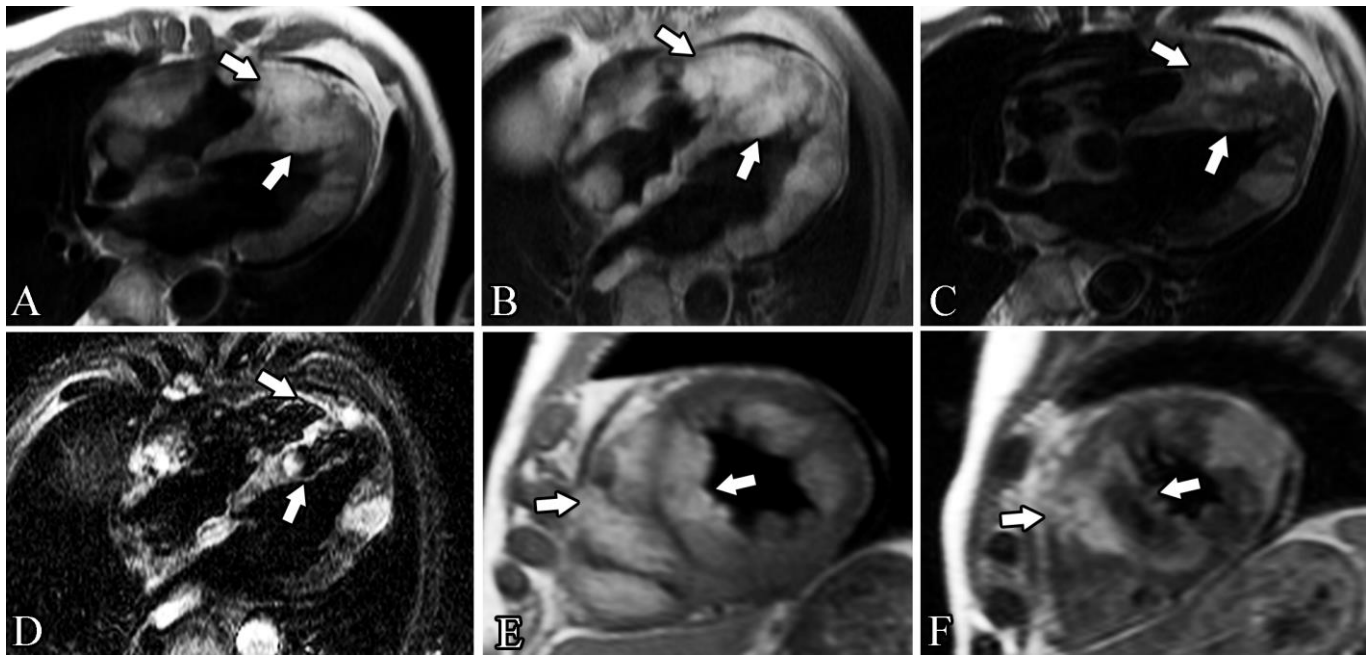


Figure 4: 61-year-old male with cardiac metastases of melanoma.

Findings: these various CMR sequences, before the administration of contrast agent, show several intramyocardial masses involving both ventricles and the right atrium and highlight the heterogeneous composition of the masses, even if most of them appear to be hyperintense on both T1 weighted and T2 weighted images. The biggest lesion has maximum diameters around 45x50 mm, infiltrates the interventricular septum and extends to the right cardiac apex (white arrows). The presence of a fat component is confirmed by the loss of signal in the images with fat saturation.

Technique: cardiac magnetic resonance, 1.5 T MR System (Siemens, Symphony, Germany), breath-holding, before the administration of contrast agent.

A: T1 weighted turbo spin-echo, 4-chamber view, TE 7.1 ms, TR 642 ms.

B: T1 weighted turbo spin echo fat sat (FS), 4-chamber view, TE 7.1 ms, TR 669.4 ms.

C: T2 weighted turbo spin echo, 4-chamber view, TE 71 ms, TR 2033 ms.

D: T2 weighted turbo inversion recovery magnitude (TIRM), 4-chamber view, TE: 69 ms, TR 1167.2 ms.

E: T1 weighted turbo spin-echo, short axis view, TE 7.1 ms, TR 671 ms.

F: T2 weighted turbo spin echo, short axis view, TE 71 ms, TR 2135 ms.

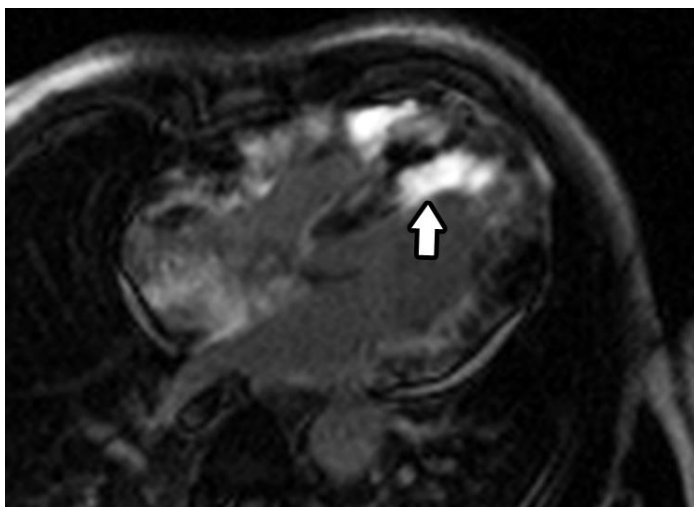


Figure 5 (left): 61 year old male with cardiac metastases of melanoma.

Findings: CMR after the injection of gadolinium clearly shows a inhomogeneous, but diffuse and avid contrast enhancement of almost all the masses previously seen, in particular around the distal part of the interventricular septum (arrow).

Technique: cardiac magnetic resonance, 1.5 T MR System (Siemens, Symphony, Germany), breath-holding, 6 minutes after intravenous injection of 0.15 mmol/kg of Gadolinium contrast agent (gadopentetate dimeglumine, Magnevist), inversion recovery late gadolinium enhancement (LGE) image in 4 chamber view, TE 1.3 ms, TR 500 ms, flip angle 650, IT 255 ms.

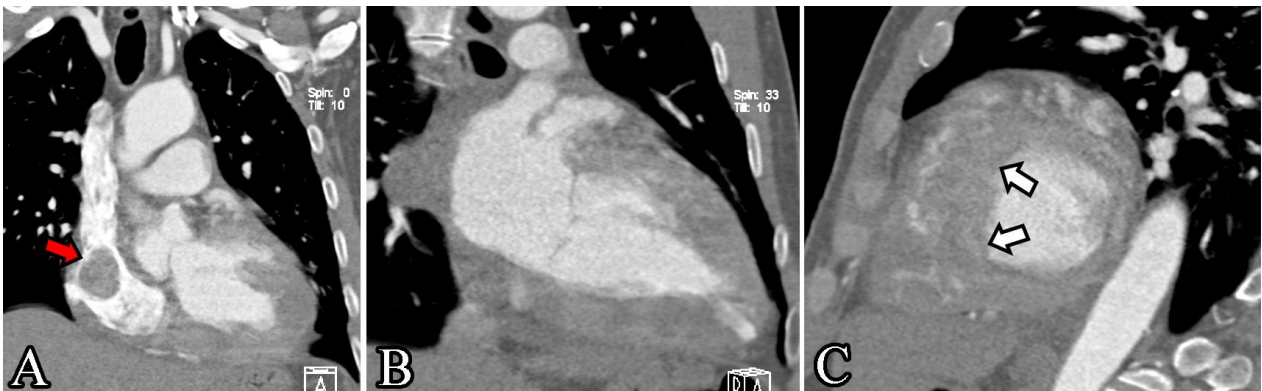

Figure 6: 61 year old male with cardiac metastases of melanoma.

Findings: MPR images of contrast enhanced CT of the chest in the arterial phase confirmed the polymorphism of cardiac masses, both infiltrating and vegetating. The areas with greater infiltration are the apex of the right ventricle, the mid-to-distal interventricular septum (white arrows), the posterior wall of the right ventricle and the lateral wall of the left ventricle. Clearly shown is also the atrial mass in the right atrium (red arrow), near superior vena cava.

Technique: chest CT (Somatom Definition 64-slice multidetector CT, Siemens, Germany), without ECG-gating, arterial phase after the intravenous injection of iodine contrast agent (100 ml at 5 ml/sec, Iomeron 400 mg iodine/ml, Bracco), slice thickness of 0.75 mm, 120 kVp, 160 mAs. Multiplanar reconstruction (MPR) images. A: inflow tract projection, B: 2-chamber view, C: short axis view.

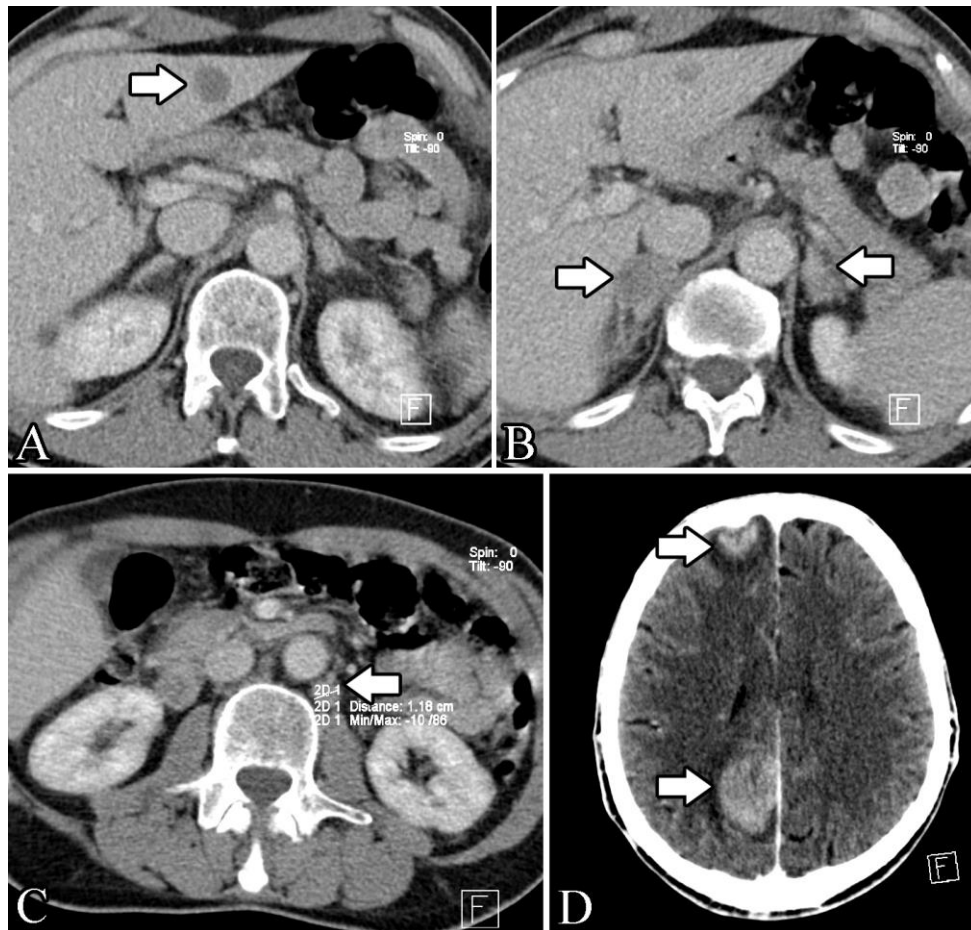


Figure 7: 61 year old male with cardiac metastases of melanoma.

Findings: axial contrast enhanced total body CT in the venous phase highlights a hypodense lesion of hepatic segment III, most likely a metastasis, with maximum diameters of around 15x19 mm (fig. 7a) (arrow). In B is evident the tumefaction of both adrenal glands (around 18x20 mm the left gland, 23x28 mm the right) (arrows) with radiological characteristic of metastasis. Image 7c shows para-aortic (arrow) and para-caval lymph nodes, most likely malign (around 11x13 and 13x15 mm). 2 cerebral focal lesions (arrows) with vivid contrast enhancement (around 25x32 mm the posterior one and 15x18 mm the anterior), highly suggestive for metastasis, are clearly recognizable in D.

Technique: total body CT (Somatom Definition 64-slice multidetector CT, Siemens, Germany) venous phase (70 seconds after the intravenous injection of iodine contrast agent, 300 seconds after the injection for the brain scan, 100 ml at 5 ml/sec, Iomeron 400 mg iodine/ml, Bracco), slice thickness of 5 mm on chest and abdomen, 4 mm on the brain scan, 120 kVp, 98 mAs. A: axial plane of the abdomen. B: axial plane of the abdomen. C: axial plane of the abdomen. D: axial plane of the brain.

Etiology	Environmental and genetic factors for melanoma
Incidence	<ul style="list-style-type: none"> • 50% at autopsy • Rare diagnosis ante mortem
Gender ratio	No sexual predilection
Age predilection	Melanoma incidence rates increase with age
Risk factors	<p>Melanoma risk factors:</p> <ul style="list-style-type: none"> • Excessive ultraviolet light exposure • Personal or family history of melanoma • Age • Fair skin • Immune suppression • Xeroderma pigmentosum
Signs or symptoms	<ul style="list-style-type: none"> • Usually clinically silent • Pericardial effusion • Superior vena cava syndrome • Tachycardia • Arrhythmias • Dyspnea • Edema • Congestive heart failure
ECG findings	Non specific
Treatment	<ul style="list-style-type: none"> • Surgical intervention should be considered as the first-line therapy to avoid cardiac failure • In most of the cases there is an extracardiac involvement making systemic chemotherapy also necessary
Prognosis	It exhibits an unpredictable clinical behavior so the natural history is difficult to predict
Localization	<ul style="list-style-type: none"> • May involve any part of the cardiac structure • Most of the cases: pericardium and myocardium, right side • Rarely: valves and endocardium
Findings on MRI imaging	<ul style="list-style-type: none"> • T1w, T2w and LGE sequences: anatomic definition and tissue characterization • Cine sequences: functional impact • We expect melanoma to be <u>T1 hyperintense and T2 hypointense</u>, but only a small percentage of melanoma metastasis have these classic findings • Amelanotic melanoma may be T1 iso- and hypo-intense • Usually <u>diffuse and avid gadolinium enhancement</u>

Table 1: Summary table of general characteristics of melanoma and cardiac metastasis of melanoma.

MRI: magnetic resonance imaging, T1w: T1 weighted, T2w: T2 weighted, LGE: late gadolinium enhancement.

	Characteristics	Uni- /multifocal	CT	MRI		
				T1w	T2w	CE
Cardiac melanoma metastasis	Multifocal cardiac masses +/- pericardial effusion	Multifocal	Body staging	Hyper	Hypo	Diffuse and avid
Thrombus	Intracavitary	Uni- or multifocal	Filling defect after CA injection	Hyper (if new), Hypo (if organized)	Hyper (if new), Hypo (if organized)	No
Pericarditis	Possible nodularity and thickening of the pericardium	Uni- or multifocal	Enhancement of thickened pericardium	Hypo	Hyper	Yes
Fibroma	Homogeneous soft-tissue mass, margined or infiltrative	Unifocal	Calcifications are common	Iso	Hypo	Usually no
Primary malign tumor	Thickening and deformation of the myocardium	Uni- or multifocal	Often low-attenuated mass, irregular or nodular	Variable	Variable	Yes
Bronchogenic carcinoma (cardiac involvement)	Frequently by direct extension	Unifocal	Must be suspected when CT or MRI demonstrates obliteration of the superior pulmonary vein			
Breast cancer metastasis	Myocardial and/or pericardial mass	Multifocal	Low attenuation mass	Hypo	Hyper	Yes
Lymphoma	No regional predilection	Focal	Irregular thickening of the walls, hypo/iso-attenuated	Iso	Hyper	Yes
Osteosarcoma (cardiac involvement)	Metastases contain bone	Focal	Calcific areas of increased opacity	Hypo/iso	Iso/hyper	Yes

Table 2: Differential Diagnosis table for cardiac metastases of melanoma [3].

CT: computed tomography, MRI: magnetic resonance imaging, T1w: T1 weighted, T2w: T2 weighted, CE: contrast enhancement, hyper: hyperintense signal, hypo: hypointense signal, iso: isointense signal, CA: contrast agent

ABBREVIATIONS

CCTA: cardiac computed tomography angiography
 CMR: cardiac magnetic resonance
 CT: computed tomography
 ECG: electrocardiogram
 FDG-PET: fluorine-18-fluorodeoxyglucose positron emission tomography
 LGE: late gadolinium enhancement
 LV: left ventricle
 PET/CT: positron emission tomography-computed tomography
 RA: right atrium
 SSFP: steady state free precession
 SVC: superior vena cava
 T1w: T1 weighted
 T2w: T2 weighted

KEYWORDS

Cardiovascular magnetic resonance; computed tomography; metastases; melanoma; cardiac tumours

Online access

This publication is online available at:
www.radiologycases.com/index.php/radiologycases/article/view/1700

Peer discussion

Discuss this manuscript in our protected discussion forum at:
www.radiopolis.com/forums/JRCR

Interactivity

This publication is available as an interactive article with scroll, window/level, magnify and more features.
 Available online at www.RadiologyCases.com

Published by EduRad



www.EduRad.org