

# Bilateral cryptorchidism mimicking external iliac lymphadenopathy in a patient with leg melanoma: role of FDG-PET and ultrasound in management

Samuel Kyle<sup>1,2\*</sup>, W Phillip Law<sup>1,2</sup>

1. Department of Radiology, Princess Alexandra Hospital, Brisbane, Australia

2. School of Medicine, University of Queensland, Brisbane, Australia

\* **Correspondence:** Samuel Kyle; Department of Radiology, Princess Alexandra Hospital, Brisbane, QLD, Australia 4102  
(✉ [samuel\\_kyle@health.qld.gov.au](mailto:samuel_kyle@health.qld.gov.au))

Radiology Case. 2014 Jan; 8(1):13-19 :: DOI: 10.3941/jrcr.v8i1.1661

## ABSTRACT

Cryptorchidism is the most common congenital anomaly present at birth in males. Spontaneous testicular descent occurs in the majority of patients, typically before 6 months of age. Radiology plays an important role, predominantly in the assessment of the nonpalpable testis, with ultrasound being the most commonly employed modality. Magnetic resonance imaging is however the most accurate modality for the assessment of the nonpalpable testis, particularly with the use of fat suppressed T2 and diffusion weighted sequences. While traditionally treated in infancy, the untreated or occult form can radiologically be mistaken for lymphadenopathy. Fluorodeoxyglucose (FDG) positron emission tomography can play an important role in differentiating cryptorchidism from lymphadenopathy, most commonly in patients with known malignancy, although FDG uptake can be variable. We present a case of bilateral cryptorchidism in an adult male which masqueraded as lymphadenopathy in a patient with lower limb melanoma.

## CASE REPORT

### CASE REPORT

#### CLINICAL PRESENTATION

A 75 year old male presented to their family practitioner with a pigmented, ulcerated lesion on their left shin. Initial biopsy of the lesion was consistent with malignant melanoma, having a Breslow thickness of 3.1mm and Clark level IV with 20 mitoses/mm<sup>2</sup> (T3b). Subsequently the patient was referred to the specialist melanoma clinic at our institution.

Clinical examination revealed a palpable mass in the left inguinal region, consistent with inguinal lymphadenopathy, and fine needle aspiration (FNA) of the palpable node was revealed this to be a melanoma nodal metastasis. In addition, a subcutaneous nodule was noted distant from the pigmented lesion on the patient's left shin, and FNA of this nodule was consistent with a cutaneous in-transit melanoma metastasis.

#### IMAGING FINDINGS

A staging contrast-enhanced computed tomography (CECT) was performed and revealed left inguinal lymphadenopathy, with the largest left inguinal node measuring 15 x 12 x 16mm (Figure 1). The CT revealed hypodense ovoid masses along the external iliac arteries bilaterally, on the left measuring 48 x 29 x 25mm and on the right 31 x 22 x 23mm (Figures 2-4), and these were originally thought to represent necrotic iliac lymphadenopathy. The empty scrotal sac was overlooked on the initial CECT.

The patient was then referred for further assessment with fluorodeoxyglucose (FDG) positron emission tomography (PET) to accurately stage the melanoma. The lesions along the external iliac arteries demonstrated no significant FDG avidity (Figures 5-7), while the lymphadenopathy in the left inguinal region demonstrated moderate-intense FDG avidity.

There were no other areas of abnormal FDG avidity in the inguinal regions, and no distant FDG-avid metastases were demonstrated.

At this stage the findings were discussed with the referring clinicians, and the possibility of bilateral cryptorchidism raised. Clinical examination was performed and revealed an empty scrotum, and on questioning the patient stated that this had been the case since birth.

A targeted ultrasound was performed which confirmed the ovoid lesions along the distal external iliac arteries represented bilateral undescended testes (Figures 8-11).

#### MANAGEMENT

The patient underwent wide local excision at the site of the primary melanoma and excision of the in-transit subcutaneous nodule. Given the inguinal lymphadenopathy a left inguinal nodal dissection was performed.

#### FOLLOW-UP

The primary melanoma was excised with clear pathologic margins, in addition to the subcutaneous nodule that was confirmed as an in-transit dermal melanoma. Three of the six left inguinal lymph nodes excised contained melanoma, with evidence of extra-nodal spread. The patient is to participate in ongoing clinical and radiologic follow-up in the specialist melanoma clinic. The patient has been referred to a urologist, however given their age nonoperative management has been recommended.

### DISCUSSION

#### ETIOLOGY AND DEMOGRAPHICS

The normal testis undergoes caudal migration from the abdomen into the scrotum during fetal life. By the third month of fetal life, the testis is located in the retroperitoneum. The gubernaculum extends from the lower pole of the testis through the muscles of the anterior abdominal wall to the subcutaneous tissues of the scrotum. Just inferior to the lower pole of the testis a peritoneal diverticulum herniates through the anterior abdominal muscles into the scrotal sac, forming the processus vaginalis. The normal testis remains at the abdominal end of the inguinal canal until the seventh fetal month, reaching the scrotal sac by the end of the eighth fetal month [1].

Normal testicular descent is dependent on a number of hormones, particularly androgens, and a number of genetic and environmental factors have been implicated in abnormal testicular migration [2]. Arrest of testicular descent at any point along its normal pathway is known as cryptorchidism, while if the descending testis does not follow the main gubernacular fibromuscular band it will result in an ectopic testis [1].

Cryptorchidism, or undescended testis, is the most common congenital anomaly present at birth in males [3]. The incidence of undescended testis is 2.2-3.8% at birth, with spontaneous descent occurring in 50-70% by 3 months of age [3]. Almost all cases of spontaneous descent occur by 1 year

of age, when the prevalence reaches 0.8-1%, which stays constant throughout life without surgical intervention. Approximately 65-71% of cases are unilateral [3].

Risk factors include prematurity, low birth weight, breech presentation, maternal diabetes, maternal exogenous estrogen exposure and family history of cryptorchidism or other genital anomalies [4].

#### CLINICAL AND IMAGING FINDINGS

Testicular position is traditionally determined at birth by physical examination. In those presenting later in life clinical examination of the scrotum and inguinal regions in the mainstay of initial assessment. Clinically it is important to differentiate from the retractile testis, which can be returned to the scrotum and will maintain its position within the scrotum when the cremasteric muscle is fatigued. If there is true cryptorchidism, it needs to be determined if the testis is palpable or impalpable, as this alters the management approach. It is also important to determine whether it is unilateral or bilateral and if isolated or as part of a syndrome [4]. Diagnostic imaging is generally only indicated in children when the location of the testis is not clinically evident, or when there are other genitourinary anomalies present [5].

Ultrasound is the most commonly used imaging modality in the assessment of cryptorchidism [5]. Ultrasound is helpful in the localisation of the high scrotal or inguinal testis [6]. However ultrasound cannot reliably identify intra-abdominal testis, which accounts for 20% of all undescended testes [5], or in localisation of an ectopic testis [6]. Accurate localisation depends on identifying a structure similar to the contralateral, normally positioned testis [6]. The undescended testis appears as a homogeneously hypoechoic, ovoid structure (Figures 8-11), but is usually smaller and isoechoic or hypoechoic relative to the normally located testis. Identification of the echogenic mediastinum testis improves diagnostic confidence [6]. Assessment with Doppler ultrasound can also be helpful to confirm vascularity, although the Doppler appearances can vary from that seen in the normal scrotal testis [6].

Computed tomography no longer plays a role in the assessment of cryptorchidism, due to the risk of ionising radiation and being superseded by magnetic resonance imaging (MRI) [5,6]. The undescended testis presents as a hypodense mass above the scrotum (Figure 1), often aided by absence of the spermatic cord within the inguinal canal.

MRI does not involve ionising radiation, however requires young children to be sedated or anaesthetised. The undescended testis has similar signal characteristics to the scrotal testis, being T1 hypointense and T2/FLAIR hyperintense [5]. The use of fat-suppressed T2 sequences increases contrast between the hyperintense testis and surrounding tissues, and helps distinguishing from lymph nodes [7]. On diffusion weighted imaging (DWI) sequences, an intraabdominal testis is hypercellular relative to adjacent tissues, and thus demonstrates increased signal intensity [8]. By combining conventional MRI sequences with fat-suppressed T2 and DWI sequences, the sensitivity and specificity of MRI in the diagnosis and localisation of the non-

palpable testis is 100% and 97.3%, respectively [7]. MRI can also demonstrate the gubernaculum, which appears as a low T2 signal curvilinear structure extending from the lower pole of the testis to the scrotal sac[6].

#### TREATMENT AND PROGNOSIS

Treatment for the undescended testis is usually performed between 6 months and 1 year of age, given spontaneous testicular descent rarely occurs after 6 months of age [9]. Management of the palpable testis involves examination under anaesthesia to confirm testicular location followed by inguinal orchidopexy, although a primary scrotal approach orchidopexy may be used in cases with a low near-scrotal testis [4]. The clinically nonpalpable testis may undergo pre-operative imaging or diagnostic laparoscopy for testicular localisation [4]. The management in this case is typically laparoscopic orchidopexy. Variations of these approaches will vary depending on patient age, testis size and condition of the contralateral testis [4]. Neoadjuvant hormonal therapy is often used in Europe with the intent of improving testis histology and fertility potential prior to surgery, however is generally not recommended in North America [4, 9].

Cryptorchid testes commonly demonstrate abnormal germ cell development, a key factor in the prognostic implications [4]. While spermatogenic function is commonly reduced in males with previous cryptorchidism, normal fertility is expected in unilateral cases [4]. There is an increased risk of germ cell tumour in the cryptorchid testis and to a lesser extent the contralateral descended testis [4]. These long term risks persist even after successful surgical correction, although earlier orchidopexy may reduce the frequency of such complications [4]. The increased relative risk of testicular malignancy in the cryptorchid testis is approximately 2.5 to 8, reducing to 2 to 3 following prepubertal orchidopexy [4].

Orchidectomy is recommended in males up to the age of 50 years due to poor fertility potential and the malignancy risk, however nonoperative management is suggested for men over the age of 50 because their cancer risk is unknown [4].

#### DIFFERENTIAL DIAGNOSIS AND ROLE OF FDG-PET/CT

As illustrated in this case report, the key differential diagnosis in the nonpalpable or intraabdominal testis is that of lymph nodes, particularly in patients with known malignancy such as melanoma or lymphoma.

Sonography of enlarged lymph nodes demonstrates a hypoechoic ovoid-round mass, often with an echogenic vascular hilum, particularly if enlarged due to benign causes. Enlarged lymph nodes at CT are often homogeneous and of soft tissue density, although they may become hypodense centrally if there is necrosis or suppuration.

Lymph nodes typically demonstrate low to intermediate T1 signal intensity, with intermediate to high T2 signal intensity. As detailed above, the use of fat-suppressed T2 weighted and diffusion weighted imaging with MRI can help distinguish the abdominal testis from lymph nodes, with the

undescended testis typically being more T2 and DWI hyperintense.

FDG PET/CT imaging is commonly used in the staging and assessment of malignancy, and can prove useful in differentiation of intraabdominal testis from lymphadenopathy (see table 3). The normal physiologic accumulation of FDG in testes can vary significantly, but is typically faint and declines with age, and may also be asymmetric (Figure 2) [10, 11, 12]. The standardised uptake value on FDG-PET studies was found by Kitakima et al to be 2.44 +/- 0.45 [11]. In distinction lymph nodes involved in metastatic malignancy, such as melanoma and testicular cancer, typically demonstrate significantly increased FDG avidity [10]. Nodal involvement in lymphoma is also typically FDG avid, other than some less common forms such as small lymphocytic lymphoma and MALT marginal zone lymphoma [13]. Reactive lymphadenopathy (secondary to regional infection or inflammation) is typically mildly FDG avid (for example SUVmax 2-4).

In this case report, review of the FDG-PET study demonstrated no significant uptake in the masses along the iliac chains, which prompted further clinical and imaging assessment and enabled the diagnosis of intraabdominal cryptorchidism to be made over the initial working diagnosis of iliac lymphadenopathy.

The other differential diagnoses for inguinal cryptorchidism are more readily distinguished. An inguinal hernia will have a "gut signature" at ultrasound imaging, as evident by the target echo pattern [14]. With CT the connection to the abdominal cavity can be identified at the external inguinal ring, with the hernial sac containing bowel loops and mesenteric fat [12]. Variable FDG uptake is present in inguinal hernias, depending on their contents and whether there is any inflammatory change present. A varicocele consists of dilated, serpiginous veins, easily confirmed with Doppler imaging, where there is prominent retrograde colour flow [15].

#### TEACHING POINT

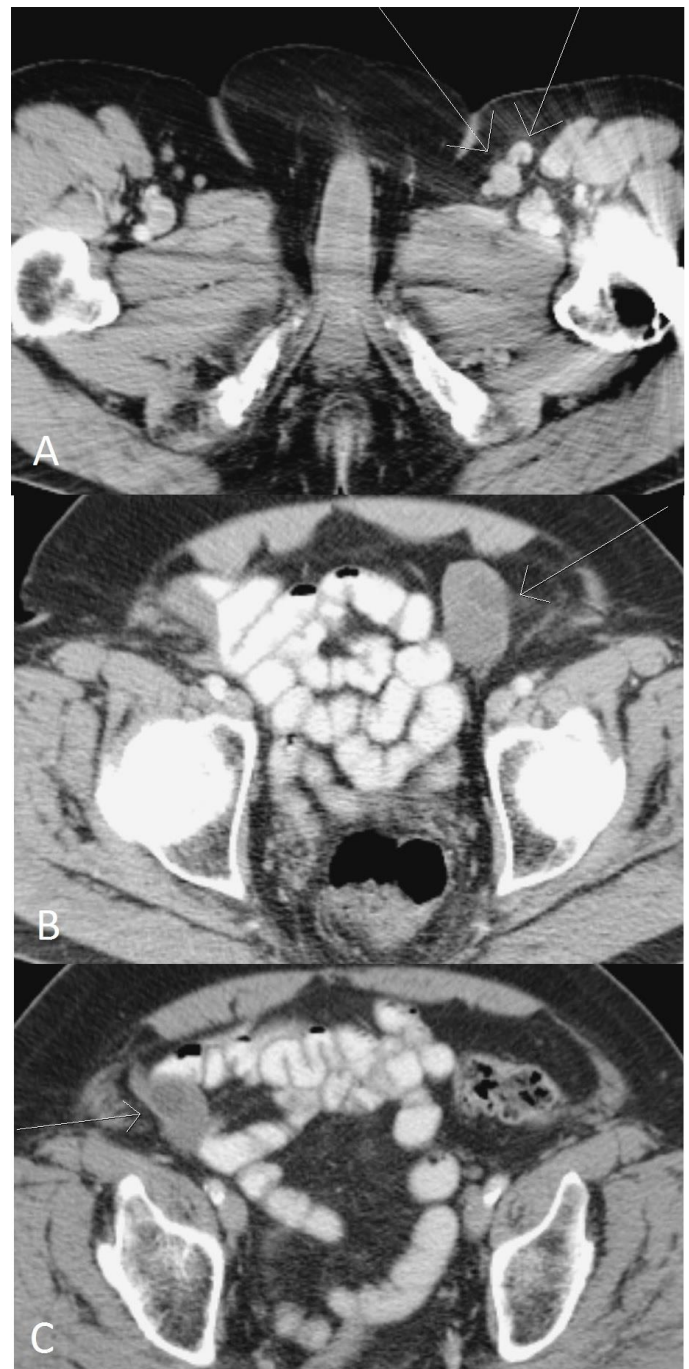Cryptorchidism is a common congenital anomaly which needs to be considered in the differential diagnosis for lymphadenopathy, particularly along the iliac nodal chains. Physical examination is the first line tool for assessment of this condition, with the use of ultrasound, MRI and FDG-PET/CT being important complimentary modalities in selected cases.

#### REFERENCES

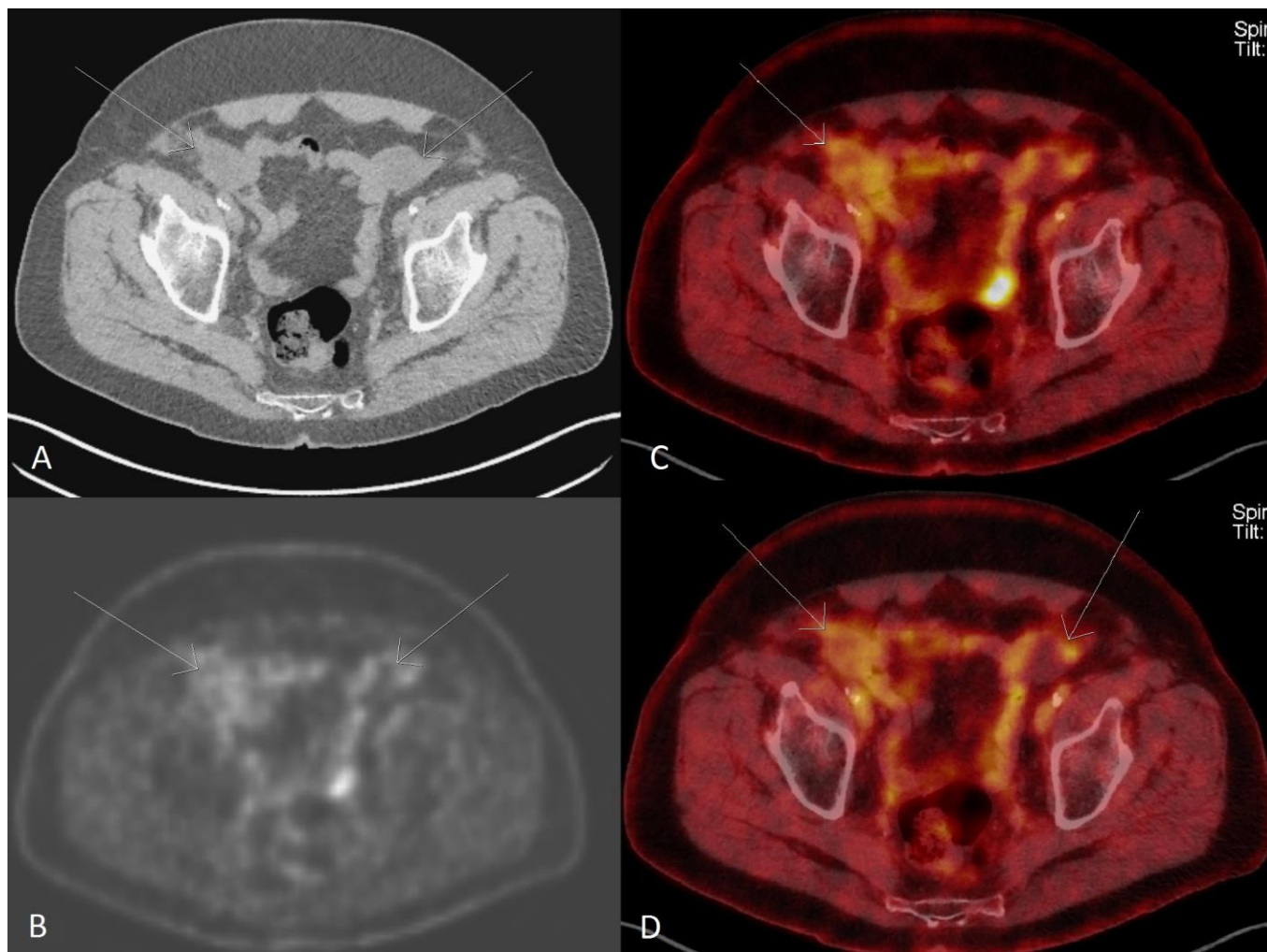
1. Tanagho EA, McAninch JW. Smith's General Urology. 16th ed. New York; Lange / McGraw-Hill, 2004; 26. ISBN 0071396489.
2. Virtanen HE, Toppari J. Epidemiology and pathogenesis of cryptorchidism. Hum Reprod Update. 2008; 14 (1) 49-58. PMID 18032558.

3. Spencer J, Gonzalez R. The epidemiology of congenital cryptorchidism, testicular ascent and orchiopexy. *J Urol.* 2003 Dec; 170 (6): 2396-2401. PMID: 14634436.
4. Ashley RA, Barthold JS, Kolon TF. Cryptorchidism: Pathogenesis, Diagnosis, Treatment and Prognosis. *Urol Clin North Am.* 2010 May; 37 (2): 183-93. PMID 20569797.
5. Tasian GE, Copp HL, Baskin LS. Diagnostic imaging in cryptorchidism: utility, indications and effectiveness. *J Pediatr Surg.* 2011 Dec; 46 (12): 2406-13. PMID 2215893.
6. Frush DP, Sheldon CA. Diagnostic imaging of pediatric scrotal disorders. *Radiographics.* 1998 Jul; 18 (4): 969-85. PMID 9672981.
7. Kato T, Kojima Y, Kamisawa H et al. Findings of fat-suppressed T2-weighted and diffusion-weighted magnetic resonance imaging in the diagnosis of non-palpable testis. *BJU Int.* 2011 Jan; 107 (2): 290-4. PMID 20735388.
8. Kantarci M, Doganay S, Yalcin A et al. Diagnostic performance of diffusion-weighted MRI in the detection of nonpalpable undescended testes: Comparison with conventional MRI and surgical findings. *AJR Am J Roentgenol.* 2010 Oct; 195 (4): W268-73. PMID 20858788.
9. Comploj E, Pycha A. Diagnosis and management of cryptorchidism. *Eur Urol Suppl.* 2012 Apr; 11: 2-9.
10. Paes FM, Kalkani DG, Sideras PA et al. FDG PET/CT of extranodal involvement in non-Hodgkin lymphoma and Hodgkin disease. *Radiographics.* 2010 Jan; 30(1): 269-91. PMID 20083598.
11. Kitajima K, Nakamoto Y, Senda M et al. Normal uptake of 18F-FDG in the testis: an assessment by PET/CT. *Ann Nucl Med.* 2007 Sep; 21 (7): 405-10. PMID 17876554.
12. Kara PO, Kaya B, Gedik GK et al. Undescended Testis in Inguinal Canal Detected Incidentally on Fluorodeoxyglucose PET/CT Imaging. *Urology.* 2012 Mar; 70(3): e29-30. PMID 22245311.
13. Weiler-Sagie M, Bushelev O, Epelbaum R et al. 18F-FDG Avidity in Lymphoma Readdressed: A Study of 766 Patients. *J Nucl Med.* 2010 Jan; 51(1): 25-30. PMID 20009002.
14. Lolge, SJ. Groin Hernias. Statdx.com. Retrieved March 17, 2013 from [https://my.statdx.com/STATdxMain.jsp?rc=false#dxContent;groin\\_hernias\\_us](https://my.statdx.com/STATdxMain.jsp?rc=false#dxContent;groin_hernias_us).
15. Jeffrey RB. Varicocele. Statdx.com. Retrieved March 17, 2013 from <https://my.statdx.com/STATdxMain.jsp?rc=false#dxContent;varicocele>.

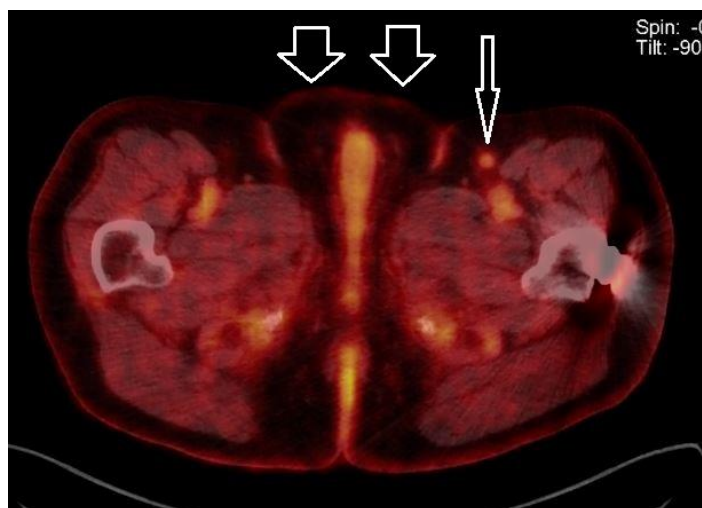FIGURES



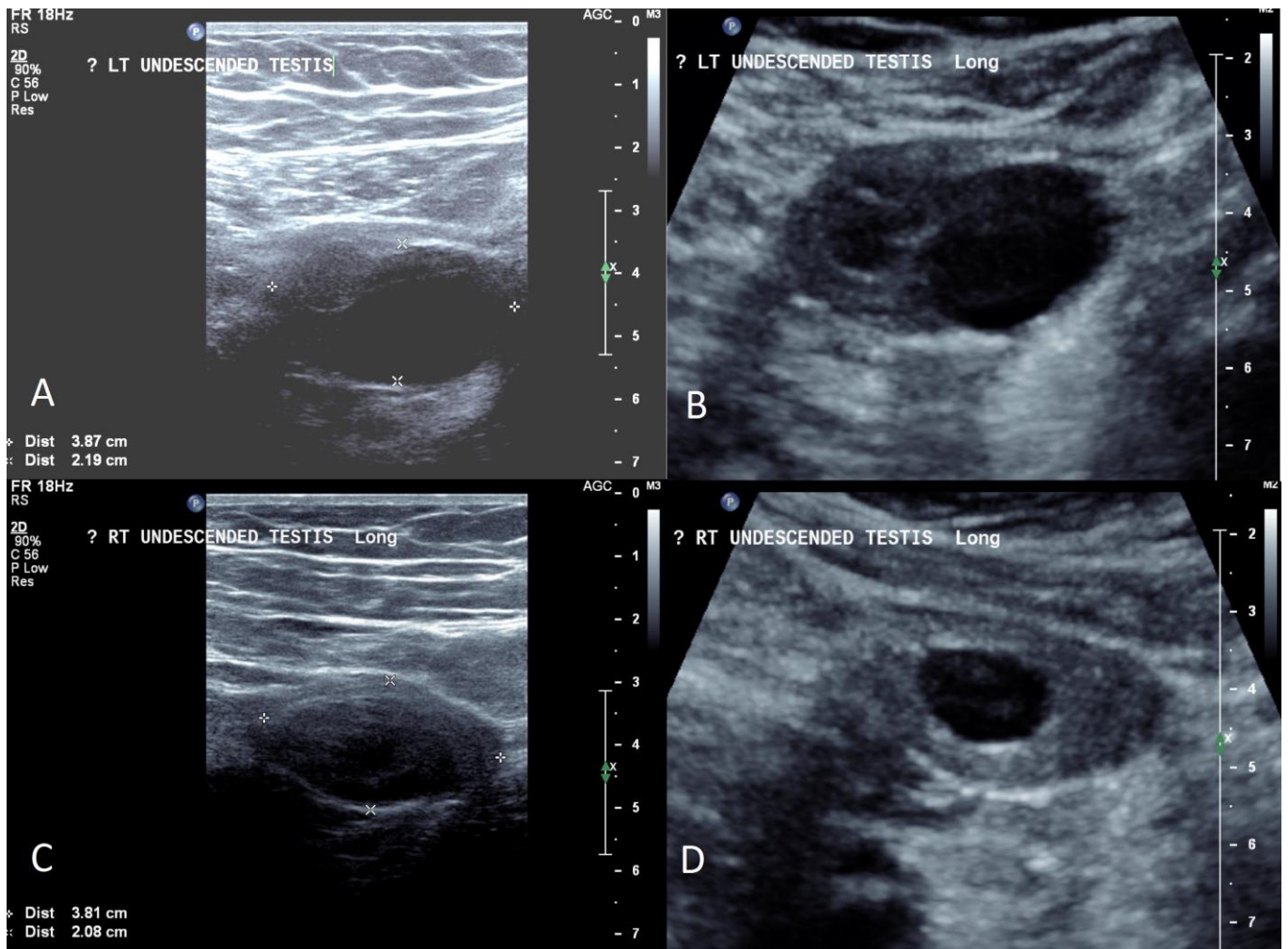
**Figure 1.** 72 year old male with metastatic melanoma and bilateral cryptorchidism. FINDINGS: Axial contrast-enhanced CT of the abdomen demonstrates left inguinal lymphadenopathy (arrows, Figure 1a). The largest (medial) lymph node measures 15 x 12 x 16mm, the smaller (lateral) node measures 12 x 11 x 14mm. An ovoid, predominantly hypodense mass just anteromedial to the left external iliac vessels measuring 48 x 29 x 25mm (arrow, Fig 1b), with a further mass noted anterior to the right external iliac artery measuring 31 x 22 x 23mm (arrow, Fig 1c). TECHNIQUE: Axial CT, 45 mAs, 120 kV, 10mm slice thickness, 100mL of IV Optiray 350 (ioversol 350mg/mL) with 45 second delay.



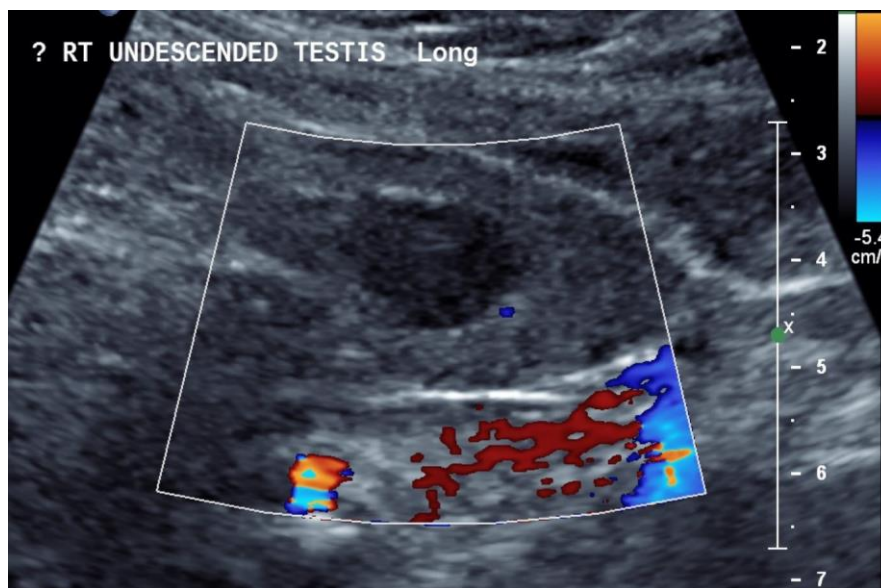
**Figure 2.** 72 year old male with metastatic melanoma and bilateral cryptorchidism. FINDINGS: Axial attenuation-correction CT (A), axial FDG-PET (B) and two axial FDG-PET-CT fused images of the abdomen (C and D) demonstrate the bilateral ovoid masses (arrows) are photopenic, or non-FDG-avid, which is uncommon for melanoma lymphatic metastases. This left mass measured 48 x 29 x 25mm and the right mass 31 x 22 x 23mm. TECHNIQUE: Emission tomographic images were obtained following the intravenous injection of 369 MBq of F-18 FDG. A low-dose CT was performed for attenuation correction, and fused images were reconstructed axially.



**Figure 3 (left).** 72 year old male with metastatic melanoma and bilateral cryptorchidism. FINDINGS: Axial FDG-PET-CT fused image of the pelvis a mildly avid left inguinal node (thin arrow) and the empty scrotal sac (thick arrows). TECHNIQUE: Emission tomographic images were obtained following the intravenous injection of 369 MBq of F-18 FDG. A low-dose CT was performed for attenuation correction, and fused images were reconstructed axially.



**Figure 4.** 72 year old male with metastatic melanoma and bilateral cryptorchidism. FINDINGS: 3A and 3B: Ultrasound of the pelvis demonstrates a 3.9 x 2.2cm hypoechoic lesion in the left anterior pelvis deep to the anterior abdominal wall. No convincing evidence of a mediastinum testis was demonstrated. 3C & 3D: A hypoechoic lesion in the left anterior pelvis deep to the anterior abdominal wall is consistent with the right undescended testis. TECHNIQUE: Philips 5-12 MHz linear probe oriented to the long axis of the lesion.



**Figure 5.** 72 year old male with metastatic melanoma and bilateral cryptorchidism. FINDINGS: Ultrasound of the pelvis with color Doppler demonstrates very minimal vascularity within the right undescended testis. TECHNIQUE: Philips 5-12 MHz linear probe oriented to the long axis of the lesion.

<b>Etiology</b>	Failure of normal caudal migration of the testis along the gubernaculum from the retroperitoneum to the scrotum. Hormonal influences (particularly androgens). Genetic and environmental causes.
<b>Incidence</b>	2.2-3.8% at birth, reducing to 0.8-1.0% at 1 year of age.
<b>Gender ratio</b>	Males only.
<b>Age predilection</b>	Usually present at birth. Most common in early infancy. Most will descend by 6 months of age.
<b>Risk factors</b>	Prematurity, low birth weight, breech presentation, maternal diabetes, maternal exogenous estrogen exposure, family history of cryptorchidism or other genital anomalies.
<b>Treatment</b>	Palpable: inguinal orchidopexy. Nonpalpable: laparoscopic orchidopexy.
<b>Prognosis</b>	Good if operated on at 6-12 months of age. Usually preserved fertility if unilateral. Increased risk of germ cell tumour.
<b>Imaging findings</b>	US: Homogeneously hypoechoic. Ovoid. Echogenic mediastinum. CT: Hypodense mass above scrotum. MRI: T1 hypointense; T2 hyperintense; DWI hyperintense. FDG-PET: Faint but variable uptake.

**Table 1:** Summary table for cryptorchidism

Diseases	US	CT	MRI	FDG-PET
<b>Cryptorchidism</b>	Homogeneously hypoechoic. Ovoid. Echogenic mediastinum.	Hypodense mass above scrotum.	T1 hypointense; T2 hyperintense; DWI hyperintense.	Faint but variable uptake.
<b>Lymphadenopathy</b>	Hypoechoic +/- echogenic vascular hilum.	Homogeneous or central hypodense.	T1 low-mid and T2 mid-high signal.	Increased avidity with malignancy.
<b>Hernia</b>	Gut signature, target sign. Peristalsis.	Contains bowel and fat.	Bowel signal. Contains fat.	Variable uptake.
<b>Varicocele</b>	Retrograde colour flow.	Dilated serpiginous veins.		No uptake.

**Table 2:** Differential diagnosis table for inguinal/iliac chain masses which can mimic or be mistaken for cryptorchidism

Disease entity	FDG-PET appearance
<b>Cryptorchidism</b>	Variable uptake, but usually faint. Can be asymmetric.
<b>Lymphoma</b>	Most forms of lymphoma are FDG-avid. Some forms however are variably FDG avid (e.g. small lymphocytic lymphoma, MALT marginal zone lymphoma).
<b>Metastatic lymphadenopathy</b>	Typically FDG-avid.
<b>Reactive lymphadenopathy</b>	Usually mildly FDG-avid.

**Table 3:** Different patterns of FDG uptake in pelvic and inguinal lesions relevant to cryptorchidism

**ABBREVIATIONS**

CT: computed tomography  
 CECT: contrast-enhanced computed tomography  
 DWI: diffusion weighted imaging  
 FDG: fluorodeoxyglucose  
 FNA: fine needle aspiration  
 MRI: magnetic resonance imaging  
 PET: positron emission tomography

**KEYWORDS**

Cryptorchidism; Undescended testis; Lymphadenopathy; Lymph node; Melanoma

**Online access**

This publication is online available at:  
[www.radiologycases.com/index.php/radiologycases/article/view/1661](http://www.radiologycases.com/index.php/radiologycases/article/view/1661)

**Peer discussion**

Discuss this manuscript in our protected discussion forum at:  
[www.radiopolis.com/forums/JRCR](http://www.radiopolis.com/forums/JRCR)

**Interactivity**

This publication is available as an interactive article with scroll, window/level, magnify and more features.  
 Available online at [www.RadiologyCases.com](http://www.RadiologyCases.com)

Published by EduRad



[www.EduRad.org](http://www.EduRad.org)