

# Diagnosis of pancreatic duct-portal vein fistula; a case report and review of the literature

Anthony Brown<sup>1\*</sup>, Eric Malden<sup>2</sup>, Marcelo Kugelmas<sup>3</sup>, Eric Kortz<sup>4</sup>

1. Department of Radiology, University of Colorado hospital, Denver, USA

2. Department of Radiology, Swedish hospital, Denver, USA

3. Department of Gastroenterology, Swedish hospital, Denver, USA

4. Department of Surgery, Swedish hospital, Denver, USA

\* Correspondence: Anthony Brown M.D., University of Colorado, Department of Radiology, 1635 Aurora court, Aurora, CO, USA  
[✉ Anthony.brown@ucdenver.edu](mailto:Anthony.brown@ucdenver.edu)

Radiology Case. 2014 Mar; 8(3):31-38 :: DOI: 10.3941/jrcr.v8i3.1552

## ABSTRACT

Pseudocysts containing activated enzymes are a common complication of pancreatitis. Pseudocysts can rupture into adjacent structures including the peritoneal cavity, adjacent organs, and rarely vascular structures. While arterial pseudoaneurysms and venous thrombosis or occlusion are well known complications of acute and chronic pancreatitis, only 17 cases of pancreas-portal venous fistula have been encountered in review of the literature. A patient with chronic pancreatitis presented with a history of weight loss, fatigue and was found to have a pancreatic duct-portal vein fistula. The patient was treated surgically with good outcome.

## CASE REPORT

### CASE REPORT

A 50 year-old woman with history of chronic pancreatitis caused by long-term alcohol use presented to her primary care physician with fatigue, weight loss and anorexia. Her most recent hospitalization was for alcohol-induced seizures the previous year. Initial pertinent lab values included alkaline phosphatase 664 IU/L (normal 33-131 IU/L), gamma-glutamyl transpeptidase (GGT) of 997 (normal 5-55 U/L), amylase 190 (normal 25-115 U/L) and albumin 1.3 g/dl. (Normal =3.2-5 g/dl). Contrast enhanced CT (Fig. 1-3) showed liver cirrhosis and small ascites as well as findings of chronic pancreatitis including three small pseudocysts, the largest of which measured 1.4 cm. The two adjacent cysts each measured less than 1 cm. A larger, 2.6 cm pseudocyst was in the pancreatic tail near the splenic hilum. The splenic and superior mesenteric veins appeared to be chronically thrombosed and there were peri-portal collaterals in the hepatic hilum. The portal vein was dilated measuring 1.5 cm and the lumen appeared to be filled with fluid. This unusual appearance of the portal vein prompted further investigation for evidence of

fistula given the proximity of the pseudocysts to the portal vein. Initial invasive imaging with endoscopic retrograde cholangiopancreatography (ERCP) (Fig. 4) was performed and demonstrated a distal common bile duct stricture related to chronic pancreatitis and several pseudocysts, but there was no evidence of connection to the portal vein. The pancreatic duct (Fig. 5) was thin and narrow due to chronic inflammation, but did not show any evidence of fistula. Therefore, a stent was placed across the common bile duct stricture and further evaluation with MRI/MRCP was performed in order to re-evaluate the ductal anatomy and assess for any extra-ductal cause of the suspected fistula. MRI showed 3 pseudocysts in the pancreatic head, the largest measuring 1.4 cm in close proximity to the fluid signal intensity portal vein (Fig. 6,7). MRCP showed a dilated portal system with fluid signal intensity matching that of adjacent pseudocysts. Thin fluid signal between the pancreatic duct and the portal confluence was suspicious for, but not diagnostic of a fistula (Fig. 8,9).

Ultrasound guided trans-hepatic portography was performed in order to both aspirate the fluid for analysis and

evaluate for flow within the vein. Upon accessing the portal vein (Fig. 10), fluid aspirate yielded clear brown fluid with an amylase of 37455 IU/dl and lipase 39050 IU/dl. There was complete stasis of flow, but contrast injection revealed a fistulous tract between the portal venous system and the pancreatic duct (Fig. 11,12). The patient was discharged and admitted one month later for pylorus preserving pancreaticoduodenectomy, takedown of pancreatoco-portal fistula, cholecystectomy and liver biopsy. Intra-operatively, the direct communication between a branch of the pancreatic duct and the portosplenic venous confluence was identified (Figure 13).

Postoperatively, the patient was successfully treated for postsurgical polymicrobial gram-negative bacteremia and discharged. Four months later she was hospitalized for malnutrition, intractable ascites and pneumonia for which she had laparoscopic surgery and loculated ascites was drained. Seven months later she was admitted for an adhesive small bowel obstruction that was treated surgically with lysis of adhesions. Despite these complications, the patient was doing well at 24-month follow-up.

## DISCUSSION

A patient with abdominal pain and weight loss was shown to have a pancreatic duct -portal vein fistula caused by presumed rupture of a pseudocyst and subsequent erosion into the portal venous system. There are 17 other cases of pancreas-portal vein fistula in the English literature. All of the cases were reviewed and relevant data summarized (Table 1).

### *Etiology and Demographics:*

Pancreatic fistulas occur primarily as a result of trauma, pancreatic surgery and disruption of the pancreatic duct in chronic pancreatitis [5-6]. 14 of 17 patients had a significant alcohol history and 14 had chronic pancreatitis. Eleven of sixteen patients who presented with a fistula to the portal vein had a pseudocyst present in the head of the pancreas in close proximity to the portal vein. The proposed mechanism of pancreas-portal fistula formation involves uninhibited pancreatic enzymes within a pseudocyst causing erosion of the wall of the portal vein. The erosion incites thrombosis followed by a break down of the thrombus and subsequent filling of the portal vein with pancreatic secretions [2]. Other pathologic causes of portal vein thrombosis that do not result in a fistula are mass effect from a pseudocyst without rupture and tumor or lymphadenopathy in the hepatic hilum [21]. The pancreatic enzymes within the portal venous system can result in presentation varying from vague abdominal pain to symptoms associated with disseminated fat necrosis, which is a severe complication of pancreas-portal fistula and is manifested most commonly with hyperamylasemia, painful erythematous lesions on the lower extremities and arthritis [4, 8, 10, 14]. Abdominal pain was the most common presenting symptom occurring in 12/17 patients, and 11/17 had hyperamylasemia, though amylase was not recorded in six of the patients. Five patients presented with or developed disseminated fat necrosis. Patients with recorded amylase greater than 6000 all presented with disseminated fat necrosis.

This more severe disease state is likely due to the uninhibited pancreatic secretions being introduced into the systemic circulation, though it is unclear why some patients present with this severe disease state and others do not [1].

### *Differential Diagnosis:*

The variation in imaging techniques used in the literature to identify pancreas-portal vein fistula underlines the difficult and subtle nature of the diagnosis. More common differential diagnoses of a low attenuation portal vein include bland portal vein thrombosis, usually due to cirrhosis, hypercoagulable state, or extrinsic compression of the portal vein by tumor or lymphadenopathy.

### *Clinical and Imaging findings:*

Initial ultrasound evaluation of patients with pancreas-portal vein fistula would demonstrate complex fluid within the portal vein and absent flow. Conversely, ultrasound of bland thrombosis would demonstrate absent portal flow and thrombus within the vein. Extrinsic compression resulting in thrombosis would show absent flow with narrowing of the vein at the site of compression. The cross sectional imaging findings of a pancreatic duct-portal vein fistula include a fluid attenuation portal vein and may show adjacent pseudocysts. MRI findings include a fluid signal intensity portal vein, pseudocysts and may show a hyperintense fistula tract. Cross sectional imaging findings in bland portal vein thrombosis include a hypodense portal vein on CT that does not enhance, an isointense portal vein on T1WI MRI and increased portal vein signal on T2WI. Peri-portal collateral vessels within the hepatic hilum may be present in all cases if thrombosis is chronic. Thrombosis due to external compression from tumor or lymphadenopathy will show similar findings in the portal vein, but may show an enhancing or non-enhancing mass in the hilum or within the portal vein after contrast administration. Percutaneous hepatic portography is diagnostic if a fistula is identified during contrast injection whereas bland thrombosis will show stasis of flow and no fistula. Tumor or lymph nodes in the hilum may show a defect from external compression. ERCP is diagnostic if a fistula is identified extending from the pancreatic duct. ERCP will not depict portal thrombosis directly but can show evidence of portal biliopathy that is more common in cases of portal vein thrombosis not related to cirrhosis. Portal biliopathy involves dilatation and congestion of the paracholedochal veins of Petren and the epicholedochal venous plexus of Saint resulting in compression and stricture of the extrahepatic bile ducts. [22]

Advanced invasive and noninvasive imaging has been shown to definitively diagnose portal vein fistulae. 14/17 patients had initial contrast enhanced CT which, in pancreas-portal fistula often demonstrates low attenuation thrombus with non-enhancing portal vein but is unlikely to depict the fistula. Definitive diagnosis of the fistula by CT occurred in 1/17 patients. ERCP gave definitive diagnosis of pancreatic duct-portal vein fistula in 4 of the cases, and was used as a supplemental tool in 4 other cases. ERCP is limited in depicting a fistula if there is not a direct connection between the pancreatic duct and the pseudocyst or if there is incomplete opacification of the pancreatic duct due to stricture or stone in the main duct. MRI rendered the diagnosis in 2/17 cases.

Percutaneous trans-hepatic portography (PTP) is the most direct route of access to the portal system. PTP was diagnostic in 4/17 cases and offered supplemental information in 4 other cases. In the current case, the tract from the pseudocyst to the portal vein was clearly identified using PTP, and the technique also allowed for the extraction of portal fluid for analysis [10]. PTP is used to treat portal vein thrombosis after major surgery and can also define the extent of major portal venous invasion by pseudocysts as well as tumors in the liver, pancreas and porta hepatis [19, 20]. PTP provides precise anatomic data regarding the extent of major portal venous invasion and has shown excellent correlation with surgical findings [18]. In 5 cases the fistula was not revealed until either surgery (3 cases) or autopsy (2 cases).

*Treatment and Prognosis:*

Patients with pseudocyst-portal vein fistula must be evaluated on an individual basis and the imaging findings are important in surgical planning. Earlier surgical intervention may be justified if the patient presents with or develops disseminated fat necrosis due to the reports of worsened morbidity and mortality [5, 8,15]. Our patient presented with vague symptoms of abdominal pain and weight loss but her history and imaging findings of pseudocysts in close association with a fluid filled portal vein gave clinical suspicion for a fistula. A high clinical suspicion is necessary to diagnose such a fistula but the information gathered allowed for prompt surgical treatment of this condition, which alleviated the patient's symptoms of weight loss and fatigue, prevented future complications of the fistula and led to a positive outcome.

**TEACHING POINT**

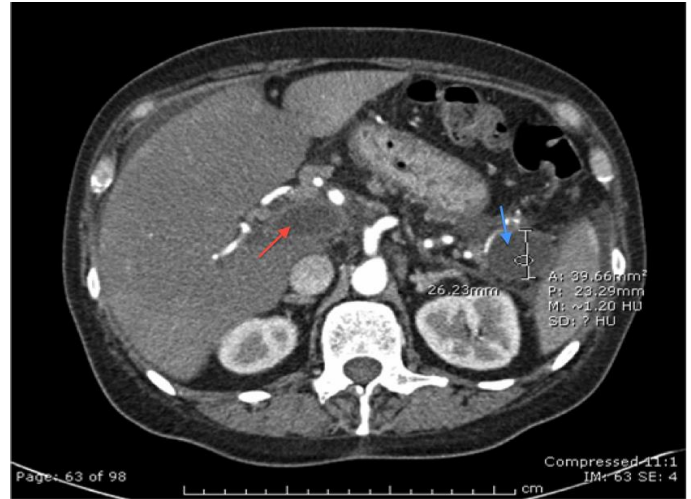Findings of a fluid density portal vein on contrast enhanced CT in a patient with chronic pancreatitis and pseudocysts should raise suspicion for pseudocyst-portal vein fistula, and subsequent imaging should be performed to definitively identify the fistula for surgical planning. While CT and MRI are both helpful for initial characterization of pseudocysts and ductal anatomy, ERCP and transhepatic portography have been most effective in visualization of pseudocyst-portal fistulas.

**REFERENCES**

1. Zeller M, Hetz HH. Rupture of a pancreatic cyst into the portal vein. Report of a case and generalized fat necrosis. *JAMA* 1966;195:869-871. PMID: 12608186
2. Dawson B, Kasa D, Mazer M. Pancreatic pseudocyst rupture into the portal vein. *South Med J* 2009;102(7):728-732. PMID: 19561436
3. Lee SH, Bodensteiner D, Eisman S, Dixon AY, McGregor DH. Chronic relapsing pancreatitis with pseudocyst erosion into the portal vein and disseminated fat necrosis. *Am J Gastroenterol* 1985;80:452-8. PMID: 2408464

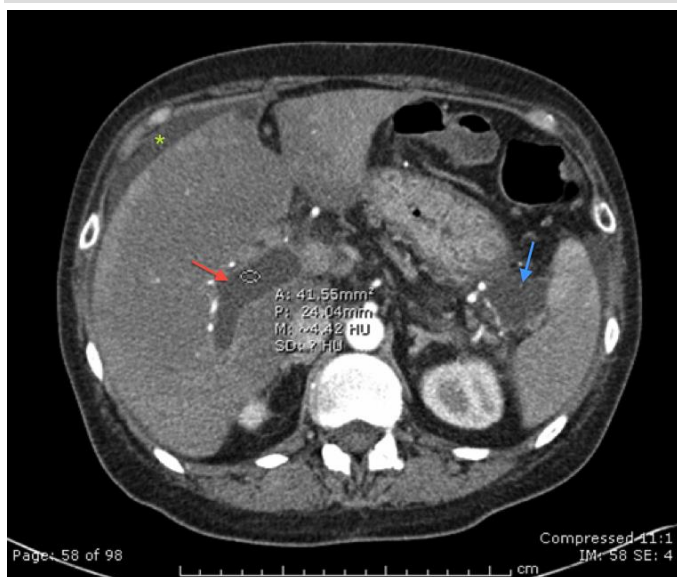
4. Willis SM, Brewer TG. Pancreatic duct-portal vein fistula. *Gastroenterology* 1989;97:1025-1027. PMID: 2777027
5. McCormick PA, Chronos N, Burroughs AK, et al. Pancreatic pseudocyst causing portal vein thrombosis and pancreatico-pleural fistula. *Gut* 1990;31:561-563. PMID: 2251306
6. Van Steenberg W, Ponette E. Pancreaticportal fistula: a rare complication of chronic pancreatitis. *Gastrointest Radiol* 1990;15:299-300. PMID: 2010199
7. Potts JR III. Pancreatic-portal vein fistula with disseminated fat necrosis treated by pancreaticoduodenectomy. *South Med J* 1991;84:632-635. PMID: 2035087
8. Skarsgard ED, Ellison E, Quenville N. Spontaneous rupture of a pancreatic pseudocyst into the portal vein. *Can J Surg* 1995;38:459-463. PMID: 7553473
9. Procacci C, Mansueto GC, Graziani R, et al. Spontaneous rupture of a pancreatic pseudocyst into the portal vein. *Cardiovasc Intervent Radiol* 1995;18:399-402. PMID 8591628
10. Yamamoto T, Hayakawa K, Kawakami S, et al. Rupture of a pancreatic pseudocyst into the portal venous system. *Abdom Imaging* 1999;24:494-496. PMID: 10475935
11. Chang L, Francoeur L, Schweiger F Pancreaticportal fistula in association with antiphospholipid syndrome presenting as ascites and portal system thrombosis. *Can J Gastroenterol* (2002) 16: 601-605. PMID: 12362212
12. Hammar AM, Sand J, Lumio J, et al. Pancreatic pseudocystportal vein fistula manifests as residivating oligoarthritis, subcutaneous, bursal and osseal necrosis: a case report and review of literature. *Hepatogastroenterology* 2002;49:273-278. PMID: 11941974
13. Riddell A, Jhaveri K, Haider M. Pseudocyst rupture into the portal vein diagnosed with MRI. *Br J Radiology* 2005; 78:265-8. PMID: 15730995
14. Rasmussen IC, Karlson BM, Löfberg AM. Biliary pancreatic portal fistula as a complication of chronic pancreatitis: a case report with review of the literature. *Ups J Med Sci.* 2006;111(3):329-38. PMID: 17578800
15. Yoon SE, Lee YH, Yoon KH, et al. Spontaneous pancreatic pseudocyst-portal vein fistula presenting with pancreatic ascites: strength of MR cholangiopancreatography. *Br J Radiol* 2008;81e13-e16. PMID: 18079345
16. Takayama T, Kato K, Sano H, et al. Spontaneous rupture of a pancreatic pseudocyst into the portal venous system. *AJR Am J Roentgenol* 1986;147:935-6. PMID: 3490165
17. Cho YD, Cheon YK, Cha SW et al. Pancreatic duct-portal vein fistula. *Gastrointest Endosc.* 2003 Sep; 58(3):415. PMID: 14528217

18. Kim KR, Ko GY, Sung KB, Yoon HK. Percutaneous Transhepatic Stent Placement in the Management of Portal Venous Stenosis After Curative Surgery for Pancreatic and Biliary Neoplasms. PMID: 21427310
19. Adani G, Baccarani U, Risaliti A, et al. Percutaneous Transhepatic Portography for the Treatment of Early Portal Vein Thrombosis After Surgery. Cardiovascular and Interventional Radiology, 2007, Volume 30, Number 6, Pages 1222-1226. PMID: 17573552
20. Stein M, Schneider P, Ho H, Eckert R, Urayama S, Bold R. Percutaneous Transhepatic Portography with Intravascular Ultrasonography for Evaluation of Venous Involvement of Hepatobiliary and Pancreatic Tumors. JVIR 2002; 12(8): 805-814. PMID: 12171984
21. Brant WE, Helms CA. Fundamentals of diagnostic radiology. Lippincott Williams &Wilkins. (2007) ISBN:0781761352
22. Walser EM, Runyan BR, Heckman MG, et al. Extrahepatic portal biliopathy: proposed etiology on the basis of anatomic and clinical features. Radiology. 2011 Jan;258(1):146-53. Epub 2010 Nov 2. PMID: 21045178

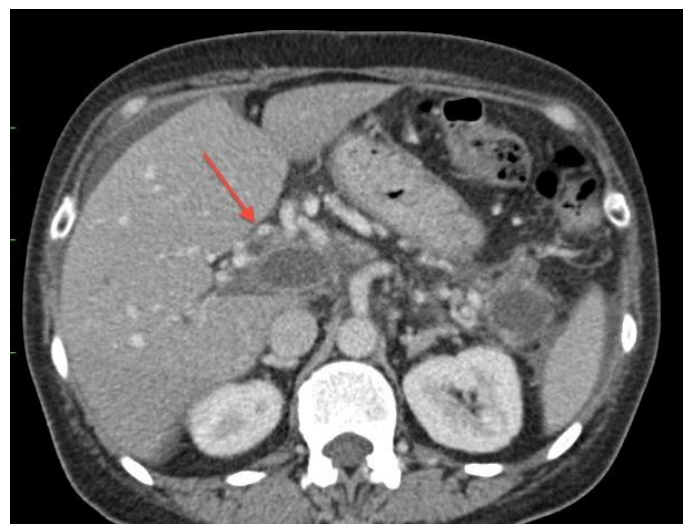

**Figure 2:** 50 year-old female with pancreatic duct-portal vein fistula. Contrast enhanced axial CT image in arterial phase caudal to Figure 1. shows fluid density (1.20 HU) in a pseudocyst (blue arrow) that is in the splenic hilum. The pseudocyst measures 2.6 cm in axial dimension. Fluid density is shown within the main portal vein (red arrow). (Protocol: 64 slice scanner, axial arterial-phase 2.0mm axial images. 64 slice scanner, 260 mAs, 120 kV, 100 ml iopamidol (Isoview 370, Bracco Diagnostics Milan, Italy))

FIGURES

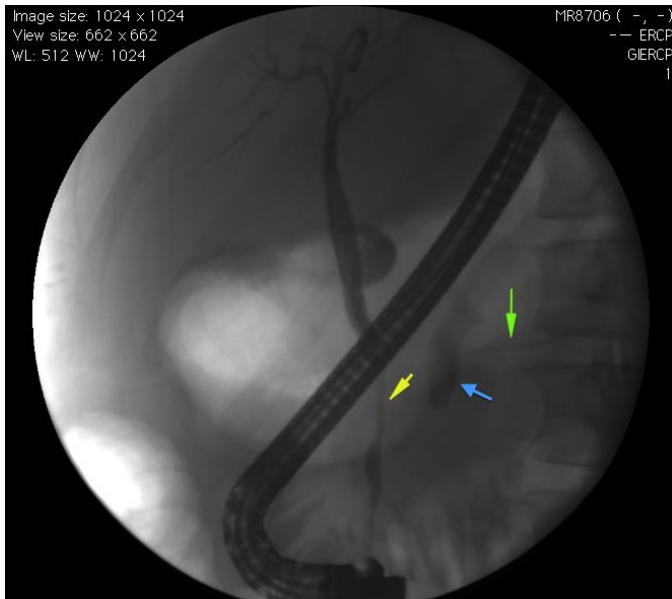


**Figure 1:** 50 year-old female with pancreatic duct-portal vein fistula. Axial contrast enhanced CT image in arterial phase at the level of the hepatic hilum shows a dilated, 15 mm fluid attenuation portal vein (4.42 Hounsfield units) (red arrow). The liver is heterogeneous in enhancement and small ascites is present along the anterior margin of the liver (green asterisk) as well as along the margin of the spleen. There is no splenomegaly. A fluid attenuation structure representing a pseudocyst is shown in the splenic hilum (blue arrow). (Protocol 64 slice scanner, Arterial-phase 2.0mm axial images. 260 mAs, 120 kV, 100 ml iopamidol (Isoview 370, Bracco Diagnostics Milan, Italy))

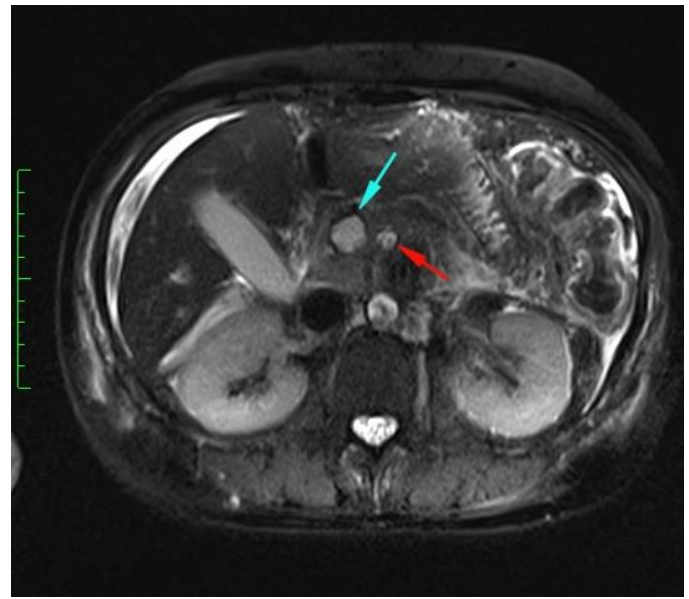


**Figure 3:** 50 year-old female with pancreatic duct-portal vein fistula. Contrast enhanced axial CT image in delayed phase demonstrating extensive collateralization within the hepatic hilum (red arrow) surrounding the fluid attenuation portal vein. The liver is enlarged with surrounding small ascites. A pseudocyst is in the splenic hilum. (Protocol: 64 slice scanner, axial 5 minute delay phase 3.0mm axial image. 64 slice scanner, 260 mAs, 120 kV, 100 ml iopamidol (Isoview 370, Bracco Diagnostics Milan, Italy), 900cc gastroview, Mallinckrodt Inc, Saint Louis, MO))

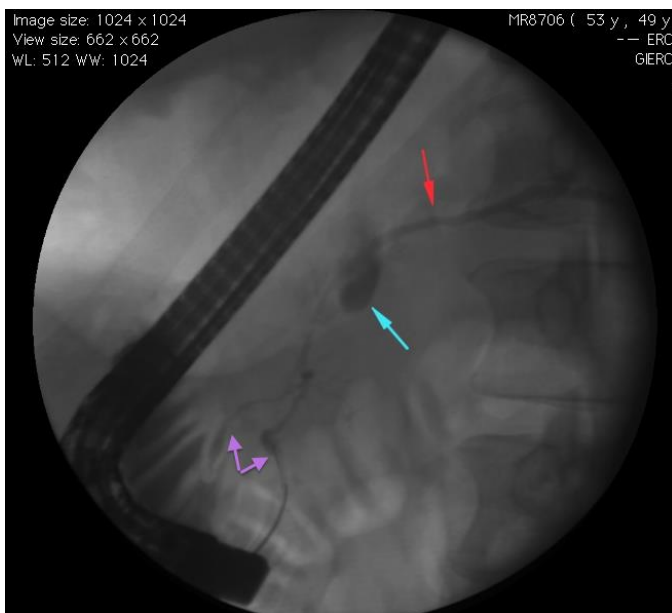




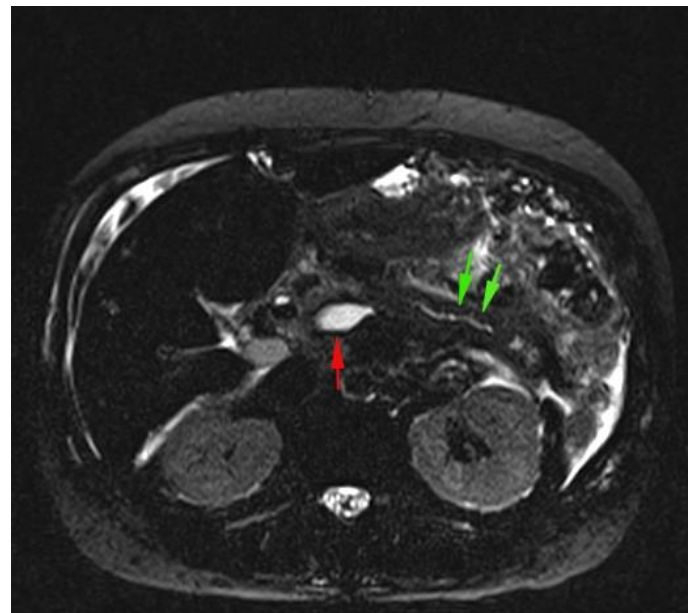
**Figure 4:** 50 year-old female with pancreatic duct-portal vein fistula. A/P projection ERCP image shows contrast opacification of the common bile duct and main pancreatic duct. The gallbladder is surgically absent. There is no intrahepatic or extrahepatic biliary duct dilatation. A stricture is within the extrahepatic common bile duct at the pancreatic head (yellow arrow). The main pancreatic duct is not dilated (green arrow), but contrast fills a pseudocyst near the pancreatic head-neck junction (blue arrow). The portal vein is not opacified.



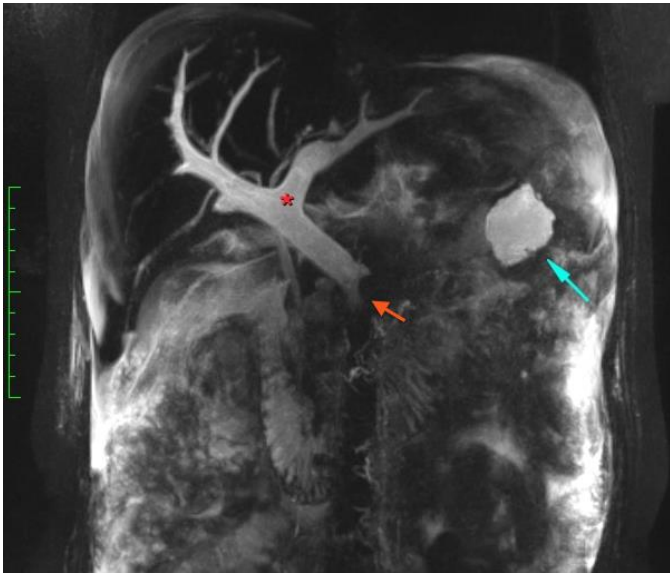**Figure 6:** 50 year-old female with pancreatic duct-portal vein fistula. Axial T2 HASTE FAT SAT MRI through the level of the pancreatic head shows T2 hyperintense signal within a 1.4 cm pseudocyst (blue arrow) and identical T2 signal within the immediately adjacent portal vein near the confluence (red arrow) without definite fistula tract. T2 hyperintensity representing ascites is along the liver capsule and along the left abdominal wall. (Protocol: MRI, 1.5T, TR 2000, TE 90 without contrast)



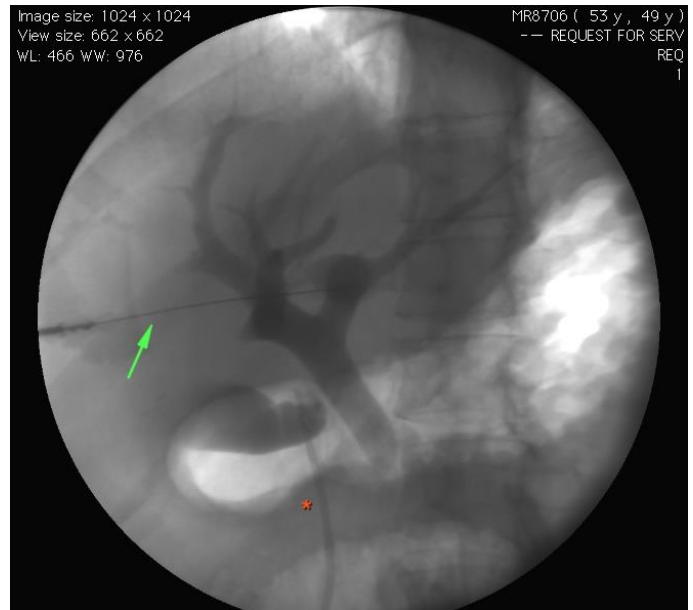
**Figure 5:** 50 year-old female with pancreatic duct-portal vein fistula. A/P ERCP magnified image shows opacification of both the dorsal and ventral pancreatic ducts in the pancreatic head, both of which are irregular with tortuous side branch ducts consistent with chronic pancreatitis (purple arrows). The main pancreatic duct in the body is normal caliber (red arrow) and pseudocyst is at the pancreatic head-neck junction (blue arrow).



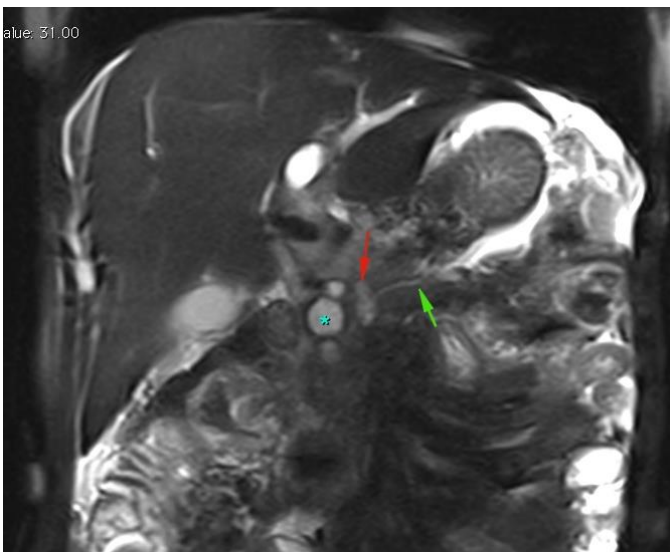
**Figure 7:** 50 year-old female with pancreatic duct-portal vein fistula. Axial T2 HASTE FAT SAT THIN SECTION shows T2 hyperintense signal within a non-dilated pancreatic duct in the pancreatic body (green arrows). The portal vein near the confluence demonstrates similar T2 signal intensity (red arrow). Ascites is present along the liver margin and along the left abdominal wall. (Protocol: MRI, 1.5T, TR 2000, TE 241 without contrast)



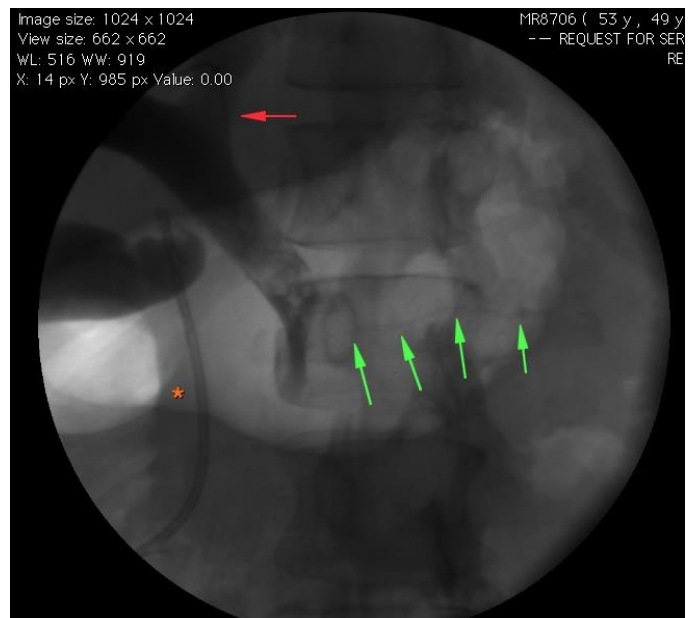
**Figure 8:** 50 year-old female with pancreatic duct-portal vein fistula. 3D coronal SPACE MRCP MIP image shows the T2 hyperintense portal vein (red asterisk) with abrupt cutoff of signal at the portal confluence (orange arrow). There is no signal in the superior mesenteric and splenic veins related to thrombosis. A T2 hyperintense mass near the splenic hilum represents a 2.6 cm pseudocyst (blue arrow). (Protocol: 1.5T, TR 4448, TE 710 without contrast)



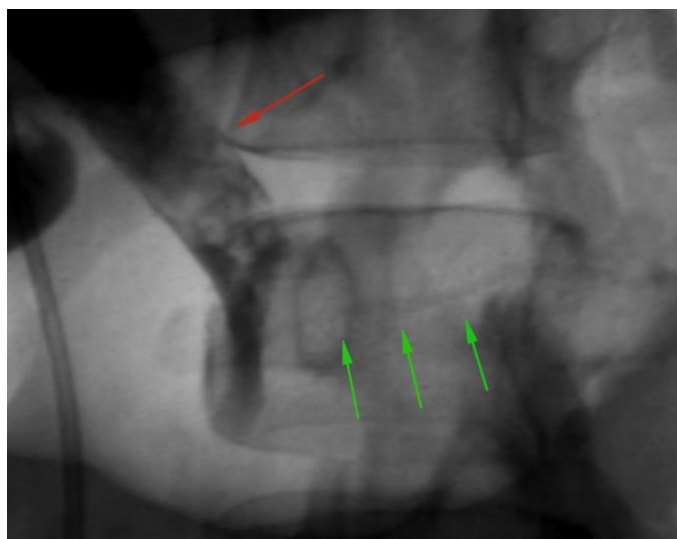
**Figure 10:** 50 year-old female with pancreatic duct-portal vein fistula. A/P projection percutaneous transhepatic portogram shows needle access within the proximal left intrahepatic branch of the portal vein (green arrow) and contrast opacification of the portal vein demonstrating complete stasis of flow. No contrast reflux into the superior mesenteric or splenic veins is demonstrated. A 7 French, 7cm biliary stent is present in the extra-hepatic bile duct (orange asterisk)



**Figure 9:** 50 year-old female with pancreatic duct-portal vein fistula. CORONAL T2 HASTE FAT SAT section through the pancreatic head suggests a communication between the portal vein (red arrow) and the non-dilated main pancreatic duct (green arrow). 3 nearby pseudocysts are in the pancreatic head, the largest of which measures 1.4 cm (blue asterisk). The liver is enlarged measuring 18.7 cm. Small ascites is present. (Protocol: MRI, 1.5T, TR 2000, TE 92 without contrast)



**Figure 11:** 50 year-old female with pancreatic duct-portal vein fistula. A/P projection magnification view percutaneous transhepatic portogram shows a contrast opacified portal vein (red arrow) with extension of contrast into the main pancreatic duct (green arrows). The 7 French, 7cm biliary stent is in the extrahepatic common bile duct (orange asterisk).



**Figure 12:** 50 year-old female with pancreatic duct-portal vein fistula. Magnified A/P projection transhepatic portogram showing the fistulous connection of the portal vein (red arrow) to the pancreatic duct (green arrows).

**Figure 13:** 50 year-old female with pancreatic duct-portal vein fistula. Intra-operative photo showing the exposed portal vein during operative takedown of the pancreatic fistula. The surgical probe is inserted into the fistula tract in the wall of the portal vein (blue asterisk) that extends into the pancreas (black arrow).

Study	Age	Sex	Etoh	Amy/Lip	Diagnostic modalities	Abd pain	DFN	CP	Pseudocyst location	PVT	Treatment
Current study	50	F	Y	190/NR	CT, MRI, ERCP DX=US guided transhepatic portography, surgery	Y	N	Y	Head, Tail	Y	Pancreaticoduodenectomy
Zeller	57	M	Y	NR	autopsy	N	Y	Y	Head	Y	Autopsy
Willis	59	M	N	2000/NR	DX=ERCP CT, portography	Y	Y	Y	None	Y	None, fistula closed spontaneously
Van Steenberg	38	M	Y	266/1015	Dx=ERCP CT, US, portography	Y	N	Y	Head	Y	Conservative
Skarsgard	47	F	Y	29/NR	Autopsy CT, US	Y	N	Y	Head	Y	Autopsy
Hammar	29	M	N	21980/NR	Dx=Surgery CT, ERCP, portography	N	Y	N	Body	NR	Roux-en-y pancreaticojejunostomy
Rasmussen	60	M	Y	0.9/NR	DX=Cholecystography CT	Y	N	Y	NR	N	Cholecystostomy, conservative
Lee	63	M	Y	18500/NR	Autopsy	N	Y	Y	Head, neck, tail	Y	Autopsy
McCormick	36	M	Y	2663/NR	Dx=ERCP US	Y	N	Y	Head	Y	Autopsy
Yoon	43	M	Y	986/2517	Dx=MRCP CT, ERCP	Y	N	Y	Head	NR	Pancreaticocenterostomy
Dawson	61	M	Y	NR	DX=CT US	Y	N	Y	Head	Y	Supportive
Potts	62	M	Y	18860/2460	DX=Surgery CT,	N	Y	N	Head	NR	Pancreaticoduodenectomy
Procacci	36	F	Y	NR	DX=CT guided portography, CT, MRI, ERCP	Y	N	NR	Head	Y	Pancreaticojejunostomy
Riddell	42	F	N	NR	Dx=MRI CT, US	NR	N	Y	Neck	Y	Supportive
Takayama	82	M	Y	1780/960	Cholecystography, CT	Y	NR	Y	Tail	NR	Supportive
Takayama	52	M	Y	972/36	DX=Cholecystography CT	Y	N	NR	Head	Y	Surgical drainage of ascites
Yamamoto	49	M	Y	214/NR	Dx= ERCP US, CT, portography	Y	N	Y	Tail	Y	Supportive

**Table 1:** Literature review of reported pancreatico-portal vein fistulae with epidemiology, important clinical, laboratory, imaging findings and treatment. Abbreviations: DFN= disseminated fat necrosis, CP= Chronic pancreatitis, PVT= portal vein thrombosis, Amy= Amylase, Lip= Lipase.



<b>Etiology</b>	Pseudocyst enzymatic erosion of vessel wall
<b>Incidence</b>	17 reported cases
<b>Gender ratio</b>	3:1 M: F
<b>Age predilection</b>	Range 36-82
<b>Risk factors</b>	<ul style="list-style-type: none"> <li>• Chronic pancreatitis</li> <li>• Chronic ETOH use</li> </ul>
<b>Treatment</b>	<ul style="list-style-type: none"> <li>• Observation if asymptomatic</li> <li>• Surgical takedown of fistula based on patient symptoms</li> </ul>
<b>Prognosis</b>	<ul style="list-style-type: none"> <li>• Good prognosis if fistula is identified and treated, either supportively (8:17 cases), or surgically (5:17 cases).</li> <li>• Prognosis is worse if disseminated fat necrosis occurs or if the fistula is not identified. (4:17 fistulas were diagnosed at autopsy)</li> </ul>
<b>Findings on imaging</b>	<ul style="list-style-type: none"> <li>• Pseudocysts, typically at the head of the pancreas</li> <li>• Fluid attenuation or signal within portal vein</li> <li>• Collateralization of hepatic vessels</li> <li>• Fistula tract from pancreatic duct or pseudocyst to portal vein</li> </ul>

**Table 2:** Summary of pseudocyst-portal vein fistula from literature review.

Diagnosis/Modality	Pancreatic duct portal vein fistula	Portal vein thrombosis	Tumor compression of portal vein
<b>CT</b>	<ul style="list-style-type: none"> <li>• Fluid attenuation portal vein</li> <li>• Pseudocysts may be present</li> <li>• Peri-portal collateral vessels</li> </ul>	<ul style="list-style-type: none"> <li>• Soft tissue attenuation portal vein</li> <li>• Peri-portal collateral vessels</li> </ul>	<ul style="list-style-type: none"> <li>• Peri-portal collaterals</li> <li>• Tumor in porta hepatis</li> <li>• Soft tissue portal vein that may show enhancement.</li> </ul>
<b>MR</b>	<ul style="list-style-type: none"> <li>• Fluid signal portal vein.</li> <li>• Fistula tract may be demonstrated</li> </ul>	<ul style="list-style-type: none"> <li>• Absence of flow void in portal vein.</li> </ul>	<ul style="list-style-type: none"> <li>• Post contrast enhancement of tumor.</li> </ul>
<b>Angiography / venography</b>	<ul style="list-style-type: none"> <li>• May or may not show fistula communication between portal vein and pancreatic duct</li> </ul>	<ul style="list-style-type: none"> <li>• Periportal collaterals in chronic occlusion</li> </ul>	<ul style="list-style-type: none"> <li>• Portal vein filling defect caused by external compression.</li> </ul>
<b>ERCP</b>	<ul style="list-style-type: none"> <li>• May or may not show fistula communication between portal vein and pancreatic duct.</li> <li>• Portal biliopathy may be present from portal hypertension</li> </ul>	<ul style="list-style-type: none"> <li>• Portal biliopathy (i.e. biliary strictures) related to portal hypertension</li> </ul>	<ul style="list-style-type: none"> <li>• Portal biliopathy (i.e. biliary strictures) related to portal hypertension</li> </ul>
<b>US</b>	<ul style="list-style-type: none"> <li>• Complex echogenic fluid within the portal vein</li> <li>• Absent flow</li> <li>• Pseudocysts</li> </ul>	<ul style="list-style-type: none"> <li>• Absent flow</li> </ul>	<ul style="list-style-type: none"> <li>• Portal vein narrowing</li> <li>• +/- thrombosis</li> <li>• Increased flow velocities due to stenosis from external compression</li> </ul>

**Table 3:** Differential diagnosis of Pseudocyst-portal vein fistula with findings by modality.

**ABBREVIATIONS**

- Amy = Amylase  
 CP = Chronic pancreatitis  
 DFN = disseminated fat necrosis  
 ERCP = endoscopic retrograde cholangiopancreatography  
 ERP = endoscopic retrograde pancreatography  
 GGT = gamma-glutamyl transpeptidase  
 Lip = Lipase  
 MRCP = magnetic resonance cholangiopancreatography  
 PTP = percutaneous transhepatic portography  
 PVT = portal vein thrombosis

**KEYWORDS**

pancreatic duct; portal vein; fistula; pseudocyst; pancreatitis; fat necrosis; percutaneous trans-hepatic portography

**Online access**

This publication is online available at:  
[www.radiologycases.com/index.php/radiologycases/article/view/1552](http://www.radiologycases.com/index.php/radiologycases/article/view/1552)

**Peer discussion**

Discuss this manuscript in our protected discussion forum at:  
[www.radiopolis.com/forums/JRCR](http://www.radiopolis.com/forums/JRCR)

**Interactivity**

This publication is available as an interactive article with scroll, window/level, magnify and more features.  
 Available online at [www.RadiologyCases.com](http://www.RadiologyCases.com)

Published by EduRad



[www.EduRad.org](http://www.EduRad.org)