

# A leak too far - Gastro-pleural fistula mimicking recurrence of repaired congenital diaphragmatic hernia following fundoplication

Bhanumathi Lakshminarayanan<sup>1\*</sup>, Robert David Morgan<sup>1</sup>, Kaye Platt<sup>2</sup>, Kokila Lakhoo<sup>1</sup>

1. Department of Paediatric Surgery, John Radcliffe Hospital, Oxford, UK

2. Department of Paediatric Radiology, John Radcliffe Hospital, Oxford, UK

\* **Correspondence:** Miss Bhanumathi Lakshminarayanan, Department of Paediatric Surgery, Level 2, Children's Hospital, John Radcliffe Hospital, Headley Way, Headington, Oxford OX3 9DU, UK  
(✉ [bhanumathi1979@hotmail.com](mailto:bhanumathi1979@hotmail.com))

Radiology Case. 2013 Sep; 7(9):33-38 :: DOI: 10.3941/jrcr.v7i9.1505

## ABSTRACT

Recurrence rate after a congenital diaphragmatic hernia repair is high especially after a patch repair. Recurrence can be asymptomatic, followed by respiratory or gastrointestinal symptoms and the diagnosis is usually confirmed radiologically. We present an unusual case of radiologically diagnosed recurrent left diaphragmatic hernia but at surgery was found to be a gastro-pleural fistula that occurred as a complication following fundoplication surgery.

## CASE REPORT

### CASE REPORT

A female infant born at term and weighing 3.27 Kg was antenatally diagnosed to have left sided Bochdalek type congenital diaphragmatic hernia (CDH). (Fig 1). After an initial period of management in the neonatal intensive care unit for her pulmonary hypertension, which was managed without extracorporeal membrane oxygenation (ECMO), she underwent a surgical repair of the CDH. At laparotomy, it was noted that the diaphragm was severely deficient posteriorly and medially. Hence a patch repair with Gore-Tex was required. It was felt that this would be high-risk for recurrence of the CDH.

She was regularly followed up at 3 to 6 monthly intervals as an out-patient. During this period she showed signs of gastro-oesophageal reflux disease, which manifested mainly as vomiting and poor weight gain not responding to maximal medical therapy. Chest x-rays and barium meal showed no evidence of recurrence of CDH, but evidence confirming severe reflux disease and hiatus hernia. (Fig 2a & 2b).

A Nissen fundoplication and Stamm gastrostomy using a button was performed when she was 2 ½ years of age. This

was done as a laparotomy approach. The stomach was well adherent to the diaphragmatic patch and was difficult to mobilize. She became unwell 48 hours later with respiratory distress. A chest x-ray was done which showed opacification of the left hemithorax with numerous rounded radiolucencies over the left chest that appeared in continuity with similar lucencies in the abdominal left upper quadrant. (Fig 3a & 3b). This was highly suspicious for recurrence of the left diaphragmatic hernia. A contrast study was recommended, but due to instability of the patient, a full contrast study was not possible. A limited study was done by placing water soluble Omnipaque contrast through the gastrostomy followed by x-ray on the ward. This study showed contrast within the left hemithorax and upper abdomen in keeping with recurrent herniation of the small bowel into the chest. (Fig 4)

It was decided to repair the recurrence from the chest due to previous difficulties noted during laparotomy. Contrary to the radiology report, the operative findings showed no diaphragmatic hernia, but a 3mm hole in the diaphragm with contrast in the left hemithorax from a leaking gastrostomy. Washout of the left hemithorax was performed and the diaphragmatic hole closed using non-absorbable sutures. A

further Laparotomy incision was required to identify the leak from the gastrostomy site and repaired. Post-operative recovery was slow mainly due to feeding difficulties.

Further follow-up at 6 weeks in surgical out-patients and subsequent 2 monthly follow-ups with her local physician have shown full clinical recovery and the gastrostomy has now been removed after establishing full oral intake.

## DISCUSSION

Recurrence of diaphragmatic hernia is a known complication following repair of congenital diaphragmatic hernia. The incidence is between 10 - 31% of cases [1,2]. The single most predictor of recurrence is use of patch for repair. In the series from Jancelewicz et al, 46% of all patch repairs had recurrence [1]. According to a multivariate analysis by Fisher et al, comparing 238 patients with recurrence and no recurrence, 67% of all patch repairs had recurrence [2]. The other factors that determine recurrence are - age at repair, length of stay, associated morbidity and type of prosthesis [1,2].

Apart from having a high risk of recurrence, children with a patch repair are prone to increased morbidity from gastro-oesophageal reflux [3,4]. In a series from Koivusalo et al, 42% had incidence of reflux based on endoscopic findings and pH-metry, 60% of these patients had patch repair [3]. In a similar study, Su et al, found 54% reflux in their series [4]. Anti-reflux surgery will be required in 5-25% [3-5]. In our patient, the majority of the diaphragm was deficient and after the initial surgery she was frequently monitored for recurrence. As in most other patients with CDH with patch repair, our patient underwent fundoplication for gastro-oesophageal reflux. It was necessary to place the gastrostomy for better feeding due to failure to thrive.

As the child became unwell and chest x-ray showed rounded radiolucencies in the left hemithorax, recurrence of left sided diaphragmatic hernia was felt to be the most possible diagnosis. However, similar features can also be seen in empyema. As per the intra-operative findings, this was established to be an iatrogenic gastropleural fistula from a gastrostomy leak through a small 3 mm defect in the diaphragm. This occurred at the time of the fundoplication surgery. On further enquiry, it came to light that the gastrostomy button became partially dislodged on the first post-operative day when the tubing got caught in the patient's bed.

A gastro-pleural fistula can present radiologically as hydro-pneumothorax with empyema like features. The gastro-pleural fistula in this case was mimicking a recurrence of the diaphragmatic hernia. Previously published gastro-pleural fistulas have been case reports describing gastric perforation after lung resection, complication of a traumatic diaphragmatic hernia with necrosis of incarcerated stomach, malignancy, and iatrogenic causes such as placement of nasogastric tube and chest drain insertion [6-13]. A summary of this condition is detailed in Table 1.

There are no previous described cases of gastro-pleural fistulas in the setting of previous repair of congenital diaphragmatic hernia or Nissen fundoplication done through an abdominal approach. Mansour et al in their article have reported complications of Nissen fundoplication done as a transthoracic procedure. In this case series, the fundoplication wrap that were left in the chest were prone to complications such as gastric rupture causing gastro-bronchial fistula in 1 case and gastro-pleural fistula in 2 cases leading to mortality [14]. The authors condemn the practice of leaving the fundoplication wrap in the chest. In our report, the gastro-pleural fistula occurred in spite of the laparotomy approach. The reason for this could be that the 3 mm defect occurred accidentally during separation of dense adhesions from the previously repaired left diaphragm. The further dislodgement of the gastrostomy button led to leaking of gastric contents through this defect leading to gastro-pleural fistula.

The other differential diagnosis to be considered in a similar case will be iatrogenic diaphragmatic hernia or traumatic diaphragmatic hernia. Clinical and radiological features for the various pathologies are described in Table 2.

This case particularly proved a radiological challenge, as the limited images resembled recurrence of diaphragmatic hernia. In retrospect, a full contrast study in the radiological department might have been less challenging.

In conclusion, recurrent diaphragmatic hernia is still the most common complication following a patch repair.

## TEACHING POINT

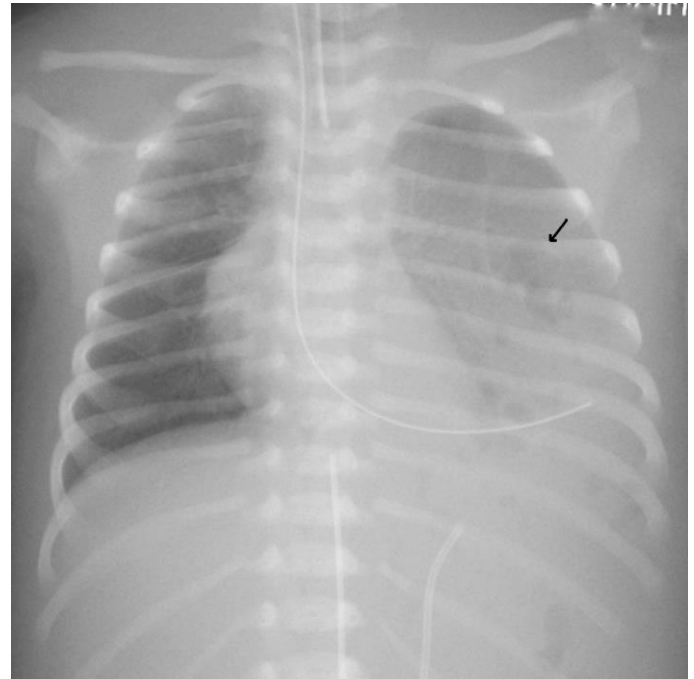
Gastro-pleural fistula can occur as a complication following difficult fundoplication. Radiographs can have features of radiolucencies or air fluid level in the chest. In the setting of a previously repaired congenital diaphragmatic hernia, these imaging features can mimic recurrence of diaphragmatic hernia.

## REFERENCES

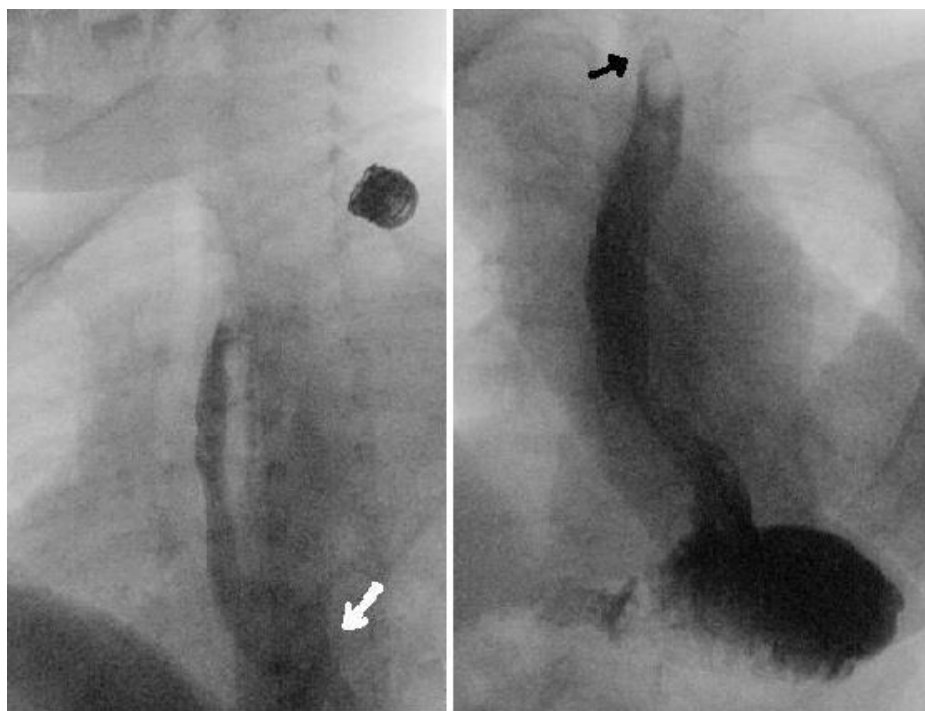
1. Jancelewicz T., Vu L. T., Keller R. L., Bratton B., Lee H., Farmer D., Harrison M., Miniati D., Mackenzie T., Hirose S. & Nobuhara K. Long-term surgical outcomes in congenital diaphragmatic hernia: observations from a single institution. *J Pediatr Surg*, 2010, 45, 155-160. PMID: 20105597
2. Fisher J. C., Haley M. J., Ruiz-Elizalde A., Stolar C. J. H., Arkovitz M. S. Multivariate model for predicting recurrence in congenital diaphragmatic hernia. *J Pediatr Surg*, 2009, 44, 1173-1180. PMID: 19524735
3. Koivusalo A. I., Pakarinen M. P., Lindahl H. G., Rintala R. J. The cumulative incidence of significant gastroesophageal reflux in patients with congenital diaphragmatic hernia-a systematic clinical, pH-metric, and endoscopic follow-up study. *J Pediatr Surg*, 2008, 43, 279-282. PMID: 18280274

4. Su W., Berry M., Puligandla P. S., Aspirot A., Flageole H., Laberge J.-M. Predictors of gastroesophageal reflux in neonates with congenital diaphragmatic hernia. *J Pediatr Surg*, 2007, 42, 1639-1643. PMID: 17923189
5. Rocha G., Azevedo I., Pinto J. C., Guimaraes H. Follow-up of the survivors of congenital diaphragmatic hernia. *Earl Hum Dev*, 2012, 88, 255-258. PMID: 21945360
6. Takeda S., Funaki S., Yumiba T., Ohno K. Gastropleural fistula due to gastric perforation after lobectomy for lung cancer. *Interact Cardiovasc Thorac Surg*, 2005, 4, 420-422. PMID: 17670447
7. O'Keefe P. A., Goldstraw P. Gastropleural fistula following pulmonary resection. *Thorax*, 1993, 48, 1278-1279. PMID: 8303639
8. Schwab R. J., Jarcik J. G. Tension pneumothorax secondary to a gastropleural fistula in a traumatic diaphragmatic hernia. *Chest*, 1991, 99, 247-249. PMID: 1984967
9. Adachi Y., Sato Y., Yasui H., Nishimura S., Tanimura A., Yuasa H., Ishi Y., Imai K., Kata Y. Gastropleural fistula derived from malignant lymphoma. *J Gastroenterol*, 2002, 37, 1052-1056. PMID: 12522538
10. Warburton C. J., Calverley P. M. Gastropleural fistula due to gastric lymphoma presenting as tension pneumothorax and empyema. *Eur Respir J*, 1997, 10, 1678-1679. PMID: 9230265
11. Dias O. M., Barbosa C. C., Teixeira L. R., Vargas F. S. Gastropleural fistula from gastric perforation due to renal cell carcinoma after bevacizumab chemotherapy: a case report. *Clinics (Sao Paulo)*, 2011, 66, 1495-1498. PMID: 21915507
12. Bini A., Grazia M., Petrella F., Stella F., Bazzocchi R. Spontaneous biliopneumothorax (thoracobilia) following gastropleural fistula due to stomach perforation by nasogastric tube. *Ann Thorac Surg*, 2004, 78, 339-341. PMID: 15223464
13. Darbari A., Tandon S., Singh G. P. Gastropleural fistula: rare entity with unusual etiology. *Ann Thorac Med*, 2007, 2, 64-65. PMID: 19727349
14. Mansour K. A., Burton H. G., Miller J. I Jr., Hatcher C. R Jr. Complications of intrathoracic Nissen fundoplication. *Ann Thorac Surg*. 1981, 32, 173-178. PMID: 7259357
15. Calder A., Owens C. M. Imaging of parapneumonic pleural effusions and empyema in children. *Pediatr Radiol*. 2009, 39, 527-537. PMID: 19198826
16. De Lange C. Radiology in paediatric non-traumatic thoracic emergencies. *Insights Imaging*. 2011, 2, 585-598. PMID: 22347978
17. Eren S., Ciris F. Diaphragmatic hernia: diagnostic approaches with review of the literature. *Eur J Radiol*. 2005, 54, 448-459. PMID: 15899350
18. Eren S., Kantarci M., Okur A. Imaging of diaphragmatic rupture after trauma. *Clin Radiol*. 2006, 61, 467-477. PMID: 16713417

FIGURES

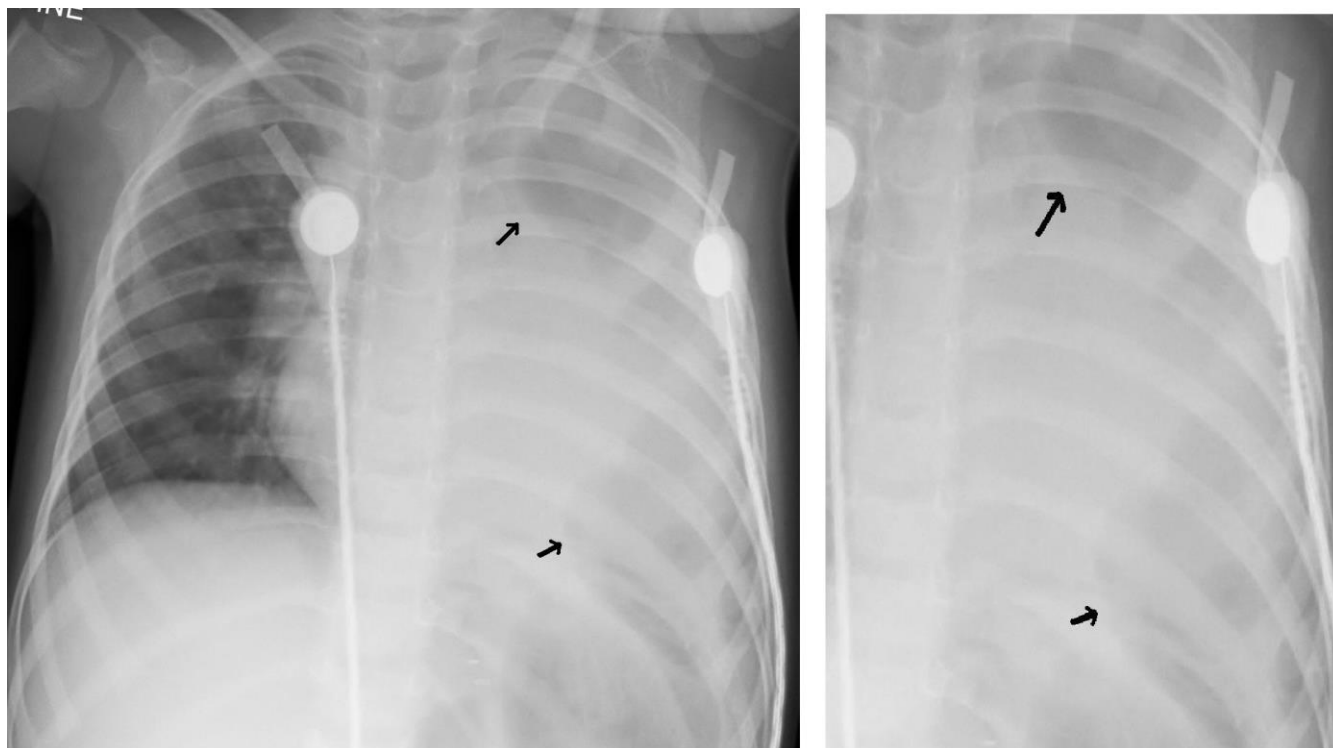


**Figure 1:** Supine, AP view of plain chest x-ray of a neonate showing congenital left sided diaphragmatic hernia. The black arrow points at the radiolucencies in the left side of the chest in continuity with the abdomen indicating bowel loops in the chest. The naso-gastric tube is also in the left hemithorax indicating that the stomach has also herniated into the chest. There is mediastinal shift to the right and the left costophrenic angle is obliterated. The x-ray also shows a well placed endotracheal tube, umbilical artery and umbilical venous catheters.

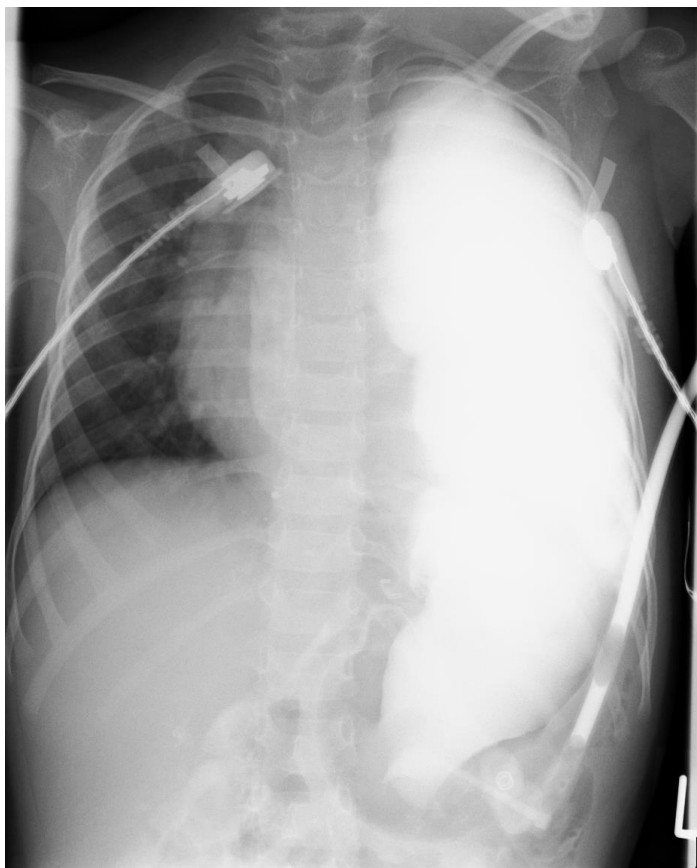


**Figure 2:** 2 ½ year old girl with previous patch repair of left congenital diaphragmatic hernia done during neonatal period. This is a Barium swallow and meal performed to identify cause for persistent vomiting. Figure 2a is a fluoroscopy image taken in an oblique view demonstrating a delay in oesophageal emptying to the stomach and a posterolateral angulation of the oesophageal-gastric junction suggestive of a hiatus hernia (white arrow).

Figure 2b is a fluoroscopy image taken towards the end of the Barium study showing a high level reflux up to the level of the heads of clavicle (black arrow) via a wide open oesophageal-gastric junction.



**Figure 3:** 2 ½ year old girl with previous patch repair of left congenital diaphragmatic hernia done during neonatal period. This is a Supine position, AP view of plain chest x-ray done after anti-reflux surgery. The x-ray shows numerous rounded radiolucencies (arrows) over the left chest that appear in continuity with similar lucencies in the abdominal left upper quadrant. Figure 3a shows the original chest x-ray and figure 3b has been magnified to illustrate the radiolucencies in the left chest (arrows).



**Figure 4 (left):** 2 1/2 year old girl with previous patch repair of left congenital diaphragmatic hernia done during neonatal period. Supine position, AP view chest radiograph taken as a portable film in intensive care five minutes after instillation of water soluble Omnipaque contrast via the gastrostomy. Radiograph shows opacification within the left hemithorax and upper abdomen in keeping with recurrent herniation of the small bowel into the chest. There is minimal mediastinal shift to the right.

<b>Etiology</b>	Acquired - iatrogenic or traumatic
<b>Incidence</b>	Rare, this is the first case in setting of congenital diaphragmatic hernia and fundoplication
<b>Gender ratio</b>	No predilection
<b>Age predilection</b>	None
<b>Risk factors</b>	Lung resection, traumatic diaphragmatic hernia, malignancy, nasogastric tube placement, chest drain insertion
<b>Treatment</b>	Surgical treatment depending on the cause
<b>Prognosis</b>	Depends on underlying pathology
<b>Imaging findings</b>	X ray features of hydropneumothorax or empyema. Upper GI contrast study can be conclusive

**Table 1:** Summary table of gastro-pleural fistula

Condition	Clinical features	Radiological features
<b>Recurrence of diaphragmatic hernia [1,2]</b>	Progressive respiratory symptoms in a previously repaired diaphragmatic hernia. Risk of recurrence more than 40% if previous repair using patch.	Chest x-ray diagnostic with radiolucencies suggestive of bowel in chest in the same side as previous diaphragmatic hernia. If not clear, CT scan or contrast meal can be performed to show bowel loops in chest.
<b>Empyema thoracis [15,16]</b>	Features of sepsis. Respiratory signs and symptoms.	Chest x-ray showing pleural effusion with consolidation. Loculated effusion may show radiolucency. Ultrasound of chest is more accurate to confirm collection and for drainage. Contrast enhanced CT scan might be required in special circumstances and complicated cases.
<b>Iatrogenic diaphragmatic hernia [17]</b>	Progressive respiratory symptoms and there might be features of bowel obstruction or bowel ischaemia following injury to diaphragm during surgical procedures involving chest or upper abdomen.	Chest x-ray diagnostic with radiolucencies or air-fluid level suggestive of bowel in chest. Ultrasound will show diaphragmatic discontinuity and herniated organs. Upper GI contrast study may help to show bowel loops in the chest. CT scan is diagnostic and will show diaphragmatic discontinuity, intrathoracic herniation of abdominal contents, and waistlike constriction of mesenteric folds (the “collar sign”). Features of intestinal obstruction or strangulation can be visualized on CT scan.
<b>Traumatic diaphragmatic hernia [17,18]</b>	History of blunt abdominal trauma, such as, road traffic accident or fall from height or penetrating trauma. Other associated organ injury. There could be progressive respiratory symptoms or features of bowel obstruction or ischaemia. Delayed presentation.	Chest x-ray may be normal in initial stages. Associated rib fractures can be seen. Presence of visceral gas within the thorax is pathognomonic. Upper GI contrast study may help to show bowel loops in the chest. Ultrasound will show diaphragmatic discontinuity and herniated organs. CT scan is diagnostic and will show diaphragmatic discontinuity, intrathoracic herniation of abdominal contents, and waistlike constriction of mesenteric folds (the “collar sign”). Other abdominal organ injury can be detected on CT scan. MRI scan may be occasionally required in selected patients.
<b>Gastro-pleural fistula [6-13]</b>	Requires a high index of suspicion as features can mimic empyema or diaphragmatic hernia. Most cases reported are secondary to iatrogenic causes.	Chest x-ray may show hydro-pneumothorax. CT scan might help to exclude other pathologies. Contrast study can be diagnostic to show communication between stomach and thoracic cavity.

**Table 2:** Differential diagnosis table for gastro-pleural fistula

**ABBREVIATIONS**

CDH = congenital diaphragmatic hernia  
ECMO = extracorporeal membrane oxygenation

**KEYWORDS**

Congenital diaphragmatic hernia; recurrence; gastro-pleural fistula

**Online access**

This publication is online available at:  
[www.radiologycases.com/index.php/radiologycases/article/view/1505](http://www.radiologycases.com/index.php/radiologycases/article/view/1505)

**Peer discussion**

Discuss this manuscript in our protected discussion forum at:  
[www.radiopolis.com/forums/JRCR](http://www.radiopolis.com/forums/JRCR)

**Interactivity**

This publication is available as an interactive article with scroll, window/level, magnify and more features.  
Available online at [www.RadiologyCases.com](http://www.RadiologyCases.com)

Published by EduRad



[www.EduRad.org](http://www.EduRad.org)