

Metastatic Deposit In The Skull


Kai-hung Fung, MBBS, FRCR

Radiology Department, Pamela Youde Nethersole Eastern Hospital, 3 Lok Man Road, Chai Wan, Hong Kong, China

✉ khfung@ha.org.hk

Radiology Case. 2009 Feb; 3(2):1-2 :: DOI: 10.3941/jrcr.v3i2.136

INTERESTING IMAGE



METASTATIC DEPOSIT IN THE SKULL © Kai-hung Fung, 2009

Artistically rendered 3D computed tomography (CT)

An inside view of the skull bone near the vertex showing the spoke wheel pattern of bony destruction from metastatic deposit in the skull vault originating from carcinoma of thyroid in a 76 years old lady. The original cross-sectional CT image is shown in figure 2 below.

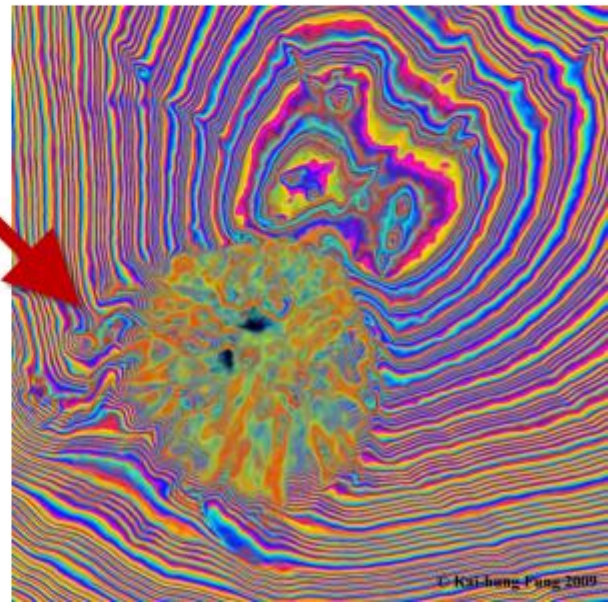
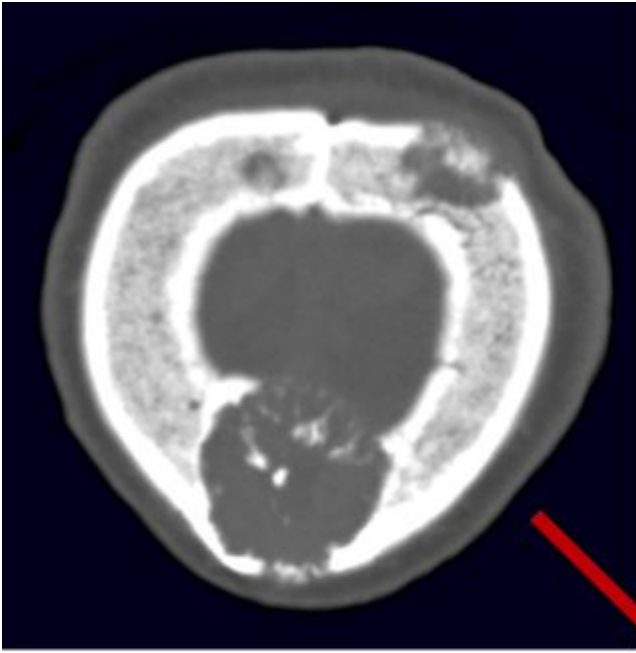


Figure 2: Axial CT scan of the skull near the vertex showing metastatic deposits from carcinoma of thyroid (top). The artistically rendered 3D computed tomography (CT) is shown to the right.

URL of this article:
www.radiologycases.com/index.php/radiologycases/article/view/136

Published by EduRad



www.EduRad.org