

Rare case of urinary bladder agenesis - Multislice CT abdomen imaging

Venkatraman Indiran^{1*}, Kabilan Chokkappan², Emmanuel Gunaseelan²

1. Department of Radiodiagnosis, Sree Balaji Medical College and Hospital, Chennai, India

2. Department of Radiodiagnosis, Bharat Scans, Chennai, India

* **Correspondence:** Venkatraman Indiran, Department of Radiodiagnosis, Sree Balaji Medical College and Hospital, 7 Works Road, Chromepet, Chennai -600044, Tamilnadu, India
(✉ ivraman31@gmail.com)

Radiology Case. 2013 Feb; 7(2):44-49 :: DOI: 10.3941/jrcr.v7i2.1326

ABSTRACT

Complete agenesis of urinary bladder is an extremely rare anomaly with only a few live cases reported so far. In most of the instances death occurs early as it may be incompatible with life. Here we report a case of adolescent female with urinary bladder and unilateral renal agenesis, who presented with a rather unusual presentation of incontinence, for a computed tomography (CT) examination. Other congenital abnormalities visualised in the CT abdomen are also discussed.

CASE REPORT

CASE REPORT

A 12 year old female patient presented with a history of urinary incontinence for the last four years and itching in the vulval and perineal region for the last 6 months. The history was quite unreliable considering the fact that the patient and her parents were illiterate. There was also history of white discharge per vagina. Patient was poorly nourished; no other significant abnormality was found on the systemic examination. Local examination revealed slow leak of clear fluid into the vagina; vaginitis was also seen. Basic blood workup like complete blood count, blood urea and serum creatinine were unremarkable. Patient was sent to us for 64 Slice CT abdomen to rule out ectopic ureter as the cause for incontinence.

Plain CT followed by arterial, venous and excretory phase images was obtained (Brilliance 64, Philips Healthcare, Veenpluis, Netherlands). Right kidney along with right renal artery, vein and ureter was absent [Fig.1]. Left kidney was orthotopic in location and mildly enlarged but showed normal enhancement of parenchyma and prompt excretion of contrast [Fig.2]. Left kidney was supplied by an accessory artery apart from the left renal artery [Fig.3]. Left calyceal system was minimally dilated. Gradually increasing dilatation of mid and lower thirds of the left ureter was seen [Fig. 4]. Lower end of

the left ureter was seen ending ectopically into anterior wall of vagina. Urinary bladder was not visualized [Fig.5].

Uterus appeared small in size and only the left horn was visualised [Fig.6]. Ovaries were normal in position and morphology except for a small functional cyst in the left ovary.

A few anatomical variations of the vascular tree were seen. High bifurcation of the abdominal aorta at the level of L3-L4 interspace was seen [Fig.7]. The artery corresponding to posterior trunk of right internal iliac artery was seen arising from right external iliac artery [Fig 8].

Developmental dysplasia of the right hip joint with superiorly migrated dysplastic femoral head was seen with associated atrophy of the gluteal and thigh muscles [Fig. 9].

At the time of writing, the patient is on treatment for urinary tract infection, she developed subsequently and is awaiting surgery.

DISCUSSION

Anomalies of the urogenital tract are among the most common organ system anomalies found in the fetus or neonate. However, complete agenesis of urinary bladder, is one of the rarest urinary tract anomalies and has been reported in a very few live individuals. Reported incidence rate is approximately 1 in 600000. As of 2012, about 61 cases have been reported with only 23 being viable births [1]. These patients have very poor survival rate because of the associated pathologies in other organ systems (reproductive tract, orthopedic, neurological and vascular). Our patient had a few incidental variations of intraabdominal vasculature and orthopedic abnormality of developmental dysplasia apart from an abnormal uterus. Our patient was also a female as were most of the previously described cases (Female to male ratio ~ 30:1). Possible cause for this gender difference is the fact that ectopic drainage of the urine into vagina, uterus or vestibule offers little resistance to the passage of urine, thereby aiding in preservation of the renal function.

Lack of assimilation of mesonephric ducts and ureters into the trigone which prevents filling and distension of urine in the bladder may cause consequent loss of the anterior division of cloaca (urogenital sinus) and possibly result in agenesis of bladder. Posterior division of the cloaca (anorectum) is usually normal and hence the hindgut is usually normal [2].

The reason for the survival in our patient was due to the normal function of the orthotopic left kidney, which showed normal enhancement and excretion of contrast. However the left kidney showed mild pelvicalyceal system dilatation and significant dilatation of distal half of left ureter, which may represent vesicoureteric reflux / primary megaureter.

Our patient presented with history of frequent dribbling of urine and itching in the vulva and perineum. The causes of urinary incontinence in young girls include vesicovaginal reflux, extravesical infrasphincteric ectopic ureteral orifice, spinal dysraphism, sacral agenesis and very rare causes like female epispadias and urinary bladder agenesis [3, 4, 5], apart from the functional causes.

It is imperative to image any child with incontinence to rule out underlying structural disorders. This was emphasized by Glenn [6] as early as in 1959.

Contrast enhanced CT abdomen with arterial, portal and excretory phase images could be a one stop shop for identifying all the urinary tract anomalies and providing exquisite structural detail about urinary tract as well as other associated intraabdominal anomalies. Non enhanced CT images can demonstrate gross anatomy of the renal system and show findings like calculi / calcification. Arterial phase images can provide details about the vascular tree of the renal as well as other systems. Portal phase images can demonstrate the enhancement pattern of kidneys. Excretory phase images can provide excellent detail of the course, caliber and lumen of the ureters. Delayed images can provide beautiful cystogram images resembling cystoscopy images. MR imaging with MR urography can also be a useful modality if there is a need for

avoiding radiation and iodinated contrast [7]. Ultrasonography can only raise the question of a structural abnormality but it can give neither adequate detail of the ureters nor any information about renal function. Nuclear scans can aid in assessing the function of kidneys but cannot give adequate structural detail; hence it has to be correlated in the light of other imaging findings. Of the conventional modalities, retrograde ureterography and pyelography is useful to study the anatomy of ureter and kidneys [2].

In patients with bladder agenesis, the initial treatment is urinary diversion to save renal function, which may be followed by complex urogenital construction at a later age when appropriate [8].

TEACHING POINT

Though urinary bladder agenesis is very rare, it should be kept in mind in the list of differentials for any case of incontinence, especially if there is lack of adequate filling of urinary bladder. Contrast enhanced CT abdomen including excretory phase images could be offered for further workup.

REFERENCES

1. Syed Muhammad Nazim, Zafar Zaidi. Bilateral ectopic ureters with bladder agenesis. *J Pak Med Assoc* 2012 Oct; 62(10) 1086 -1089.
2. Krull CL, Heyns CF, de Klerk DP. Agenesis of the bladder and urethra: a case report. *J Urol*. 1988 Oct;140(4):793-4. PMID: 3418800.
3. Warade M, Majid Y, Dayananda L, Gupta K. Vesicovaginal reflux: A case report. *Indian J Radiol Imaging*. 2009 Jul-Sep;19(3):235-7. PMID: 19881094.
4. Braverman RM, Lebowitz RL. Occult ectopic ureter in girls with urinary incontinence: diagnosis by using CT. *AJR Am J Roentgenol*. 1991 Feb;156(2):365-6. PMID: 1898815.
5. Singh DR, Sagade SN. Female epispadias. *Indian J Urol* 2000; 16:163-4.
6. Glenn JF. Agenesis of the bladder. *J Am Med Assoc*. 1959 Apr 25; 169(17):2016-8. PMID: 13640964.
7. Chen CY, Tsao TF, Chang HM et al. Bladder agenesis and bilateral ectopic ureters draining into the vagina in a female infant: demonstrated by MR imaging. *Surg Radiol Anat*. 2012 Jan; 34(1):89-92. Epub 2011 Jun 19. PMID: 21688139.
8. Adams MC, Joseph DB. Urinary tract reconstruction in children. In: Wein AJ, Kavoussi LR, Novick AC, Partin AW, Peters CA, editors. *Campbell-Walsh Urology*. 9th ed. Saunders-Elsevier; 2007. pp. 3656-702.

FIGURES

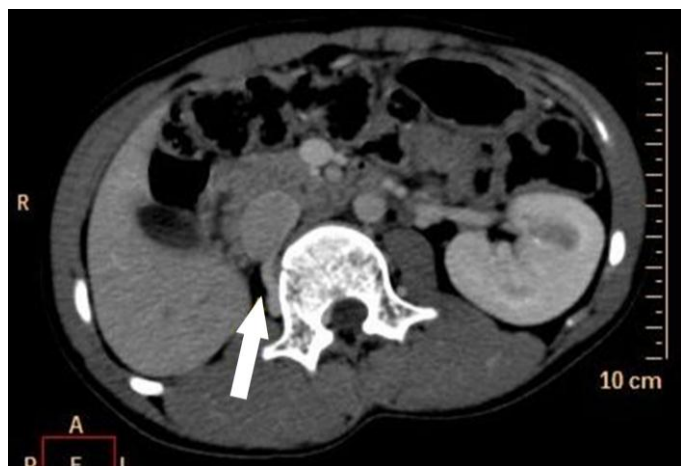

Figure 1: 12 year old female with urinary bladder and right renal agenesis. Contrast enhanced CT abdomen in portal phase shows empty right renal fossa (arrow) and normally enhancing orthotopic left kidney. Protocol: Philips Brilliance 64 slice CT 200 mAs, 120 kV, 1.5 mm slice thickness, 45 ml Omnipaque.

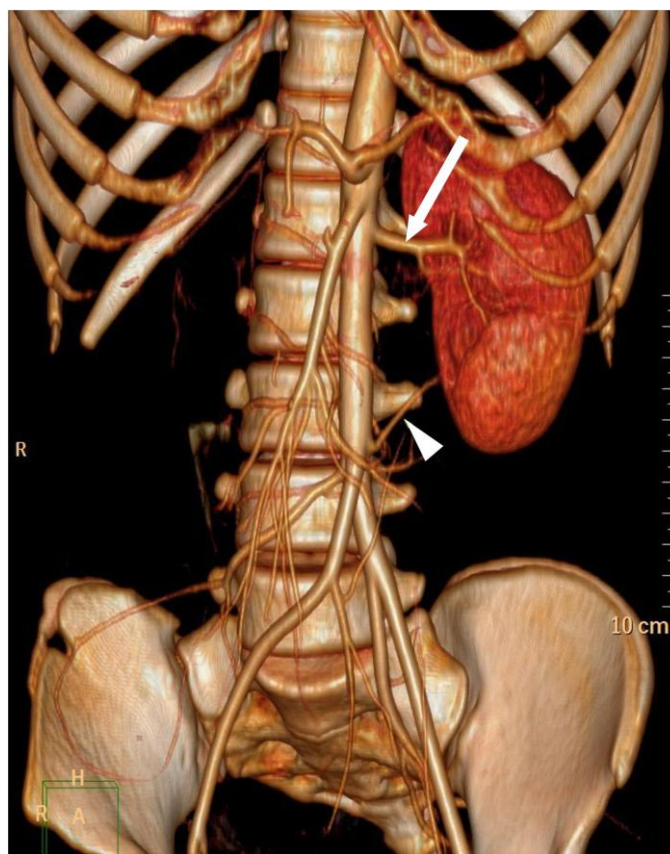


Figure 3 (top): 12 year old female with urinary bladder and right renal agenesis. Contrast enhanced CT abdomen in arterial phase with volume rendered image shows the left main renal artery (arrow) arising at L1 level and an accessory left renal artery (arrowhead) arising at L3 level. Protocol: Philips Brilliance 64 slice CT 200 mAs, 120 kV, 1.5 mm slice thickness, 45 ml Omnipaque.

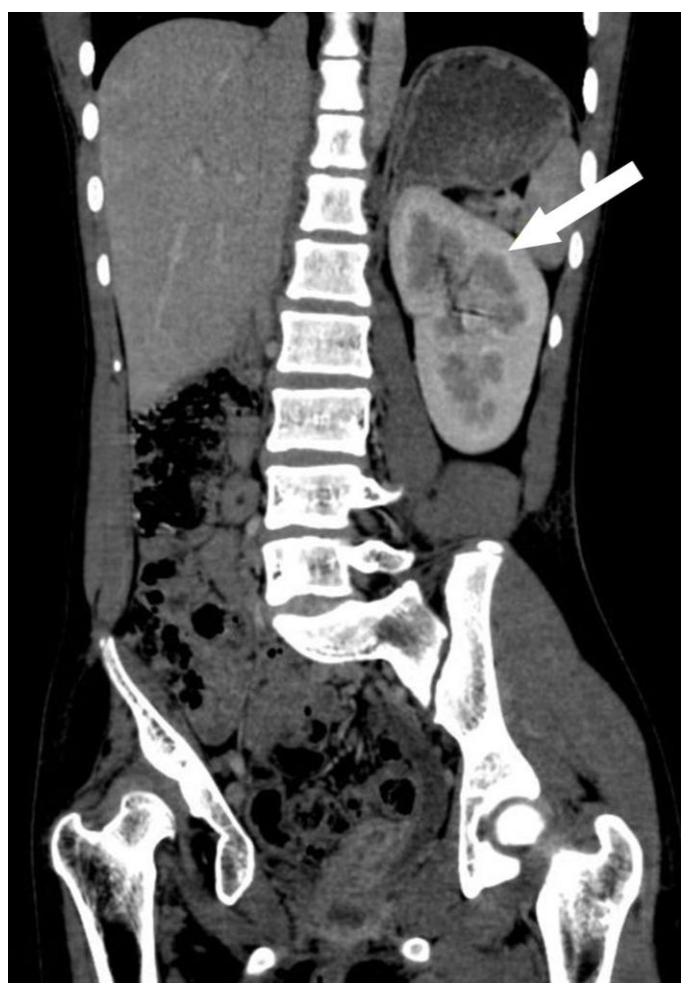

Figure 2 (left): 12 year old female with urinary bladder and right renal agenesis. Contrast enhanced CT abdomen in portal venous phase and multiplanar coronal reformat shows orthotopic mildly enlarged left kidney (arrow) showing normal enhancement of parenchyma. Odd positioning is due to dysplastic right hip. Protocol: Philips Brilliance 64 slice CT 200 mAs, 120 kV, 3 mm slice thickness, 45 ml Omnipaque.

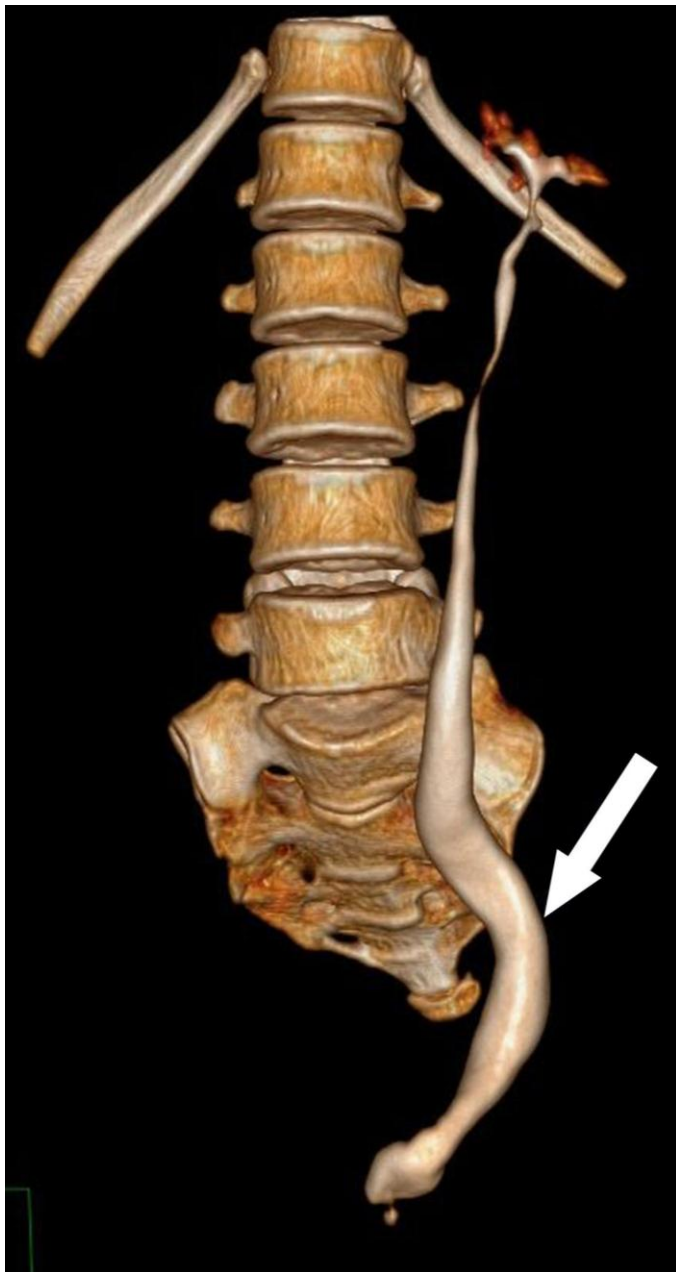

Figure 4: 12 year old female with urinary bladder and right renal agenesis. Contrast enhanced CT abdomen in excretory phase with volume rendered image shows the gradually increasing dilatation mid and lower thirds of the left ureter (arrow) with absence of urinary bladder. Protocol: Philips Brilliance 64 slice CT 200 mAs, 120 kV, 1 mm slice thickness, 45 ml Omnipaque

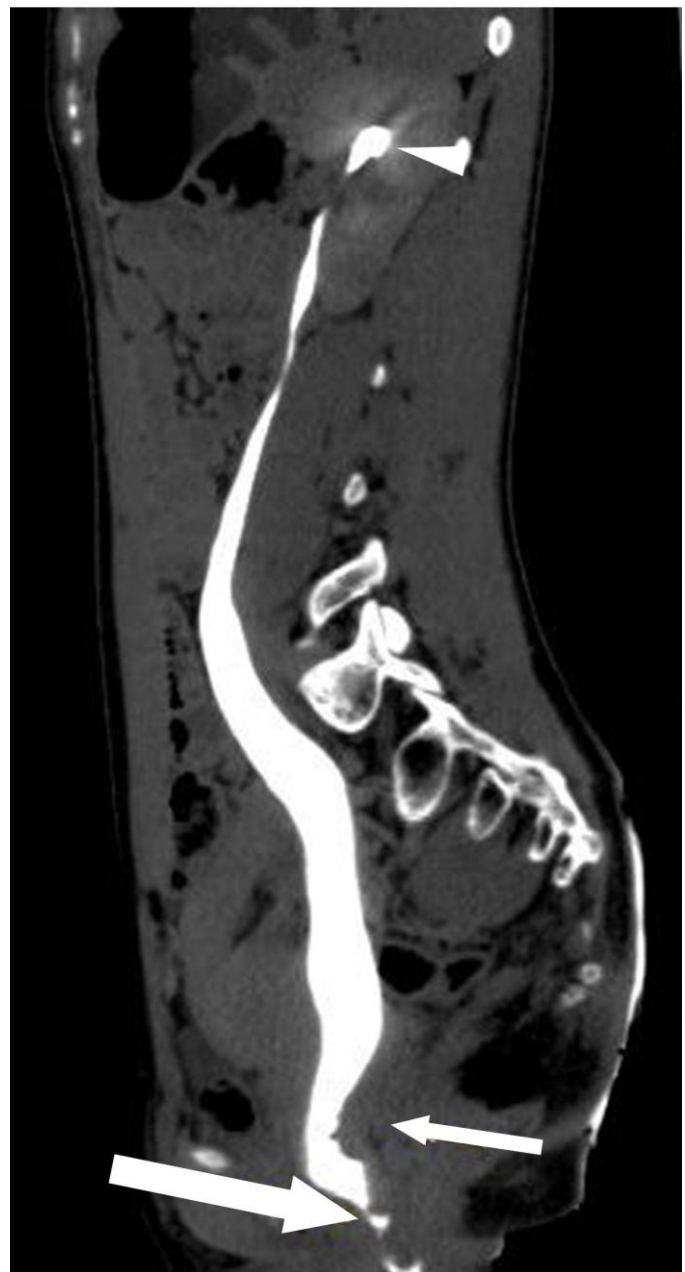

Figure 5: 12 year old female with urinary bladder and right renal agenesis. Contrast enhanced CT abdomen in excretory phase with curved multiplanar image shows lower end of left ureter ending ectopically into anterior wall of vagina (thick arrow) with absence of urinary bladder. Thin arrow represents the cervix. Arrowhead represents the minimal dilated upper pole calyx. Protocol: Philips Brilliance 64 slice CT 200 mAs, 120 kV, 1mm slice thickness, 45 ml Omnipaque

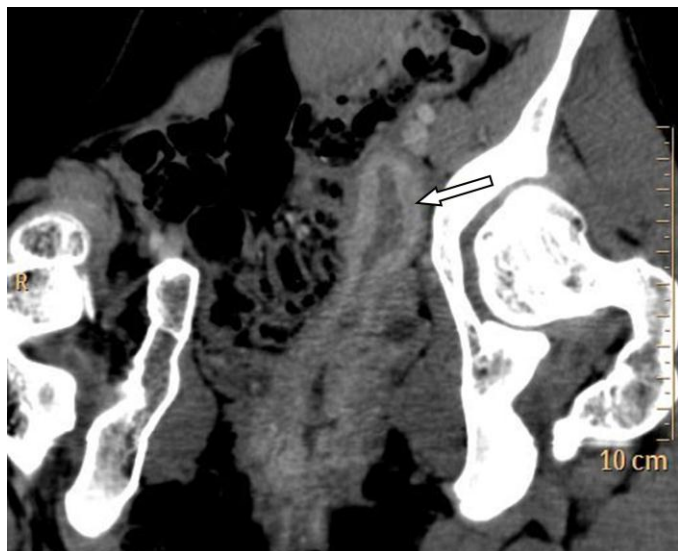


Figure 6: 12 year old female with urinary bladder and right renal agenesis. Contrast enhanced CT abdomen in venous phase with curved multiplanar image shows a small uterus with only the left horn being visualised (arrow). Protocol: Philips Brilliance 64 slice CT 200 mAs, 120 kV, 1.5 mm slice thickness, 45 ml Omnipaque

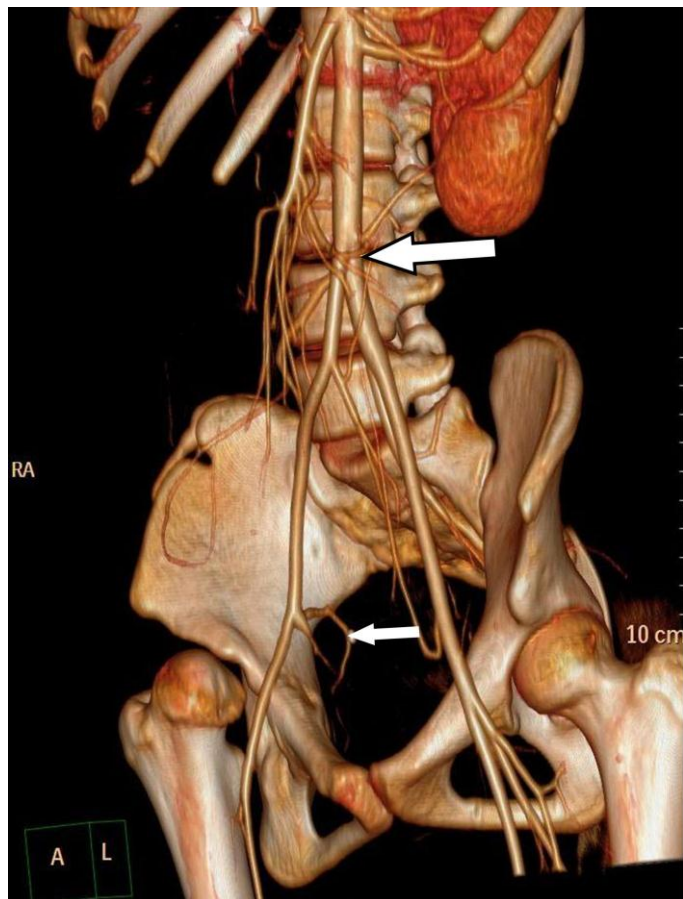


Figure 7 (top): 12 year old female with urinary bladder and right renal agenesis. Contrast enhanced CT abdomen in arterial phase with volume rendered image shows high bifurcation of abdominal aorta (large arrow) and artery corresponding to posterior trunk of right internal iliac artery arising from right external iliac artery (small arrow). Protocol: Philips Brilliance 64 slice CT 200 mAs, 120 kV, 3 mm slice thickness, 45 ml Omnipaque.

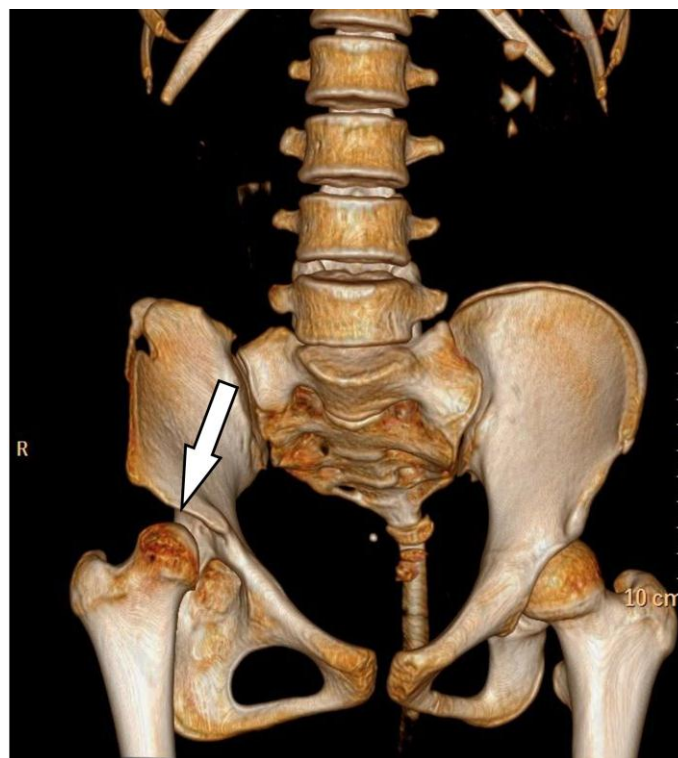


Figure 8 (left): 12 year old female with urinary bladder and right renal agenesis. Contrast enhanced CT abdomen in excretory phase with volume rendered image shows developmental dysplasia of right hip joint with superiorly migrated dysplastic femoral head (arrow). Protocol: Philips Brilliance 64 slice CT 200 mAs, 120 kV, 1.5 mm slice thickness, 45 ml Omnipaque.

Etiology	Lack of assimilation of mesonephric ducts and ureters into the trigone prevents filling and distension of urine in the bladder, causes loss of the anterior division of cloaca (urogenital sinus) and possibly result in agenesis of bladder
Incidence	Very rare ; 1:600000; only about 61 reported cases so far
Gender ratio	Female > male ; approximately 30:1
Age predilection	Congenital ; Presentation – from birth till adulthood
Risk factors	N/A
Treatment	Initial treatment is urinary diversion to save renal function; followed with complex urogenital construction later.
Prognosis	Depends on the renal function and associated anomalies
Findings on imaging	Contrast enhanced CT abdomen: Absent right kidney and ureter. Orthotopic mildly enlarged left kidney showing normal enhancement prompt excretion of contrast. Minimally dilated left pelvicalyceal system. Left ureteric dilatation gradually increasing from upper to lower segment. Lower end of ureter ending ectopically into anterior wall of vagina. Absent urinary bladder. Smaller bicornuate uterus with atrophic right horn. High bifurcation of abdominal aorta and other incidental anatomical vascular variations Developmental dysplasia of right hip joint

Table 1: Summary table for urinary bladder agenesis

Diagnosis	CT abdomen findings
Urinary bladder agenesis	Absent urinary bladder Ectopic ureteric insertion in vagina, uterus or vestibule Other genitourinary, vascular and orthopedic abnormalities, if any.
Extravesical infraspincteric ectopic ureteral orifice	Normal urinary bladder Ectopic ureteric insertion in vagina, uterus or vestibule
Vesicovaginal reflux	Contrast filling the vagina on pre void images with emptying on the post void images (excretory phase images) No abnormal fistulous communication between genital and urinary tract.
Spinal dysraphism and sacral agenesis	Bony abnormalities well depicted.

Table 2: Differential diagnosis table for urinary bladder agenesis**ABBREVIATIONS**

CT - Computed tomography

KEYWORDS

Urinary bladder agenesis; computed tomography; urinary incontinence

ACKNOWLEDGEMENTS

I would like to thank Dr. Premkumar for help in image compilation.

Online accessThis publication is online available at:
www.radiologycases.com/index.php/radiologycases/article/view/1326**Peer discussion**Discuss this manuscript in our protected discussion forum at:
www.radiopolis.com/forums/JRCR**Interactivity**This publication is available as an interactive article with scroll, window/level, magnify and more features.
Available online at www.RadiologyCases.com

Published by EduRad

www.EduRad.org