

# Solitary epidural brain metastasis of a peripheral neuroepithelioma (a primitive neuroectodermal tumor): a case report

Atoosa Adibi<sup>1</sup>, Roozbeh Barikbin<sup>1</sup>, Navid Koleini<sup>1\*</sup>, Maryam Farghadani<sup>1</sup>, Kourosh Mougouei<sup>1</sup>, Farnaz Farshidfar<sup>1</sup>

1. Department of Radiology, Saint Alzahra hospital, Isfahan University of medical sciences

\* **Correspondence:** Navid Koleini Department of Radiology, Saint Alzahra hospital, Isfahan University of medical sciences, Sofeh Avenue, 0098 Isfahan, Iran. (✉ [navid\\_koleini@yahoo.com](mailto:navid_koleini@yahoo.com)) :: Phone: +98 913 327 4826 :: Fax: +98 311 6251065

Radiology Case. 2008 Jul; 2(1):16-19 :: DOI: 10.3941/jrcr.v2i1.13

## ABSTRACT

A 14 year old male was referred to a CT scan at our hospital for evaluation of headache. The patient was a known case of cervical soft tissue primitive neuroectodermal tumor (PNET) who has undergone surgery and radiotherapy 4 years ago. CT scan showed a large solitary extra axial, epidural lesion in the right parietal region, with mass effect and bony involvement. Subsequently, surgery was performed and the resultant biopsy was neuroepithelioma. After diagnosis the patient has undergone chemotherapy and radiotherapy. He remained symptom free, and also follow up CT scans of the brain, chest, and abdomen were normal after two years post surgery. This is the first reported case of epidural metastasis of a head and neck (peripheral) PNET.

## INTRODUCTION

Primitive neuroectodermal tumors (PNETs) include a heterogeneous group of tumors thought to originate from primitive or undifferentiated neuroepithelial cells that typically occur in pediatric patients (Ref. 1). PNETs usually have an aggressive behavior and common sites of metastases are the lungs and skeletal system (Ref. 2). However, metastases to the epidural space have not been reported yet. In this case report we describe an epidural brain metastasis of a head and neck, peripheral PNET.

## CASE REPORT

A 14 year old male was referred to a CT (computed tomography) scan at our hospital by the clinician for evaluation of headache for 1 month duration. A brain CT was obtained which revealed a large solitary extra axial, epidural mass (4.9 x 4.1 x 3.9 cm) in the right parietal region, with mass effect and bony involvement (Fig. 1-4). The patient was a known case of cervical soft tissue primitive neuroectodermal tumor. He presented with a right mandibular angle mass about 4 years ago (Fig. 5) and underwent subsequently surgery. The resultant pathology specimen had been reported as

neuroepithelioma tumor by light microscopy and histochemical surveys (Fig. 6). The patient did not undergo chemotherapy before or after surgery, and treated only by radiotherapy. Primary location for the tumor was the right infratemporal fossa and masticator space extending down to right side of the oral cavity.

Surgery was performed for the brain lesion, which was excised totally following a right craniotomy and sent for evaluation by light microscopy and histochemical survey to three pathology centers. The mass was well circumscribed, with some invasion to the surrounding bony structures (Fig. 3 and Fig. 4). The cut surface of the lesion was solid and tan colored. Microscopically (HE stain) the tumor consisted of small round blue cells in solid and trabecular pattern. Also, it consisted of solid sheets of cells divided into irregular masses by fibrous strands. Individual cells were small and uniform. The cell outlines were indistinct, resulting in a "syncytial" appearance. The nuclei were round, with frequent indentations, small nucleoli, and brisk mitotic activity. Also seen was a well-developed vascular network. Some of the tumor cells arranged themselves around the vessels in a pseudo rosette fashion. Exceptionally, a few true rosettes (without central lumen) were formed (these having provided some of the early evidence for a neuroepithelial differentiation in this neoplasm). Necrosis was seen. Immunohistochemical studies performed for differential diagnosis of round small blue cell tumors, in which

they were positive for vimentin, neuron-specific enolase (providing evidence for neuroepithelial differentiation), CD99 (a cell membrane protein coded by a gene located on the short arms of the X and Y chromosomes that is consistently expressed by the cells of Ewing's sarcoma (ES)/PNET) while they were negative for LCA, CD3 and CD20. With these findings a diagnosis of PNET was rendered. Magnetic resonance imaging (MRI) was not performed because it was not requested by the surgeon prior to surgery, and also in regard of the patient's economic situation. After diagnosis, the patient has undergone chemotherapy (a regimen including, vincristine, actinomycin D, cyclophosphamide and doxorubicin) and radiotherapy. The patient was followed by a medical oncologist every 2-3 months. Follow up CT scan of the brain, chest, and abdomen were normal after two years of surgery. This is the first reported case of epidural metastasis of a head and neck (peripheral) PNET.

#### DISCUSSION

PNETs include a subgroup of embryonal tumors that originated from primitive or undifferentiated neuroepithelial cells. Embryonal tumors typically occur in infants and children. Medulloblastoma is the most common tumor of this group. Other less common tumors of this group are PNETs, ependymoblastomas, medulloepitheliomas, and atypical teratoid/rhabdoid tumors (ATRTs) (Ref. 3, Ref. 4). PNETs are described as central (originating from the central nervous system) and peripheral PNETs based on their origin. By definition, a peripheral neuroepithelioma is a PNET arising from peripheral, nonautonomic neural tissue (Ref. 1, Ref. 5). Peripheral PNETs are uncommon. The most common locations of peripheral PNETs have been reported in the thoracopulmonary region, the retroperitoneal paravertebral soft tissues, the soft tissues of the head and neck, and the intraabdominal and intrapelvic soft tissues and extremities.

Metastases are quite common at the time of diagnosis, most often involving bone, bone marrow, lymph nodes, lungs, and liver (Ref. 2, Ref. 6). But to our knowledge this patient hadn't have metastasis at the time of diagnosis. Metastases of PNETs to leptomeninges have been also reported, mainly from central PNETs (Ref. 5). PNETs could have metastases to the skull the same as other bones too. However, epidural metastases from peripheral PNET have not been reported yet.

Differential diagnosis of epidural or dural metastasis is most often secondary to carcinoma of the breast, lymphoma, carcinoma of the prostate, and neuroblastoma (which is one of the PNET tumors, Other common sources are carcinomas of the lung and kidney (Ref. 7).

The histopathologic hallmark of PNET/ES is sheets of densely packed, small, round cells with scant clear cytoplasm and vesicular, hyperchromatic regular nuclei (Ref. 8). The presence of strong vimentin and CD99 membranous reactivity is typical of peripheral PNET (Ref. 3, Ref. 9). Although the imaging appearance of peripheral PNETs is nonspecific, radiological studies such as CT scanning and magnetic resonance imaging (MRI) are essential in determining the limits of tumor involvement and ruling out metastatic disease. On CT scans, PNETs appear as heterogeneous masses, often

invading surrounding tissues, including bone. MRI reveals a mass isointense to muscle on T1-weighted images, while hyperintense on T2-weighted images (Ref. 3, Ref. 9). These tumors commonly show heterogeneous enhancement with internal hemorrhage and necrosis. They might be locally aggressive with vascular invasion and invasion of adjacent organs and have metastatic potential. Sometimes, these tumors may show internal septations or calcifications (Ref. 9).

PNET is a very aggressive neoplasm and it has a poor prognosis, with a 5-year symptom free survival rate of 45–55% (Ref. 10). The gene expression of the peripheral PNET that metastasizes is probably different from the gene expression of the peripheral PNET that is restricted to the site of the origin (Ref. 4). In this case, although the tumor had metastasized after 4 years, the behavior of the tumor was not highly aggressive because 2 years after skull surgery the patient remains symptom free (Ref. 11). Also the physical examination and CT scan of the patient were normal after 2 years of surgery.

Management includes aggressive surgery in combination with/without chemotherapy (Adriamycin, Cyclophosphamide, Ifosfamide, and Vincristine) and/or radiotherapy (Ref. 2, Ref. 12, Ref. 13). As in this patient, a combination of surgery followed by radiotherapy and chemotherapy was preferred. Despite aggressive treatment, recurrence is common; often occurring in the early post treatment phase; but in our patient after 2 years of epidural metastasis there were no obvious signs of tumor recurrence.

#### TEACHING POINT

PNETs are aggressive embryologic tumors with a poor prognosis and are divided in central and peripheral types. Although peripheral PNETs spread early to bones, lymph nodes, lung and liver, a leptomeningeal spread, as in this case, is extremely rare.

#### ABBREVIATIONS

PNET: Primitive neuroectodermal tumor.  
ES: Ewing's sarcoma.  
CT: Computed tomography.  
MRI: Magnetic resonance imaging.  
HE: Hematoxylin & Eosin

#### REFERENCES

1. Majós C, Alonso J, Aguilera C, Serrallonga M, Acebes JJ, Arús C, Gili J. Adult primitive neuroectodermal tumor: proton MR spectroscopic findings with possible application for differential diagnosis. *Radiology*. 2002 Nov;225(2):556-66.
2. Somers GR, Shago M, Zielenska M, Chan HS, Ngan BY. Primary Subcutaneous Primitive Neuroectodermal Tumor with Aggressive Behavior and an Unusual Karyotype: Case Report. *Pediatr Dev Pathol*. 2004 Sep-Oct;7(5):538-45.

3. Armbruster C, Huber M, Prosch H, Dworan N, Attems J. Ewing's sarcoma and peripheral primitive neuroectodermal tumor in adults: different features of a rare neoplasm. *Onkologie* 2008 Apr;31(4):179-84.

4. Weissferdt A, Neuling K, English M, Arul S, McMullan D, Ely A, et al. Peripheral primitive neuroectodermal tumor with postchemotherapy neuroblastoma-like differentiation. *Pediatr Dev Pathol* 2006 May;9(3):229-33.

5. Mattos JP, Bonilha L, Ferreira D, Borges W, Fernandes YB, Borges G. Multiple systemic metastases of posterior fossa - primitive neuroectodermal tumor (PF-PNET) in adult. *Arq Neuropsiquiatr*. 2003 Mar;61(1):100-3.

6. Meazza C, Ferrari A, Fumagalli M, Collini P, Casanova M, Pugni L, et al. A case of congenital peripheral primitive neuroectodermal tumor presenting with multiple metastases. *J Pediatr Hematol Oncol* 2008 Jan;30(1):36-8.

7. Posner JB, Chernik NL: Intracranial metastases from systemic cancer. *Adv Neurol*. 1978;19:579-92. 2008.

8. Begemann M, Lyden D, Rosenblum MK, Lis E, Wolden S, Antunes NL, Dunkel IJ. Primary leptomeningeal primitive neuroectodermal tumor. *J Neurooncol*. 2003 Jul;63(3):299-303.

9. Kim MS, Kim B, Park CS, Song SY, Lee EJ, Park NH, Kim HS, Kim SH, Cho KS. Radiologic findings of peripheral primitive neuroectodermal tumor arising in the retroperitoneum. *AJR Am J Roentgenol*. 2006 Apr;186(4):1125-32.

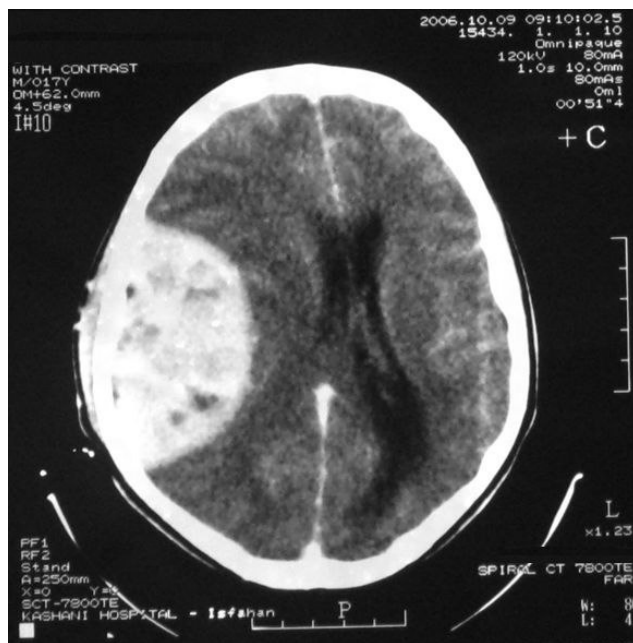
10. Yamazaki T, Kuroki T, Katsume M, Kameda N. Peripheral primitive neuroectodermal tumor of the jugular foramen: case report. *Neurosurgery* 2002 Nov;51(5):1286-9.

11. Moschovi M, Trimis G, Stefanaki K, Anastasopoulos J, Syriopoulou V, Koulouki E, et al. Favorable outcome of Ewing sarcoma family tumors to multiagent intensive preoperative chemotherapy: a single institution experience. *J Surg Oncol* 2005 Mar 15;89(4):239-43.

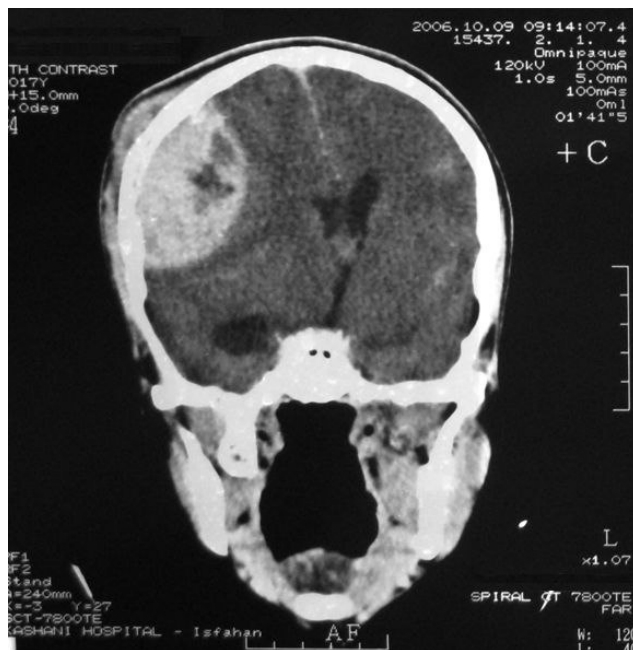12. Cebrian JL, Ibarzabal A, Garcia-Crespo R, Marco F, Ortega L, Lopez-Duran L. Peripheral primitive neuroectodermal tumor after radiotherapy. *Clin Orthop Relat Res* 2003 Aug;(413):255-60.

13. Nikitakis NG, Salama AR, O'Malley BW, Jr., Ord RA, Papadimitriou JC. Malignant peripheral primitive neuroectodermal tumor-peripheral neuroepithelioma of the head and neck: a clinicopathologic study of five cases and review of the literature. *Head Neck* 2003 Jun;25(6):488-98.

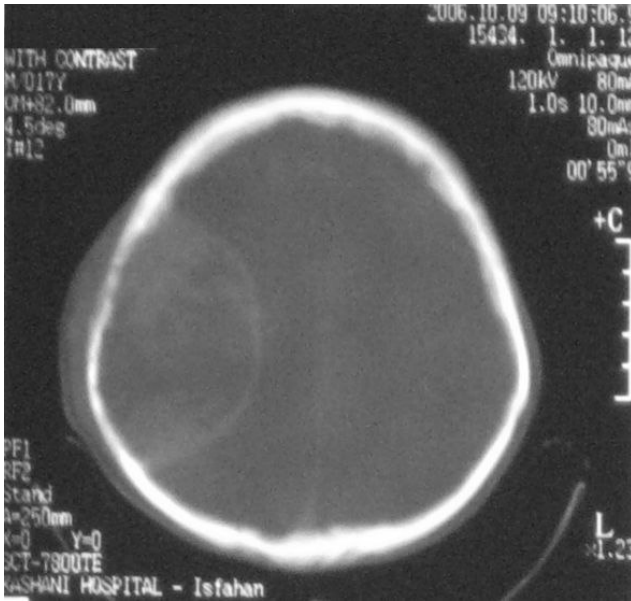
FIGURES



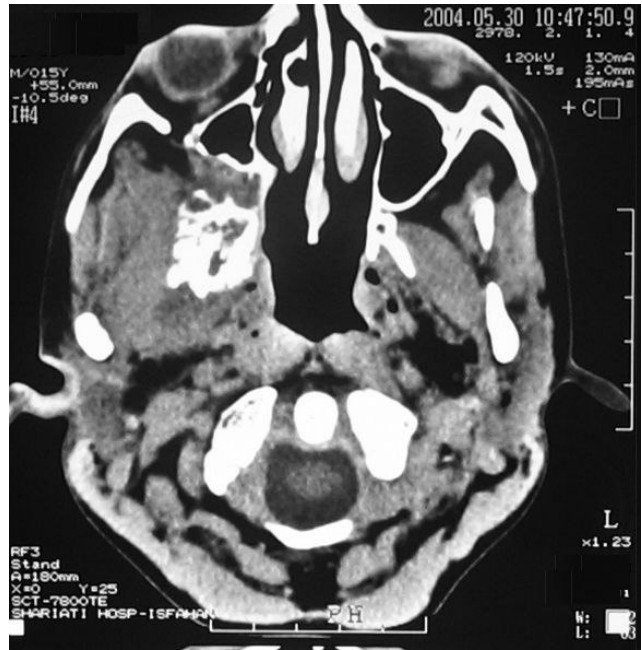**Figure 1:** Axial CT scan of the head with IV contrast, showing a large extra axial, heterogeneously enhancing mass (neuroepithelioma).



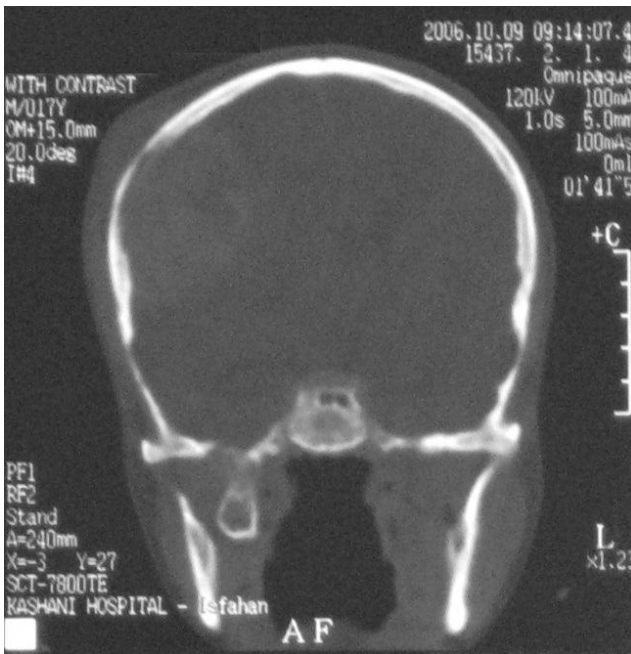
**Figure 2:** Coronal CT scan of the head with IV contrast, showing a heterogeneously enhancing, extra axial mass (neuroepithelioma), with bony involvement and extension into the overlying scalp soft tissues.



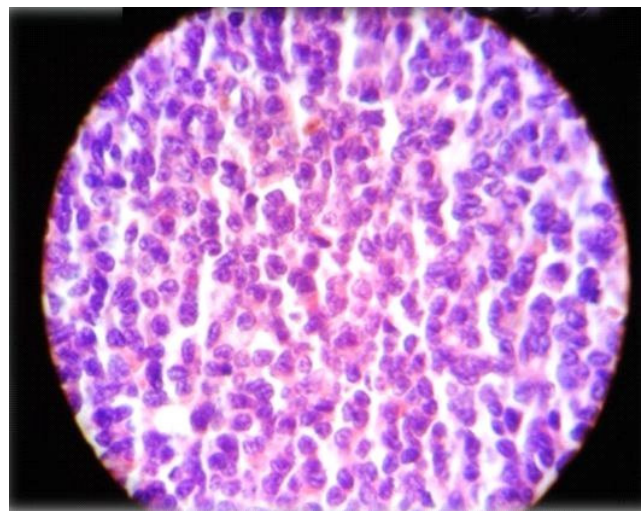
**Figure 3:** Axial CT scan of the head in bone window demonstrates local erosion and involvement of both internal and external tables of the right frontoparietal bones (more prominent on internal table) by an epidural mass (neuroepithelioma).



**Figure 5:** Axial CT scan of the neck with IV contrast. Right infratemporal, heterogeneously enhancing mass (neuroepithelioma) with unilateral pterygoid plate involvement.



**Figure 4:** CT scan of the head in coronal view and bone window demonstrates local erosion and involvement of both internal and external tables of the right frontoparietal bones (more prominent on internal table) by an epidural mass (neuroepithelioma).



**Figure 6:** Light microscopic view of the resected mass (neuroepithelioma). High power field (magnification of 400), showing small to moderate sized, relatively uniform round cells, with inconspicuous nucleoli and scant cytoplasm. (Hematoxylin & Eosin staining).

URL of this article:

[www.radiologycases.com/index.php/radiologycases/article/view/13](http://www.radiologycases.com/index.php/radiologycases/article/view/13)

Published by EduRad



[www.EduRad.org](http://www.EduRad.org)