

Seahorse

Kai-hung Fung^{1*}, Yiu Shiobhon Luk¹

1. Department of Radiology, Pamela Youde Nethersole Eastern Hospital, Hong Kong, China

* **Correspondence:** Dr. Kai-hung Fung, Department of Radiology, Pamela Youde Nethersole Eastern Hospital, 3 Lok Man Road, Chai Wan, Hong Kong, China
(✉ khfung@ha.org.hk)

Radiology Case. 2012 Jun; 6(6):35-36 :: DOI: 10.3941/jrcr.v6i6.1170

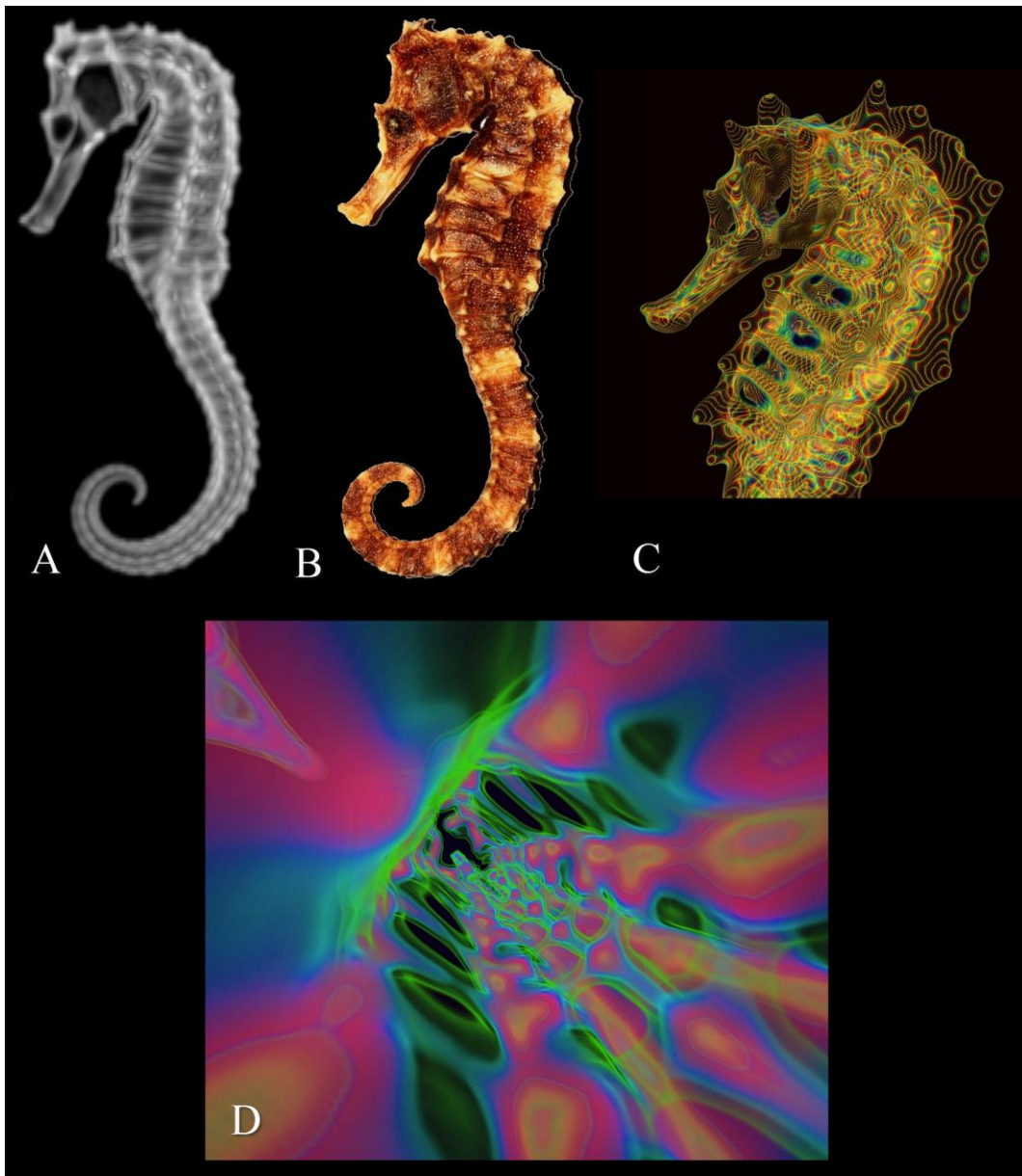
INTERESTING IMAGE

Seahorse

Seahorse belongs to the genus *Hippocampus*, a strange sea creature with its head resembling that of a horse. Seahorses are found in tropical and temperature zone shallow and sheltered waters throughout the world.

Seahorses are used in traditional Chinese medicine (TCM) as a tonic food. They are believed to enhance the Yin component of the Yin-Yang concept of health imbalance in TCM concept of health and disease. Seahorses are also associated with the liver and kidney meridians. As such, they are useful in conditions such as asthma, arteriosclerosis, incontinence, impotence, high cholesterol, throat infections, insomnia and many other ailments. They can also be applied to the skin to treat sores and infections.

The imaging data of the artwork was derived from computed tomography (CT) examination of a dried seahorse bought from a local traditional Chinese medicine shop in Hong Kong (Figures A and B). Thin-section (0.5mm) volumetric data, acquired with a 64-section multi-detector CT scanner, were then processed with medical 3D software (Vitrea 2.0) for 3D reconstruction. The 3D image was then further modified using the 'Rainbow Technique' developed by Dr Kai-hung Fung (Figure C) [1]. The 3D image of the seahorse was further manipulated in virtual reality. Figure D is a virtual endoscopic view inside the thorax of the seahorse looking towards the tail of the seahorse.



(A) CT scan of dried seahorse in maximum intensity projection (MIP).
 (B) Photograph of dried seahorse as sold in Chinese medicine shops in Hong Kong.
 (C) Artwork of seahorse created from CT scan data using the unique "Rainbow Technique" of 3D color rendering pioneered by Dr. Kai-hung Fung.
 (D) Artwork by Dr. Kai-hung Fung created from CT scan data showing virtual endoscopic view inside the thorax of a dried seahorse looking towards the tail of the seahorse. The spine of the seahorse is located on the right lower quadrant of the image and the anterior chest wall is located on the left upper quadrant of the image. The tail of the seahorse is at the centre of the image and the 2 rows of adjacent oval spaces are the intercostal spaces.

Reference: 1. Fung KH. The rainbow technique: and innovative approach to the artistic presentation of 3D computed tomography. LEONARDO 2006;39(2):101-3

URL of this article:

www.radiologycases.com/index.php/radiologycases/article/view/1170

Published by EduRad



www.EduRad.org